

Endovascular Therapy for Aneurysmal Subarachnoid Hemorrhage Complicated by Neurogenic Pulmonary Edema and Takotsubo-Like Cardiomyopathy: A Report of Ten Cases

Abstract

Objective: Patients sustaining aneurysmal subarachnoid hemorrhage (aSAH) can be further complicated by neurogenic pulmonary edema (NPE) and Takotsubo-like cardiomyopathy (TCM) with dismal outcomes. The present study aimed to validate the efficacy of endovascular therapy for patients with aSAH complicated by NPE and TCM. **Materials and Methods:** Patients who were diagnosed with aSAH complicated by NPE and TCM and treated by endovascular therapy were retrospectively evaluated. **Results:** In the past 5 years, a total of ten female patients with aSAH were also diagnosed with NPE and TCM. Six of the ten were cases with high-grade aSAH (Hunt and Hess Grades IV and V), whereas four were low-grade aSAH (Grades II and III). The locations of ruptured aneurysms were the internal carotid-posterior communicating artery junctional site in five patients, the anterior communicating artery in two, the vertebral artery in two, and the middle cerebral artery in one. These aneurysms were successfully embolized by endovascular therapy without any procedure-associated complications. The clinical outcome measure at 6 months after discharge on the Modified Rankin Scale was found to be 0 in four patients, 1 in two, 3 in one, and 5 in three. **Conclusions:** Endovascular therapy can be a feasible, alternative measure for the treatment of patients with high-grade aSAH who also have NPE and TCM.

Keywords: Aneurysmal subarachnoid, endovascular therapy, hemorrhage, neurogenic, pulmonary edema, Takotsubo-like cardiomyopathy

Introduction

Outcomes of aneurysmal subarachnoid hemorrhage (aSAH) with Hunt and Hess (H and H) Grades IV and V are still poor.^[1] Such high-grade aSAH is likely to be complicated by cardiopulmonary dysfunction such as neurogenic pulmonary edema (NPE) and Takotsubo-like cardiomyopathy (TCM). NPE is estimated to be present in 2%–29% of patients with aSAH,^[2] whereas TCM is thought to be present in 4%–15% of them.^[3] It is important to diagnose aSAH-associated NPE and TCM because they are not only critical conditions necessitating prompt and appropriate managements but also important prognostic factors.^[4–6] Endovascular therapy has become a popular alternative to open microsurgical clipping in the treatment of aSAH.^[7,8] However, there are very few reports documenting the efficacy of endovascular therapy for patients with

aSAH complicated by NPE and TCM.^[8] The present study aimed to validate it.

Materials and Methods

The present study was performed in accordance with the human ethical guidelines of our institution. Written informed consent was obtained from all the patients upon commencement of this study. Initially, medical records of the patients who were diagnosed with aSAH and treated by endovascular therapy over the past 5 years were retrieved from the Juntendo University Urayasu Hospital database. Among them, files of cases complicated by NPE and TCM were extracted for analysis. For the period, we assessed aSAH grade at presentation with H and H scale, and endovascular therapy was chosen as the first-line measure for the treatment of patients with aSAH, regardless of the sites responsible for cerebral aneurysms.

This is an open access journal, and articles are distributed under the terms of the Creative Commons Attribution-NonCommercial-ShareAlike 4.0 License, which allows others to remix, tweak, and build upon the work non-commercially, as long as appropriate credit is given and the new creations are licensed under the identical terms.

For reprints contact: reprints@medknow.com

How to cite this article: Nonaka S, Oishi H, Tsutsumi S, Ishii H. Endovascular therapy for aneurysmal subarachnoid hemorrhage complicated by neurogenic pulmonary edema and takotsubo-like cardiomyopathy: A report of ten cases. *Asian J Neurosurg* 2020;15:113-9.

Submission: 08-11-2019 **Accepted:** 16-01-2020
Published: 25-02-2020

**Senshu Nonaka,
Hidenori Oishi¹,
Satoshi Tsutsumi,
Hisato Ishii**

*Department of Neurosurgery,
Juntendo University
Urayasu Hospital, Urayasu,
Chiba, Japan, ¹Department
of Neurosurgery, Juntendo
University School of Medicine,
Tokyo, Japan*

Address for correspondence:
Dr. Senshu Nonaka,
Department of Neurosurgery,
Juntendo University
Urayasu Hospital, 2-1-1
Tomioka, Urayasu,
Chiba 279-0021, Japan.
E-mail: snonaka@juntendo.ac.jp

Access this article online

Website: www.asianjns.org

DOI: 10.4103/ajns.AJNS_331_19

Quick Response Code:



Clinical criteria for NPE included auscultation of crackles suggesting fluids in the lungs and bronchi, in addition to chest radiography showing diffuse infiltrates within the lung fields.^[4,5] Clinical criteria for TCM included echocardiographic findings, indicating abnormal motions in the regional walls. In addition, elevation and depression in ST-T segment, prolongation of QT interval, and inversion of T-wave were recorded as supplementary, abnormal electrocardiographic findings that could be associated with cardiac dysfunctions. The cardiologists diagnosed as NPE and TCM. We chose endovascular therapy for all the ruptured cerebral aneurysms complicated by NPE and TCM. During endovascular procedures, heparin was intravenously administered so as to maintain activated clotting time approximately at twice the normal control value. At the start of the procedure, a 6 Fr guiding sheath was deployed in the parent vessel through the right femoral artery. A microcatheter was advanced through the guiding catheter until the tip reached near the neck of aneurysm. Then, the aneurysm was embolized with platinum coils. The NPE and TCM were not treated during endovascular procedures, just starting to manage immediately after the procedure. We stabilized general condition of the treated patients with cardiologists during acute phase after endovascular therapy. Cardiologists checked the chest radiography, echocardiography, gain or loss of daily total fluid balance, and electrocardiographic findings of the patients. When a total fluid balance was assessed to be excessive, more than 1500 ml/24 h, or the patients' respiratory status got worse with an emergence of infiltrates on chest radiography, intravenous administration of diuretics (furosemide: 5–20 mg/day) was started. Furthermore, mechanical ventilation was conducted with sedatives for altered conditions caused by NPE and TCM. A positive pressure ventilation was performed set at 5–8 mmHg. If patients' systolic blood pressure decreased below 80 mmHg, continuous intravenous infusion of vasopressor was started for maintaining it above 120 mmHg. Outcome of the treatment was evaluated, and grades were assigned to individual patients on the Modified Rankin Scale (mRS) after 6 months of discharge.

Results

In total, thirty patients underwent microsurgical clipping for ruptured cerebral aneurysms, and 74 patients underwent endovascular therapy between September 2013 and December 2018. Endovascular therapy group comprised 54 males and 20 females, with a mean age of 59.5 ± 13.6 years (range: 28–89 years). In patients belonging to the group, SAH grades at presentation that were assessed with H and H grade were as follows: Grade I for 9 patients, Grade II for 20, Grade III for 14, Grade IV for 9, and Grade V for 19. In 74 patients, ruptured aneurysms were located in the anterior circulation, whereas in 5, aneurysms were identified in the posterior circulation. Ten of the 104 patients with ruptured cerebral aneurysms (9.6%) were complicated by NPE and TCM. Further, abnormal electrocardiographic findings were identified in all the ten patients. These results were variable, and there was no specific finding. The patients underwent coil embolization within 72 h from the onset for obliterating ruptured aneurysms, following careful evaluation of the cardiopulmonary function and stabilization of general condition. All the ten patients were female, presenting with H and H Grade II (one patient), Grade III (three patients), Grade IV (one patient), and Grade V (five patients) [Table 1]. Locations of ruptured aneurysms were as follows: the internal carotid artery–posterior communicating artery (ICA-PCoA) junctional site in five patients, anterior communicating artery in two, intracranial vertebral artery (VA) in two, and middle cerebral artery in one. Two aneurysms identified on the VA were considered as dissecting in etiology based on their clinical symptoms and angiographical appearance. Compared to the anterior circulation, NPE and TCM were more frequent complications in patients with aneurysms of the posterior circulation (11.6% vs. 40.0%). For seven patients, endovascular procedure was carried out under general anesthesia, whereas three underwent the procedure with local anesthetics and intravenous sedatives for low ejection fraction of <20%. These aneurysms were successfully embolized without any identifiable

Table 1: Summary of 10 cases complicated by neurogenic pulmonary oedema and takotsubo-like cardiomyopathy

| | Age (y) | Sex | H & H grade | Aneurysm Location | Anaesthesia | mRS after 6M |
|---------|---------|-----|-------------|-------------------|-------------|--------------|
| Case 1 | 49 | F | 5 | AcoA | General | 0 |
| Case 2 | 54 | F | 5 | Lt. ICA-PcoA | Local | 1 |
| Case 3 | 68 | F | 2 | Rt. MCA | General | 0 |
| Case 4 | 46 | F | 5 | Lt. ICA-PcoA | Local | 5 |
| Case 5 | 68 | F | 4 | Acom | General | 5 |
| Case 6 | 73 | F | 5 | Lt. ICA-PcoA | General | 5 |
| Case 7 | 47 | F | 3 | Lt. VA | Local | 0 |
| Case 8 | 48 | F | 3 | Rt. ICA-PcoA | General | 3 |
| Case 9 | 35 | F | 5 | Rt. VA | General | 1 |
| Case 10 | 52 | F | 3 | Lt. ICA-Pcom | General | 0 |

AcoA: Anterior communicating artery; F: Female; H & H: Hunt and Hess; Lt: Left; MCA: Middle cerebral artery; mRS: Modified Rankin Scale; Rt: Right; VA: Vertebral artery

endovascular procedure-associated complications. In all the patients, time taken from the placement of guiding sheath into the femoral artery to the completion of the coiling was within 2 h. The mRS score at 6 months after discharge from the hospital was 0 in four patients, 1 in two, and 3 in one. Thus, the outcome of seven patients (70%) was favorable with a mRS score of 0–3. In the remaining three patients, mRS was 5. In patients who underwent endovascular therapy but were not present NPE or TCM, the mRS score at 6 months after discharge was 0–3 in 48 patients, 4–5 in 11, and 5 in 6. The favorable outcome (mRS: 0–3) without NPE and TCM was 75.0%.

Illustrative case 1

A 54-year-old previously healthy woman with severe headache, disturbed consciousness, and H and H Grade V was referred to our hospital. Her blood pressure at the time of presentation was 88/50 mmHg, and the oxygen saturation was 82% without external administration of pure oxygen. Her chest radiography revealed diffuse infiltrates, bilaterally in the lung fields with crackles on auscultation [Figure 1]. Electrocardiography demonstrated abnormal depressions in ST-T segments. Cardiac echocardiography showed abnormal motions in the left ventricular walls, consistent with TCM. The ejection fraction was assessed to be 10%. Emergent catheter angiography demonstrated that there were no coronary lesions responsible for cardiac dysfunction. Noncontrast cranial computed tomography (CT) scans at the presentation showed diffuse thick SAH and accompanying mild ventriculomegaly [Figure 2]. Three-dimensional CT angiography revealed a saccular aneurysm at the left ICA-PCoA junctional site, measuring 11 mm in maximum dimension. Based on these findings, the patient was diagnosed with aSAH complicated by NPE and TCM. The patient underwent coil embolization with local anesthetics and intravenous administration of midazolam for severely depressed cardiac function. The aneurysm was successfully embolized without identifiable procedure-associated

complications [Figures 3 and 4]. Echocardiographic findings of the patient showed a gradual improvement with resolution of signs of pulmonary edema on chest radiography in the following 1 week. After placement of a ventriculoperitoneal shunt for persistent communicating hydrocephalus, the patient was discharged on the 56th day after the operation with mRS 2.

Illustrative case 2

A 35-year-old previously healthy woman sustained abrupt disturbance of consciousness 2 days after delivery, during hospitalization in our hospital. She was discovered to be comatose with H and H Grade V. Noncontrast cranial CT scans showed diffuse and thick SAH [Figure 5]. Her chest radiography revealed diffuse infiltrates, bilaterally in the lung fields with crackles on auscultation [Figure 6]. Electrocardiography demonstrated abnormal depressions in ST-T segments. Cardiac echocardiography showed abnormal motions in the left ventricular walls, consistent with TCM. The ejection fraction was assessed to be 10%. Three-dimensional CT angiography revealed a fusiform dissecting aneurysm at the right VA, where the right posterior inferior cerebellar artery (PICA) was found to arise from the dome of the aneurysm [Figure 7]. Based on these, the patient was diagnosed with aSAH complicated by NPE and TCM. The patient underwent coil embolization with local anesthetics and intravenous administration of midazolam for severely depressed cardiac function. The aneurysm was successfully occluded involving the original site of the right PICA and a segment of the VA proximal to the site [Figure 8]. Territory of the right PICA was perfused by the left PICA and ipsilateral right anterior inferior cerebellar artery, and there were no procedure-associated complications after surgery. The patient was under control of mechanical ventilation for 2 weeks because of the disturbed cardiac function. Her echocardiographic findings showed a gradual improvement with resolution of signs of

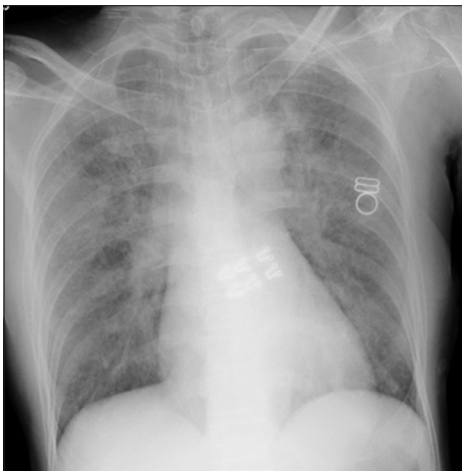


Figure 1: Chest X-ray, anteroposterior view, showing diffuse infiltrates bilaterally in the lung field indicating pulmonary edema

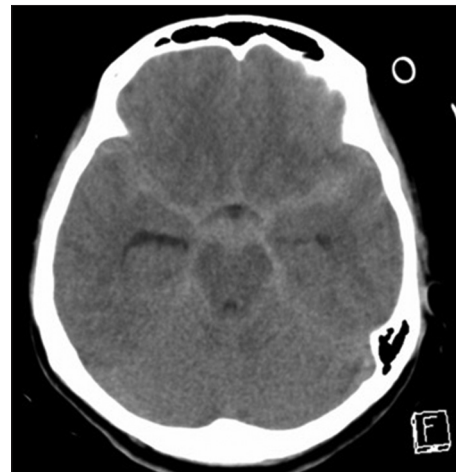

Figure 2: Noncontrast axial computed tomography scans taken at presentation showing diffuse subarachnoid hemorrhage and mild ventriculomegaly

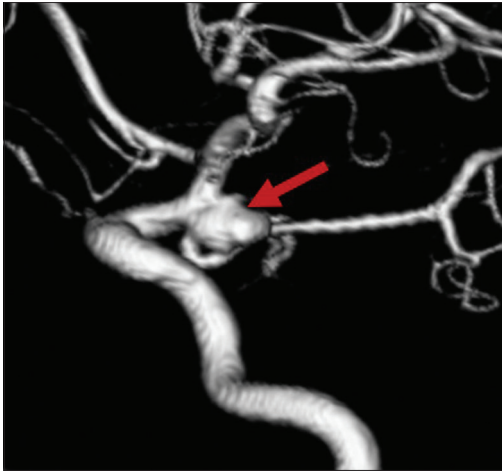

Figure 3: Three-dimensional left internal carotid angiography, oblique view, showing a saccular aneurysm (arrow) on the internal carotid-posterior communicating artery junctional site. ICA: Internal carotid artery; PCoA: Posterior communicating artery

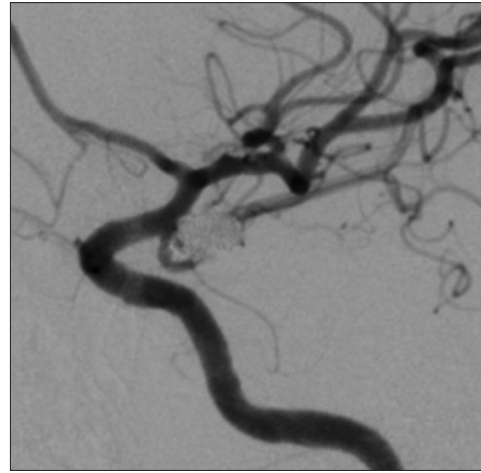


Figure 4: Left internal carotid angiography, after coil embolization, showing successful obliteration of the aneurysm

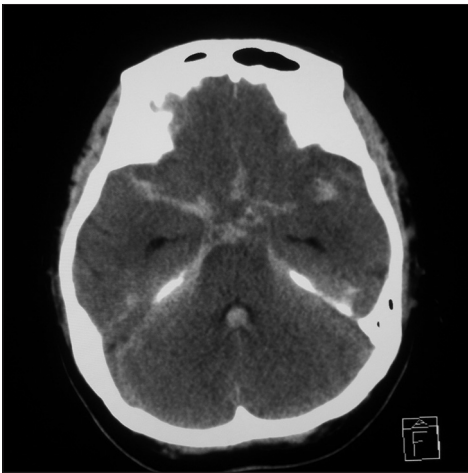


Figure 5: Noncontrast axial computed tomography scans taken at the onset showing diffuse subarachnoid hemorrhage

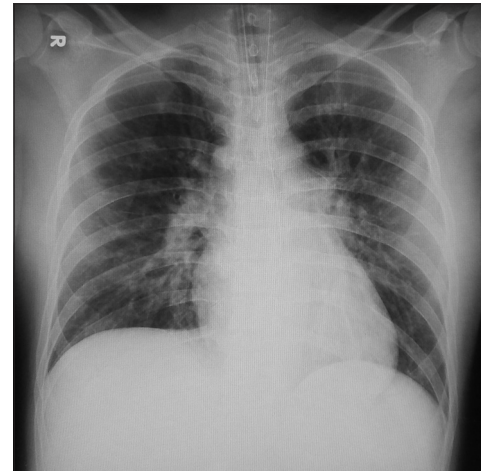


Figure 6: Chest X-ray, anteroposterior view, showing diffuse infiltrates bilaterally in the lung field indicating pulmonary edema

pulmonary edema on chest radiography in the following same 2 weeks. After placement of a ventriculoperitoneal shunt for persistent communicating hydrocephalus, the patient was discharged with mRS 0.

Illustrative case 3

A 47-year-old previously healthy woman suddenly sustained severe headache and disturbed consciousness, who was referred to our hospital in H and H Grade III. Cranial CT scans showed diffuse SAH [Figure 9]. Three-dimensional CT angiography revealed a fusiform aneurysm on the left VA, where the left PICA arose from the dome of the aneurysm. Her chest radiography revealed mild infiltrates bilaterally in the lung fields with crackles on auscultation. Electrocardiography demonstrated abnormal depressions in ST-T segments. Cardiac echocardiography showed abnormal motions in the left ventricular walls, consistent with TCM. The ejection fraction was assessed to be 30%. Therefore, we diagnosed

that the patient was aSAH complicated by mild NPE and TCM. The patient underwent coil embolization under general anesthesia. On catheter angiography, the left PICA arose from the dome of the aneurysm [Figure 10]. The aneurysm was successfully embolized with a segment of the left VA and the original site of the PICA [Figure 11]. Postoperatively, procedure-associated complications were not noted. The patient extubated the next day of embolization; however, her respiratory status gradually deteriorated by progression of NPE and TCM. Then, the patient was again intubated on postembolization day 6 and was treated of NPE and TCM with diuretics and continuous intravenous administration of sedatives, under mechanical ventilation. Echocardiographic findings of the patient showed a gradual improvement with resolution of signs of pulmonary edema on chest radiography in the next 1 week. Her respiratory status was gradually improved after 2 weeks. Although posttreatment cerebral magnetic resonance imaging showed an ischemic region in the occluded PICA territory [Figure 12], the patient

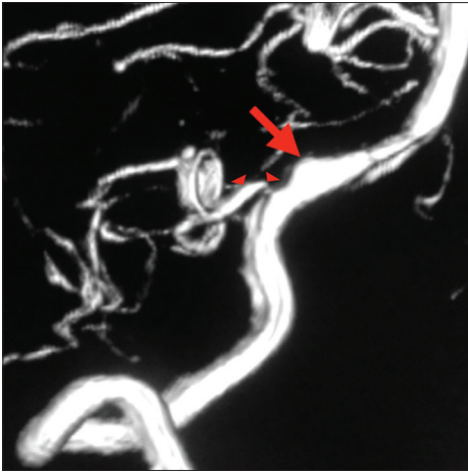


Figure 7: Three-dimensional right vertebral artery angiography, oblique view, showing a fusiform aneurysm (arrow). The right posterior inferior cerebellar artery arises from the dome of the aneurysm (arrowheads)

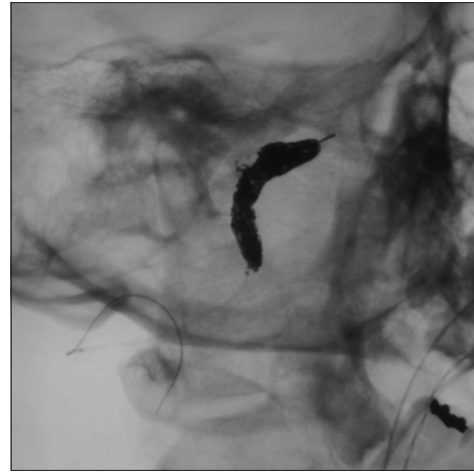


Figure 8: Right vertebral angiography, after coil embolization, showing successful obliteration of the offending aneurysm involving the original site of the posterior inferior cerebellar artery and a segment of the vertebral artery proximal to the site

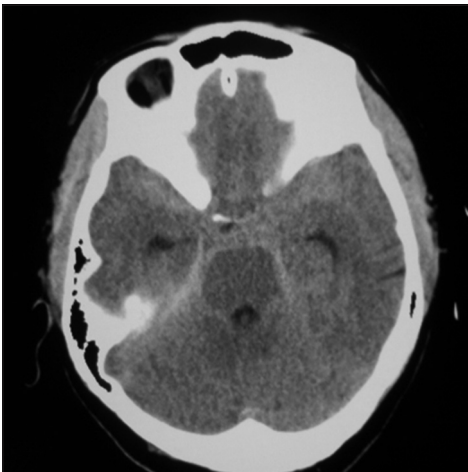


Figure 9: Noncontrast axial computed tomography scan taken at the presentation showing diffuse subarachnoid hemorrhage

was discharged with mRS 1 on the 38th postoperative day without ventriculoperitoneal shunt.

Discussion

Despite extensive investigations, studies on the outcome of patients with high-grade aSAH are still limited.^[1] In the present study, 60% of the cases complicated by NPE and TCM had high-grade aSAH. The most frequent location of the aneurysms was the ICA-PCoA junctional site, although previous reports documented a predisposition for the posterior circulation.^[2-5,7-11] The discrepancy may be attributed to the small population of the present study. There were no complications associated with the endovascular procedures. Furthermore, 70% of outcomes were favorable as assessment after 6 months revealed a mRS score of 0–3.

NPE has been described as the consequence of various types of brain injury, head trauma, seizure, and intracranial hemorrhages.^[12] Kato *et al.* documented that clinical conditions associated with high catecholamine levels

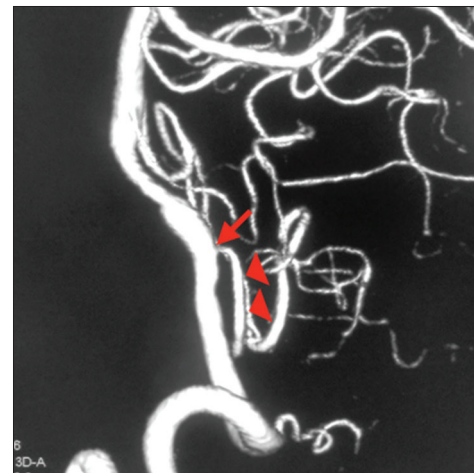

Figure 10: Three-dimensional left vertebral angiography, oblique view, showing a fusiform aneurysm (arrow). The left posterior inferior cerebellar artery arises from the dome of the aneurysm (arrowheads)

caused by diverse pathologies, acute SAH accompanying sympathetic storm, and acute thyrotoxicosis could cause TCM.^[12]

There has been a marked difference in the incidence of SAH between both the sexes, with females being the more frequently afflicted. Deshmukh *et al.* reported that women are at nine times higher risk of developing TCM compared with men.^[13] Furthermore, in aSAH cases complicated by NPE and TCM, there was a clear female preponderance.^[10] In the present study too, all the cases complicated by NPE and TCM were of female patients. We are yet to identify the reason behind such an observation.

Yabumoto *et al.* have proposed an early surgical intervention for ruptured aneurysms and management of NPE, claiming that NPE should not be an obstacle to radical intervention when cardiorespiratory control can maintain the minimal anesthetic limit.^[11] Neurosurgeons

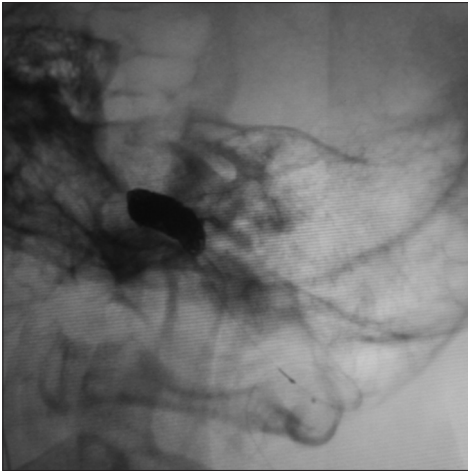


Figure 11: Left vertebral angiography after coil embolization, oblique view, showing successful obliteration of the offending aneurysm involving the original site of the posterior inferior cerebellar artery and a segment of the vertebral artery proximal to the site

may encounter a dilemma when they treat aSAH complicated by NPE and TCM.^[10] To date, however, an optimal treatment strategy for such aSAH has not been defined. Recent studies recommend early intervention with an endovascular procedure for aSAH cases complicated by NPE and TCM.^[2,8,14] Advantages of endovascular therapy for such patients involve less invasiveness and a short duration for completing the procedures.^[7] In any of our ten patients, time taken from the placement of the guiding sheath to the completion of coiling was within 2 h.

An induced hypertension for aSAH patients with normal cardiopulmonary functions is recommended to prevent delayed ischemic neurological deficit caused by cerebral vasospasm.^[15] The therapeutic strategy is, however, contraindicated in cases complicated by NPE and TCM. Cardiac prognosis related to TCM is commonly favorable for its self-limiting nature with usual resolution in a few weeks.^[16] However, once TCM has complicated with a high-grade aSAH, the treatment becomes challenging with risks of cardiopulmonary arrest and death.^[17,18]

There are certain limitations in the current study. First, it was a retrospective review of patients who were treated by coil embolization. Second, the treatment outcome of the study was not compared with that provided by open microsurgical clipping. Furthermore, as the study involved only ten patients, the obtained results cannot provide a definitive conclusion. A well-designed, randomized study involving a sufficiently large population is necessary to establish an appropriate therapeutic strategy for aSAH cases complicated by NPE and TCM. Because of a retrospective analysis, our study did not compare two populations with and without NPE and TCM who underwent endovascular treatment. Future investigation should need the comparison.

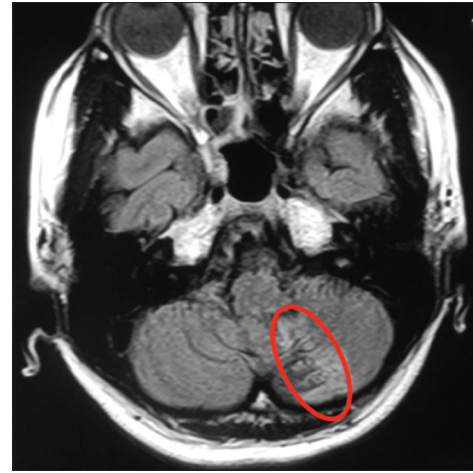

Figure 12: Axial fluid-attenuated inversion recovery image after 6 months of discharge showing ischemic changes in the territory of the left posterior inferior cerebellar artery (encircled area)

Conclusions

Although treatment outcome of high-grade aSAH is still poor, we consider that endovascular therapy can be a feasible alternative treatment for patients with high-grade aSAH complicated by NPE and TCM.

Declaration of patient consent

The authors certify that they have obtained all appropriate patient consent forms. In the form the patient(s) has/have given his/her/their consent for his/her/their images and other clinical information to be reported in the journal. The patients understand that their names and initials will not be published and due efforts will be made to conceal their identity, but anonymity cannot be guaranteed.

Financial support and sponsorship

Nil.

Conflicts of interest

There are no conflicts of interest.

References

1. Wilson DA, Nakaji P, Albuquerque FC, McDougall CG, Zabramski JM, Spetzler RF. Time course of recovery following poor-grade SAH: The incidence of delayed improvement and implications for SAH outcome study design. *J Neurosurg* 2013;119:606-12.
2. Inamasu J, Nakatsukasa M, Mayanagi K, Miyatake S, Sugimoto K, Hayashi T, et al. Subarachnoid hemorrhage complicated with neurogenic pulmonary edema and takotsubo-like cardiomyopathy. *Neurol Med Chir (Tokyo)* 2012;52:49-55.
3. Ako J, Honda Y, Fitzgerald PJ. Takotsubo-like left ventricular dysfunction. *Circulation* 2003;108:e158.
4. Cacciotti L, Passaseo I, Marazzi G, Camastra G, Campolongo G, Beni S, et al. Observational study on Takotsubo-like cardiomyopathy: Clinical features, diagnosis, prognosis and follow-up. *BMJ Open* 2012;2. pii: E001165.
5. McLaughlin N, Bojanowski MW, Girard F, Denault A.

- Pulmonary edema and cardiac dysfunction following subarachnoid hemorrhage. *Can J Neurol Sci* 2005;32:178-85.
6. Muroi C, Keller M, Pangalu A, Fortunati M, Yonekawa Y, Keller E. Neurogenic pulmonary edema in patients with subarachnoid hemorrhage. *J Neurosurg Anesthesiol* 2008;20:188-92.
 7. Manto A, De Gennaro A, Manzo G, Serino A, Quaranta G, Cancellà C. Early endovascular treatment of aneurysmal subarachnoid hemorrhage complicated by neurogenic pulmonary edema and Takotsubo-like cardiomyopathy. *Neuroradiol J* 2014;27:356-60.
 8. Meguro T, Terada K, Hirotsune N, Nishino S, Asano T, Manabe T. Early embolization for ruptured aneurysm in acute stage of subarachnoid hemorrhage with neurogenic pulmonary edema. *Interv Neuroradiol* 2007;13 Suppl 1:170-3.
 9. Pérez-Castellanos A, Martínez-Sellés M, Mejía-Rentería H, Andrés M, Sionis A, Almendro-Delia M, *et al.* Tako-Tsubo syndrome in men: Rare, but with poor prognosis. *Rev Esp Cardiol (Engl Ed)* 2018;71:703-8.
 10. Yokota H, Sugiura S, Ida Y, Itoh H. Neurogenic stress cardiomyopathy following aneurysmal subarachnoid hemorrhage in a very elderly patient – Case report. *Neurol Med Chir (Tokyo)* 2011;51:842-6.
 11. Yabumoto M, Kuriyama T, Iwamoto M, Kinoshita T. Neurogenic pulmonary edema associated with ruptured intracranial aneurysm: Case report. *Neurosurgery* 1986;19:300-4.
 12. Kato K, Lyon AR, Ghadri JR, Templin C. Takotsubo syndrome: Aetiology, presentation and treatment. *Heart* 2017;103:1461-9.
 13. Deshmukh A, Kumar G, Pant S, Rihal C, Murugiah K, Mehta JL. Prevalence of Takotsubo cardiomyopathy in the United States. *Am Heart J* 2012;164:66-710.
 14. Jain R, Deveikis J, Thompson BG. Management of patients with stunned myocardium associated with subarachnoid hemorrhage. *AJNR Am J Neuroradiol* 2004;25:126-9.
 15. Adamczyk P, He S, Amar AP, Mack WJ. Medical management of cerebral vasospasm following aneurysmal subarachnoid hemorrhage: A review of current and emerging therapeutic interventions. *Neurol Res Int* 2013;2013:462491.
 16. Akashi YJ, Goldstein DS, Barbaro G, Ueyama T. Takotsubo cardiomyopathy: A new form of acute, reversible heart failure. *Circulation* 2008;118:2754-62.
 17. Cardin C, Roncalli J, Lairez O, Austruy J, Elbaz M, Carrie D, *et al.* Subarachnoid haemorrhage associated with midventricular Tako-Tsubo syndrome. *Int J Cardiol* 2011;146:e46-8.
 18. Suzuki H, Sakurai M, Fujimoto M, Tsuchiya T, Sakaida H, Taki W. Complete recovery from aneurysmal subarachnoid hemorrhage associated with out-of-hospital cardiopulmonary arrest. *Eur J Emerg Med* 2010;17:42-4.