

Diagnostic Utility of Endometrial Aspiration Cytology in Women with Abnormal Uterine Bleeding

Uma Handa, Chakshu Bansal, Phiza Aggarwal, Anju Huria¹, Harsh Mohan

Departments of Pathology and ¹Obstetrics and Gynecology, Government Medical College and Hospital, Chandigarh, India

ABSTRACT

Context: Abnormal uterine bleeding (AUB) is a common problem for which women seek gynecological consultation. Endometrial aspiration cytology (EAC) has emerged as a minimally invasive and cost-effective diagnostic procedure for screening the endometrial status of these patients that can aid in diagnosis in high-burden and resource-limited settings. **Aims:** The study was conducted to evaluate the utility of EAC in women with AUB, and the cytological diagnosis was compared with the histopathology. **Materials and Methods:** A total of 100 patients presenting with AUB were subjected to EAC using a 4-mm Karman's cannula. Later, they also underwent endometrial dilation and curettage. The cytology smears were evaluated for architectural and cytomorphological features. The cytological diagnoses henceforth made were compared with the histopathological diagnosis to calculate sensitivity, specificity, and diagnostic accuracy of EAC. **Results:** EAC showed a sample adequacy of 89% viz a viz 90% for histopathology. EAC showed a sensitivity of 87.5% and 100% for diagnosing benign and malignant conditions, respectively. There was a good overall agreement between cytological and histopathological diagnosis ($\kappa = 0.585$). **Conclusions:** EAC is an effective and minimally invasive procedure for the primary investigation of women with AUB.

KEYWORDS: Abnormal uterine bleeding, endometrial aspiration cytology, histopathology

INTRODUCTION

Abnormal uterine bleeding (AUB) is a common and debilitating condition affecting women of all ages. Chronic AUB is defined as bleeding from the uterine corpus that is abnormal in volume, regularity and/or timing that has been present for the majority of the last 6 months.^[1] The condition has a high reported prevalence rate of 17.9% in India.^[2] As per the Federation of Gynecology and Obstetrics classification, uterine bleeding can occur in a variety of benign and malignant conditions such as endometrial hyperplasia, endometrial polyps, adenomyosis, leiomyoma, and malignancy.^[1] In 50% of the cases, AUB is not associated with an organic cause, where it is termed as dysfunctional uterine bleeding.^[3]

Till date, endometrial biopsy or curettage has remained as the diagnostic investigation for different endometrial lesions. However, this invasive procedure requires

hospitalization and poses a risk to the patient from anesthesia, surgical trauma, and acquired infections.^[4] Hence, it is not suitable to use it for mass screening of patients for endometrial carcinoma.^[5] Over the past decade, endometrial aspiration cytology (EAC) has emerged as an attractive alternative to biopsy for early diagnosis of endometrial lesions. It is a rapid and noninvasive modality that can be done as an outpatient department (OPD) procedure without the requirement for anesthesia.^[6] Studies done across the globe have reported its sensitivity and specificity between 83%–89% and 92%–100%, respectively.^[7–10] However, the results may not be comparable due to differences in EAC techniques used in the studies.

Address for correspondence: Dr. Uma Handa, Department of Pathology, Government Medical College and Hospital, Sector-32, Chandigarh, India. E-mail: umahanda@hotmail.com

This is an open access journal, and articles are distributed under the terms of the Creative Commons Attribution-NonCommercial-ShareAlike 4.0 License, which allows others to remix, tweak, and build upon the work non-commercially, as long as appropriate credit is given and the new creations are licensed under the identical terms.

For reprints contact: reprints@medknow.com

How to cite this article: Handa U, Bansal C, Aggarwal P, Huria A, Mohan H. Diagnostic utility of endometrial aspiration cytology in women with abnormal uterine bleeding. J Mid-life Health 2018;9:140-4.

Access this article online	
Quick Response Code: 	Website: www.jmidlifehealth.org
	DOI: 10.4103/jmh.JMH_80_18

Despite being a high-burden country for various endometrial diseases, there is a scarcity of studies comparing the efficacy of EAC with histopathology from Indian settings.^[6,7] In view of relative simplicity and cost-effectiveness, if found useful, EAC can be a better option for OPD-based routine/mass screening of patients for different endometrial conditions, especially malignancy. Hence, the present study was planned to assess the yield of EAC, quality of evidence generated (in the form of cytomorphological features) and to compare it with histopathology in the evaluation of patients with AUB.

MATERIALS AND METHODS

This was an prospective, interventional study carried out at a tertiary care hospital over a period of 1.5 years. A total of 100 women presenting with AUB to the gynecology OPD were prospectively enrolled. Informed consent was taken from the patients before the enrollment. The study was approved by the Institutional Ethics Committee.

Procedure

After a detailed history and clinical examination, patients underwent endometrial aspiration in a minor operation theater (OT) in the gynecology OPD. The material was obtained by aspiration technique using Karman's cannula with 4-mm diameter. Under aseptic precautions, the cannula was inserted into the endometrial cavity, and 5 ml of normal saline was introduced followed by suction of the cavity material using a 10 ml syringe. Aspirated contents were examined grossly for the presence of tissue fragments and smears prepared were stained with May-Grunwald Giemsa (MGG) stain, hematoxylin and eosin (H and E) stain, and Papanicolaou (PAP) stain. The cytology slides were independently reviewed by two observers and categorized into benign, malignant, or inadequate. All benign lesions were further classified as secretory phase, proliferative phase, shedding endometrium, and hyperplasia.

Different cytomorphological features, that is, cellularity, epithelial/stromal ratio, epithelial architecture, cytoplasmic vacuolations, nuclear atypia, mitosis, stromal decidualization, and background characteristics were noted on the cytology smears. Based on relative frequency of epithelium to stroma, four groups of smears were categorized: Group -ve: Only epithelial cells with absence of stromal cells; Group 1+: Epithelial cells twice as stromal cells; Group 2+: Epithelial cells same as stromal cells; and Group 3+: Epithelial cells less as compared to stromal cells.

Endometrial curettage

Endometrial curettage was performed in the same sitting in the OT by the gynecologist under short general/local

anesthesia using the standard procedure. The biopsy was fixed in 10% formalin and processed by paraffin embedding techniques. Sections of 3–5 μ thickness were cut and stained with H and E stain. The pathologist examining the histopathology slides were blinded for the cytology findings of the aspiration smears.

The impressions made on cytological analysis were compared with histopathological diagnosis for sensitivity, specificity, and diagnostic accuracy using appropriate statistical tests.

RESULTS

The mean age of patients was 44.3 + 8.6 years. Out of 100 patients, 52 were in perimenopausal group, 33 in reproductive, and 15 in postmenopausal age group.

Cytological findings

On cytological examination, totally 85 patients were diagnosed as having benign disease, 4 were as malignant, and 11 patients were rendered as inadequate. The smears were inadequate if there was no/scanty cellularity, stromal cells, or endocervical cells only. Benign cases on cytology were further subtyped into different phases as shown in Table 1.

Cytomorphological features

Different cytomorphological and architectural features were evaluated on cytology smears as shown in Table 2. It was seen that features such as epithelial/stromal ratio, architectural pattern of epithelial cells, nuclear atypia, and mitosis differentiated between benign and malignant conditions whereas epithelial architecture, cytoplasmic vacuolations, and background were important

Table 1: Distribution of diagnosis by cytology and histopathology (n=100)

Cytological diagnosis	Number of cases	Histopathological diagnosis	Number of cases
Secretory phase	71	Secretory phase	58
		Proliferative phase	4
		Hyperplasia without atypia	4
		Atrophic endometrium	1
		Inadequate	4
Proliferative phase	4	Proliferative phase	3
		Secretory phase	1
Shedding endometrium	6	Shedding endometrium	5
		Inadequate	1
Hyperplasia without atypia	4	Hyperplasia without atypia	4
Adenocarcinoma	4	Adenocarcinoma	4
Inadequate	11	Inadequate	5
		Proliferative phase	2
		Secretory phase	3
		Atrophic endometrium	1

cytomorphological features differentiating among individual benign conditions. All 58 cases of secretory phase confirmed on histopathology showed honeycomb sheets, cytoplasmic vacuolations, and stripped nuclei in the background [Figure 1] Tubes and dense sheets were noted in the majority of cases of proliferative phase [Figure 2]. All four cases of adenocarcinoma had predominance of singly scattered cells, irregular clusters, nuclear atypia, and mitosis [Figure 3].

Comparison between cytological and histopathological diagnosis

The sensitivity, specificity, and diagnostic efficacy of the EAC in diagnosing benign and malignant lesions of endometrium are mentioned in Table 3. There was good overall agreement between cytology and histopathology with kappa value of 0.58. It was seen that EAC was more accurate in diagnosing malignant conditions than diagnosing cyclical endometrium.

DISCUSSION

The present study evaluated the efficacy of EAC in comparison with histopathology in patients of AUB. The results showed a good agreement between EAC and histopathology. Adequacy of the representative sample

is an important factor limiting the utility of EAC. In the present study, a sample adequacy of 89% was achieved using Karman’s cannula that involves a simple and cost-effective technique. Different studies, using different technique/device for endometrial sample collection, have yielded variable adequacy rates ranging from 59% to 100%.^[7,11-13] Some of these include insemination cannula, infant feeding tube, intra-cath cannula, Isaac’s cell sampler, and pistol aspirator. However, the difference in methodology did not affect the sensitivity and specificity of the cytological results that remained between 68.2%–97% and 79%–100%, respectively.^[7]

In coherence with recent Indian studies,^[11,13] the present study showed a 100% sensitivity, specificity, and diagnostic accuracy of EAC for the diagnosis of endometrial carcinoma. However, in view of a less number of patients in the carcinoma group, the results require confirmation in bigger studies. The age of the patients in the study ranged from 22 to 64 years with 85 patients presenting in reproductive/perimenopausal age group. As a result, benign pathologies dominated the diagnoses in the study cohort. The sensitivity, specificity, and diagnostic accuracy of EAC in detecting benign pathologies

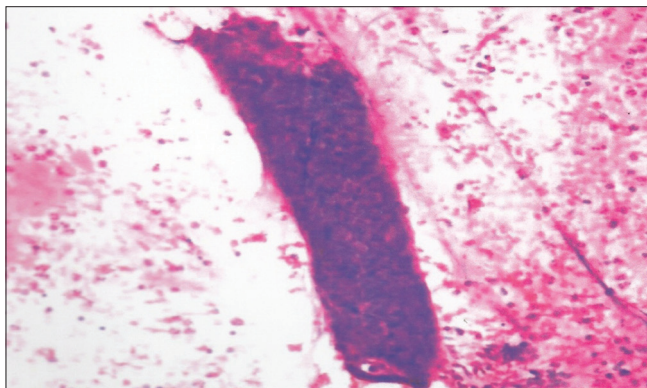


Figure 1: Smear from proliferative phase showing tubes and dense sheets of endometrial cells (H and E, ×100)

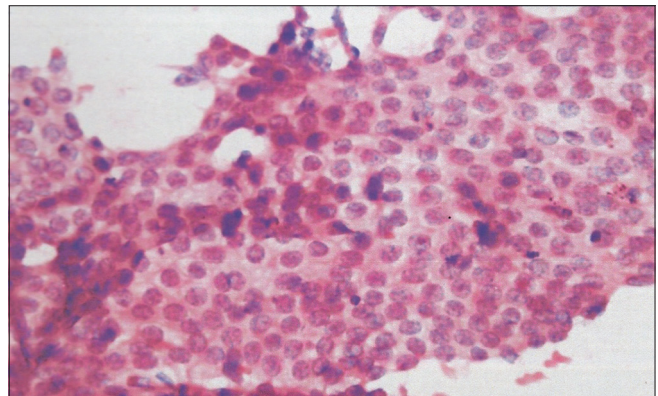


Figure 2: Secretory phase showing flat honeycomb sheet of epithelial cells with round-to-oval nucleus and vacuolated cytoplasm (H and E, ×400)

Table 2: Distribution of different cytomorphological features as studied on cytology smears

	Total (n=89)	Cellularity (3+)	Epithelial/stroma ratio Group	Epithelial architecture	Cytoplasmic vacuolation	Nuclear atypia	Mitosis	Stromal decidualization	Predominant background
Secretory phase	71	47	0	Honeycomb sheets, Tubes	69	0	2	9	Stripped nuclei
Proliferative phase	4	4	0	Tubes and dense sheets	0	0	1	0	Clean
Shedding endometrium	6	3	0	Ball-like clusters	1	0	0	0	Stripped nuclei and inflammatory
Hyperplasia without atypia	4	4	0	Oval clusters	0	0	0	0	Stripped nuclei
Adenocarcinoma	4	4	4	Irregular clusters and singly scattered	1	4	4	0	Clean (2) Necrotic (2)

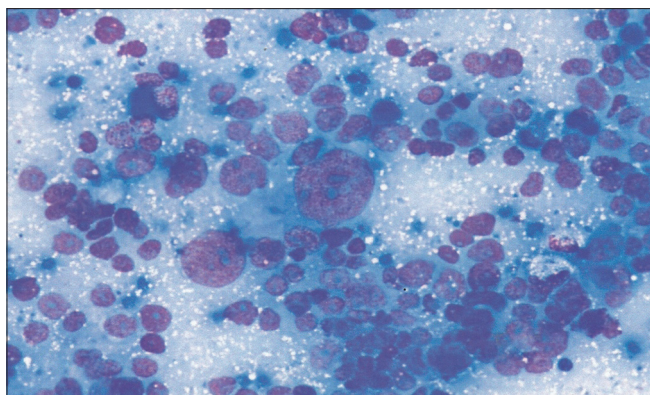


Figure 3: Smear from endometrial adenocarcinoma show scattered tumor cells with marked nuclear pleomorphism and prominent nucleoli (MGG, $\times 400$)

Table 3: Sensitivity, specificity, and accuracy of endometrial aspiration cytology

Cytological diagnosis	Sensitivity	Specificity	Diagnostic accuracy
Benign (%)	87.5	100	88
Malignant (%)	100	100	100

(including morphological hormonal evaluation) was 87.5%, 100%, and 88%, respectively. The results are comparable to previous studies that yielded a diagnostic accuracy of 93.8^[13] and 97.6%,^[11] respectively. On subgroup analysis, EAC showed 93.5% sensitivity and 76.3% specificity for detecting secretory phase whereas it was only 33% sensitive and 98.9% specific for diagnosing proliferative phase. In contrast, previous studies^[7,11,13] showed a better sensitivity to the tune of 100% in detecting proliferative phase. Less number of patients in the proliferative phase, attributed to the timing of endometrial sampling (which is usually done 2–3 days before menstruation), might have affected the results.

In the present study, a detailed cytological analysis of the endometrial samples was done based on eight cytomorphological parameters as described by Kobayashi *et al.*^[14] These parameters helped to diagnose different benign and malignant conditions of the endometrium. In coherence with previous studies,^[7,15,16] features such as the predominance of irregular clusters and singly scattered epithelial cells, nuclear atypia, and significant mitosis in a necrotic background were found to be highly specific for endometrial carcinoma [Table 2]. Secretory phase is characterized by the presence of honeycomb sheets of cells with cytoplasmic vacuolations in different studies.^[14,17] The finding that was also validated in the study.

The present study reinforced the evidence for the efficacy of EAC in the evaluation of AUB. Histopathological correlation and blinded-study design increased the authenticity of results. We used 3 staining techniques

in aspiration cytology that helped in the comprehensive evaluation of all the cytomorphological features. Being cost effective, less time-consuming with a comparable yield, the procedure may serve to be a good screening tool for endometrial carcinoma. However, one air-dried preparation (MGG stain) and either of the wet-fixed smear stains (H and E/PAP) may be a suitable alternative for screening nuclear and cytoplasmic details. Our study also had few limitations. In view of small sample size, the results may not be extrapolated to all causes of AUB. Studies with a large sample of patients having diverse benign/malignant conditions may help to consolidate the results. With a large number of devices/techniques in use for EAC, head-to-head comparison between these in future studies may help to clarify the picture.

CONCLUSION

The present study advocates the use of EAC using Karman's cannula as an initial investigation in the evaluation of patients with AUB, especially those with suspected malignancy. Further studies with large sample size with diverse etiologies might help to consolidate the role of the EAC in the evaluation of AUB.

Financial support and sponsorship

Nil.

Conflicts of interest

There are no conflicts of interest.

REFERENCES

- Whitaker L, Critchley HO. Abnormal uterine bleeding. *Best Pract Res Clin Obstet Gynaecol* 2016;34:54-65.
- Sharma A, Dogra Y. Trends of AUB in tertiary centre of Shimla hills. *J Midlife Health* 2013;4:67-8.
- Ewenstein BM. The pathophysiology of bleeding disorders presenting as abnormal uterine bleeding. *Am J Obstet Gynecol* 1996;175:770-7.
- Byrne AJ. Endocyte endometrial smears in the cytodagnosis of endometrial carcinoma. *Acta Cytol* 1990;34:373-81.
- Favre J, Bernard P, Besançon D, Siebert S. A five-year experience with intrauterine washing cytology. *Acta Cytol* 1982;26:623-9.
- Hemalatha AN, Pai MR, Raghuvver CV. Endometrial aspiration cytology in dysfunctional uterine bleeding. *Indian J Pathol Microbiol* 2006;49:214-7.
- Malik R, Agarwal R, Tandon P. Cytological assessment of endometrial washings obtained with an insemination cannula and its histological correlation. *J Cytol* 2008;25:128-32.
- Tansathit T, Chichareon S, Tocharoenvanich S, Dechsukhum C. Diagnostic evaluation of karman endometrial aspiration in patients with abnormal uterine bleeding. *J Obstet Gynaecol Res* 2005;31:480-5.
- Maksem JA, Meiers I, Robboy SJ. A primer of endometrial cytology with histological correlation. *Diagn Cytopathol* 2007;35:817-44.
- Isaacs JH, Ross FH Jr. Cytologic evaluation of the endometrium in women with postmenopausal bleeding. *Am J Obstet Gynecol* 1978;131:410-5.

11. Jadhav MV, Phatke AS, Kadgi NV, Rane SR, Kulkarni KK. Endometrial aspiration cytology in gynecological disorders. *J Cytol* 2016;33:13-6.
12. Liza Sister, Rameshkumar K, Lillian Sister. Value of endometrial aspiration cytology in assessing endometrial status in symptomatic peri and postmenopausal women. *Indian J Cancer* 1999;36:57-61.
13. Kaur N, Chahal JS, Bandlish U, Kaul R, Mardi K, Kaur H, *et al.* Correlation between cytological and histopathological examination of the endometrium in abnormal uterine bleeding. *J Cytol* 2014;31:144-8.
14. Kobayashi H, Otsuki Y, Simizu S, Yamada M, Mukai R, Sawaki Y, *et al.* Cytological criteria of endometrial lesions with emphasis on stromal and epithelial cell clusters: Result of 8 years of experience with intrauterine sampling. *Cytopathology* 2008;19:19-27.
15. Norimatsu Y, Shimizu K, Kobayashi TK, Moriya T, Tsukayama C, Miyake Y, *et al.* Cellular features of endometrial hyperplasia and well differentiated adenocarcinoma using the endocyte sampler: Diagnostic criteria based on the cytoarchitecture of tissue fragments. *Cancer* 2006;108:77-85.
16. Skaarland E. New concept in diagnostic endometrial cytology: Diagnostic criteria based on composition and architecture of large tissue fragments in smears. *J Clin Pathol* 1986;39:36-43.
17. Coscia-Porrazzi LO, Maiello FM, de Falco ML. The cytology of the normal cyclic endometrium. *Diagn Cytopathol* 1986;2:198-203.