

CASE REPORT

Pulmonary coccidioidomycosis mimicking malignancy associated with Sweet's syndrome (acute febrile neutrophilic dermatosis)

Nattanicha Chaisrimaneepan¹  | Austin Guadarrama² |
Pitchaporn Yingchoncharoen¹  | Maria Batchinsky²

¹Department of Internal Medicine,
Texas Tech University Health Sciences
Center, Lubbock, Texas, USA

²Texas Tech University Health Sciences
Center School of Medicine, Lubbock,
Texas, USA

Correspondence

Nattanicha Chaisrimaneepan,
Department of Internal Medicine,
Texas Tech University Health Sciences
Center, 3601 4th St, Lubbock, 79430
Texas, USA.
Email: [nattanicha.chaisrimaneepan@
ttuhsc.edu](mailto:nattanicha.chaisrimaneepan@ttuhsc.edu)

Key clinical message

A suspicious malignant lung nodule with cutaneous reaction is not always cancer, especially in low risk for malignancy patients. A lung biopsy should be taken into consideration. The associated cause of Sweet's syndrome directs the treatment in each patient.

KEYWORDS

acute febrile neutrophilic dermatosis, lung nodule, pulmonary coccidioidomycosis, sweet syndrome

1 | INTRODUCTION

Coccidioidomycosis, known as Valley Fever, is the disease caused by the inhalation of arthroconidia from the soil-dwelling dimorphic fungi, *Coccidioides immitis* and *Coccidioides posadasii*.¹ In the United States, coccidioidomycosis is endemic to the southwestern part of the country, with most cases located in the San Joaquin Valley of California and Southern Arizona. The incidence of coccidioidomycosis is approximately 10,000 cases reported annually.^{1,2} Coccidioidomycosis may affect any demographic, but primarily affects those aged 40–60 years old and has a slight male predominance. Clinical manifestations range from asymptomatic to disseminated infection depending on the patient's immune status.

Cutaneous manifestations in coccidioidomycosis can be classified as reactive or organism-containing lesions in secondary or primary cutaneous infection.³ Sweet

syndrome, or acute febrile neutrophilic dermatosis, is an inflammatory, non-infectious skin reaction rarely observed as one of the reactive skin manifestations of coccidioidomycosis. Patients with Sweet syndrome clinically present with fever, leukocytosis with neutrophilia, and painful erythematous papules, plaques, pustules, and nodules commonly appearing on the upper limbs, trunk, head, and neck.⁴ Here, we present a case of coccidioidomycosis associated with Sweet's syndrome.

2 | CASE DESCRIPTION

A 51-year-old man with a past medical history of 16 pack years of smoking presented to the emergency department with new onset severe bilateral ankle pain. He reported a 10 days history of fatigue, fever with a maximum temperature of 39.2°C, night sweats, and the development

This is an open access article under the terms of the [Creative Commons Attribution-NonCommercial-NoDerivs](https://creativecommons.org/licenses/by-nc-nd/4.0/) License, which permits use and distribution in any medium, provided the original work is properly cited, the use is non-commercial and no modifications or adaptations are made.

© 2024 The Authors. *Clinical Case Reports* published by John Wiley & Sons Ltd.

of erythematous, painful papular rashes that started on his knees and continued to spread all over the body. The patient also noted an episode of chest pain and dry coughs but denied shortness of breath and hemoptysis. Additionally, the patient reported a 24-lb weight loss over several weeks due to loss of appetite. He denied a history of oral or genital ulcers.

Occupational history revealed he worked on a city farm and had previously worked as an environmental specialist in a sewage plant. The patient denied a history of exposure to animal droppings, hazardous materials, recent travel outside the state, or sick contacts.

On physical examination, the patient was afebrile, and his respiratory system was unremarkable. Posterior cervical lymphadenopathies and multiple painful, well-circumscribed, erythematous, edematous plaques involving 10%–12% of his body surface area with sparing of the

palms and soles were noted (Figure 1). Mild swelling and pain with motion of the bilateral ankles were observed.

3 | METHODS

Initial laboratory investigations showed mild leukocytosis at 10.82 K/uL (normal range: 4.23–9.07 K/uL), elevated ESR at 78 mm/hr., elevated CRP at 19.2 mg/dL, and normal C3 and C4 levels. Hepatitis viral panel, HIV, and syphilis were non-reactive. PCR for respiratory viral infection and Neisseria and Chlamydia were all negative. A CT chest revealed a 1.5 cm spiculated nodule present in the posterior right lower lobe surrounded by ground-glass attenuation with an enlarged right hilar lymph node and a few sub-centimeter nodules in the right lower lobe (Figure 2A). A CT-guided tissue biopsy of the peripheral lung nodule was

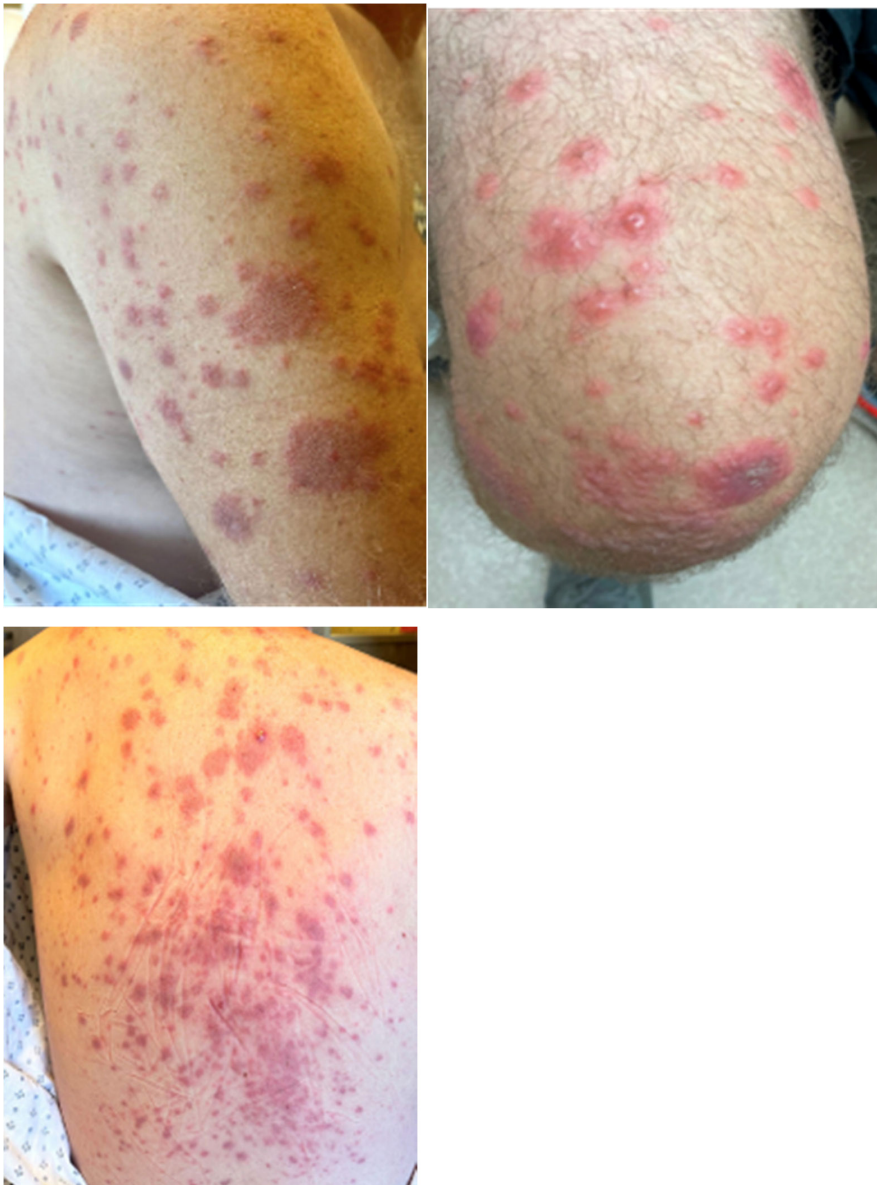

FIGURE 1 Multiple tender erythematous edematous plaques and papules distributed on the trunk and extremities.

performed for definitive diagnosis. Additionally, skin biopsies of the cutaneous manifestations were done. While anticipating the biopsy results, the patient's rashes and painful swollen ankles gradually resolved on their own.

The pathological report of the lung biopsy demonstrated granulomatous inflammation with multinucleated giant cells and was negative for malignancy, raising suspicion for inflammatory processes which included fungal infection, tuberculosis, and sarcoidosis (Figure 3A,B). The immunohistochemistry stains for CD68 highlighted histiocytes, and CK7 showed lung parenchyma around granulomas. GMS was negative for fungal infection, and AFB was negative for mycobacteria (Figure 4). The skin biopsies showed significant papillary dermal edema with a mixed inflammatory infiltrate composed of lymphocytes and neutrophils, and direct immunofluorescence studies were all negative, consistent with Sweet's syndrome.

Additional laboratory investigations including QuantiFERON TB, Aspergillus, Histoplasma, Blastomyces, Thermoactinomyces spp., Saccharopolyspora rectivir, and Saccharomonospora viridis later returned negative. Coccidioides Ab Complement Fixation (CF) was positive with a titer of 1:16, yeast phase Ab titer of 1:32, and mycelial phase Ab <1:8. Antibody to TP antigen IgM and antibody to F antigen IgG were also positive. The patient was diagnosed with pulmonary coccidioidomycosis associated with Sweet's syndrome. Due to borderline Coccidioides CF (titer 1:16) and yeast phase Ab (titer

1:32), the infectious disease team recommended treating the infection as disseminated coccidioidomycosis with fluconazole 800 mg daily for at least 3 months even though there was no clinical evidence apart from yeast phase Ab titer of 1:32.

4 | RESULTS (OUTCOME AND FOLLOW-UP)

At the outpatient follow-up, a CT chest was repeated 1 week after treatment initiation and demonstrated a decrease in size of both the pulmonary nodule at the right posterior lung base and right hilar adenopathy. Additionally, there were no new nodule formations or infiltrating lesions (Figure 2B). Coccidioides CF titer has decreased to 1:2 after 2 months of fluconazole treatment, and the patient has had complete resolution of symptoms.

5 | DISCUSSION

Coccidioidomycosis manifests a heterogeneous clinical spectrum depending on the immune status of the host. The true number of cases is 6–14 times greater than the number reported since only 40% of coccidioidomycosis infections are symptomatic; among them, some do not seek medical care, others are misdiagnosed, and some

FIGURE 2 (A). A computed tomography (CT) of the chest shows a 1.5 cm spiculated right lower lobe lung nodule. (B). Computed tomography (CT) of the chest shows a reduction in the size of pulmonary nodule to 0.9 cm after 1 week of fluconazole treatment.

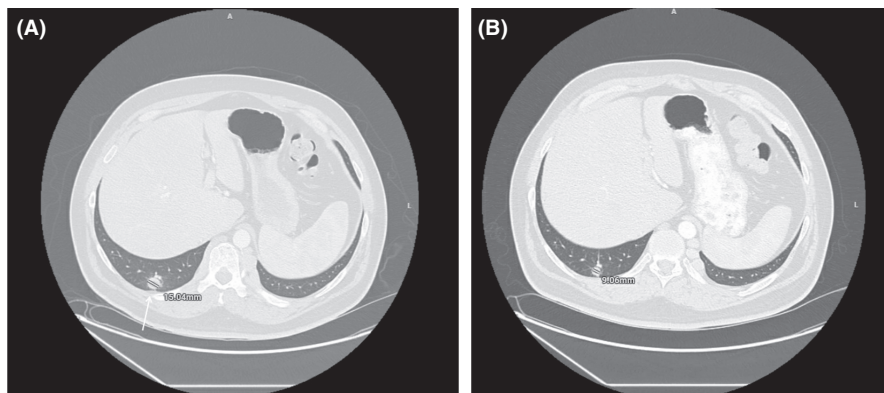
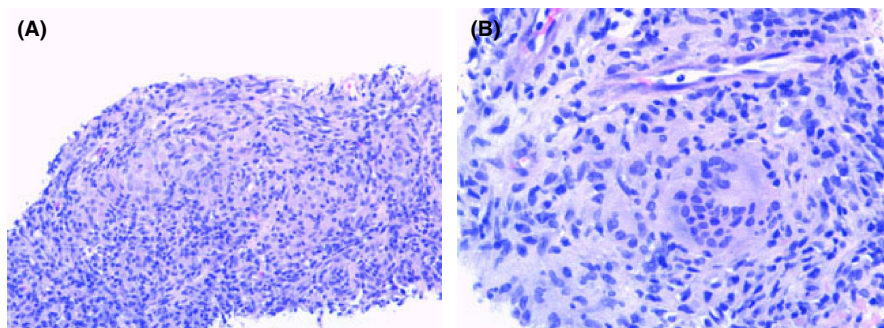


FIGURE 3 (A). Histopathology with H&E stain at 40x of the right lung biopsy specimen shows granulomatous inflammation with infiltration of multinucleated giant cells and scattered eosinophils. (B). Histopathology with H&E stain at 60x magnification shows multinucleated giant cells.



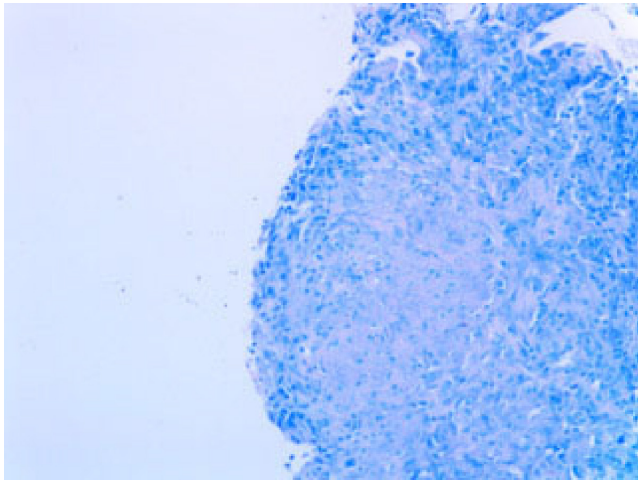


FIGURE 4 Lung tissue histopathology with AFB stain at 40x which shows a negative result for mycobacteria.

identified cases are not reported.⁴ Males are reported to have a greater risk for dissemination, suggesting a hormonal or genetic component. However, dust exposure within endemic regions due to occupation is considered the primary risk factor for infection.³

Primary pulmonary coccidioidal infection is the most common disease presentation in immunocompetent patients, with symptoms manifesting 7–21 days after exposure. Pulmonary symptoms are typically associated with systemic complaints such as fever, headache, night sweats, weight loss, and fatigue.^{1,2} Patients with primary pulmonary disease may also develop symmetric arthralgia and cutaneous manifestations. Radiographic findings in primary pulmonary disease include dense pulmonary infiltration, hilar adenopathy, and pulmonary nodules or cavities. Conversely, disseminated coccidioidomycosis infection often involves the skin, bones, joints, and central nervous system. Progression to disseminated disease through hematogenous or lymphatic spread occurs in less than 0.2% of coccidioidal infections, with immunocompromised patients being at the highest risk.^{1,2}

Skin involvement is one of the most common extrapulmonary manifestations of coccidioidal infection. It can be categorized as reactive lesions and organism-specific lesions. Reactive manifestations that do not contain visible microorganisms include erythema nodosum, erythema multiforme, acute generalized exanthema, and Sweet's syndrome. These manifestations occur during acute primary pulmonary infection in up to 50% of cases due to host immunological response.³ Organism-specific manifestations contain microorganisms within lesions and can be classified as primary cutaneous disease from direct inoculation or secondary cutaneous disease from hematogenous spreading.³

Sweet's syndrome has been observed as one of the reactive skin manifestations of coccidioidomycosis. Few cases

have been reported, with most patients presenting with erythematous plaques commonly involving the trunk, neck, and upper extremities.^{5,6} Skin biopsy specimens in Sweet's syndrome typically show a diffuse inflammatory infiltrate in the dermis, with neutrophils and leukocytoclastic debris. The treatment for Sweet's syndrome should focus on the underlying cause. When no specific cause is evident, systemic corticosteroids are the mainstay of therapy; however, they are not recommended in the setting of coccidioidal infection.

Our patient did not have dominant respiratory symptoms associated with primary coccidioidal infection, but instead presented with extrapulmonary nonspecific systemic symptoms such as fever, night sweats, and weight loss. While these symptoms were suspicious of malignancy, the patient's arthralgia and cutaneous manifestations were suggestive of an underlying inflammatory process. The initial CT chest showed a spiculated lung mass with hilar lymphadenopathy, also suggestive of malignancy. Initial radiographic findings in primary coccidioidal infection may resemble malignancy. Additionally, cutaneous manifestations associated with Sweet's syndrome can be associated with pregnancy, drugs, infection, and malignancy; as such, a biopsy of the lung mass should be considered for definitive diagnosis. In this case, the lung biopsy specimen showed granuloma formation with scattered eosinophils and no malignant cells. An immunohistochemical marker CK7, a marker for primary lung cancer, was also negative. These results, correlated with clinical findings and positive coccidioidal serology studies, allowed for the correct diagnosis of coccidioidomycosis to be established.

Diagnosis of suspected primary coccidioidal infection is confirmed with serology testing. Enzyme-linked immunoassay (EIA) is performed to detect coccidioidal IgM and IgG antibodies. Immunodiffusion testing is typically performed after an initial positive EIA test to quantify coccidioidal antibody concentration and support the diagnosis. Definitive diagnostic testing may be performed with histopathology of biopsy specimens, revealing granulomatous inflammation and spherules of endospores upon cytological staining.^{7,8} Finally, fungal culture from patient respiratory samples may be used for definitive diagnosis, since *Coccidioides* spp. are not part of the normal human microbiota.

Treatment of coccidioidomycosis is based on the severity of pulmonary infection, the presence or absence of dissemination, and host immunity status. Asymptomatic or mild disease may not require antifungal therapy because the disease is commonly self-limiting in normal hosts. However, it is important to classify between primary pulmonary and disseminated infection to decide on the duration of treatment.⁷ Several studies indicated that CF titers of 1:32 were considered a specific

indication of heightened activity and possible dissemination.^{7,8} Our patient showed no clinical evidence of disseminated infection, but with a high yeast phase Ab titer (1:32), which is infectious, the infectious disease consultant decided to pursue the treatment for disseminated coccidioidomycosis with Fluconazole 800 mg for at least 3 months.

6 | CONCLUSION

This case illustrates the potential for immunologic extrapulmonary manifestations during acute pulmonary coccidioid infection and the value of a complete history in patients residing within endemic regions. The patient's occupational history led the admitting team to include fungal infection in the differential diagnosis despite initial pulmonary workup suggesting malignancy. Diagnosis of coccidioidomycosis can be difficult, as signs and symptoms may be relatively nonspecific and resemble other respiratory diseases or lung malignancies. In our case, recognition of the cutaneous manifestations and rheumatologic symptoms of this disease aided in making the correct diagnosis. While radiographic imaging studies help make a diagnosis of coccidioidomycosis, initial findings may be unremarkable or share similarities with other diseases, such as malignancy in the case of our patient. Therefore, histopathological studies from lung biopsy and serology studies were used to make a definitive diagnosis of coccidioidomycosis.

AUTHOR CONTRIBUTIONS

Nattanicha Chaisrimaneepan: Resources; writing – original draft; writing – review and editing. **Austin Guadarrama:** Resources; writing – original draft. **Pitchaporn Yingchoncharoen:** Conceptualization; resources; writing – original draft. **Maria Batchinsky:** Resources.

ACKNOWLEDGMENTS

We would like to express our gratitude to Dr. Daniel Davis and Dr. Brian Shroeder, our colleagues and attending, who were involved in the care of the patient. We graciously appreciate Dr. Kenneth Nugent's opinion from the pulmonology aspect to proceed with the lung biopsy.

FUNDING INFORMATION

The authors did not receive financial support for the research, authorship, and/or publication of this article.

CONFLICT OF INTEREST STATEMENT

All the authors declare no conflict of interest.

DATA AVAILABILITY STATEMENT

Data underlying the results are available as part of the article, and no additional source data are required.

CONSENT

Written informed consent was obtained from the patient to publish this report in accordance with the journal's patient consent policy.

ORCID

Nattanicha Chaisrimaneepan  <https://orcid.org/0000-0002-3183-7853>

Pitchaporn Yingchoncharoen  <https://orcid.org/0000-0003-0764-6472>

REFERENCES

- Williams SL, Chiller T. Update on the epidemiology, diagnosis, and treatment of coccidioidomycosis. *Journal of Fungi*. 2022;8(7):666.
- McCotter OZ, Benedict K, Engelthaler DM, et al. Update on the epidemiology of coccidioidomycosis in the United States. *Med Mycol*. 2019;57(Supplement_1):S30-S40. doi:10.1093/mmy/myy095
- Garcia Garcia SC, Salas Alanis JC, Flores MG, Gonzalez Gonzalez SE, Vera Cabrera L, Ocampo CJ. Coccidioidomycosis and the skin: a comprehensive review. *An Bras Dermatol*. 2015;90(5):610-619. doi:10.1590/abd1806-4841.20153805
- Cohen PR, Kurzrock R. Sweet's syndrome: a review of current treatment options. *Am J Clin Dermatol*. 2002;3(2):117-131. doi:10.2165/00128071-200203020-00005
- Jafri Z, Shedlofsky L, Newman A, Lam T, Mengesha Y. A sweet presentation of a bitter disease: acute febrile neutrophilic dermatosis associated with Coccidioidomycoses. *SKIN J Cutan Med*. 2021;5(2):174-177. doi:10.25251/skin.5.2.17
- DiCaudo DJ, Ortiz KJ, Mengden SJ, Lim KK. Sweet syndrome (acute febrile neutrophilic dermatosis) associated with pulmonary coccidioidomycosis. *Arch Dermatol*. 2005;141(7):881-884. doi:10.1001/archderm.141.7.881
- Peçanha-Pietrobon PM, Tirado-Sánchez A, Gonçalves SS, Bonifaz A, Colombo AL. Diagnosis and treatment of pulmonary Coccidioidomycosis and Paracoccidioidomycosis. *J Fungi*. 2023;9(2):218.
- McHardy IH, Dinh BN, Waldman S, et al. Coccidioidomycosis complement fixation titer trends in the age of antifungals. *J Clin Microbiol*. 2018;56(12):e01318-18. doi:10.1128/jcm.01318-18

How to cite this article: Chaisrimaneepan N, Guadarrama A, Batchinsky M, Yingchoncharoen P. Pulmonary coccidioidomycosis mimicking malignancy associated with Sweet's syndrome (acute febrile neutrophilic dermatosis). *Clin Case Rep*. 2024;12:e8651. doi:10.1002/ccr3.8651