

Primary Adenocarcinoma of the Urethra: A Case Report and Review of the Literature

Abbas Basiri, MD,¹ Behzad Narouie, MD,¹ Mohammad Hossein Moghadasi, PhD,²
Mohammad Ghasemi-Rad, MD,³ and Reza Valipour, MD¹

Abstract

Primary adenocarcinoma of the urethra is rarely reported. We report a case of a 47-year-old male with symptoms of urinary obstruction started 2 years before diagnosis. Video-assisted urethrocystoscopy revealed a papillary mass almost obstructing the entire lumen with bleeding. Pathology report was consistent with primary adenocarcinoma of the urethra.

Introduction

PRIMARY URETHRAL CARCINOMA (UC) is defined as a tumor that is first detected in the urethra unlike secondary UC that is a recurrence of tumor in the urethra after prior diagnosis and treatment of carcinoma somewhere else in the urinary tract. Most causes of secondary UCs are reported after radical cystectomy of the urinary bladder caused by bladder cancer.¹ Primary UC is considered a rare cancer,^{2–4} accounting for <1% of all malignancies³ with an incidence rate of 4/1,000,000/year.² The survival for superficial type is 83% and for deep type it is 36%.⁴ Most primary UCs are of transitional type and squamous cell type, with less than 5% being reported as adenocarcinoma.⁵ Here we report a patient with symptomatic urinary obstruction having a well-differentiated adenocarcinoma of the urethra.

Case Report

A 47-year-old male patient with 2-year history of symptomatic urinary obstruction was presented to our urology clinic at a tertiary referral hospital. He was also complaining of frequent gross terminal hematuria and lower urinary tract symptoms. Six months ago, he had total hematuria, and upon referring to a urologist, he was found to have urethral stricture and a retrograde urethrography, after which video urethrocystoscopy was performed (Fig. 1). Urethroscopy revealed mild penile urethral narrowing at the level of bulbar urethra, which was dilated. It showed a papillary tumor with bleeding, measuring 2 to 3 cm and almost filling the lumen. A sample was taken and sent to a pathologist. The membranous, prostatic urethra and bladder neck were intact as well as no pathology

was seen inside the bladder. The pathology report showed papillary formed neoplastic tissue, in which atypical tall columnar epithelial with enlarged hyperchromatic nuclei and prominent nucleoli was clear. Cytoplasm and the underlying inflamed stroma infiltrated mostly by acute inflammatory cells, consistent with well-differentiated adenocarcinoma with focal mucin production (Fig. 2). The tumor had invaded into the submucosa and the deep margin is free of tumor. A pelvic MRI with and without contrast was performed to investigate possible metastasis (Fig. 3). A 44×19 mm intraurethral enhancing circumferential mass in the bulbar portion of the urethra was seen that causes expansion of urethra. The membranous part of the urethra was clear. There was no evidence of extracorporeal invasion of the mass. Prostate gland with 55 cc volume was enlarged. The bladder had irregular border. The patient underwent surgery and the mass was removed. After 6 months of follow-up, the patient is fine and has no complaints.

Discussion

Tumors of the male urethra are categorized according to location and histologic features.⁶ The UC is localized to the bulbomembranous urethra in 60% of the patients, penile urethra in 30% of patients, and prostatic urethra in 10% of patients.⁷ A recent population-based study, Surveillance, Epidemiology, and End Results (SEER), and analysis of 2065 men with primary UC (mean age: 73 years) showed that urothelial carcinoma (78%) was most common, and squamous cell carcinoma (SCC) (12%) and adenocarcinoma (5%) were significantly less frequent.⁵

¹Urology and Nephrology Research Center, Department of Urology and Renal Transplantation, Shahid Labbafinejad Medical Center, Shahid Beheshti University of Medical Sciences, Tehran, Iran.

²Department of Medical Laboratory, Shahid Labbafinejad Medical Center, Iranian Social Security Organization Tehran, Iran.

³Division of Interventional Radiology, Harvard Medical School, Massachusetts General Hospital, Boston, Massachusetts.



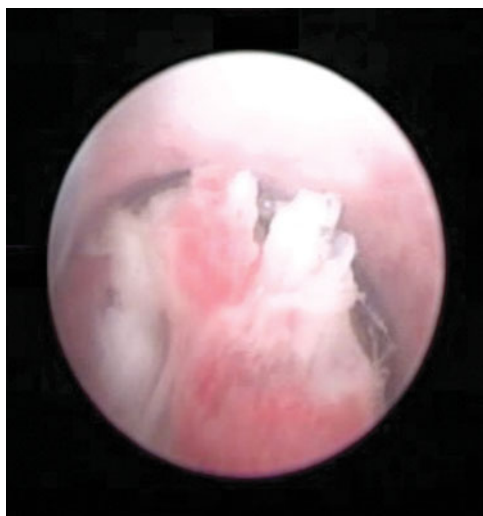


FIG. 1. Video urethroscopy showing papillary tumor at the level of bulbar urethra.

For male primary UC, various predisposing factors have been reported, including urethral strictures,^{2,4,8,9} chronic irritation after intermittent catheterization or urethroplasty,^{10–12} external beam radiation therapy,¹³ radioactive seed implantation,¹⁴ chronic urethral inflammation urethritis after sexually transmitted diseases (i.e., condylomata associated with human papillomavirus 16),^{4,15,16} and congenital origin (i.e., clear cell adenocarcinoma).¹⁷

The histologic subtype of UC also varies by anatomic location. Carcinomas of the prostatic urethra are of transitional cell origin in 90% and of squamous cell origin in 10%; and carcinomas of the bulbomembranous urethra are of squamous cell origin in 80%, of transitional cell origin in 10%, and of adenocarcinoma or undifferentiated in 10%.⁷ Male UC can spread by direct extension to adjacent structures, usually involving the vascular spaces of the corpus spongiosum and the periurethral tissues, or it can metastasize through lymphatic embolization to regional lymph nodes. The lymphatic vessels from the anterior urethra drain into the superficial and deep inguinal lymph nodes

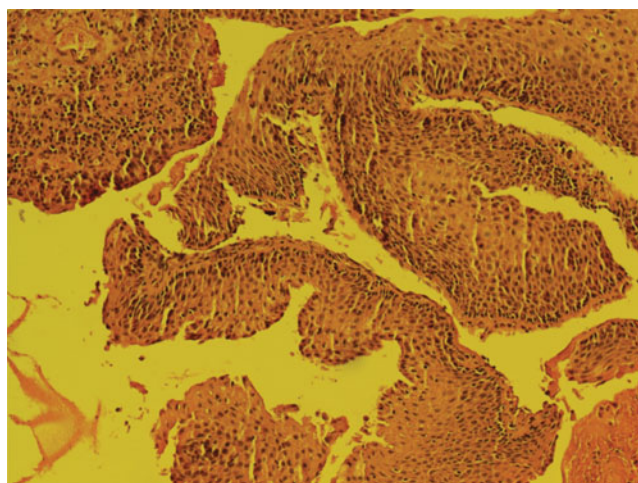


FIG. 2. Papillary formed neoplastic tissue with atypical tall columnar epithelial, enlarged hyperchromatic nuclei, prominent nucleoli.

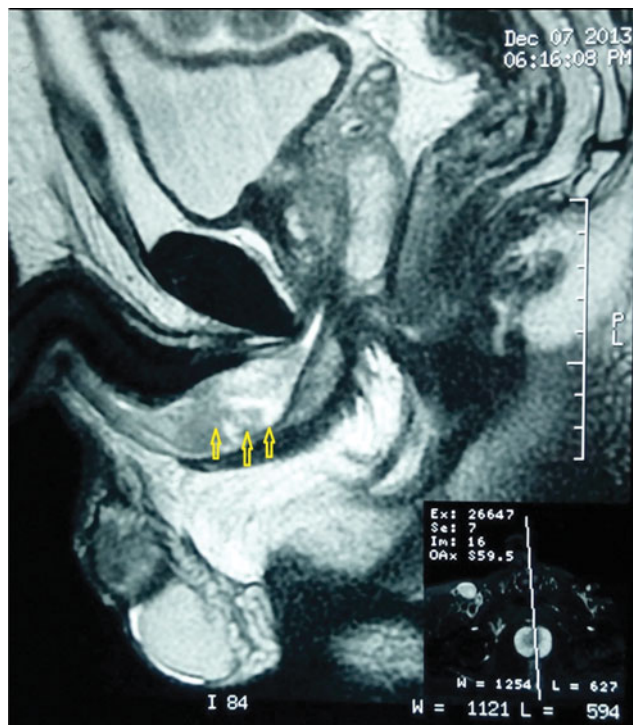


FIG. 3. Sagittal T2 weighted shows a high signal large well-defined lesion at the bulbar portion of corpus spongiosum.

and occasionally into the external iliac lymph nodes. Tumors of the posterior urethra most commonly spread to the pelvic lymph nodes. Palpable inguinal lymph nodes occur in about 20% of cases and almost always represent metastatic disease, in contrast to penile cancer, in which a large percentage of palpable nodes may be inflammatory. Hematogenous dissemination is uncommon except in advanced disease.¹⁸

When primary UC becomes clinically apparent, most patients (45%–57%) present with symptoms associated with locally advanced disease (T3/T4).^{19,20} At initial presentation, visible hematuria or bloody urethral discharge is reported in as much as 62% of the cases. Further symptoms of locally advanced disease include an extraurethral mass (52%), bladder outlet obstruction (48%), pelvic pain (33%), urethrocutaneous fistula (10%), abscess formation (5%), or dyspareunia.²⁰

The onset of malignant change in a patient with chronic urethral stricture disease may be insidious, and a high index of clinical suspicion is necessary to diagnose these tumors expediently. The most common presenting symptoms are urethral bleeding, a palpable urethral mass, and obstructive voiding symptoms.² In men, physical examination should comprise palpation of the external genitalia for suspicious indurations or masses and a digital rectal examination.²¹ Bilateral inguinal palpation should be conducted to assess the presence of enlarged lymph nodes, describing location, size, and mobility.²²

The role of urinary cytology in primary UC is limited, and its sensitivity ranges between 55% and 59%.²³ Detection rate depends on the underlying histologic entity. In male patients, the sensitivity for urothelial carcinoma and SCC was reported to be 80% and 50%, respectively.²¹

Depending on the depth of infiltration according to the TNM classification for UC, superficial tumors as papillary carcinoma *in situ* or at the basement membrane crossing are



described as T1. The infiltration of the corpus spongiosum, prostate, or periurethral muscle is classified with T2. In addition, the involvement of the corpora cavernosa, the bladder neck, or a prostate capsule sunburst as T3 and an infestation of adjacent organs are defined as T4.²

The primary treatment is surgery. For UC in stage pT2, there are two curative surgical approaches: in the proximal urethra, this involves the prostatic urethra and membranous urethra. Should a penectomy with prostatectomy be necessary, it should be performed with cystoprostatectomy and removal of the pelvic lymph nodes.²

Earlier lesions of the bulbomembranous urethra have been treated effectively by transurethral resection or by segmental excision of the involved urethral segment with an end-to-end anastomosis. Unfortunately, cases appropriate for limited resection are rare.⁷

A statement on evidence-based therapies is difficult. The etiology may contribute to the development of a UC by several factors.² In a distal localization, the bulbar, penile urethra, and navicular fossa comprising a penis-conserving surgery can be performed.²

Adenocarcinoma of the urethra, although rare, should be in deferential diagnosis of patients with a long history of urinary obstruction and gross hematuria.

Acknowledgments

The authors thank the Urology and Nephrology Research Center (UNRC), Department of Urology and Kidney Transplantation, Shahid Labbafinejad Medical Center, and Shahid Beheshti University of Medical Sciences, Tehran, Iran, for their help in preparing this article.

Disclosure Statement

No competing financial interests exist.

References

1. Boorjian SA, Kim SP, Weight CJ, Cheville JC, Thapa P, Frank I. Risk factors and outcomes of urethral recurrence following radical cystectomy. *Eur Urol* 2011;60:1266–1272.
2. Maek M. [Penis-preserving surgery in patients with primary penile urethral cancer] (Ger). *Urologe A* 2014;53:1800–1804.
3. Gatta G, van der Zwan JM, Casali PG, et al. Rare cancers are not so rare: The rare cancer burden in Europe. *Eur J Cancer* 2011;47:2493–2511.
4. Dalbagni G, Zhang ZF, Lacombe L, Herr HW. Male urethral carcinoma: Analysis of treatment outcome. *Urology* 1999;53:1126–1132.
5. Rabbani F. Prognostic factors in male urethral cancer. *Cancer* 2011;117:2426–2434.
6. Mostofi FK, Davis CJ, Jr., Sesterhenn IA. Carcinoma of the male and female urethra. *Urol Clin North Am* 1992;19:347–358.
7. Craig AP. *Campbell-Walsh Urology*, 10th ed. Philadelphia: Elsevier Saunders, 2012.
8. Medina Perez M, Valero Puerta J, Sanchez Gonzalez M, Valpuestas Fernandez I, Marin Martin J. [Squamous carcinoma of the male urethra, its presentation as a scrotal abscess] (Spa). *Arch Esp Urol* 1999;52:792–794.
9. Van de Voorde W, Meertens B, Baert L, Lauweryns J. Urethral squamous cell carcinoma associated with urethral stricture and urethroplasty. *Eur J Surg Oncol* 1994;20:478–483.

10. Colapinto V, Evans DH. Primary carcinoma of the male urethra developing after urethroplasty for stricture. *J Urology* 1977;118:581–584.
11. Mohanty NK, Jolly BB, Saxena S, Dawson L. Squamous cell carcinoma of perineal urethrostomy. *Urol Int* 1995;55:118–119.
12. Sawczuk I, Acosta R, Grant D, White RD. Post urethroplasty squamous cell carcinoma. *N Y State J Med* 1986;86:261–263.
13. Mohan H, Bal A, Punia RP, Bawa AS. Squamous cell carcinoma of the prostate. *Int J Urol* 2003;10:114–116.
14. Arva NC, Das K. Diagnostic dilemmas of squamous differentiation in prostate carcinoma case report and review of the literature. *Diagn Pathol* 2011;6:46.
15. Cupp MR, Malek RS, Goellner JR, Espy MJ, Smith TF. Detection of human papillomavirus DNA in primary squamous cell carcinoma of the male urethra. *Urology* 1996;48:551–555.
16. Wiener JS, Liu ET, Walther PJ. Oncogenic human papillomavirus type 16 is associated with squamous cell cancer of the male urethra. *Cancer Res* 1992;52:5018–5023.
17. Gandhi JS, Khurana A, Tewari A, Mehta A. Clear cell adenocarcinoma of the male urethral tract. *Indian J Pathol Microbiol* 2012;55:245–247.
18. Vapnek JM, Hricak H, Carroll PR. Recent advances in imaging studies for staging of penile and urethral carcinoma. *Urol Clin North Am* 1992;19:257–266.
19. Derksen JW, Visser O, de la Riviere GB, Meuleman EJ, Heldeweg EA, Lagerveld BW. Primary urethral carcinoma in females: An epidemiologic study on demographical factors, histological types, tumour stage and survival. *World J Urol* 2013;31:147–153.
20. Gheiler EL, Tefilli MV, Tiguert R, de Oliveira JG, Pontes JE, Wood DP, Jr. Management of primary urethral cancer. *Urology* 1998;52:487–493.
21. Karnes RJ, Breau RH, Lightner DJ. Surgery for urethral cancer. *Urol Clin North Am* 2010;37:445–457.
22. Blaivas JG, Flisser AJ, Bleustein CB, Panagopoulos G. Periurethral masses: Etiology and diagnosis in a large series of women. *Obstet and Gynecol* 2004;103(5 Pt 1):842–847.
23. Touijer AK, Dalbagni G. Role of voided urine cytology in diagnosing primary urethral carcinoma. *Urology* 2004;63:33–35.

Address correspondence to:

Behzad Narouie, MD

Department of Urology

Shahid Labbafinejad Medical Center

Shahid Beheshti University of Medical Sciences

Tehran

Iran

E-mail: b_narouie@yahoo.com

Abbreviations Used

MRI = magnetic resonance imaging

SCC = squamous cell carcinoma

UC = urethral carcinoma

Cite this article as: Basiri A, Narouie B, Moghadasi MH, Ghasemi-Rad M, Valipour R (2015) Primary adenocarcinoma of the urethra: a case report and review of the literature. *Journal of Endourology Case Reports* 1:1, 75–77, DOI: 10.1089/cren.2015.0026.

