

The “BioHumi” Humeral Head Elliptical Osteochondral Allograft Transplantation



Eric E. Peterson, M.D., Paul E. Caldwell III, M.D., and Sara E. Pearson, Ph.D.

Abstract: Cartilage defects of the humeral head in young, active patients provide a challenge to treating surgeons. The causes of humeral head osteochondral lesions are variable, but these lesions most commonly result from trauma and recurrent glenohumeral instability. Palliative and reparative techniques such as arthroscopic debridement and microfracture have traditionally been used as surgical treatment but have high failure rates. Similarly to surgical trends in the knee, cartilage restoration in the shoulder is becoming more prevalent in younger patients. Osteochondral allograft transplantation (OAT) has been used as a joint-preserving surgical option to restore hyaline cartilage in multiple joints for decades. Although OAT is more commonly used to re-establish the subchondral bony architecture in the treatment of recurrent shoulder instability, the procedure may also be indicated in young, active patients with focal humeral head chondral defects. OAT has been shown in early studies to provide improvement in functional outcome scores and good long-term graft survival with relatively low rates of complications. This report describes our straightforward, reproducible technique for the treatment of large, oblong chondral defects of the humeral head using OAT.

Osteochondral allograft transplantation (OAT) of the humeral head is becoming a more common treatment for chondral and osteochondral lesions of the humeral head. Cartilage lesions of the humeral head are associated with trauma and recurrent shoulder instability. OAT was initially described for the treatment of osteochondral lesions of the femoral condyle.^{1,2} The

success of OAT in the knee led Gerber and Lambert³ to describe the treatment of humeral head defects resulting from chronic locked posterior dislocations of the shoulder with OAT in 1996. Multiple techniques have since been described using fresh humeral head or femoral head allografts to restore healthy hyaline cartilage and subchondral bone. Studies examining the outcomes of these procedures have found excellent patient satisfaction and improved functional outcome scores.⁴ Previously described techniques have used concentric, circular allograft geometry to treat chondral lesions of the humeral head. This traditional approach is challenging when addressing larger oblong or elliptical lesions. Treatment of larger lesions with multiple circular grafts carries the inherent risks of articular incongruity, graft loosening, paucity of allograft, and increased operative time. We advocate using the Arthrex BioUni OATS Instrumentation Set (Arthrex, Naples, FL) to create a single, oblong graft and present our preferred technique, titled the “BioHumi” technique.

From Orthopaedic Research of Virginia, Richmond, Virginia, U.S.A. (E.E.P., P.E.C., S.E.P.); and Tuckahoe Orthopaedic Associates, Richmond, Virginia, U.S.A. (P.E.C.).

The authors report the following potential conflicts of interest or sources of funding: The following entities have provided grant funding to Orthopaedic Research of Virginia for Fellowship support: Arthrex, ConMed/Linvatec, DePuy Synthes, DJO, Premier Med, and Smith & Nephew. E.E.P. receives fellowship support from Arthrex, ConMed/Linvatec, DJO, DePuy Synthes, Smith & Nephew, and Premier Med, outside the submitted work. P.E.C. receives fellowship support from Arthrex, ConMed/Linvatec, DJO, DePuy Synthes, Smith & Nephew, and Premier Med, outside the submitted work, and receives consulting fees from Arthrex, JRF, and Vericel. S.E.P. receives fellowship support from Arthrex, ConMed/Linvatec, DJO, DePuy Synthes, Smith & Nephew, and Premier Med, outside the submitted work. Full ICMJE author disclosure forms are available for this article online, as [supplementary material](#).

Received April 15, 2021; accepted July 1, 2021.

Address correspondence to Paul E. Caldwell III, M.D., 1501 Maple Ave, Ste 200, Richmond, VA 23226, U.S.A. E-mail: fellowship@orv.com

© 2021 THE AUTHORS. Published by Elsevier Inc. on behalf of the Arthroscopy Association of North America. This is an open access article under the CC BY-NC-ND license (<http://creativecommons.org/licenses/by-nc-nd/4.0/>). 2212-6287/21608

<https://doi.org/10.1016/j.eats.2021.07.010>

Surgical Technique

Our preference is to perform the procedure with the patient in the modified beach-chair position (Video 1, Table 1). Care is taken to position the patient on the edge of the bed to ensure that the elbow can be dropped off the side and the arm can be externally rotated to achieve adequate exposure of the humeral head

Table 1. Key Steps of BioHumi Osteochondral Allograft Transplantation Procedure

1. Obtaining adequate exposure with attention to positioning and surgical approach
2. Sizing the humeral head defect with elliptical and circular sizers to determine the best fit
3. Positioning the allograft harvest surface within the graft station perpendicular to the harvester
4. Preparing the graft with pulsatile lavage to remove marrow elements and condition with autologous conditioned plasma
5. Dilating the recipient site for easy implantation
6. Ranging the shoulder after implantation to check for graft security and congruity

(Table 2). We also advocate placing a bump behind the medial border of the scapula to stabilize and elevate the scapula. We advocate a standard deltopectoral approach to the shoulder. Our preference is to perform a subscapularis tenotomy to expose the humeral head, but alternatively, a subscapular peel or lesser tuberosity osteotomy may be used.

Once the humeral head has been exposed, the cartilage defect is evaluated for length, width, and depth, as well as the health of the surrounding cartilage (Fig 1). Smaller round defects are amenable to the standard circular techniques, but our preference is to use the BioUni OATS Instrumentation Set for larger elongated defects. Standard sizing methods are used to select the appropriate sizer and drill guide to cover the defect and match the natural curvature of the humeral head (Fig 2). A surgical marking pen is used to trace the outline of the selected sizer and drill guide onto the humeral head, and attention is then turned to preparation of the osteochondral graft (Fig 3).

The osteochondral humeral head allograft is mounted and secured into the OATS workstation (Arthrex) with special attention to positioning the graft so that the outlined donor site is level to allow the harvester to be applied in a perpendicular fashion to the graft station. The graft workstation must be placed on a secure, flat surface with an assistant stabilizing the station during the harvest. The selected sizer is placed on the allograft to confirm conformity, and a marking pen is again used to outline the sizer on the graft (Figs 4 and 5). The marking pen is also used to mark the superior aspect of the graft for orientation. The oblong cutter is assembled to the impactor handle and gently lowered onto the graft to match the previously outlined area at the harvest location. A mallet is then used to drive the cutter into the allograft until the third laser line is flush with the surrounding cartilage. During the process of driving the cutter into the allograft, constant adjustments are made to the cutter by slightly angling the impactor handle to ensure that the cutter is advanced evenly. Our preference is to have the surgeon seated at eye level with the graft station to closely monitor the advancement of the cutter and

make slight modifications while the assistant impacts the handle.

The quick-connect distractor tool (Arthrex) is used to remove the oblong cutter from the allograft. The saw depth guide (Arthrex) is secured to the impactor handle and placed into the previous cut until all 4 hard stops on the edges are in direct contact with the cartilage. A sagittal saw blade is placed through the sagittal saw guide and advanced until through the humeral head. We recommend dripping cold irrigation with a bulb syringe over the saw blade to minimize the risk of thermal necrosis to the graft. The sagittal saw attachments are removed, and the graft is contained in the sagittal saw depth guide. The distractor tool is slowly inserted to extract the graft from the sagittal saw depth guide. We recommend placing part of a surgical sponge into the distractor tool hole to protect the articular surface of the graft during extraction. Extraction of the graft within a basin will reduce the risk of mishandling and dropping of the graft on the floor. The graft is then placed into the appropriately sized donor trial to confirm sizing (Fig 6). In cases in which the graft does not fit perfectly in the sizer, we advocate slight adjustments to the graft with a rasp or small saw until an adequate fit is achieved. Adjustments to the graft are much easier to accomplish than are alterations to the recipient site. A rongeur is used to trim the edges of the graft to facilitate insertion into the recipient site. Pulse irrigation is used to remove marrow elements, and the graft is soaked in autologous conditioned plasma until implantation.

Attention is turned to preparation of the recipient site by placing the sizer and drill guide onto the previously outlined defect. The surgeon confirms that the sizer

Table 2. Pearls and Pitfalls of BioHumi Osteochondral Allograft Transplantation Procedure**Pearls**

- Remove all diseased and delaminated cartilage from the defect to ensure proper sizing.
- Have both elliptical and circular systems available for sizing and implantation.
- Use a sturdy, secure graft station for harvest of the elliptical graft. Slightly chamfer the edges of the graft with a rongeur to facilitate implantation.
- Place a polydioxanone suture under the graft during implantation to allow for safe removal if adjustments to the graft are needed for a proper fit.

Pitfalls

- An inadequate surgical approach to obtain perpendicular access for defect sizing and preparation must be avoided.
- Error in selection of the size and curvature can lead to poor congruity at the recipient-graft interface.
- Failure to secure the graft properly in the station can lead to loosening during the harvest.
- Improper positioning of the graft within the graft station can lead to an uneven harvest.
- Failure to dilate the recipient site can lead to a tight fit with incongruity of the articular surface.

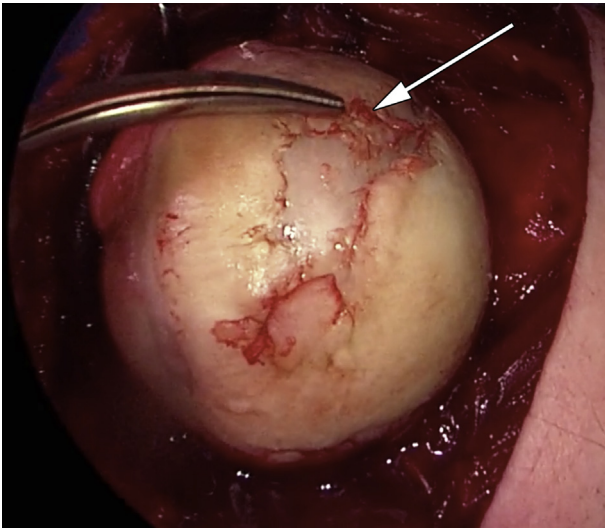


Fig 1. Large, oblong full-thickness chondral defect (arrow) of humeral head in right shoulder.

covers the entirety of the defect and that all 4 sides are flush with the healthy chondral surface. Two 4-mm drill pins are placed through the drill holes in a parallel fashion and advanced 3 cm. During this critical portion of the case, we recommend that the surgeon secure the guide in place to confirm the position and that the assistant advance the pins gently. The sizer is removed, and the drill pins are left in place. The scoring guide with the impactor handle is placed over the drill pins and impacted 2 to 3 mm into the cartilage surface. Great care is taken to ensure that the impactor remains parallel to the drill pins in orthogonal planes. The scoring device is removed, leaving the pins in place. The appropriately sized drill depth guide is placed on

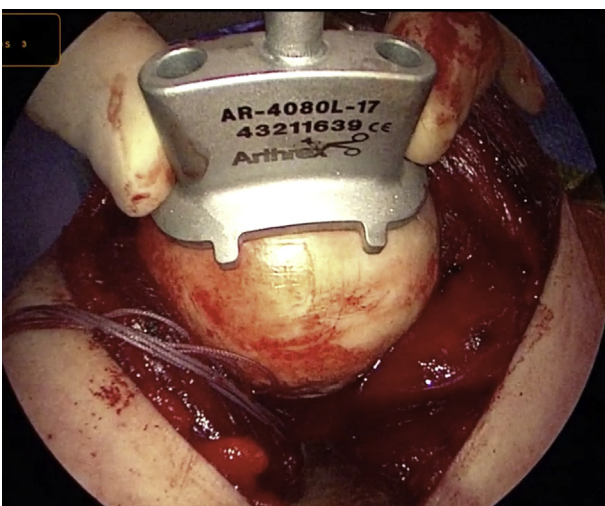


Fig 2. Sizing of chondral defect using appropriate sizing guides to appropriately match size and shape of chondral defect of humeral head in right shoulder in preparation for osteochondral allograft transplantation using BioHumi technique.

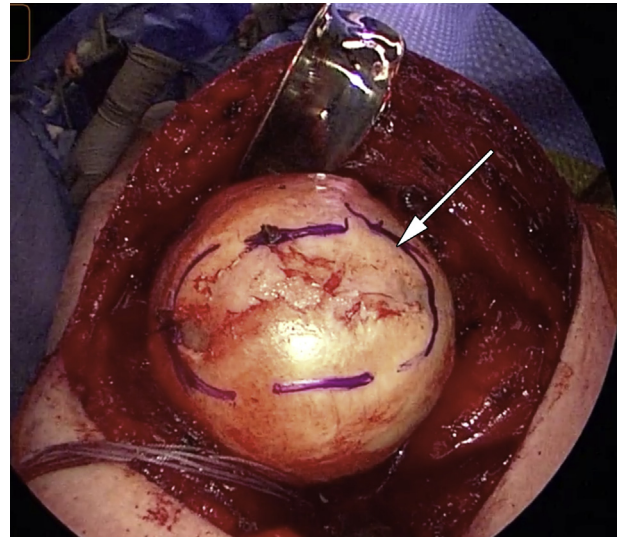


Fig 3. Planned recipient site (arrow) after tracing appropriate sizing guide around chondral defect of humeral head in right shoulder in preparation for osteochondral allograft transplantation using BioHumi technique.

the superior drill pin, and a reamer is placed on the inferior pin. The reamer is advanced until the drill depth guide prevents further insertion. The reamer and depth guide are placed on opposite pins, and the process is repeated. The box cutter is placed over the drill pins and advanced until the tabs are touching the cancellous bone and will not advance. The drill pins are removed, and the excess bone and cartilage are removed with an elevator and curette (Fig 7). The

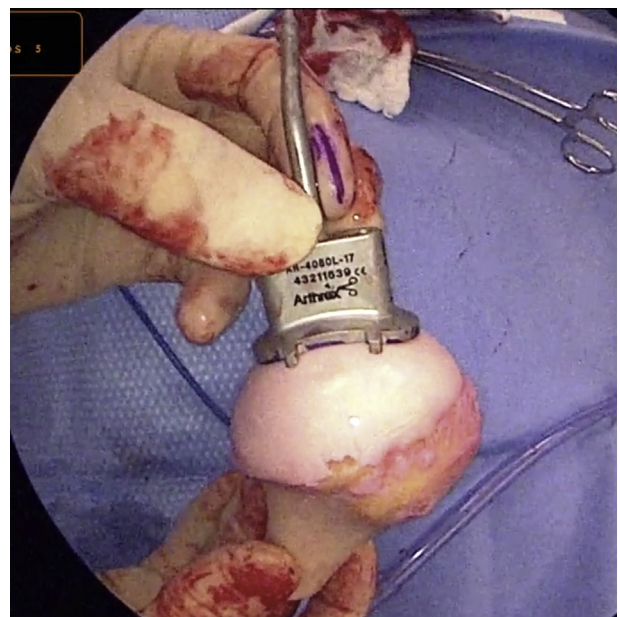


Fig 4. Matching of sizing guide to area of best fit and congruity on donor humeral head osteochondral allograft in preparation for osteochondral allograft transplantation using BioHumi technique.

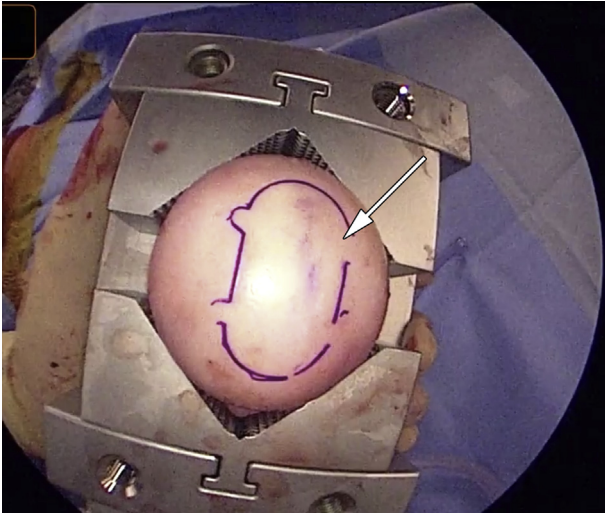


Fig 5. Planned donor allograft site (arrow) after tracing appropriate sizing guide on humeral head osteochondral allograft in preparation for osteochondral allograft transplantation using BioHumi technique.

dilatator is impacted into the recipient site to confirm the appropriate size and depth.

The graft is removed from the autologous conditioned plasma and placed into the recipient site using manual pressure (Fig 8). An impactor may be used to aid in final seating of the graft to ensure the edges are flush with the surrounding cartilage. Palpating the graft-recipient interface to confirm that the graft edges are flush or slightly recessed is crucial to the allograft

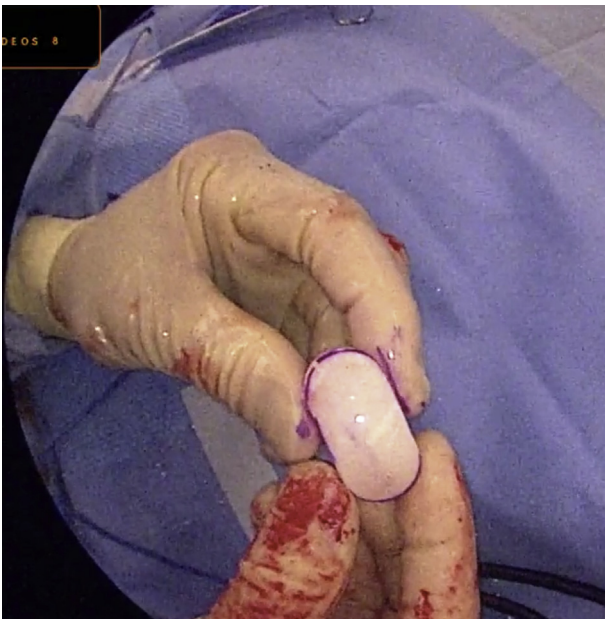

Fig 6. Donor osteochondral allograft plug from humeral head osteochondral allograft after successful harvest in preparation for osteochondral allograft transplantation using BioHumi technique.

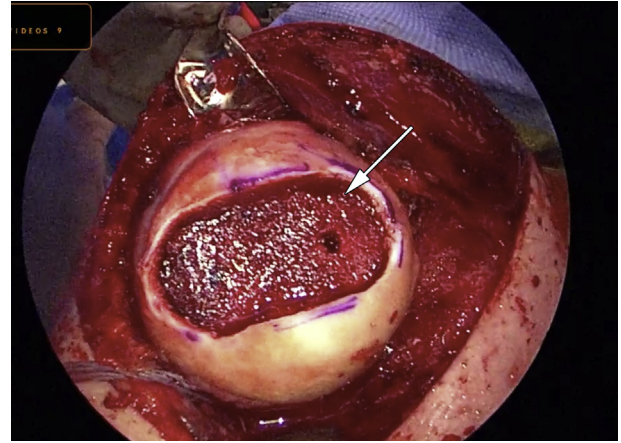


Fig 7. Fully prepared recipient site (arrow) in humeral head in right shoulder prior to implantation of humeral head osteochondral allograft in preparation for osteochondral allograft transplantation using BioHumi technique.

implantation technique. If any portion of the graft is proud, then the graft is removed and appropriate adjustments are made to ensure a proper fit. Care is taken to avoid forceful impaction of the graft to prevent potential iatrogenic chondral injury. Our preference is to place a No. 2-0 polydioxanone suture across the recipient site prior to insertion of the graft. The suture may be used to remove the graft without undue force and subsequent damage if the graft-recipient site interface is too tight and adjustments to the graft or recipient site must be made. Once the graft is well seated, the suture can be cut flush with the graft edge. The shoulder is taken through a full range of motion to ensure the security and chondral continuity of the graft.

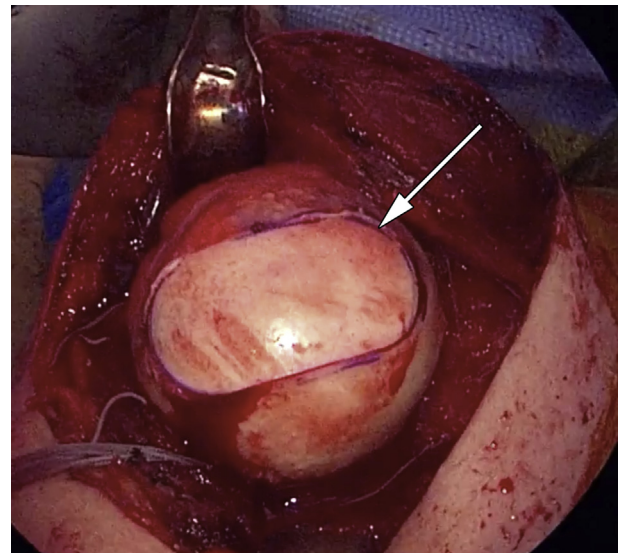


Fig 8. Humeral head osteochondral allograft (arrow) after implantation in recipient site on humeral head in right shoulder after osteochondral allograft transplantation using BioHumi technique.

Table 3. Advantages and Disadvantages of BioHumi Osteochondral Allograft Transplantation Procedure**Advantages**

- The procedure uses reproducible preparation steps with straightforward instrumentation for both graft harvest and recipient site preparation.
- The technique is an excellent option for commonly encountered oblong defects.
- Multiple size options are available to closely match the recipient site dimensions.
- Secure, press-fit fixation of graft is achieved to eliminate loosening or the need for hardware fixation.
- The need for multiple circular grafts is alleviated.

Disadvantages

- Fresh humeral head osteochondral allografts are often more difficult to obtain.
- The BioHumi technique requires a full open approach to the shoulder.
- Humeral head defects may not be elliptical.
- With an elliptical osteochondral graft, it is often more difficult to match the exact contour of the recipient articular cartilage.
- Large elliptical osteochondral grafts may potentially incorporate more slowly owing to the amount of bone.

The shoulder is irrigated copiously, and the subscapularis is repaired in the standard surgical fashion. The incision is closed in layers, and a dry, sterile dressing is applied. The patient is placed in a sling postoperatively. The patient is seen at 1 week after surgery and begins a physical therapy program to achieve full passive range of motion while the subscapularis repair is protected. Strengthening is started at 3 months postoperatively, and return to sports is considered at 6 months if the range-of-motion and strength goals are achieved. The graft incorporation is followed radiographically during the rehabilitative process.

Discussion

OAT was initially described for the treatment of chondral and osteochondral defects of the femoral condyle in the knee and has gained significant support in the literature over the past several decades.^{5,6} Long-term results have shown graft survival rates approaching 90% at 10 years and 75% at 15 years for isolated condylar lesions.⁷ Likewise, functional outcome scores and patient satisfaction have shown excellent long-term results.⁸ The success of OAT in the knee has led surgeons to adopt comparable techniques in the shoulder for the treatment of traumatic bony defects resulting from glenohumeral instability.^{3,9,10} Although chondral defects in the shoulder are not as common as those in the knee, the indications for treatment in the shoulder have expanded to include joint restoration techniques for focal, symptomatic chondral lesions of the humeral head in young, active patients.

Although the literature describing the outcomes of OAT in the shoulder is primarily limited to case reports

and small case series,⁹⁻¹⁷ the ability to restore the normal joint contour and bony architecture with high-quality hyaline cartilage and bone has shown potential. A 2015 systematic review that included 12 studies with 35 patients is the largest study to date.⁴ The majority of the patients underwent OAT owing to large Hill-Sachs lesions from shoulder instability with an average defect size of greater than 40% of the articular surface. The authors found significant improvement in shoulder range of motion and American Shoulder and Elbow Surgeons scores at an average follow-up of 57 months, with high patient satisfaction. Graft resorption was seen in 36.2% of patients, and arthritic changes were seen in 35.7%, although only 26.7% of patients required reoperation. Unlike our technique, all but 2 patients in this study received fresh-frozen osteochondral grafts. The patients who received fresh grafts showed no cases of graft resorption, necrosis, or arthritis, leading the authors to conclude that fresh allografts may lead to better graft incorporation and ultimate outcomes. Fresh osteochondral allografts have been shown to have increased chondrocyte viability compared with fresh-frozen grafts,¹⁸ and we advocate using a fresh graft for the described procedure.

More recently, Riff et al.¹⁴ reported their mid-term results of fresh OAT to the humeral head in 20 patients with an average age of 25 years. They were able to follow up 90% of their patients for an average of 67 months and found that all but 2 grafts were radiographically incorporated, with a 61% survival rate. Eleven of the patients were satisfied, with all of the dissatisfied patients having undergone concomitant glenoid surgery in the same setting. Four patients, all of whom were being treated after pain pump chondrolysis, went on to shoulder arthroplasty. Significant improvements were reported for the visual analog scale score, Simple Shoulder Test score, and American Shoulder and Elbow Surgeons score, as well as the physical component score of the 12-Item Short Form Survey. This led the authors to conclude that OAT is a viable option for young patients with isolated humeral chondral injury. They cautioned against the treatment of patients with bipolar disease or a history of intra-articular pain pump use.

Treatment of an oblong or elliptical chondral lesion in the humeral head using a single, elongated osteochondral graft has not previously been described. This technique may be beneficial to optimize coverage of larger oblong defects while minimizing disruption of normal surrounding cartilage (Table 3). The use of multiple circular grafts in a snowman or Mastercard configuration (Mastercard, Purchase, NY) been the traditional option for the treatment of longer narrow lesions in the knee. Unfortunately, this technique in the knee has been shown to be inferior to single-graft transplantation, with a reoperation rate of 44% and

failure rate of 33% compared with 20% and 6%, respectively, for single grafts.¹⁹ As expected, these multiple-graft constructs show inferior clinical outcomes, graft incorporation, and graft survival. These constructs may lead to areas of articular incongruity and subsequent “cobblestoning” with fibrocartilage fill in the spaces between the grafts. Given the recent emphasis on subchondral bone in the treatment of chondral lesions, multiple-graft constructs are less advantageous in restoring this critical foundation for long-term cartilage survival. In addition, treatment with multiple grafts adds considerable operative time and often requires graft fixation to minimize the risk of loosening. The ability to harvest a larger, single graft is also beneficial owing to the paucity of surface area available to harvest multiple grafts. Considering the literature from the knee, there may be potential benefits to our elongated single-graft technique in the treatment of oblong or elliptical chondral lesions of the humeral head.

The BioHumi technique for OAT of the humeral head provides orthopaedic surgeons with a reproducible method of addressing large, oblong chondral defects. Because of the relative scarcity of symptomatic humeral head chondral lesions in comparison to the knee, there is a paucity of literature describing the outcomes of this procedure. Our report simplifies this technically demanding procedure, allowing for more reliable graft sizing and, ultimately, improved patient outcomes.

References

- Garrett JC. Treatment of osteochondral defects of the distal femur with fresh osteochondral allografts: A preliminary report. *Arthroscopy* 1986;2:222-226.
- Garrett JC. Fresh osteochondral allografts for treatment of articular defects in osteochondritis dissecans of the lateral femoral condyle in adults. *Clin Orthop Relat Res* 1994;303:33-37.
- Gerber C, Lambert SM. Allograft reconstruction of segmental defects of the humeral head for the treatment of chronic locked posterior dislocation of the shoulder. *J Bone Joint Surg Am* 1996;78:376-382.
- Saltzman BM, Riboh JC, Cole BJ, Yanke AB. Humeral head reconstruction with osteochondral allograft transplantation. *Arthroscopy* 2015;31:1827-1834.
- McDermott AG, Langer F, Pritzker KP, Gross AE. Fresh small-fragment osteochondral allografts: Long-term follow-up study on first 100 cases. *Clin Orthop Relat Res* 1985;197:96-102.
- Mankin HJ, Doppelt S, Tomford W. Clinical experience with allograft implantation: The first ten years. *Clin Orthop Relat Res* 1983;174:69-86.
- Sherman SL, Garrity J, Bauer K, Cook J, Stannard J, Bugbee W. Fresh osteochondral allograft transplantation for the knee: Current concepts. *J Am Acad Orthop Surg* 2014;22:121-133.
- Gross AE, Shasha N, Aubin P. Long-term follow-up of the use of fresh osteochondral allografts for posttraumatic knee defects. *Clin Orthop Relat Res* 2005;435:79-87.
- Nathan ST, Parikh SN. Osteoarticular allograft reconstruction for Hill-Sachs lesion in an adolescent. *Orthopedics* 2012;35:e744-e747.
- Patrizio L, Sabetta E. Acute posterior shoulder dislocation with reverse Hill-Sachs lesion of the epiphyseal humeral head. *ISRN Surg* 2011;2011:851051.
- Provencher MT, LeClere LE, Ghodadra N, Solomon DJ. Postsurgical glenohumeral anchor arthropathy treated with a fresh distal tibia allograft to the glenoid and a fresh allograft to the humeral head. *J Shoulder Elbow Surg* 2010;19:e6-e11.
- Trajkovski T, Mayne IP, Deheshi BM, Ferguson PC. Synovial chondromatosis of the shoulder: Open synovectomy and insertion of osteoarticular allograft with internal fixation to repair intraoperative glenohumeral joint instability. *Am J Orthop* 2011;40:e154-e158.
- Zhuo H, Xu Y, Zhu F, Pan L, Li J. Osteochondral allograft transplantation for large Hill-Sachs lesions: A retrospective case series with a minimum 2-year follow-up. *J Orthop Surg Res* 2019;14:344.
- Riff AJ, Yanke AB, Shin JJ, Romeo AA, Cole BJ. Midterm results of osteochondral allograft transplantation to the humeral head. *J Shoulder Elbow Surg* 2017;26:e207-e215.
- Diklic ID, Ganic ZD, Blagojevic ZD, Nho SJ, Romeo AA. Treatment of locked chronic posterior dislocation of the shoulder by reconstruction of the defect in the humeral head with an allograft. *J Bone Joint Surg Br* 2010;92:71-76.
- DiPaola MJ, Jazrawi LM, Rokito AS, et al. Management of humeral and glenoid bone loss—Associated with glenohumeral instability. *Bull NYU Hosp Jt Dis* 2010;68:245-250.
- Martinez AA, Navarro E, Iglesias D, Domingo J, Calvo A, Carbonel I. Long-term follow-up of allograft reconstruction of segmental defects of the humeral head associated with posterior dislocation of the shoulder. *Injury* 2013;44:488-491.
- Bugbee WD, Convery FR. Osteochondral allograft transplantation. *Clin Sports Med* 1999;18:67-75.
- Cotter EJ, Hannon CP, Christian DR, et al. Clinical outcomes of multifocal osteochondral allograft transplantation of the knee: An analysis of overlapping grafts and multifocal lesions. *Am J Sports Med* 2018;46:2884-2893.