



Case report

Disease recurrence after lung transplantation for idiopathic pulmonary hemosiderosis

Bryan Ross^{a,d}, Kieran Halloran^a, Benjamin Adam^b, Bryce Laing^c, Alim Hirji^{a,*}^a Department of Medicine, University of Alberta, Edmonton, Canada^b Department of Laboratory Medicine, University of Alberta, Edmonton, Canada^c Department of Surgery, University of Alberta, Edmonton, Canada^d Department of Medicine, McGill University, Montreal, Canada

ARTICLE INFO

Keywords:

Idiopathic pulmonary hemosiderosis
 Pulmonary hypertension
 Lung transplant
 Hemoptysis
 Disease recurrence

ABSTRACT

Idiopathic pulmonary hemosiderosis is characterized by the triad of hemoptysis, iron deficiency anemia and pulmonary infiltrates. Though idiopathic pulmonary hemosiderosis has classically been described as a childhood disease, survival into adulthood is possible. Treatment options for advanced and/or refractory disease is limited, and in our unique case of idiopathic pulmonary hemosiderosis with precapillary pulmonary hypertension, lung transplantation has had a favorable short-term outcome. We also demonstrate that disease recurrence of idiopathic pulmonary hemosiderosis following lung transplantation is possible.

1. Case presentation

A 26-year-old female diagnosed with idiopathic pulmonary hemosiderosis (IPH) since age 5 presented for lung transplantation evaluation. She originally presented with childhood hemoptysis and underwent a comprehensive rheumatological and infectious workup including lung and kidney biopsy to rule out vasculitis and other potential etiologies. Without a secondary cause, she was diagnosed with idiopathic pulmonary hemosiderosis. To manage intermittent bouts of hemoptysis, she was maintained on prednisone and azathioprine, and treated with high-dose glucocorticoids during exacerbations.

Into adulthood she developed progressive hypoxic respiratory failure with severe precapillary pulmonary hypertension (mean pulmonary arterial pressure 63 mmHg) requiring treatment with tadalafil and ambrisentan, as well as continuous subcutaneous treprostinil. Computed tomography images revealed extensive basal-predominant ground glass opacities (see Fig. 1).

Pulmonary function revealed worsening forced vital capacity and diffusion capacity. At the age of 26, she underwent bilateral lung transplant. She developed severe primary graft dysfunction requiring veno-venous extracorporeal membrane oxygenation (vv-ECMO) support on day 2 post-transplant, and was eventually decannulated and liberated from ventilation one week post-transplant. Explant pathology revealed

end-stage disease, diffuse alveolar septal fibrosis, extensive interstitial and airspace hemosiderin deposition, and marked fibrointimal thickening and medial hyperplasia of the pulmonary arteries (see Fig. 2).

Lung function and oxygen saturations normalized post-transplant with no residual impairment in functional status. At 1.5 years post-transplant she experienced low-volume hemoptysis. Computed tomography revealed new lingular ground glass, and bronchoscopic samples revealed only hemosiderin-laden macrophages with negative microbiologic cultures. Repeat rheumatologic serology was negative and her presentation was deemed to be recurrence of her primary disease. Immunosuppression was augmented, by maintaining mycophenolate mofetil at 1000mg BID, tacrolimus target levels between 8 and 10 and prednisone increased to 30mg for 10 days followed by her standard dose of 5mg daily. With this management alone, her radiographic findings resolved. At 2.5 years post-transplant she developed a macular rash on her palms and soles and pulmonary nodules on chest x-ray. Rapid plasma reagin and syphilis enzyme immunoassay testing were reactive and she was diagnosed with pulmonary syphilis. Bronchoscopy cultures were negative, however alveolar hemosiderin deposits were again noted on cytological examination. She however has had no further bouts of hemoptysis and the syphilitic infection was successfully treated with IV penicillin.

* Corresponding author. University of Alberta, 11350 83rd Street, 3-114F Clinical Sciences Building, Edmonton, Alberta, T6G 2G3, Canada.

E-mail addresses: bryan.ross@mail.mcgill.ca (B. Ross), kieran.halloran@ualberta.ca (K. Halloran), baadam@ualberta.ca (B. Adam), blaing@ualberta.ca (B. Laing), ahirji@ualberta.ca (A. Hirji).

<https://doi.org/10.1016/j.rmcr.2020.101128>

Received 26 May 2020; Accepted 9 June 2020

Available online 10 June 2020

2213-0071/© 2020 The Authors.

Published by Elsevier Ltd.

This is an open access article under the CC BY-NC-ND license

(<http://creativecommons.org/licenses/by-nc-nd/4.0/>).

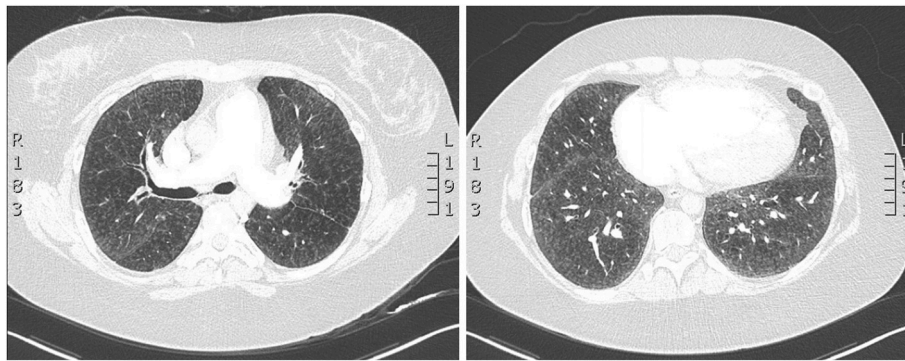


Fig. 1. Pre-transplant computed tomography images showing a dilated pulmonary artery suggestive of pulmonary hypertension (left) and extensive, basal-predominant, centrilobular ground glass opacities with smooth septal thickening (right).

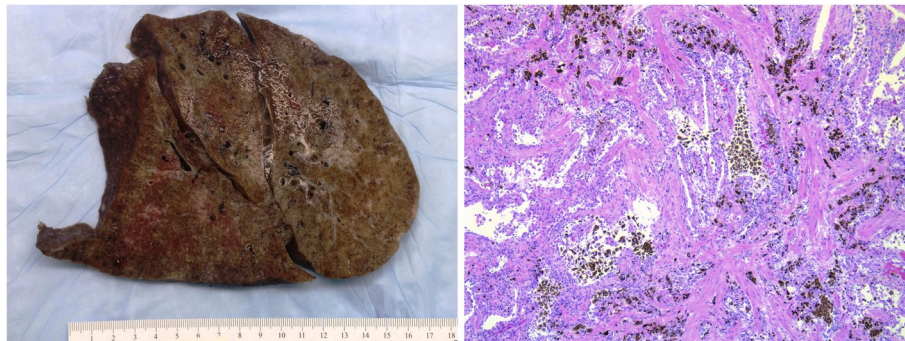


Fig. 2. Gross (left) and microscopic (right) pathology from explanted native lungs revealing diffuse homogeneous alveolar septal fibrosis with clusters of alveolar hemosiderin-laden macrophages and interstitial hemosiderin deposition.

2. Discussion

IPH is a rare cause of alveolar hemorrhage with an estimated incidence of approximately 0.24 [1]-1.23 [2] per million children. It is characterized by a triad of hemoptysis, iron deficiency anemia and pulmonary infiltrates [3]. 80% of cases are diagnosed in childhood, with a variable clinical trajectory [4,5]. Progressive hemosiderin-laden macrophage deposition occurs with recurrent alveolar bleeding episodes, ultimately leading to lung fibrosis. Although in general the prognosis of IPH is considered to be poor with a mean survival period of 2.5 years after diagnosis, long-term survival into adulthood is also observed [4]. A variety of imaging findings have been documented in the adult patient with IPH. Ground glass opacities and consolidation are typically observed in acute phases, while interlobular septal thickening and pulmonary fibrosis characterizes the chronic phase [6].

Various autoimmune, allergic, environmental and genetic mechanisms have been postulated [3,7]. The clinical response to immunosuppressive therapy additionally implicates immune processes in the pathogenesis of disease. The cornerstone of management of IPH remains chronic corticosteroids, with increased dosing during acute episodes. The evidence regarding the use of alternative therapeutic classes is lacking [8].

This is the first reported case of lung transplantation for IPH with concomitant pulmonary hypertension. To our knowledge, only two prior cases [9,10] have documented recurrence of IPH in the transplanted lung. The overall prognosis of IPH following lung transplantation is unknown. The present case demonstrates that these patients are at risk of severe group 3 pulmonary hypertension, and that successful outcomes are feasible following lung transplantation, and transplant should be considered if patients develop significant hypoxemia or functional limitation, despite maximal medical therapy. Lastly, disease recurrence remains a possibility following lung transplantation in this patient

population, but can be successfully managed with augmented immunosuppression.

Conflict of Interest Statement

None of the authors have any conflicts of interest to disclose.

Submission declaration and verification

The work described has not been published previously and is not under consideration for publication elsewhere. Its publication is approved by all authors.

Author contributions

BR collected the relevant data, images and wrote the first draft of the manuscript. KH and BL helped collect data and write and review the manuscript. BA retrieved relevant pathology slides and reviewed the manuscript. AH helped collect data and write, review and finalize the manuscript.

Funding

This research did not receive any specific grant from funding agencies in the public, commercial, or not-for-profit sectors.

Consent

Informed consent was obtained from the patient prior to submission for publication.

Declaration of competing interest

None.

Appendix A. Supplementary data

Supplementary data to this article can be found online at <https://doi.org/10.1016/j.rmcr.2020.101128>.

References

- [1] B. Kjellman, G. Elinder, S. Garwicz, H. Svan, Idiopathic pulmonary haemosiderosis in Swedish children, *Acta Paediatr. Scand.* 73 (1984) 584–588.
- [2] S. Ohga, K. Takahashi, S. Miyazaki, H. Kato, K. Ueda, Idiopathic pulmonary haemosiderosis in Japan: 39 possible cases from a survey questionnaire, *Eur. J. Pediatr.* 154 (1995) 994–995.
- [3] J. Taytard, N. Nathan, J. de Blic, M. Fayon, R. Epaud, A. Deschildre, F. Troussier, M. Lubrano, R. Chiron, P. Reix, P. Cros, M. Mahloul, D. Michon, A. Clement, H. Corvol, New insights into pediatric idiopathic pulmonary hemosiderosis: the French RespiRare® cohort, *Orphanet J. Rare Dis.* 8 (2013) 161–167.
- [4] L. Le Clainche, M. Le Bourgeois, B. Fauroux, N. Forenza, J.P. Dommergues, J. C. Desbois, G. Bellon, J. Derelle, G. Dutau, C. Marguet, I. Pin, I. Tillie-Leblond, P. Scheinmann, J. De Blic, Long-term outcome of idiopathic pulmonary hemosiderosis in children, *Medicine* 79 (2000) 318–326.
- [5] M.M. Saeed, M.S. Woo, E.F. Mac Laughlin, M.F. Margetis, T.G. Keens, Prognosis in pediatric idiopathic pulmonary hemosiderosis, *Chest* 116 (1999) 721–725.
- [6] L. Khorashadi, C.C. Wu, S.L. Betancourt, B.W. Carter, Idiopathic pulmonary haemosiderosis: spectrum of thoracic imaging findings in the adult patient, *Clin. Radiol.* 70 (2015) 459–465.
- [7] O. Ioachimescu, S. Sieber, A. Kotch, Idiopathic pulmonary haemosiderosis revisited, *Eur. Respir. J.* 24 (2004) 162–170.
- [8] C.I.C. Chin, S.L. Kohn, T.G. Keens, M.F. Margetis, R.M. Kato, A physician survey reveals differences in management of idiopathic pulmonary hemosiderosis, *Orphanet J. Rare Dis.* 10 (2015) 98.
- [9] B.M. Wroblewski, C.R. Stefanovic, V.M. McDonough, P.J. Kidik, The challenges of idiopathic pulmonary hemosiderosis and lung transplantation, *Crit. Care Nurse* 17 (1997) 39–44.
- [10] F. Calabrese, C. Giacometti, F. Rea, M. Loy, F. Sartori, G. Di Vittorio, A. Abudurehman, G. Thiene, M. Valente, Recurrence of idiopathic pulmonary hemosiderosis in a young adult patient after bilateral single-lung transplantation, *Transplantation* 74 (2002) 1643–1645.