



Surgical techniques for Baerveldt glaucoma implant removal[☆]

Zaid Parekh^a, Ian Patterson^b, Mary Qiu^{b,*}

^a The University of Chicago Pritzker School of Medicine, Chicago, IL, USA

^b Department of Ophthalmology & Visual Sciences, University of Chicago, Chicago, IL, USA

ARTICLE INFO

Keywords:

Baerveldt glaucoma implant
Ahmed glaucoma valve
Glaucoma drainage device
Aqueous shunt
Tube shunt
Glaucoma surgery
Surgical technique

ABSTRACT

Purpose: To describe two surgical techniques for removing Baerveldt-350 Glaucoma Implants (BGI-350).
Observations and plan: A 91-year-old female with history of bilateral BGI-350s and prior history of tube associated endophthalmitis in the left eye requiring tube removal and resultant phthisis was referred for tube erosion and hypopyon in the right only-seeing eye, and we recommended tube removal. On exam, the left phthisical eye still had a BGI-350 plate attached under the lateral rectus muscle by one anchoring stalk, as it had not been fully removed previously, and the patient recalled severe pain during attempted tube removal in the left eye. We performed concurrent removal of both BGI-350s under general anesthesia. We describe a surgical technique for removing a BGI-350 when the conjunctiva does not need to be spared for future surgery. We also present a second case of BGI-350 removal with a different technique that aims to spare the conjunctiva for future surgery.
Conclusions and importance: BGI-350s can develop complications requiring repositioning, revision, or removal. Improper removal of BGI-350s can lead to patient discomfort and future complications. We highlight two different techniques to remove a BGI-350, depending on whether the conjunctiva is intended to be spared for future surgery or not. With either technique, we advocate for general anesthesia and a posterior scleral traction suture to provide patient comfort and optimal exposure of the surgical field.

1. Introduction

Baerveldt-350 glaucoma implants (BGI-350), a common surgery for lowering intraocular pressure, may develop complications requiring repositioning, revision, or removal.^{1,2} Although tubes are typically tunneled through sclera and covered with patch grafts (donor sclera, cornea, or pericardium), postoperative tube exposure and erosions have still been reported to occur in 2–7% of patients and exposure rates are similar in various patch graft materials.^{3,4,5} If a tube-associated infection results, the tube may need to be repositioned or removed.³ It can often be technically challenging to remove BGI-350s since the implant's "wings" are meant to be positioned under two adjacent rectus muscles and the plate becomes encapsulated over time.¹ The BGI-350's plate has six holes, two anterior holes for suture fixation to the globe, and four posterior holes along the length of the plate, two of which are in the wings under the muscles. A fibrous stalk grows through each of the six holes, and the four through the plate promote a lower-profile bleb. All 6 fibrous stalks must be identified and severed in order to completely

remove a BGI-350 plate.

The purpose of this report is to describe various surgical strategies and techniques for safely and completely removing BGI-350s. The first strategy is demonstrated via an illustrative case of a patient who underwent bilateral BGI-350s by an outside glaucoma specialist and subsequently developed sequential tube erosions and tube-associated infections in both eyes necessitating complete implant removal in both eyes. The second strategy is demonstrated via an illustrative case of a patient who underwent a same-quadrant exchange of a BGI-350 to an Ahmed FP7 for hypotony as well as a need to reposition the tube tip from the anterior chamber to the ciliary sulcus. The current literature does not adequately address surgical techniques for BGI-350 removal in these clinical situations.

2. Case presentation #1

A 91-year-old African American pseudophakic female with history of severe primary open angle glaucoma in both eyes and bilateral BGI-350

List of Abbreviations: BGI-350, Baerveldt-350 glaucoma implants; NLP, no light perception; IOP, Intraocular Pressure.

[☆] Institution at which the study was conducted: University of Chicago Medical Center.

* Corresponding author. 5758 S. Maryland Ave, Suite 1B, Chicago, IL, 60637, USA.

E-mail address: mary.qiu@gmail.com (M. Qiu).

<https://doi.org/10.1016/j.ajoc.2023.101948>

Received 25 March 2023; Received in revised form 3 October 2023; Accepted 11 October 2023

Available online 2 November 2023

2451-9936/© 2023 The Authors. Published by Elsevier Inc. This is an open access article under the CC BY-NC-ND license (<http://creativecommons.org/licenses/by-nc-nd/4.0/>).

implants was referred by her retina specialist for tube erosion in the right eye. Records indicate that her left eye had developed tube-associated endophthalmitis several years ago, underwent removal of the BGI-350, and became NLP and phthisical.

On presentation, the right eye had a visual acuity of 20/60, and the intraocular pressure was 10 mmHg on 3 topical IOP-lowering medications. There was a superotemporal BGI-350 with the tube tip in the anterior chamber, and the conjunctiva was eroded over the tube at its insertion site 1–2mm behind the limbus. There was no visible scleral or corneal patch graft. The cornea was clear. The anterior chamber was deep with 4+ cell and a 0.5mm hypopyon. There was no vitritis, the retina was attached, and the referring retina specialist had already administered intravitreal antibiotics. Given her monocular status and previous history of tube-associated endophthalmitis in the fellow eye, we recommended urgent removal of the BGI-350 from the right eye.

On examination of her phthisical left eye, it was discovered that there was still a BGI-350 plate in the superotemporal quadrant attached to the eye by a single anchoring stalk under the lateral rectus muscle. The rest of the plate, including the wing that was originally under the superior rectus muscle, was superficial to the conjunctiva, and five of the six anchoring stalks in the plate appeared to have been severed. The tube appeared to have been “unplugged” from the eye and amputated from the plate. The operative report from the surgery to remove the tube from the left eye was not available. Upon further questioning, the patient reported that she remembers being awake under mild sedation during the tube removal surgery for the left eye and it was extremely painful,

which we hypothesize may have contributed to its incomplete removal. We recommended concurrent removal of BGI-350 plate from the left eye. Surgery on both eyes was performed under general anesthesia.

Video 1 and Video 2 demonstrate the surgery to remove the BGI-350 from this patient’s right and left eye, respectively.

This patient was adamant that she did not want any future tube implants, so the surgical approach to remove the BGI-350 prioritized efficiency rather than conjunctival sparing (*Strategy 1*). The conjunctiva was dissected off the tube at the limbus. The tube was “unplugged” from the eye, amputated from the plate, and the track was sutured with an 8-0 Vicryl (Ethicon, Raritan, NJ) on a BV needle parallel to, and directly through, the track. This step can alternatively be performed with a figure-of-8 stitch. A posterior scleral traction suture was placed. The conjunctiva, Tenons, and capsule were opened in a line overlying the BGI-350’s “ridge” with a full-thickness radial-relaxing incision in the middle of the plate, creating a T-shaped incision which provided access to both of the BGI-350’s two wings (Fig. 1A and B). The two anterior anchoring stalks were identified and severed. The four posterior anchoring stalks were identified, either by direct visualization for the central two stalks or with a blunt strumming motion for the two stalks under the rectus muscles, and subsequently severed, and the plate was removed (Fig. 1C). The conjunctiva was closed with interrupted sutures, and a watertight seal was not necessary.

Post-operatively, the patient’s right eye remained in the 20/60 range without infection. As expected, the IOP increased after tube removal, so she underwent *trans*-scleral “slow burn” cyclophotocoagulation 20 days

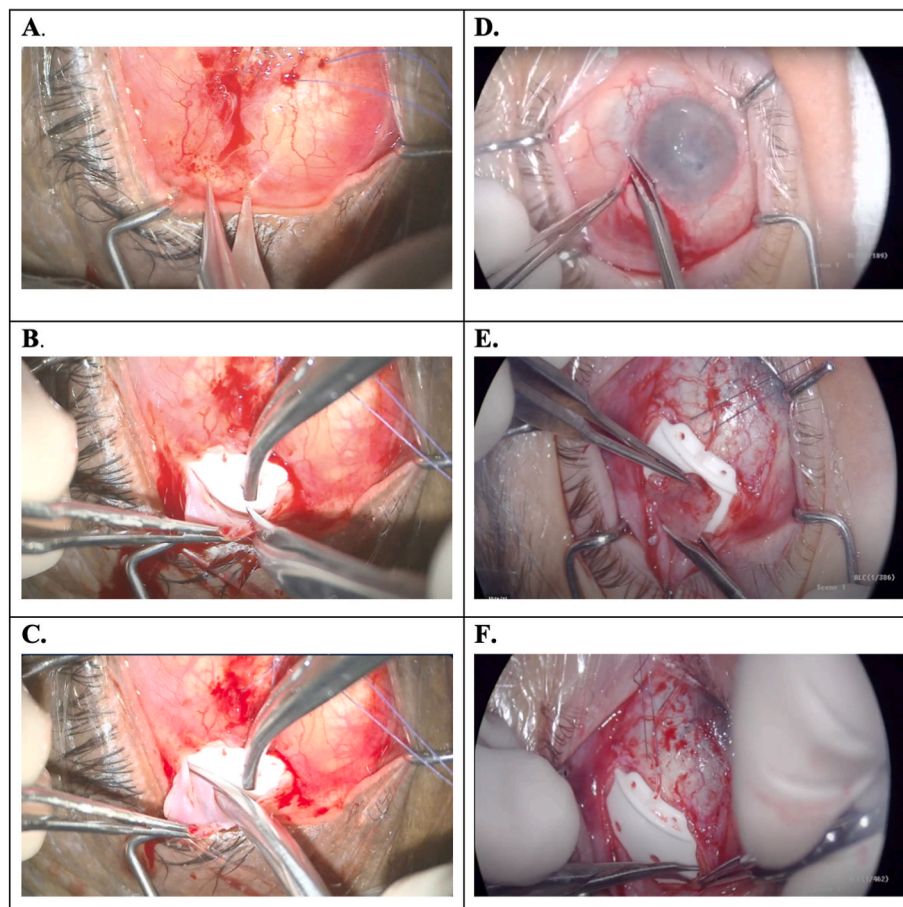


Fig. 1. Video stills highlighting key didactic points from the surgeries. **A.** When sacrificing the conjunctiva (*Strategy 1*), an incision was made in the conjunctiva directly overlying the ridge of the Baerveldt plate. **B.** A full thickness radial relaxing incision was made in the conjunctiva and capsule in between the two central anchoring stalks growing through the plate. **C.** Central anchoring stalk was identified and severed. **D.** When planning to spare the conjunctiva (*Strategy 2*), the conjunctiva was opened at the limbus. **E.** Two radial incisions were made in the BGI-350 capsule adjacent to the rectus muscles and connected to harvest a square-shaped piece of capsular tissue for later use as a patch graft. **F.** Anchoring stalk under the rectus muscle was identified using blunt strumming motion and severed.

later.⁶ The patient's best corrected visual acuity remained 20/60, a repeat *trans*-scleral cyclophotocoagulation was performed 9 months later. By postoperative month 14 after the original tube removal surgery, the best corrected visual acuity was 20/50 (one line better than her presenting visual acuity), and the IOP was 10 mmHg on applanation on one IOP-lowering medication (preservative-free timolol). The left eye remained phthisical and comfortable without infection.

3. Case presentation #2

The second case is a 51-year-old monocular pseudophakic male with aniridia associated keratopathy and a prior BGI-350 in the anterior chamber in the right eye. There was hypotony, corneal failure requiring a planned future penetrating keratoplasty, and the retina was attached on B-scan. The cornea service requested for the IOP to be higher and for the tube tip to be repositioned to the ciliary sulcus to facilitate a future penetrating keratoplasty. A same-quadrant BGI-350 to Ahmed FP7 was performed, which is demonstrated in Video 3.

Since this patient was to undergo the implantation of a new Ahmed FP7 in the same quadrant as the prior BGI-350, the surgical approach to remove the BGI-350 prioritized conjunctival sparing for planned future surgery (*Strategy 2*). The conjunctiva was opened at the limbus, with radial relaxing incisions superiorly and temporally (Fig. 1D). The tube was "unplugged" from the anterior chamber, amputated from the plate, and the track was sutured in the same manner as *Strategy 1*. A posterior scleral traction suture was placed. The conjunctiva and Tenons were dissected to reveal the BGI-350 capsule. The capsule was opened in a line directly along the BGI-350's "ridge". Two radial incisions were made in the BGI-350 capsule, adjacent to the rectus muscles, taking care to avoid the muscles. The two anterior anchoring stalks were identified and severed. The two anchoring stalks in the center of the plate were severed, and the radial incisions were connected to harvest a square-shaped capsular autograft (Fig. 1E).⁷ The remaining anchoring stalks under the rectus muscles were identified either by direct visualization or with a blunt strumming motion, and severed, and the plate was removed (Fig. 1F). Since this was a planned tube exchange, the new Ahmed FP7 was implanted in this quadrant, and the capsule tissue from the prior BGI-350 was used as a patch graft for the new tube.⁷ The conjunctiva could not be reapproximated to the limbus without significant tension, so a conjunctival free graft from the contralateral NLP eye was harvested to aid with conjunctival closure; the patient had been consented for this in advance, since this was an anticipated possible issue.

Post-operatively, the IOP rose as intended, the new tube was in the ciliary sulcus, and the patient transferred care to a different institution so long-term follow-up is not available.

4. Discussion

The surgical removal of Baerveldt-350 implants is often challenging. Through the presentation of two distinct cases, we showcase techniques for the safe and effective BGI-350 removal that add to the literature.

In Case #1, the indication for BGI-350 removal was tube erosion with anterior chamber reaction and hypopyon in a monocular patient who had already suffered tube-associated endophthalmitis in the fellow eye with resultant NLP vision. There are numerous surgical strategies for managing tube erosion with associated infection. If there is no concern for plate infection and the intention is to attempt to salvage the function of the existing device, the tube can be "unplugged" from the eye, tucked into the subconjunctival space, and subsequently reinserted after the infection resolves.⁸ Alternatively, if the intention is not to salvage the function of the existing device, and the goal is to disinsert the tube from the eye as efficiently as possible, the tube can be "unplugged" from the eye and amputated from the plate, and the plate and its surrounding capsule can be left in place. However, the plate itself can potentially harbor an indolent infection even in the absence of frank injection or purulence. Leaving the plate behind can risk current or future infection

spreading to the orbit, since orbital cellulitis associated with tube shunts has been reported both in the presence and absence of tube erosion.^{9,10} Orbital cellulitis also carries a theoretical risk of infection spreading to the brain or blood stream, which has been reported in the setting of sinusitis or trauma,¹¹⁻¹³ but has not yet been reported in the setting of an infected tube shunt. Finally, the most thorough option involves "unplugging" the tube from the eye and removing the entire tube-plate complex to eliminate any possible source of evolving infection. Since this patient had already suffered a blinding tube-associated endophthalmitis in the fellow eye, she was strongly motivated to undergo complete removal of the entire tube-plate complex, and wished to avoid any future tubes in her only-seeing eye.

There is a paucity of literature describing surgical techniques for BGI-350 removal. Morino et al. reported a case of Baerveldt removal in a 35-year-old patient with secondary glaucoma who had developed strabismus after the Baerveldt implantation which was refractory to multiple strabismus surgeries.¹⁴ The BGI was removed in combination with a lateral rectus resection for esotropia. In that case, incisions adjacent to the lateral rectus were employed to perform the muscle disinsertion. Both of our patients were monocular, so strabismus and diplopia were not a concern. Nonetheless, we aimed to avoid disrupting or injuring the rectus muscles with our BGI-350 removal surgery. In general, we caution against cutting too close to the rectus muscles when removing a BGI-350. In the absence of strabismus concerns, if exchanging a BGI-350 for a smaller device (e.g. BGI-350 to Ahmed, BGI-350 to BGI-250, BGI-350 to ClearPath 250, etc.), there would be no reason to disturb the portion of the capsule that is under the rectus muscle, since the capsule retains the shape of the original plate and provides ample width for the insertion of a smaller device in the same quadrant. When exchanging a BGI-350 to an Ahmed, as in Case #2, the Ahmed is longer in the anterior-posterior direction which requires that the posterior cul-de-sac of the BGI-350 capsule be incised or removed so the new Ahmed can be positioned far enough posteriorly.

Conversely, there may be instances when exchanging a smaller device for a larger device is warranted (e.g. Ahmed to BGI 350). Our group published a report describing the surgical technique for performing a same-quadrant Ahmed to Baerveldt-350 exchange.¹⁵ While the overall techniques and principles are similar to the Baerveldt-350 to Ahmed exchange shown in Case #2, a notable distinction is the difference in the width of the two devices. When exchanging an Ahmed for a BGI-350, the surgeon must ensure that the capsule next to the rectus muscles is carefully dissected off the bare sclera and muscle edge so that the new BGI wings can be tucked under the muscles. There is a theoretical risk of injuring the rectus muscles and causing strabismus. Even if the muscle is not directly injured, there is still a potential risk of restrictive strabismus due to fibrosis near the rectus muscles.

In conclusion, when removing BGI-350s, we advocate for general anesthesia and a posterior scleral traction suture to provide optimal exposure of the surgical field. If the goal is to remove the tube and there is no intention to return to the same quadrant for subsequent surgery, then it may be advantageous to open the conjunctiva and capsule with a T-shaped incision directly over the plate (*Strategy 1*). Conversely, if the goal is to preserve the quadrant for another future tube, it may be advantageous to open the conjunctiva at the limbus to keep the conjunctiva in one continuous sheet and open the capsule with two radial incisions adjacent to the two rectus muscles (*Strategy 2*). These surgical techniques are useful in various clinical scenarios when BGI-350 removal is indicated.

5. Patient consent

- Patient #1: The patient consented to publication of the case in writing.
- Patient #2: Consent to publish the case report was not obtained because the patient has transferred care elsewhere. This report does

not contain any personal information that could lead to the identification of the patient.

Declaration of competing interest

The authors declare that they have no known competing financial interests or personal relationships that could have appeared to influence the work reported in this paper.

Acknowledgments and disclosures

No funding or grant support. The following authors have no financial disclosures: (ZP, MQ, IP). All authors attest that they meet the current ICMJE criteria for Authorship.

Appendix A. Supplementary data

Supplementary data to this article can be found online at <https://doi.org/10.1016/j.ajoc.2023.101948>.

References

- Bains U, Hoguet A. Aqueous drainage device erosion: a review of rates, risks, prevention, and repair. *Semin Ophthalmol*. 2018;33(1):1–10. <https://doi.org/10.1080/08820538.2017.1353805>.
- Stewart WC, Kristoffersen CJ, Demos CM, Fsadni MG, Stewart JA. Incidence of conjunctival exposure following drainage device implantation in patients with glaucoma. *Eur J Ophthalmol*. 2010 Jan-Feb;20(1):124–130. <https://doi.org/10.1177/112067211002000117>. PMID: 19927268.
- Chaku M, Netland PA, Ishida K, Rhee DJ. Risk factors for tube exposure as a late complication of glaucoma drainage implant surgery. *Clin Ophthalmol*. 2016 Mar 30;10:547–553. <https://doi.org/10.2147/OPHTH.S104029>. PMID: 27099461; PMCID: PMC4820194.
- Kang JM, Hsia YC, Han Y. A novel technique for recurrent tube exposure repair. *Case Rep Ophthalmol Med*. 2020;2020, 6878025. <https://doi.org/10.1155/2020/6878025>. Published 2020 Mar 2.
- Smith MF, Doyle JW, Ticrney Jr JW. A comparison of glaucoma drainage implant tube coverage. *J Glaucoma*. 2002 Apr;11(2):143–147. <https://doi.org/10.1097/00061198-200204000-00010>. PMID: 11912362.
- Khodeiry MM, Liu X, Lee RK. Clinical outcomes of slow-coagulation continuous-wave transscleral cyclophotocoagulation laser for treatment of glaucoma. *Curr Opin Ophthalmol*. 2022 May 1;33(3):237–242. <https://doi.org/10.1097/ICU.0000000000000837>. Epub 2022 Feb 23. PMID: 35200163; PMCID: PMC9530031.
- Qiu M. Aqueous shunt revision with autologous capsular patch graft: surgical technique description and preliminary results. *Ophthalmol Glaucoma*. 2021;4(6):646–648. <https://doi.org/10.1016/j.ogla.2021.05.005>.
- Mitsui N, Sugihara K, Seguchi J, Chihara E, Morizane Y, Narita A. Corynebacterium ocular infection after Baerveldt glaucoma implant surgery: treatment involving immediate tube withdrawal and temporary subconjunctival tube placement: a case report. *BMC Ophthalmol*. 2021 Oct 18;21(1):368. <https://doi.org/10.1186/s12886-021-02136-6>. PMID: 34663253; PMCID: PMC8525009.
- Laviña AM, Creasy JL, Tsai JC. Orbital cellulitis as a late complication of glaucoma shunt implantation. *Arch Ophthalmol*. 2002;120(6):849–851.
- Kassam F, Lee BE, Damji KF. Concurrent endophthalmitis and orbital cellulitis in a child with congenital glaucoma and a glaucoma drainage device. *Digit J Ophthalmol*. 2011;17(4):58–61. <https://doi.org/10.5693/djo.02.2011.10.002>. Epub 2011 Nov 6. PMID: 23362400; PMCID: PMC3516167.
- Berdouk S, Pinto N. Fatal orbital cellulitis with intracranial complications: a case report. *Int J Emerg Med*. 2018;11:51. <https://doi.org/10.1186/s12245-018-0211-x>.
- Constantin F, Niculescu PA, Petre O, et al. Orbital cellulitis and brain abscess - rare complications of maxillo-spheno-ethmoidal rhinosinusitis. *Rom J Ophthalmol*. 2017 Apr-Jun;61(2):133–136. <https://doi.org/10.22336/rjo.2017.25>. PMID: 29450387; PMCID: PMC5710022.
- Kyari F. Emergency management: orbital cellulitis. *Community Eye Health*. 2018;31(103):60. PMID: 30487680; PMCID: PMC6253316.
- Morino MU, Akagi T, Miyata M, et al. Removal of a Baerveldt glaucoma implant and fibrous adhesion for refractory mechanical strabismus. *Case Rep Ophthalmol*. 2020 Jun 29;11(2):249–255. <https://doi.org/10.1159/000508067>.
- Kim IJ, Kanter JA, Qiu M. A surgical technique for same-quadrant ahmed-to-baerveldt exchange. *Ophthalmol Glaucoma*. 2023 Sep-Oct;6(5):564–565. <https://doi.org/10.1016/j.ogla.2023.05.004>. Epub 2023 May 18. PMID: 37207888.