

# Azithromycin in DuraSite<sup>®</sup> for the treatment of blepharitis

Jodi Luchs

Department of Ophthalmology  
and Visual Sciences, Albert Einstein  
College of Medicine, Bronx, NY, USA

**Abstract:** Blepharitis is a common inflammatory disease of the eyelid. Posterior blepharitis affects the posterior lamella of the eyelid and involves inflammation of the meibomian glands, whereas anterior blepharitis affects the anterior lamella of the eyelid and the eyelashes; either version can be inflammatory or infectious in nature. Each of these conditions can incite or propagate the other; anterior blepharitis, if not treated, can lead to meibomian gland disease, and vice versa. Blepharitis is typically chronic, and can be associated with a variety of systemic diseases such as dermatitis, as well as ocular diseases such as dry eye, conjunctivitis, or keratitis. The standard treatment regimen historically consists of lid hygiene with warm compresses and eyelid scrubs, although these treatment modalities may have limited efficacy for many patients, especially those with more severe disease. Adjunctive treatment includes systemic and topical antibiotics, topical corticosteroids, and tear replacement therapy. Topical antibiotics are recommended to decrease the bacterial load, and topical corticosteroids may help in cases of severe inflammation. Azithromycin ophthalmic solution 1% in DuraSite<sup>®</sup> (AzaSite<sup>®</sup>; Inspire Pharmaceuticals, Durham, North Carolina, USA) has been proposed as a novel treatment for posterior blepharitis, based on its well-known anti-infective profile, its anti-inflammatory properties, its excellent tissue penetration, and its regulatory approval for the treatment of bacterial conjunctivitis. This review focuses on an off-label indication for topical azithromycin 1% in DuraSite for the treatment of blepharitis.

**Keywords:** lid margin disease, meibomian gland disease

## Introduction

Blepharitis is one of the most common ocular surface disorders encountered by eye care professionals. However, the condition is frequently overlooked due to its multifactorial etiology and the variability of the presenting signs and symptoms. It often presents in combination with other ocular surface diseases, while it may also present as a standalone condition, further contributing to its underdiagnosis in clinical settings.<sup>1</sup> Classically, several forms of the disease have been described,<sup>2,3</sup> most of which are chronic in nature.<sup>1,4</sup> The disease can be broadly categorized into anterior and posterior, with the former involving an infectious and inflammatory condition of the external lamella of the eyelids and lashes, and the latter involving inflammation of the inner lamella of the eyelids and the meibomian glands, associated with an altered composition of meibomian gland secretions. Posterior blepharitis is also referred to as meibomian gland disease (MGD). Compared with patients with anterior blepharitis, those with posterior blepharitis (MGD) tend to be older and may present with a longer history of symptoms. Although the disease typically first manifests in middle age, it can also present in childhood.<sup>5</sup>

Correspondence: Jodi Luchs  
2185 Wantagh Avenue, Wantagh,  
NY 11793, USA  
Tel +1 516-785-3900  
Fax +1 516-783-0033  
Email jluchs@aol.com

Clinical symptoms are usually chronic and include burning, grittiness, dryness or a foreign body sensation, redness, crusty eyelids, heavy eyelids, or fluctuating vision. Clinical signs include lid margin hyperemia, crusting of the lashes, plugging or inspissation of the meibomian gland orifices, abnormal, thickened meibomian gland secretions, foamy tears, and tear film debris or an unstable tear film.

Interestingly, there is a paucity of information on the epidemiology and prevalence rates of blepharitis.<sup>5</sup> A recent survey indicated that blepharitis may be present in 37%–47% of all patients seen by ophthalmologists and optometrists.<sup>6</sup> The same survey found that age is a factor in the presentation – men older than 65 years and women aged between 46 and 65 years were most often predisposed to posterior blepharitis.<sup>6</sup> Overall published prevalence rates range from 12% to 47%,<sup>6–9</sup> yet some of these studies have inherent limitations, including a relatively small sample size<sup>8,9</sup> or an inherent bias in survey responses due to the known study sponsorship.<sup>7</sup> Prevalence rates may be further confounded by the diagnostic confusion resulting from the overlap of clinical signs and symptoms of blepharitis with those of other ocular surface diseases such as dry eye. A study by Macsai et al<sup>10</sup> reported a significant overlap in symptoms between patients with dry eye disease and blepharitis; 68% of patients older than 60 years presented with signs and symptoms of both diseases. Such results may be due to the prevalence of dry eye disease presenting as a coexisting condition along with blepharitis in this population or the presence of a secondary keratoconjunctivitis sicca due to evaporative tear loss that may be evident in up to 50% of patients with blepharitis.<sup>5</sup>

Most cases of chronic blepharitis, whether anterior or posterior, are associated with a bacterial component, usually consisting of gram-positive organisms such as staphylococcal species.<sup>5</sup> However, due to the variety of associated bacteria, the wide range of clinical signs and symptoms and the incidence of additional comorbid ocular diseases, the current therapeutic goals are aimed at chronic disease management rather than a cure of the condition.

At present, there is no US Food and Drug Administration (FDA)-approved definitive therapy for either anterior or posterior blepharitis in the United States.<sup>1</sup> Because both acute and chronic forms of the disease involve the presence of inflammation and bacteria, a comprehensive therapy that offers both antibiotic and anti-inflammatory properties coupled with good penetration into the lid tissue and convenient dosing may prove beneficial for this condition.

Azithromycin ophthalmic solution 1% in DuraSite® (AzaSite®; Inspire Pharmaceuticals, Durham, North Carolina,

USA) has been proposed as a novel treatment for blepharitis. Azithromycin, like erythromycin (another macrolide) and doxycycline, has been historically shown to have anti-inflammatory properties,<sup>11,12</sup> and to improve clinical signs and symptoms of blepharitis after oral administration.<sup>13</sup> An effective topical delivery system for azithromycin could potentially deliver the same effects without the systemic side effects associated with oral administration. Topical delivery of ophthalmic preparations can be advantageous by delivering high drug concentrations directly to the ocular surface, yet challenges remain with this delivery system. Most notably, rapid clearance through the nasolacrimal duct, dilution through the production of reflex tearing, and protein binding are all concerns with topical ophthalmic delivery of antibiotic medications.<sup>14,15</sup> Furthermore, the azithromycin molecule is extremely lipophilic, making a stable aqueous formulation of the drug historically difficult to manufacture. However, when coupled with the DuraSite drug delivery vehicle (which contains polycarbophil), azithromycin can form a stable aqueous formulation, thus enhancing its stability and bioavailability on the ocular surface. When azithromycin is delivered via DuraSite, it binds to the mucin-coated surfaces of the eye (including the palpebral conjunctiva), resulting in the formation of a sustained-release gel that prolongs the release and availability of the drug on the ocular surface and enhances the penetration of the drug into the eyelids, conjunctiva, and cornea,<sup>16,17</sup> thus increasing its potential as a treatment for blepharitis.

This review discusses the antibiotic and anti-inflammatory properties of this broad-spectrum macrolide antibiotic, as well as off-label studies of the drug in the DuraSite delivery vehicle for the treatment of blepharitis.

## Development of ophthalmic azithromycin

Broad-spectrum antibacterial coverage continues to be a challenge while developing new antibiotics for ophthalmic anti-infective therapy.<sup>18</sup> With increasing resistance to fluoroquinolones,<sup>19,20</sup> there is a need to have a wide variety of antibiotics of different classes and mechanisms of action available to treat infections.

Azithromycin is a well-known, broad-spectrum macrolide antibiotic that has been available in oral form in the United States since 1992. Prior to the introduction of AzaSite, the only commercially available macrolide antibiotic for ophthalmic use was erythromycin. Structurally, azithromycin contains nitrogen in its macrolide ring, whereas erythromycin contains a methyl group, which may explain azithromycin's broader antibiotic spectrum and improved potency against

gram-negative microorganisms.<sup>21,22</sup> Consequently, it was an excellent candidate for development into an ophthalmic formulation. Azithromycin demonstrates potency against gram-positive, gram-negative, atypical bacteria, and chlamydia. Azithromycin's antibiotic properties are due to the inhibition of bacterial protein synthesis by its binding to the 50S ribosomal subunit of susceptible microorganisms. Furthermore, its pharmacokinetic properties lend themselves to once- or twice-daily dosing, which may be beneficial for patient compliance.<sup>18</sup>

Unlike most macrolides, azithromycin is distinguished by its high tissue distribution and prolonged elimination half-life.<sup>17</sup> Animal studies confirmed that, when reconstituted from its dry form, aqueous formulations of azithromycin had higher tissue concentration levels than that of clarithromycin.<sup>23</sup> A single topical dose in healthy individuals found azithromycin to achieve significant tissue concentrations and maintain those levels for up to 24 hours.<sup>24</sup>

## Ophthalmic uses of azithromycin

In ophthalmology, oral azithromycin has been used to treat trachoma and adult inclusion conjunctivitis. In 2007, the topical formulation of the drug was approved for ophthalmic use in the United States for the treatment of bacterial conjunctivitis caused by susceptible isolates of CDC coryneform group G, *Haemophilus influenzae*, *Staphylococcus aureus*, *Streptococcus mitis* group, and *Streptococcus pneumoniae*.<sup>25</sup> In phase 3 studies, azithromycin in an ophthalmic formulation was shown to have a wide spectrum of coverage, as well as increased tissue penetration and persistence when compared with other common antibiotics<sup>18</sup> (Table 1). When compared with tobramycin for the treatment of bacterial conjunctivitis, azithromycin was shown to have equivalent outcomes with fewer doses.<sup>26</sup> Furthermore, the results of these phase 3 trials are similar to those for other commonly used topical antibiotics including fluoroquinolones.<sup>19,27–29</sup> AzaSite was also recommended by the Centers for Disease Control and

**Table 1** Bacterial eradication rates with azithromycin 1% in DuraSite

Organism	Bacterial eradication, %	Clinical resolution, %
<i>Staphylococcus aureus</i>	82.4	70.6
<i>Staphylococcus epidermidis</i>	75	100
<i>Streptococcus mitis</i> group	100	100
<i>Streptococcus pneumoniae</i>	87.3	85.5
<i>Haemophilus influenzae</i>	93	89.5

**Note:** Evaluations occurred on day 6.

Adapted from Friedlander and Protzko 2007.<sup>18</sup>

Prevention as the treatment of choice for neonatal prophylaxis of chlamydia during the recent shortage of erythromycin ointment in the United States.

## Anti-inflammatory properties

Through almost 2 decades of study, while azithromycin was available for the treatment of systemic infections, it was discovered that macrolide antibiotics such as azithromycin exhibit anti-inflammatory properties. Studies have demonstrated that they can inhibit the production of proinflammatory cytokines<sup>30</sup> and the production of matrix metalloproteinases (MMPs).<sup>30</sup> Although the specific anti-inflammatory mechanism of action remains unknown, the suppression of the nuclear transcription factor nuclear factor kappa B (NF- $\kappa$ B) has been shown to play a role.<sup>12,30–32</sup>

Furthermore, the concentration of macrolide antibiotics such as azithromycin within polymorphonuclear leukocytes (PMNs) may also modulate their role in infection-mediated inflammation.<sup>30</sup> Research has shown that systemically administered azithromycin acts as both an immunomodulator and an anti-infective in patients with chronic respiratory diseases.<sup>30–32</sup>

With respect to ocular inflammatory diseases, an *in vitro* study found azithromycin in DuraSite as effective in suppressing MMPs in the corneal epithelium and endothelium as doxycycline (a tetracycline analog with known anti-inflammatory properties) in both human and bovine cells.<sup>12</sup> However, the clinical significance of this effect *in vivo* is unknown. MMPs have been implicated several ocular surface diseases, including blepharitis. Zymosan, a fungal toll-like receptor-2 ligand that stimulates production of inflammatory mediators in corneal epithelial cells, has been shown to be inhibited by treatment with azithromycin, suggesting another anti-inflammatory mechanism of action for azithromycin in ocular tissue.<sup>33</sup> Macrophage and dendritic cell infiltration into the cornea has also been mitigated by topical azithromycin use in a mouse study of keratitis.<sup>34</sup>

## Limitations of current therapy for blepharitis

Although blepharitis is a common ocular disorder, there is no consensus on standard management. Since anterior blepharitis is commonly associated with an infectious condition on the lid margin, typically gram positive in nature, treatment options usually include antibiotic ointments such as bacitracin and erythromycin, as well as lid hygiene with warm compresses and commercial lid scrubs.

The treatment of posterior blepharitis involves therapy to relieve inflammation on the lid margin, kill pathogenic bacteria, unclog the meibomian glands, and restore the normal character of the meibomian gland secretions. The classic approach involves (1) warm compresses and lid massage to open and unclog the meibomian glands, (2) antibiotic ointments for any infectious component, and (3) oral tetracyclines for their anti-inflammatory effect on the meibomian glands, their ability to improve the quality of the meibomian secretions over time, and their antimicrobial effect.

Topical corticosteroids are often used to treat severe symptoms in patients with lid margin disease, whether they suffer from anterior or posterior disease. However, although topical corticosteroids may provide immediate relief, they do not treat the underlying pathophysiology of the condition, and should only be used for the short term, due to the risk of steroid-related complications.

Unfortunately, classical therapy described earlier often falls short due to the chronic nature of the disease and the need to maintain chronic therapy in many patients, as well as the side effects of the treatment regimen itself. Patients often report that antibiotic ointments are difficult to apply and blur their vision. Furthermore, oral tetracycline compounds are often poorly tolerated due to systemic side effects of gastrointestinal upset, sun sensitivity, or yeast infections in women and require weeks to become effective. Finally, only few patients are compliant with warm compresses or lid scrubs after a few weeks, despite the fact that chronic therapy with these measures is often required to maintain control of the condition.

Accordingly, the classical treatment measures for blepharitis are often inadequate, and there continues to be a need for better treatment modalities. Several studies regarding novel treatments of blepharitis and those analyzing the efficacy of topical azithromycin in the DuraSite drug delivery vehicle are under way.

## Current azithromycin studies

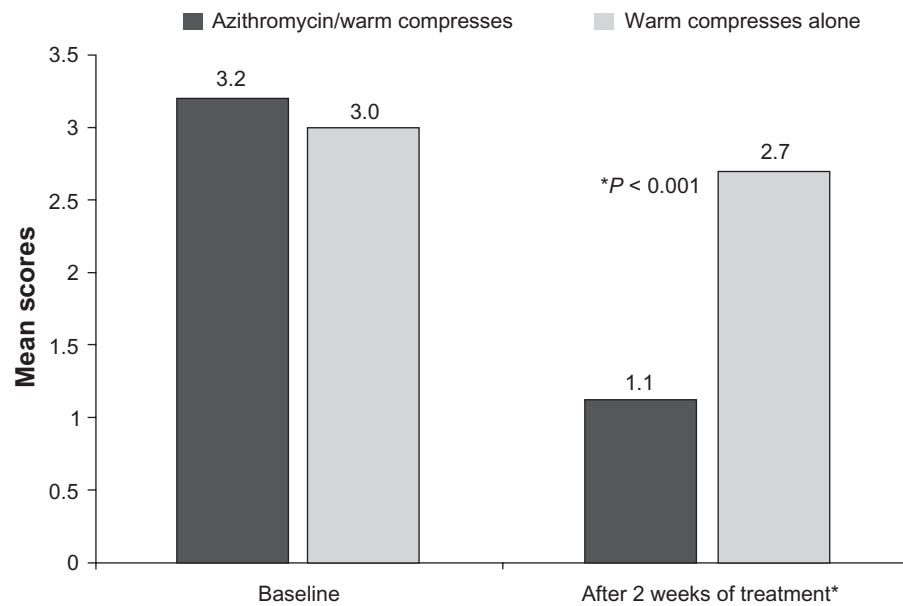
Azithromycin 1% in DuraSite (AzaSite) is the only FDA-approved topical formulation of azithromycin available and marketed in the United States. It is indicated for the treatment of bacterial conjunctivitis;<sup>25</sup> the studies reviewed in this section discuss off-label uses of the medication.

Several animal studies that have been performed concluded that, after topical administration of AzaSite, high concentrations of azithromycin can be demonstrated in ocular surface tissues. In one such study in which AzaSite was administered according to the FDA-indicated dosing regimen

for bacterial conjunctivitis (twice daily [BID] for 2 days followed by once daily [QD] for 5 days), peak concentrations of azithromycin more than 200  $\mu\text{g/g}$  of tissue were achieved in human eyelid tissue as the drug accumulated over the 7 days of therapy. Furthermore, 5 days after discontinuing the medication, tissue concentrations of azithromycin more than 50  $\mu\text{g/g}$  were still present in the eyelids.<sup>18</sup> Similar results were found for corneal and conjunctival samples in this study. In contrast, other studies have demonstrated that, when azithromycin in aqueous solution *without* DuraSite was administered topically, the concentrations of azithromycin in ocular surface tissues were negligible.<sup>17</sup> Taken together, these studies demonstrate that the combination of azithromycin and the DuraSite vehicle allows the drug to be absorbed into ocular surface tissues in high concentrations.

Another study was performed in humans who were scheduled to undergo cataract surgery and received AzaSite BID for 2 days then QD for an additional 5 days prior to surgery. Conjunctival biopsies were taken at the time of surgery to determine the concentration of azithromycin in the tissue. Similar to the animal studies, conjunctival concentrations of azithromycin more than 300  $\mu\text{g/mL}$  were found after 7 days of therapy, with levels persisting above 50  $\mu\text{g/g}$  for 5 days after stopping the drug.<sup>35</sup> These animal and human studies suggest that the drug penetrates into ocular surface tissues in high concentrations and persists in therapeutic concentrations for several days after therapy is discontinued.<sup>17,33</sup>

The high levels of azithromycin, which can be achieved in ocular surface tissues, particularly eyelids, after topical administration when combined with the DuraSite delivery vehicle, and the degree to which these levels persist after discontinuing the drug, distinguish azithromycin in DuraSite from other commonly used topical antibiotics such as fluoroquinolones. For example, another postmarketing study compared AzaSite 1% and moxifloxacin 0.5% (an ocular antibiotic commonly prescribed for the treatment of bacterial conjunctivitis) to determine the pharmacokinetic parameters of the drops after a single instillation into healthy human conjunctiva ( $N = 48$ ).<sup>24</sup> Azithromycin tissue concentrations peaked at 30 minutes after administration and remained high at therapeutic concentrations at 24 hours, whereas moxifloxacin concentrations peaked at 2 hours after administration and were undetectable at 24 hours, illustrating the differences in tissue absorption and clearance between topical azithromycin and fluoroquinolones.<sup>24</sup> Conversely, other studies have demonstrated that concentrations of moxifloxacin in the aqueous humor are significantly higher



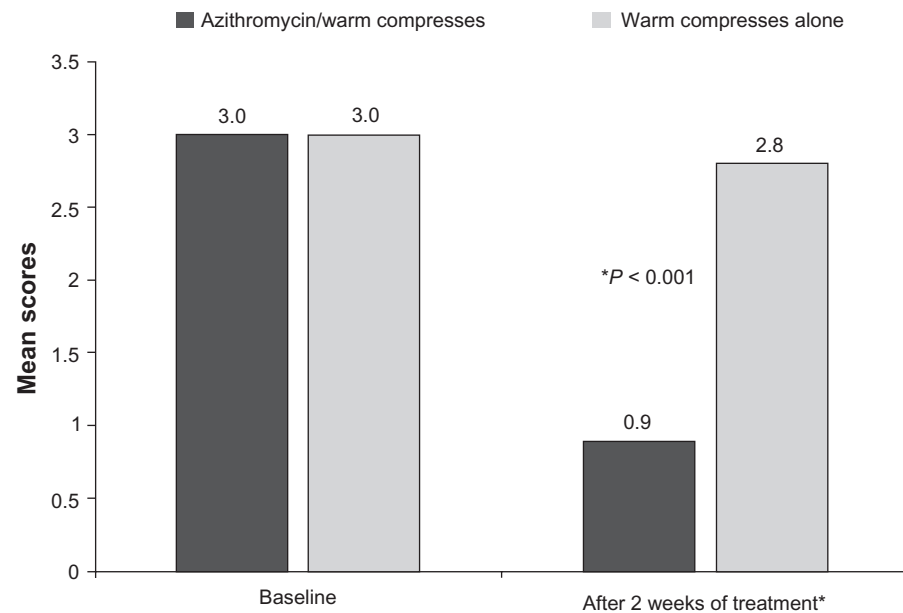
**Figure 1** Effects of topical azithromycin in combination with warm compresses, compared with warm compress-only group on lid redness.

**Note:** The clinical signs were rated by the investigator as 0 = normal, 1 = mild, 2 = moderate, 3 = severe, and 4 = very severe.

than those of azithromycin after topical administration.<sup>33</sup> These results suggest that azithromycin tends to partition primarily within tissue, rather than in aqueous solution, whereas fluoroquinolones such as moxifloxacin partition readily in aqueous solution.<sup>35</sup>

Since azithromycin has both antibacterial and anti-inflammatory properties that may make it a viable treatment option for chronic MGD, the author recently performed a 2-week study comparing the efficacy of topical azithromycin

1% in the DuraSite drug delivery vehicle (AzaSite) combined with warm compresses to warm compresses alone for the treatment of posterior blepharitis.<sup>36</sup> In this study (N = 21), 10 patients were randomized to the study drug and warm compresses; 11 received warm compresses alone. Patients in the azithromycin group showed a statistically significant improvement over baseline in the extent of lid margin redness ( $P < 0.001$ , Figure 1), meibomian gland plugging ( $P < 0.001$ , Figure 2), and quality of meibomian gland



**Figure 2** Effects of topical azithromycin in combination with warm compresses, compared with warm compress-only group on meibomian gland plugging.

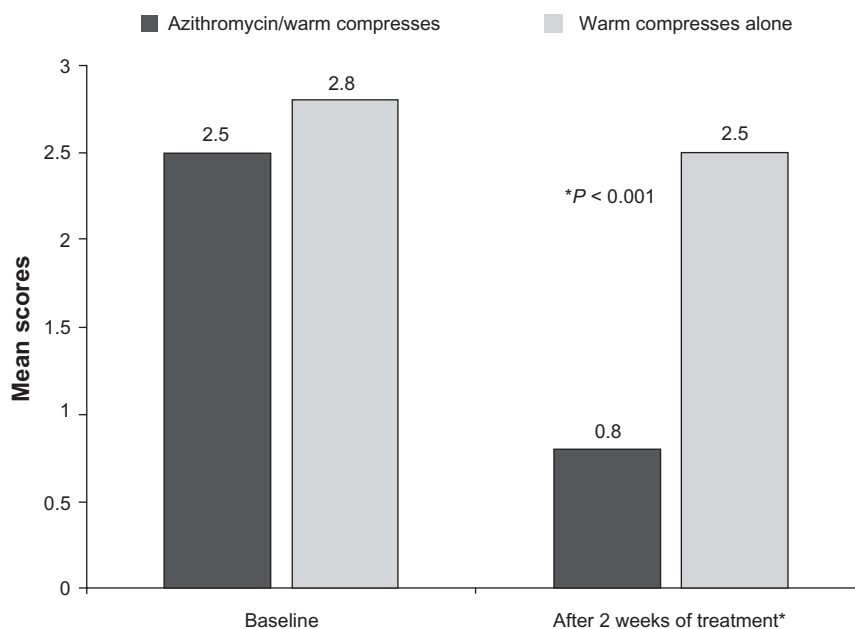
**Note:** The clinical signs were rated by the investigator as 0 = normal, 1 = mild, 2 = moderate, 3 = severe, and 4 = very severe.

secretions ( $P < 0.001$ , Figure 3); patients in the warm compress-only group did not show a statistically significant improvement in any of these parameters. Of interest, 44% of the patients in the azithromycin group showed complete resolution of their plugging in at least 1 eye compared to none in the compress-only group; almost a quarter of those in the azithromycin group also showed a normalization of the meibomian gland secretions after 2 weeks of therapy (none in the compress-only group had normalization). Further, there were only minor adverse events (vision blur and eye irritation) in the azithromycin group.

A second multicenter pilot study<sup>37</sup> enrolled 76 patients with moderate to severe blepharitis, randomized to warm compresses alone or warm compresses and topical 1% azithromycin, for a 4-week treatment period. At week 1, investigators rated the efficacy of azithromycin as excellent or good in 44% of patients in the azithromycin group, compared with only 15% in the compress-only group. This improved to 70% in the azithromycin group after 4 weeks of therapy, compared to 48% in the compress-only group. More importantly, the positive improvements achieved in the azithromycin group persisted as long as 2 weeks after therapy had concluded. Although the data did not reach statistical significance between the 2 groups, there was a trend toward improvement in the azithromycin group for eyelid swelling, quality of the meibomian gland secretions, and ocular pain or burning.

Another open-label study<sup>38,39</sup> of 26 patients with moderate to severe blepharitis evaluated changes in the signs and symptoms of anterior and posterior blepharitis after a 4-week course of treatment with topical azithromycin 1% in DuraSite (AzaSite). Patients were prohibited from using warm compresses in this study. Patient-rated symptom scores for itching, foreign body sensation, ocular dryness, ocular burning, and swollen eyelids were all statistically significantly improved from baseline levels after 4 weeks of therapy ( $P < 0.001$  for each symptom), and the improvement persisted for 4 weeks after stopping therapy. This supported the investigator-rated assessment of the clinical signs of blepharitis, which demonstrated statistically significant improvements in lid margin and conjunctival hyperemia, meibomian gland plugging, and ocular discharge after 4 weeks of therapy, which also persisted for 4 weeks after stopping therapy (last visit on day 57).

These studies suggest that topical azithromycin 1% in the DuraSite drug delivery vehicle may be effective as a standalone treatment for blepharitis as well as an adjunctive therapy with warm compresses; the studies demonstrate that topical azithromycin is more successful in treating the signs and symptoms of blepharitis than just mechanical therapy (warm compresses) alone. However, these studies are limited by their small size, open-label design, lack of a control arm, and potential bias due to the relationships of some of the investigators with the study sponsor.



**Figure 3** Effects of topical azithromycin in combination with warm compresses, compared with warm compress-only group on quality of meibomian gland secretion. **Note:** The clinical signs were rated by the investigator as 0 = normal, 1 = mild, 2 = moderate, 3 = severe, and 4 = obstructed.

Another study by Foulks et al<sup>40</sup> evaluated the physical properties of the meibomian secretions in patients with MGD. This study demonstrated that the phase transition temperature and lipid ordering of the meibomian secretions trended toward normal after once-daily dosing of topical azithromycin 1% in DuraSite for 4 weeks. These results correlate with the time course of the clinical improvements in the quality of the meibomian secretions noted in the aforementioned study and suggest that azithromycin may have a direct effect on the meibomian glands or their secretions. Further study is warranted in this area.

These pilot studies have led to the initiation of larger, prospective, multicenter studies of the effect of topical azithromycin 1% in the DuraSite drug delivery vehicle on blepharitis (clinicaltrials.gov NCT00894530 and NCT00892970). The 2 phase 2, randomized, double-masked, placebo-controlled studies of different lengths (2 and 4 weeks, respectively) have recently been completed and will evaluate both primary and secondary outcome measures in patients with blepharitis. In these studies, primary outcome measure is eyelid margin erythema and secondary outcomes include additional clinical signs and clinical symptoms of blepharitis.

Another study (clinicaltrials.gov NCT00803452) evaluates the effects of oral doxycycline, oral essential fatty acids, or topical azithromycin 1% in the DuraSite drug delivery vehicle in expressing meibomian gland secretions before and after treatment in subjects with MGD and/or dry eye disease. In this prospective study, doxycycline is dosed at 100 µg BID for 2 months, essential fatty acids are dosed at 1,000 µg/day for 2 months, and topical azithromycin 1% in the DuraSite drug delivery vehicle is dosed once daily for 1 month.

## Conclusions

The known antibacterial and anti-inflammatory aspects of topical azithromycin 1% in DuraSite and the promising results from early studies in subjects with chronic blepharitis (both anterior and posterior) are encouraging, although the results are limited by the study designs; further studies are warranted, and a randomized, prospective, placebo-controlled trial has recently been completed. In a chronic and common disease such as blepharitis that currently has no single approved treatment, is complicated in its management, and has wide-ranging signs and symptoms, treatments that rapidly improve both clinical and self-reported signs and symptoms are welcome.

## Acknowledgments and disclosures

The author is a consultant for Inspire Pharmaceuticals, Inc, but does not have any direct financial interests in the content of this review. Editorial assistance in the preparation of this review was provided by Michelle Dalton; support for this assistance was funded by Inspire Pharmaceuticals, Inc.

## References

1. American Optometric Association. Optometric clinical practice guideline: care of the patient with ocular surface disorders. 2002. Available from: <http://www.aoa.org/documents/CPG-10.pdf> Accessed Jan 14, 2010.
2. Jackson WB. Blepharitis: current strategies for diagnosis and management. *Can J Ophthalmol*. 2008;43(2):170–179.
3. Smith RE, Flowers CW. Chronic blepharitis: a review. *CLAO J*. 1995; 21(3):200–207.
4. Foulks GN, Bron AJ. Meibomian gland dysfunction: a clinical scheme for description, diagnosis, classification, and grading. *Ocul Surf*. 2003; 1:107–126.
5. American Academy of Ophthalmology. Preferred practice patterns: blepharitis. 2008. Available from: <http://one.aao.org/CE/PracticeGuidelines/PPP.aspx> Accessed Jan 20, 2010.
6. Lemp MA, Nichols KK. Blepharitis in the United States 2009: a survey-based perspective on prevalence and treatment. *Ocul Surf*. 2009;7 Suppl 2:S1–S14.
7. Campbell Alliance Group. Patterns of practice and prevalence rates for lid margin disease. 2008 July–Aug.
8. Venturino G, Bricola G, Bagnis A, Traverso CE. Chronic blepharitis: treatment patterns and prevalence. *Invest Ophthalmol Vis Sci*. 2003;44 [E-Abstract 774].
9. Hom MM, Martinson JR, Knapp LL, Paugh JR. Prevalence of meibomian gland dysfunction. *Optom Vis Sci*. 1990;67:710–712.
10. Macsai MS. The role of omega-3 dietary supplementation in blepharitis and meibomian gland dysfunction (an AOS thesis). *Trans Am Ophthalmol Soc*. 2008;106:336–356.
11. Scaglione F, Rossoni G. Comparative anti-inflammatory effects of roxithromycin, azithromycin, and clarithromycin. *J Antimicrob Chemother*. 1998;41 Suppl B:47–50.
12. Jacot JL, Jacot TA, Sheppard JD, et al. Evaluation of MMP 2/9 modulation by AzaSite and DuraSite in human corneal epithelial cells and bovine corneal endothelial cells in vitro. Ft. Lauderdale, FL: Association for Research in Vision and Ophthalmology; 2008 Apr 28.
13. Donaldson KE, Karp CL, Dunbar MT. Evaluation and treatment of children with ocular rosacea. *Cornea*. 2007;26(1):42–46.
14. Pecosky DA, Robinson JR. Bioadhesive polymers and drug delivery. In: Tarcha PJ, editor. *Polymers for Controlled Drug Delivery*. Boca Raton, FL: CRC Publications; 1991:100–122.
15. Lux A, Maier S, Dinslage S, et al. A comparative bioavailability study of three conventional eye drops versus a single lyophilisate. *Br J Ophthalmol*. 2003;87(4):436–440.
16. Protzko E, Bowman L, Abelson M, Shapiro A; for AzaSite Clinical Study Group. Phase 3 safety comparisons for 1.0% azithromycin in polymeric mucoadhesive eye drops versus 0.3% tobramycin eye drops for bacterial conjunctivitis. *Invest Ophthalmol Vis Sci*. 2007; 48(8):3425–3429.
17. Akpek EK, Vittitow J, Verhoeven RS, et al. Ocular surface distribution and pharmacokinetics of a novel ophthalmic 1% azithromycin formulation. *J Ocul Pharmacol Ther*. 2009;25(5):433–439.
18. Friedlander MH, Protzko E. Clinical development of 1% azithromycin in DuraSite, a topical azalide anti-infective for ocular surface therapy. *Clin Ophthalmol*. 2007;1(1):3–10.

19. Kowalski RP, Yatea KA, Romanowski EG, Karenchak LM, Mah FS, Gordon YJ. An ophthalmologist's guide to understanding antibiotic susceptibility and minimum inhibitory concentration data. *Ophthalmology*. 2005;112:1987–1991.
20. Park SH, Lim JA, Choi JS, Kim KA, Joo CK. The resistance patterns of normal ocular bacterial flora to 4 fluoroquinolone antibiotics. *Cornea*. 2009;28:68–72.
21. Retsema J, Girard A, Schelkly W, et al. Spectrum and mode of action of azithromycin (CP-62,993), a 15-membered-ring macrolide with improved potency against gram-negative organisms. *Antimicrob Agents Chemother*. 1987;31(12):1939–1947.
22. Pechere JC. Effect of the molecular structure of azithromycin on pharmacokinetics and the antimicrobial activity. *Pathol Biol (Paris)*. 1995;43(6):483–487.
23. Brown BA, Wallace RJ Jr, Onyi GO, de Rosas V, Wallace RJ III. Activities of four macrolides, including clarithromycin, against *Mycobacterium fortuitum*, *Mycobacterium chelonae*, and *M. chelonae*-like organisms. *Antimicrob Agents Chemother*. 1992;36(1):180–184.
24. Torkildsen G, O'Brien TP. Conjunctival tissue pharmacokinetic properties of topical azithromycin 1% and moxifloxacin 0.5% ophthalmic solutions: a single-dose, randomized, open-label, active-controlled trial in healthy adult volunteers. *Clin Ther*. 2008;30(11):2005–2014.
25. AzaSite [package insert]. Durham, NC: Inspire Pharmaceuticals; 2008.
26. Abelson M, Protzko E, Shapiro A, Graces-Soldana A, Bowman L; for the 1% azithromycin in DuraSite Clinical Study Group. A randomized trial assessing the clinical efficacy and microbial eradication of 1% azithromycin ophthalmic solution vs tobramycin in adult and pediatric subjects with bacterial conjunctivitis. *Clin Ophthalmol*. 2007;1(2):177–182.
27. Vigamox [package insert]. Fort Worth, TX: Alcon Laboratories, Inc; 2008.
28. Zymar [package insert]. Irvine, CA: Allergan, Inc; 2004.
29. Kowalski RP, Dhaliwal DK, Karenchak LM, et al. Gatifloxacin and moxifloxacin: an in vitro susceptibility comparison to levofloxacin, ciprofloxacin, and ofloxacin using bacterial keratitis isolates. *Am J Ophthalmol*. 2003;136:500–505.
30. Ianaro A, Ialenti A, Maffia P, et al. Anti-inflammatory activity of macrolide antibiotics. *J Pharmacol Exper Ther*. 2000;292(1):156–163.
31. Amsden GW. Anti-inflammatory effects of macrolides – an underappreciated benefit in the treatment of community-acquired respiratory tract infections and chronic inflammatory pulmonary conditions? Review. *J Antimicrob Chemother*. 2005;55:10–21. Epub 2004 Dec 8.
32. Shinkai M, Rubin BK. Macrolides and airway inflammation in children. Review. *Paediatr Respir Rev*. 2005;6:227–235.
33. Zhou N, Ma P, Li D-Q, Pflugfelder SC. Azithromycin suppresses pro-inflammatory mediators stimulated by a TLR2 ligand zymosan in human corneal epithelial cells. Ft. Lauderdale, FL: Association for Research in Vision and Ophthalmology; 2009 May 3–7.
34. Sadrai Z, Hajrasouliha AR, Chauhan SK, Saban DR, Dastjerdi MH, Dana R. Effect of topical azithromycin on innate immune responses in experimental keratitis. Ft. Lauderdale, FL: Association for Research in Vision and Ophthalmology; 2009 May 3–7.
35. Stewart WC, Crean CS, Zink RC, Haque R, Hwang DG. Pharmacokinetics of azithromycin and moxifloxacin in human conjunctiva and aqueous humor during and after the approved dosing regimens. Ft. Lauderdale, FL: Association for Research in Vision and Ophthalmology; 2009 May 3–7.
36. Luchs J. Efficacy of topical azithromycin ophthalmic solution 1% in the treatment of posterior blepharitis. *Adv Ther*. 2008;25(9):858–870.
37. Trattler WB, Kuhn KL, Haque R, Zink RC, Sall KN, Luchs J. Topical azithromycin improves blepharitis signs and symptoms. San Francisco, CA: American Society of Cataract and Refractive Surgery; 2009 Apr 3–8.
38. Touhey D, Shapiro A, Torkildsen G, et al. Efficacy of topical azithromycin ophthalmic solution 1% in the treatment of chronic blepharitis patients. Ft. Lauderdale, FL: Association for Research in Vision and Ophthalmology; 2009 May 3–7.
39. Haque RM, Torkildsen GL, Brubaker K, et al. Multi-center, open-label study evaluating the efficacy of azithromycin ophthalmic solution 1% on the signs and symptoms of subjects with blepharitis. *Cornea*. In press.
40. Foulks GN, Borchman D, Yappert M. Modification of meibomian gland lipids by topical azithromycin. Ft. Lauderdale, FL: Association for Research in Vision and Ophthalmology; 2009 May 3–7.

## Clinical Ophthalmology

### Publish your work in this journal

Clinical Ophthalmology is an international, peer-reviewed journal covering all subspecialties within ophthalmology. Key topics include: Optometry; Visual science; Pharmacology and drug therapy in eye diseases; Basic Sciences; Primary and Secondary eye care; Patient Safety and Quality of Care Improvements. This journal is indexed on

Submit your manuscript here: <http://www.dovepress.com/clinical-ophthalmology-journal>

Dovepress

PubMed Central and CAS, and is the official journal of The Society of Clinical Ophthalmology (SCO). The manuscript management system is completely online and includes a very quick and fair peer-review system, which is all easy to use. Visit <http://www.dovepress.com/testimonials.php> to read real quotes from published authors.