

# Histological appearance of postmortem pink teeth: Report of two cases

Charan Gowda BK,  
Sivapathasundharam B,  
Ananjan Chatterji,  
Laxmidevi BL

Department of Oral Pathology,  
Sri Siddhartha Dental College,  
Tumkur, Karnataka, India

**Address for correspondence:**

Dr. Charan Gowda BK,  
Department of Oral Pathology,  
Sri Siddhartha Dental College,  
Agalkote, Tumkur - 572 107,  
Karnataka, India.  
E-mail: cherrybkgowda@yahoo.  
co.in

**Abstract**

This article presents images and histological changes in the dentin of two cases involving postmortem pink teeth. Postmortem pink teeth were noted among two deceased male individuals. Pink teeth were noted during autopsy examination after twelve days in one corpse, and eight days following death in the second case. During the examination decomposition and putrefaction of the body was noted. Cause of death was drowning in one case and haemorrhages and shock in another. A central incisor tooth was obtained from each body. Both teeth exhibited a pink appearance and the intensity was more pronounced in the cervical region. Although pink teeth can be noted in death due to asphyxia, carbon monoxide poisoning and so on, it is necessary to study the exact role behind the appearance of pink teeth and try to incorporate the finding medico legally.

**Key words:** Drowning, hemoglobin, porphyrins, postmortem pink teeth

**Introduction**

Identification based on dental information is a highly efficient, reliable, and rapid procedure.<sup>[1,2]</sup> Knowledge in rugoscopy,<sup>[3,4]</sup> chelioscopy,<sup>[5,6]</sup> bite marks,<sup>[7,8]</sup> radiographs,<sup>[9,10]</sup> tooth DNA analysis<sup>[11-13]</sup> and so on, plays an important role in medico legal investigation. However, still many questions in the field of Forensic Odontology remain unanswered.<sup>[3,14]</sup> One feature is postmortem pink teeth. Further studies are required to conclude the manner of death by looking into postmortem pink tooth. The appearance of postmortem pink teeth is a common phenomenon that can be noted by the forensic personnel during exhumation.<sup>[14]</sup> Usually the pink appearance is more pronounced at the region of the cemento-enamel junction<sup>[3,14,15]</sup> and more intense among the anterior teeth than the posterior teeth.<sup>[3]</sup> Bell, in 1829, was the first person to describe pink teeth in a postmortem victim.

He noted the appearance of pink teeth in the individuals where the cause of death was drowning. Since then, there have not been many reports published in the literature regarding postmortem pink teeth<sup>[14]</sup> In 1953, Miles *et al.*, described the appearance of postmortem pink teeth in two individuals where the cause of death was drowning and burns.<sup>[15,16]</sup> Van Wyk,<sup>[17]</sup> in 1989, also observed pink teeth where the cause of death was drowning, fire, and stabbing. Kirkham *et al.*,<sup>[18]</sup> observed pink teeth during postmortem and mentioned that many cases were associated with decomposition in a moist environment.


Reviewing the literature reveals that the exact cause for the appearance of forensic pink teeth as well as the phenomenon behind its occurrence is still clearly not understood.<sup>[14,16,17,19]</sup> However, trauma and moist environment may play a role in its appearance. We present two cases of pink teeth in exhumed bodies.

The main aim of our study was to note the changes to pink teeth, histologically.

**Case Reports**

**Case 1**

A male individual aged 28 years was found dead. The medical investigator reported that death had occurred

Access this article online	
<b>Website:</b> www.jfds.org	<b>Quick Response Code</b> 
<b>DOI:</b> 10.4103/0975-1475.156200	

12 days earlier. The cause of death was registered as drowning. One maxillary central incisor [Figure 1] was obtained from the deceased individual's body.

### Case 2

A male individual aged 45 years was found dead. The medical investigator reported that death had occurred eight days earlier. Death was due to hemorrhage and shock. A maxillary central incisor tooth [Figure 2] was obtained from the deceased individual's body.

Both samples were obtained following oral consent from the medical officer and police investigator.

One tooth was subjected to ground section and the other to decalcification.

The ground section revealed red-brown discoloration of the dentin [Figures 3 and 4], whereas, the hematoxylin and eosin (H and E)-stained section does not show any notable changes [Figure 5].

### Discussion

Postmortem pink teeth phenomenon is a condition that may be noted among deceased individuals due to the development of intrapulpal pressure. Various factors including physical trauma and a moist environment play a major role in the development of the pink appearance.<sup>[14,16-18]</sup> In forensic literature, authors who reported cases of pink teeth, note the time delay between death and development of pink appearance.<sup>[16,18]</sup> They attribute the cause of discoloration to red blood cells entering the dentin.<sup>[18]</sup> However, as red blood cells are 7.5 microns in diameter and dentinal tubules are only 3 micrometers in diameter, it is the lysis of erythrocytes and the products of erythrocytes like hemoglobin, porphyrins, and hemosiderins, together with bile and related pigments that are responsible for the pink appearance. The literature mentions the variation in the intensity among different teeth and also the regions of the teeth. The appearance of pink teeth can be noted among incisors, canines, and premolars. Within the

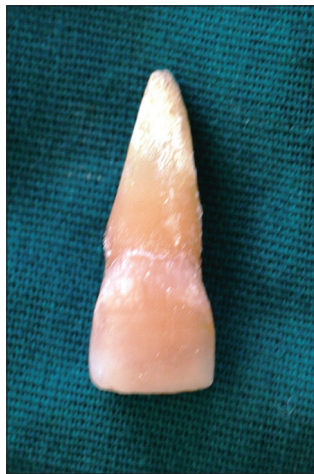

Figure 1: Pink appearance along the cervical region of the tooth

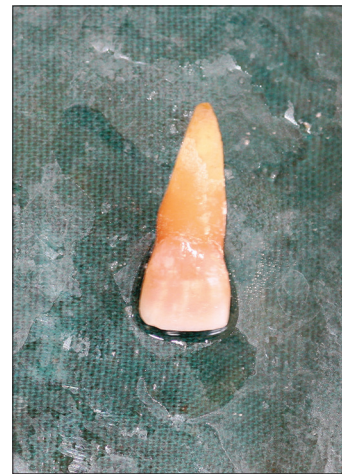

Figure 2: Pink appearance along the cervical region of the tooth




Figure 3: Ground section of teeth showing dentin

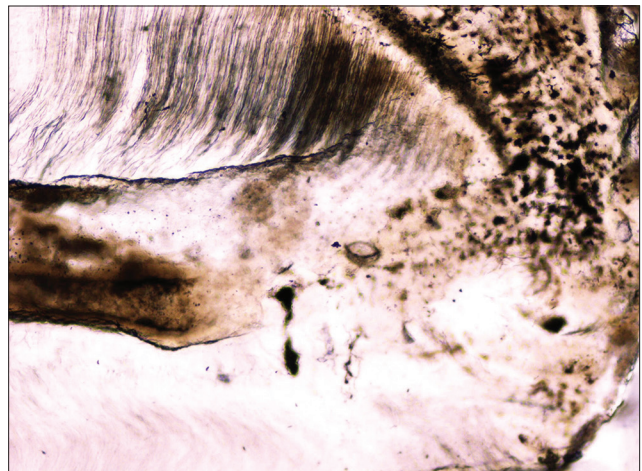
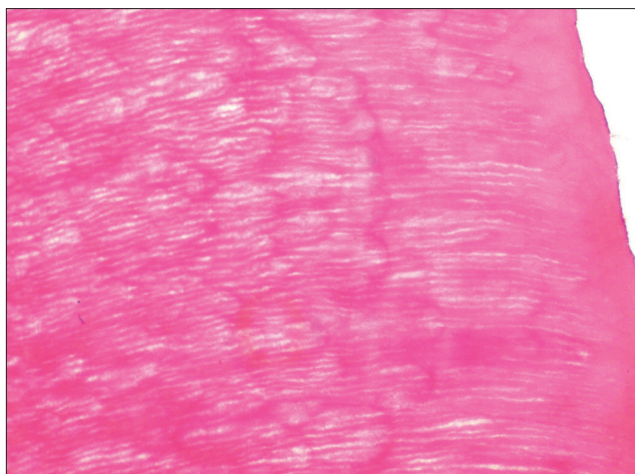


Figure 4: Ground section of teeth showing pulp



**Figure 5:** H and E-stained section of decalcified tooth

tooth, the root exhibits more intense discoloration than in the coronal region.<sup>[17,18]</sup>

In our case, we noted a similar variation in the color intensity from region to region. We noted more intense discoloration along the cervical region compared to the incisal region. Van Wyk, in 1989, studied the ground sections of postmortem pink teeth and noted the red–brown discoloration of dentin. Similar to the study by Van Wyk, the ground section of pink teeth in our case showed red –brown discoloration in the dentin but not in enamel and cementum.

We conclude that the pink appearance is due to the derivative products of hemoglobin entering the dentinal tubules.

## Conclusion

Pink teeth phenomenon may be noted in dead individuals, where great physical trauma is noted. Moist environment also plays a role as a triggering factor. However, the exact cause of the coloration remains unexplained. Large scale studies are needed to ascertain the exact cause for the appearance of the pink color and the variation in the intensity of the hue.

## Acknowledgment

Dr. Rudramurthy, Head, Department of Forensic Medicine and Residential Medical Officer, Government Hospital, Tumkur.

## References

1. Kolude B, Adeyemi BF, Taiwo JO, Sigbeku OF, Eze UO. The role of forensic dentist following mass disaster. *Ann Ibadan Postgrad Med* 2010;8:111-8.
2. Valenzuela A, Martin-de lasHeras S, Marques T, Exposito N, Bohoyo JM. The application of dental methods of identification to human burn victims in a mass disaster. *Int J Legal Med* 2000;113:236-9.
3. Borrman H, DuChesne A, Brinkmann B. Medico-legal aspects of postmortem pink teeth. *Int J Legal Med* 1994;106:225-31.
4. Mohammed RB, Patil RG, Pammi VR, Sandya MP, KalyanSV, Anitha A. Rugoscopy: Human identification by computer-assisted photographic superimposition technique. *J Forensic Dent Sci* 2013;5:90-5.
5. Barbieri AA, Scoralick RA, Naressi SC, Moraes ME, Daruge E Jr, Daruge E. The evidence of the rugoscopy effectiveness as a human identification method in patients submitted to rapid palatal expansion. *J Forensic Sci* 2013;58(Suppl 1);S235-8.
6. Venkatesh R, David MP. Cheiloscopy: An aid for personal identification. *J Forensic Dent Sci* 2011;3:67-70.
7. Malik R, Goel S. Chelioscopy: A deterministic aid for forensic sex determination. *J Indian Acad Oral Med Radiol* 2011;23:17-9.
8. Wright FD, Dailey JC. Human bite marks in forensic dentistry. *Dent Clin North Am* 2001;45:365-97.
9. Kotb NA, El Attar HS, Soliman AS. Some medicolegal aspects of odontology (case reports). 2013;31(Suppl 1);65.
10. Kvall SI, Kolltveit KM, Thomsen IO, Solheim T. Age estimation of adults from dental radiographs. *Forensic Sci Int* 1995;74:175-85.
11. Nomir O, Abdel-Mottaleb M. A system for human identification from X-ray dental radiographs. *Pattern Recognit* 2005;38:1295-305.
12. Ginther C, Issel-Tarver L, King MC. Identifying individuals by sequencing mitochondrial DNA from teeth. *Nat Genet* 1992;2:135-8.
13. Smith BC, Fisher DL, Weedn VW, Warnock GR, Holland MM. A systematic approach to the sampling of dental DNA. *J Forensic Sci* 1993;38:1194-209.
14. Soriano EP, Carvalho MV, Santos FB, Mendoza CC, Araújo MD, Campello RI. The post-mortem pink teeth phenomenon: A case report. *Med Oral Patol Oral Cir Bucal* 2009;14:E337-9.
15. Fish; Glasgow University Dental Hospital and School; Matriculation number: 0105883.
16. Dye TJ, Lucy D, Pollard AM. The occurrence and implications of post-mortem 'pink teeth' in forensic and archaeological cases. *Int J Osteoarchaeol* 1995;5:339-48.
17. Van Wyk CW. Postmortem pink teeth: *In vitro* production. *J Oral Pathol* 1988;17:568-72.
18. Kirkham WR, Andrews EE, Snow CC, Grape PM, Snyder L. Postmortem pink teeth. *J Forensic Sci* 1977;22:119-31.
19. Sainio P, Syrjänen S, Keijälä JP, Parviainen AP. Postmortem pink teeth phenomenon: An experimental study and a survey of the literature. *Proc Finn Dent Soc* 1990;86:29-35.

**How to cite this article:** Charan Gowda BK, Sivapathasundharam B, Chatterji A, Chatterji BL. Histological appearance of postmortem pink teeth: Report of two cases. *J Forensic Dent Sci* 2015;7:168-70.

**Source of Support:** Nil, **Conflict of Interest:** None declared