



Contents lists available at ScienceDirect

International Journal of Surgery Case Reports

journal homepage: www.casereports.com

Triorchidism; an incidental finding at inguinal hernia repair: A case report

Badhaasaa B. Bayissa^{a,*}, Dhugasa Tesfaye^b

^a Haramaya University, College of Health and Medical Sciences, Department of Surgery, Ethiopia

^b Oromia Regional Health Bureau, Shambo General Hospital, Ethiopia

ARTICLE INFO

Article history:

Received 15 November 2020

Received in revised form

22 November 2020

Accepted 22 November 2020

Available online 25 November 2020

Keywords:

Polyorchidism

Inguinal hernia

Undescended testis

ABSTRACT

INTRODUCTION: Polyorchidism is a rare congenital malformation with about 200 cases reported in literatures. Triorchidism and left side occurrence are the most common presentation. This case report was aimed to report the rare presentation of polyorchidism which was on the right side and along with incarcerated inguinal that make it by far the least encountered presentation. The intraoperative management for the polyorchidism was an issue of dilemma but adult type can be excised safely.

PRESENTATION OF THE CASE: A 43 year old farmer presented with right side inguino-scrotal mass and recent failure to reduce to abdomen. He used to have pain lower abdominal pain with slight pressure since childhood but didn't get any medical evaluation. He has completed his family number and didn't complain any sexual problem. Physical examination showed that there was non-tender irreducible soft right side inguino-scrotal mass. The right side testis was not appreciated.

DISCUSSION: Triorchidism is one of the commonly occurring variant of supernumerary testes that diagnosed incidentally during investigations or interventions for other pathologies. Incarcerated inguinal hernia masks its detection on physical examinations, so its diagnosis is more of intraoperative making a one time management for both pathologies at single operation especially if the operation undertake with general anesthesia. This patient was operated for incarcerated inguinal hernia with incidental finding of right side type B1 polyorchidism. Both of the right side testes were atrophic and excision was done.

CONCLUSION: Patients who present at a late adulthood age with polyorchidism and undescended testis can be successfully treated with surgical removal of the atrophic supernumerary testes.

© 2020 The Author(s). Published by Elsevier Ltd on behalf of IJS Publishing Group Ltd. This is an open access article under the CC BY-NC-ND license (<http://creativecommons.org/licenses/by-nc-nd/4.0/>).

1. Introduction

Polyorchidism is a rare anomaly of the genitourinary tract which refers to the presence of more than two testes. Nearly 200 cases were reported in literatures [1,2]. Triorchidism is the most common presentation and the left side is predominantly affected [2,3]. The common pathologies associated with polyorchidism are maldescent (40%), hernia (30%), torsion (15%), hydrocele (9%), and malignancy (6%) [3].

The classification by Bergholz et al.; based on anatomy; is a useful and more appropriate classification to use for supernumerary testes. A testis being drained by an outflow path (vas deferens) was coded as type A, whereas undrained testes without connection to a draining vas deferens were coded as type B. Type A testes were further divided into 4 subgroups. A1: Supernumerary testis has its own epididymis and vas deferens, A2: Supernumerary testis has its own epididymis but common vas deferens with neighboring testis, A3: Supernumerary testis has its common epididymis and vas def-

erens with neighboring testis, and A4: Supernumerary testis has its own vas deferens but common epididymis with neighboring testis. Type B testes were further divided into 2 subgroups. B1: Supernumerary testis has its own epididymis and B2: Supernumerary testis lacks an epididymis, thus consisting of testicular tissue only [4].

There is no consensus in the literature regarding the management of polyorchidism, especially in cases where the supernumerary testes found incidentally are one of a surgical dilemma. Some authors have suggested orchiectomy of the supernumerary testes in adults because of 4%–7% risk of malignancy [3]. This case report was encountered during routine scheduled operation at a primary level community hospital where experts from different Universities work as an outreach center.

2. Presentation of the case

A 43 years old farmer presented to Shambo general hospital with the chief complaint of irreducibility of inguino-scrotal mass for the last one week of presentation. The mass was there for three years which used to disappear on lying position or with manual compression. It was associated with discomfort and he has also later, after the operation, described slight touch around right groin area used

* Corresponding author.

E-mail address: badhok@gmail.com (B.B. Bayissa).

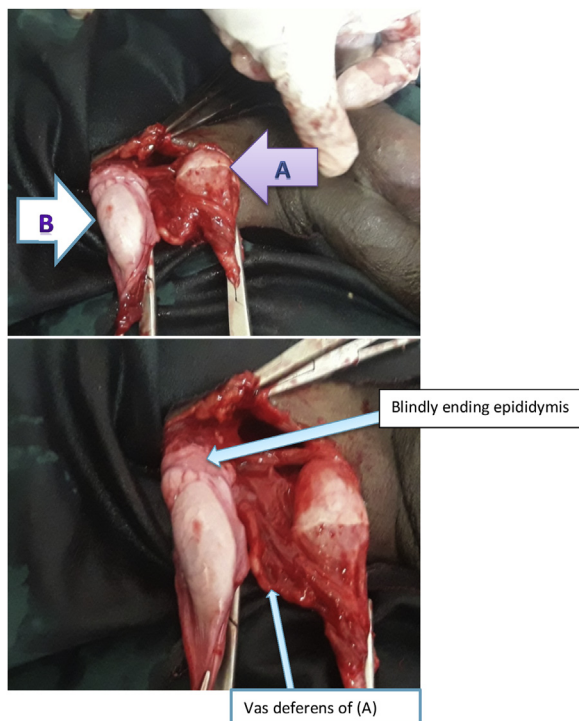


Fig. 1. Intraoperative finding of right side supernumerary testes (A the one at external inguinal ring with its complete cord structure and B blindly ending epididymis found at internal inguinal ring).

to induce brief sharp pain since his childhood. He has no history of abdominal surgery, has no history of trauma to his abdomen. There was no family history of similar illness. Otherwise, he denied any groin mass since childhood. He has five children; three son and two daughters and he did not complain any problem with his sexual life.

Up on abdominal examination, there was irreducible non tender right side inguinal mass which descends down to the scrotum. It has positive cough impulse and bowel sound was audible over the mass. Right testis was not well appreciated otherwise the left testis was well developed and in the scrotum. With the impression of right side incarcerated indirect inguinal hernia, the patient was prepared, fasted overnight, and on the next day morning he was given spinal anesthesia. Through inguinal incision the hernia sac was exposed. The findings were incarcerated loop of ileum with thickened neck of the hernia sac. There was atrophied testis with clearly visible vas deferens at the level of external inguinal ring (A). The supernumerary testis was found at internal inguinal ring (B) within well-developed tunica vaginalis and epididymis but no vas deferens. According to Bergholz classification, this variant is type B2 [4] (Fig. 1). What was done was, considering the age of the patient and his fertility status, he was informed the incidental findings and consented for removal. The cord structure was ligated at the internal ring and both of the atrophic testes were removed. Herniorrhaphy with Modified Bassini technique was performed. Skin closed with interrupted suture and patient discharge without any eventful condition on his third day. He has been followed at surgical referral clinic of the hospital, at 6 and 12 months, post-operatively with smooth course. The pain was disappeared and his sexual performance was not affected.

SCARE checklist was used to organize this case report [5].

3. Discussion

Supernumerary testes are rare developmental malformation where the number of testis become more than two. It is generally incidental finding while investigating patients for associated

pathologies or during interventions [6]. The diagnosis can be confirmed using ultrasonography (US) and magnetic resonance imaging (MRI) even though according to Duymus et al., US only can suffice [7]. A meta-analysis done by Robert Bergholz and Katharina Wenke showed 140 cases of polyorchidism were confirmed using histopathology [8]. In our case the diagnosis was intraoperative and investigations were not performed for confirmation. The supernumerary testis commonly occur on the left side and most of the extra testes are atrophic [4,9]. Unlike the majority, our case was presented having the pathology on the right side with both testes being atrophied. The other extra testis that has no vasa deferens was found upon pulling down the hernia sac at internal inguinal ring during high ligation. This finding was in agreement with report of John K. Burgers and John P. Gearhart about intra-abdominal type of polyorchidism [6].

Concerning the management of polyorchidism, there is no consensus but taking in consideration of the fertility status of patients and future risk of development of testicular malignancies, most of the reports removed the supernumerary testis [3,10]. Our patient has completed his family number. So after explaining the future risk of malignancy, both of the atrophic testes were removed. On follow up at 6 months and 1 year, the patient has no newly developed problem and the previous symptoms were vanished.

4. Conclusion

The management of polyorchidism, which most of the cases found incidentally, should be individualized. When patients present with associated complications especially at late adulthood age surgical removal of the atrophic testis doesn't cause any morbidity on short term follow up. The future risk of testicular malignancy from the atrophic testes will be prevented.

Declaration of competing interest

There is no conflict of interest.

Funding

None.

Ethical approval

Ethical approval was obtained from institutional health ethics management committee of Shambo hospital. With ref N. ORHB/sh118/2020.

Consent

Written informed consent was obtained from the patient for publication of this case report and accompanying images. A copy of the written consent is available for review by the Editor-in-Chief of this journal on request.

Author's contribution

BB a consultant, who performed the surgery, presented the case history, researched the topic and helped draft the manuscript. DhT assisted the surgery, obtained consent for publication and edited the manuscript. Both authors read and approved the final manuscript.

Registration of research studies

Not applicable.

Guarantor

Dr Badhaasaa Beyene (corresponding author).

Provenance and peer review

Not commissioned, externally peer-reviewed.

Acknowledgements

We want to address our sincere appreciation to the operation theatre staffs of Shambo General hospital for their passionate care for our patient.

References

- [1] S. Yalçınkaya, C. Şahin, A.F. Şahin, Polyorchidism: sonographic and magnetic resonance imaging findings, *Can. Urol. Assoc. J.* 5 (5) (2011) E84.
- [2] B. Sheah, H. Teh, O. Peh, Supernumerary testicle in a case of polyorchidism, *Ann. Acad. Med. Singap* 33 (2004) 368–370.
- [3] A. Bayraktar, et al., Management of polyorchidism: surgery or conservative management? *J. Hum. Reprod. Sci.* 3 (3) (2010) 162.
- [4] R. Bergholz, et al., Polyorchidism: a case report and classification, *J. Pediatr. Surg.* 42 (11) (2007) 1933–1935.
- [5] R.A. Agha, et al., The SCARE 2018 statement: updating consensus Surgical CAse REport (SCARE) guidelines, *Int. J. Surg.* 60 (2018) 132–136.
- [6] J.K. Burgers, J.P. Gearhart, Abdominal polyorchidism: an unusual variant, *J. Urol.* 140 (3) (1988) 582–583.
- [7] M. Duymuş, et al., A rare case of polyorchidism: four testes, *Pol. J. Radiol.* 81 (2016) 39.
- [8] R. Bergholz, K. Wenke, Polyorchidism: a meta-analysis, *J. Urol.* 182 (5) (2009) 2422–2427.
- [9] J.B. Amodio, et al., Polyorchidism: report of 3 cases and review of the literature, *J. Ultrasound Med.* 23 (7) (2004) 951–957.
- [10] M. Savas, et al., Polyorchidism: a three-case report and review of the literature, *Andrologia* 42 (1) (2010) 57–61.

Open Access

This article is published Open Access at [sciencedirect.com](https://www.sciencedirect.com). It is distributed under the [IJSCR Supplemental terms and conditions](#), which permits unrestricted non commercial use, distribution, and reproduction in any medium, provided the original authors and source are credited.