

# Use of the SIGN IM nail system to stabilize tibiototalcalcaneal arthrodesis in two African hospital settings

Sydney E. Burke, BBA, MPH<sup>a</sup>, Isaac K. Wangai, MD<sup>b</sup>, Geoffrey K. Koech, MD<sup>b</sup>, Jeremiah D. Galat<sup>c</sup>, Daniel D. Galat, MD<sup>d</sup>, Douglas W. Lundy, MD, MBA<sup>e</sup>

## Abstract

**Objectives:** To determine the effectiveness and describe the technique of using the Surgical Implant Generation Network (SIGN) nail to augment tibiototalcalcaneal (TTC) arthrodesis in the developing world.

**Design:** Retrospective review of the SIGN database and description of surgical technique.

**Setting:** Two centers in rural Kenya, East Africa.

**Patients:** Fifty-seven patients with ankle/hindfoot arthritis or severe trauma. We were able to follow 17 through complete arthrodesis.

**Invention:** TTC arthrodesis stabilized with SIGN nail.

**Main outcome measure:** Radiographic arthrodesis and return to function.

**Result:** Of the patients with significant follow-up, arthrodesis occurred in an average of  $19.3 \pm 7.5$  weeks from the date of surgery.

**Conclusions:** Recognizing the obstacles to follow-up, the SIGN nail placed with the Herzog curve apex posterior is shown to be an effective device to stabilize a TTC arthrodesis in a limited subgroup of patients with full follow-up.

**Keywords:** ankle arthritis, SIGN nail, tibiototalcalcaneal arthrodesis

## 1. Introduction

In the developing world, injured patients often endure severe hardship due to the sequela of posttraumatic arthritis and nonunion of distal tibial and talar fractures. These austere conditions pose significant challenges for treating surgeons in these countries due to the lack of available resources. Specifically in rural Africa, road traffic accidents are increasing at an alarming rate. According to World Health Organization's 2015 Global Status Report on Road Safety, the road traffic fatality rate in Africa is 26.6 per 100,000

population; the highest among WHO regions.<sup>[1]</sup> In 2013, low and middle-income countries accounted for 92% of the global road traffic deaths in the world.<sup>[2]</sup> In the African region, road traffic accidents account for 7.2 million disability adjusted life years, and the impact of these hardships can be catastrophic to patients and their families.<sup>[3]</sup> In many countries, salvage treatment for these patients is limited to amputation and arthrodesis. TTC arthrodesis is a surgical procedure used to treat patients with pain and deformity in the ankle and hindfoot. Indications for this procedure include osteoarthritis, avascular necrosis of the talus, failed ankle arthroplasty, rheumatoid arthritis, Charcot arthropathy, neuromuscular diseases, and posttraumatic deformities of the ankle and leg.<sup>[4]</sup> Rarely indicated as a primary treatment, this procedure may be the only option left to patients facing below-knee amputation to relieve their pain and disability.

The Surgical Implant Generation Network intramedullary (SIGN IM) nail system was designed for use in resource-poor hospitals that lack access to power equipment and fluoroscopy. The SIGN IM nail was created by Lewis Zirkle, MD (manufactured and distributed in Richland, Washington), and was designed to stabilize tibial, femoral, and humeral fractures.<sup>[5]</sup> Since 1999, the SIGN IM nail has been used in the treatment of more than 214,000 patients in 50 developing countries. This system is often the main implant used to treat patients with long bone fractures in the developing world, and it has been deployed in many nations that have suffered natural disasters.<sup>[6,7]</sup> Two of our authors (DG and GKK) have adopted the SIGN IM nail system for instrumenting tibiototalcalcaneal arthrodesis procedures.

Our hypothesis was that the SIGN intramedullary nail system is a safe and efficacious stabilization option for TTC arthrodesis for complex ankle deformities and arthritis in resource-poor areas. The purpose of our study was to determine outcomes after

Source of funding: Nil.

There was no funding received for this study.

The authors have no conflicts of interest to disclose.

The IRB was obtained at Kijabe Hospital in Kijabe, Kenya.

<sup>a</sup> Emory University Rollins School of Public Health, <sup>b</sup> Tenwek Hospital, Bomet, Kenya, <sup>c</sup> Arizona State University, Tempe, Arizona, <sup>d</sup> Kijabe Hospital, Kijabe, Kenya, <sup>e</sup> Resurgens Orthopaedics, Atlanta, Georgia.

\* Corresponding author. Address: Resurgens Orthopaedics, 61 Whitcher Street, Suite 1100, Marietta Georgia 30060. E-mail address: lundydw@resurgens.com (D. W. Lundy).

Copyright © 2020 The Authors. Published by Wolters Kluwer Health, Inc. on behalf of the Orthopaedic Trauma Association.

This is an open access article distributed under the terms of the Creative Commons Attribution-Non Commercial-No Derivatives License 4.0 (CCBY-NC-ND), where it is permissible to download and share the work provided it is properly cited. The work cannot be changed in any way or used commercially without permission from the journal.

OTA (2020) e088

Received: 7 June 2018 / Received in final form: 14 May 2020 / Accepted: 29 May 2020

Published online 26 October 2020

<https://dx.doi.org/10.1097/OI9.000000000000088>

using the SIGN IM nail system to stabilize tibiototalcaneal arthrodesis in patients presenting at 2 SIGN program hospitals in rural East Africa and to describe the surgical technique to perform this procedure.

## 2. Materials and methods

### 2.1. Study setting

This study is a retrospective review of the SIGN database of tibiototalcaneal arthrodesis performed with the SIGN IM nail system at Tenwek and Kijabe hospitals in Kenya, East Africa. This investigation using patient data for research purposes was approved by the IRB committee at Kijabe hospital, Kenya, and informed consent was obtained as required. Tenwek Hospital is a 300-bed hospital in Bomet, Kenya that has a high volume of trauma cases. Tenwek is a training site for general surgery and orthopaedic surgery residents. Kijabe Hospital is a 320-bed facility in Kijabe, Kenya specializing in more elective orthopaedic procedures. Kijabe is also a training site for general surgery and orthopaedic surgery residents as well as hosting a pediatric orthopaedic surgery fellowship program. Both hospitals offer fluoroscopy that was used for the placement of the SIGN nails included in this study, though the SIGN nail was designed to be placed without fluoroscopy. This technique can certainly be performed without fluoroscopy, but expertise in SIGN technique should be a prerequisite.

### 2.2. Study design

The SIGN database is a web-based platform used worldwide. Surgeons using SIGN nails are required to upload surgical information and radiographs for patients who are treated with this device into the SIGN database. The SIGN database was accessed to collect demographic and surgical data on patients who underwent tibiototalcaneal arthrodesis procedures at Tenwek and Kijabe Hospitals. Data collected included patient age, time to consult and surgery, indications, follow-up information, and implant placement. Injury and/or disease type were also recorded based on preoperative radiographic images. Follow-up and time to radiographic arthrodesis was determined from clinical and radiographic information.

### 2.3. Technique

To effectively plan the surgical approach, the extremity is carefully examined to assess the quality of the soft tissue envelope, neurovascular status, and presence of deformity. Radiographs are reviewed to determine the need for potential osteotomies and estimate the size of the SIGN nail. Anteroposterior lateral and mortise views of the ankle are obtained and standing views are preferred, when possible. The diameter of the SIGN nail is highly dependent on implant availability, though the most commonly used nail is 10 mm.

After induction of general or regional anesthesia, the patient is placed in the supine position on a radiolucent table. Bumps should be positioned under the ipsilateral buttock to internally rotate the affected lower extremity, and additional bumps are also placed under the extremity to facilitate fluoroscopic imaging. A tourniquet is routinely used around the mid-thigh, inflated to 300 mm Hg.

A transfibular approach to the ankle joint is commonly employed since patients requiring TTC arthrodesis often have significant hindfoot deformities. A longitudinal incision is made laterally over the fibula, extending from approximately 5 cm

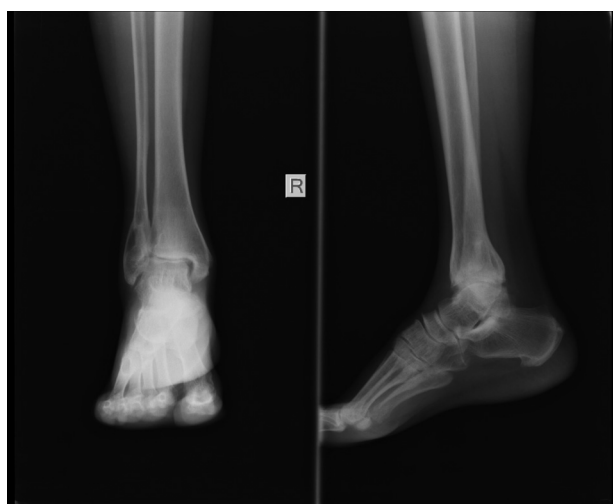
superior to the tip of the lateral malleolus curving slightly anteriorly toward the sinus tarsi. Under fluoroscopic guidance, a lateral malleolar osteotomy is performed in a beveled fashion at the level of tibial plafond to allow access to the lateral ankle to prepare the arthrodesis site. The excised lateral malleolar fragment is preserved to be used later as bone graft.

In cases of significant valgus deformity resulting from bimalleolar ankle fracture malunion, a second incision can be made medially, maintaining at least a 5 cm anterior skin bridge. This longitudinal incision starts in the supramalleolar region and extends approximately 2 cm distal to the tip of the medial malleolus. The medial malleolar fragment is removed and also preserved for bone graft. Autologous graft placed in both the medial and lateral malleolar sites is preferred as patients in this setting will tolerate minimal limb length discrepancies if the chances for primary arthrodesis without revision surgery are maximized. If the fibula or medial malleolus was removed, then it was typically used as bone graft. If not, iliac crest could be used but this was very rare. Surgical dissection along the anterior surface of the distal tibia—deep to neurovascular structures and extensor tendons—connects the medial and lateral incisions allowing excellent access to the entire tibiotalar joint surface. Osteotomies may be performed through either incision as needed to correct deformity. Preparation of the joint surfaces is performed to remove all articular cartilage while preserving subchondral bone stock. The subtalar joint surfaces may also be prepared as necessary, but this is typically not performed at our institutions.

Fluoroscopic guidance is used to select the starting point of the TTC nail on the plantar surface of the calcaneus. A 2-cm incision is made slightly laterally in the heel pad in line with the posterior facet of the calcaneus on the lateral fluoroscopic view. This is the same incision that we use for insertion of the nail and is on the plantar aspect of the foot about one-third of the way from the heel to the forefoot. On the lateral fluoroscopic image, it is directly under the posterior facet in line with the anatomic axis of the tibia. The plantar fascia is split and blunt dissection is performed to the plantar surface of the calcaneus. While maintaining the hindfoot in a neutral and slightly valgus position, a 3.5 mm drill bit is used to drill in a retrograde fashion through the calcaneus into the talus and tibial medullary canal. While drilling, care is taken to maintain collinearity of the calcaneus, talus, and intramedullary canal of the tibia on anteroposterior and lateral fluoroscopic views.

While continuing to hold the hindfoot in neutral and slightly valgus alignment, a series of progressively larger reamers—starting at 7 mm and increasing in 1 mm increments—is used to enlarge the tibiototalcaneal canal until chatter is felt in the tibia diaphysis. The subtalar joint was not specifically prepared to promote subtalar arthrodesis. A SIGN nail that is 1 to 2 mm smaller in diameter than the last reamer used is then selected. The length of the nail should be long enough to extend proximally beyond the tibial isthmus into the metaphyseal region of the proximal tibia in order to minimize potential stress risers.

The nail and target arm are then assembled on the back table in a standard fashion for SIGN nailing. The Herzog curve may be placed in either the apex posterior or anterior position, depending on the desired effect. An apex posterior position of the nail tends to produce more dorsiflexion of the ankle, thus assisting with placing the hindfoot in a neutral, plantigrade position (Figs. 1 and 2). Additionally, the nail and target arm should be assembled such that the nail is locked from lateral to medial so that the medial neurovascular structures inferior to the sustentaculum talus are not injured. The nail is then inserted in retrograde



**Figure 1.** Anteroposterior and lateral radiographs of a young man affected by posttraumatic arthritis of the ankle. Radiographs demonstrate decreased joint space, articular sclerosis, and osteophytes.

fashion into the calcaneal entry point through the talus and into the intramedullary canal of the tibia. Under lateral fluoroscopic view, the nail is impacted to a point just flush with the inferior calcaneal surface and then adjusted as necessary such that typically one distal interlock screw will engage the calcaneus and the other will engage the talus. Care should be taken so that the interlocking screws do not violate the subtalar joint.

After the insertion of the nail, sagittal and coronal alignment of the foot is set, but small adjustments of external rotation can be made. The 2 interlocking screws are placed into the calcaneus and talus from lateral to medial and the L-handle gently impacted with a mallet to compress the prepared tibiotalar surface. At this point, a single interlocking screw is placed into the proximal aspect of the nail, usually though the hole nearer to the arthrodesis. The interlocking screw is placed into a static locking

hole. Although the interlocking screws in this study were always placed using fluoroscopic guidance, the standard interlocking guides in the SIGN set may be used to place the proximal screw when fluoroscopic imaging is unavailable.

Compression of the arthrodesis site is ensured prior to locking. At this point, the tourniquet is released and irrigation using normal saline is performed. The lateral and medial malleolar pieces are prepared and packed as bone graft around the fusion site. Layered closure of the wounds is performed in standard fashion using meticulous soft tissue handling techniques. If a large dead space remains secondary to the removal of the lateral malleolus segment, a drain or cotton bolster may be used. Sterile dressings and a Robert Jones plaster splint are applied (Figs. 3–5).

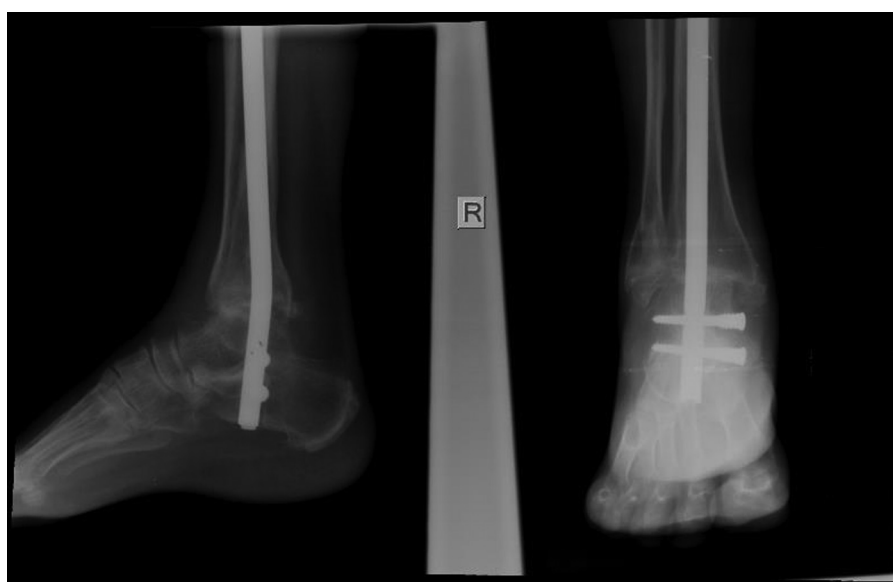Postoperatively, the patient is instructed to strictly elevate the foot. The splint is typically changed on the second postoperative day. We schedule follow-up in clinic 2 weeks after surgery for removal of skin sutures, and the patient is then placed in a below knee plaster cast. Patients will typically remain nonweight bearing for 6 weeks after surgery, and then begin progressive weight bearing in either a walking cast or CAM walker boot until fully weight bearing and with evidence of bony union.

The above technique describes use of fluoroscopic imaging during the surgical procedure. However, this procedure can be performed without imaging by using direct visualization and clinical alignment as guides during reaming and insertion of the nail.

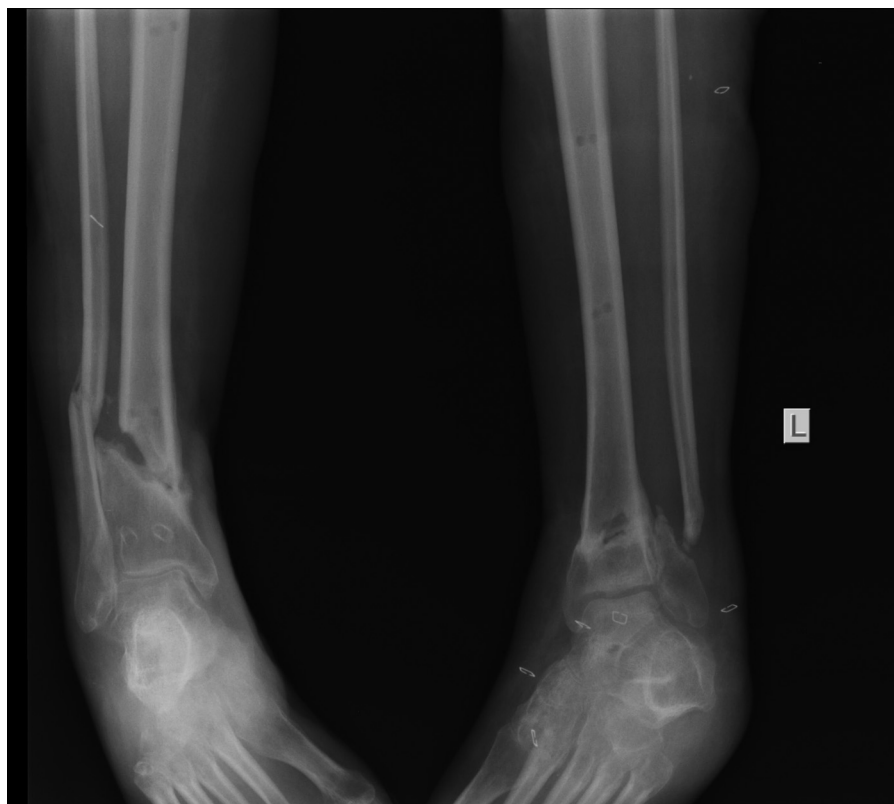
### 3. Results

#### 3.1. Study demographics

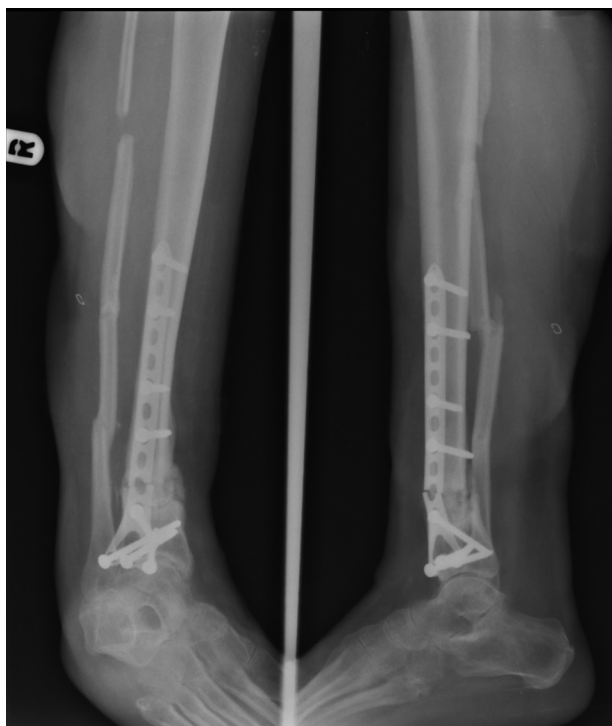Fifty-seven patients who underwent tibiototalcalcaneal arthrodesis under the supervision of one of the senior authors (DG, GKK) were identified. Twenty-two patients were female (39%) and 35 patients (61%) were male. The average age of patients was  $44.3 \pm 14.3$  years (range, 19–76). Twenty-five patients (44%) presented with injuries on the left side and 32 patients (56%) presented with



**Figure 2.** Anteroposterior and lateral radiographs of same patient after hindfoot arthrodesis using the SIGN nail. Note the apex posterior position of the Herzog curve assists in maintaining the ankle in neutral position. Since this patient had posttraumatic arthritis, the fibula was left intact, and the arthrodesis was prepared through the anteromedial approach.



**Figure 3.** Anteroposterior radiographs of a young man with bilateral distal tibial nonunions. The left tibia is relatively well aligned, but the right tibial nonunion is in varus and has no evidence of healing.



**Figure 4.** After attempted open reduction and internal fixation and bone grafting, anteroposterior and lateral radiographs demonstrate continued nonunion and fracture of the hardware. In this situation, the arthrodesis was prepared through the anteromedial approach.

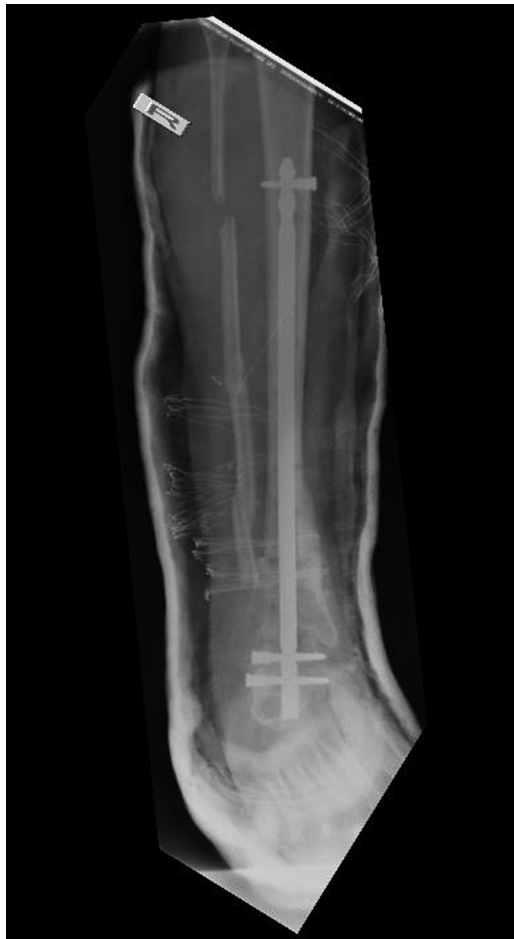right-sided injuries. Indications for the procedure are detailed in Table 1.

### 3.2. Follow-up and union of the arthrodesis

Follow-up is a well-known obstacle to performing clinical studies in the developing world, and the cost of postoperative care proves prohibitive for many patients.<sup>[8]</sup> Twenty-eight of our patients (49.1%) returned for at least 1 follow-up visit, with average follow-up length of  $155 \pm 122$  days (range, 19–607 days). Seventeen patients (29.8%) had sufficient follow-up to determine final arthrodesis. Arthrodesis was documented in these patients in an average of  $19.3 \pm 7.5$  weeks after surgery (range, 8.7–40.3 weeks). Due to constraints in follow-up, the precise time to union is unknown. Forty-nine patients (86%) were stabilized with the SIGN nail placed with the Herzog curve placed in the apex posterior position. In the 17 patients who were able to be followed up to union, no failures, infections, deformities, amputations, or revision surgeries were identified.

## 4. Discussion

In the United States, tibiototalcalcaneal arthrodesis is regarded as a salvage procedure to achieve a pain-free and functional extremity.<sup>[9]</sup> A study performed by Budnar et al<sup>[9]</sup> reported successful results with clinical and radiographic union in 89% of patients who underwent TTC arthrodesis. Eighty-two percent of the patients in their study reported decreased pain and 73% of patients reported improvement in the function of their foot. At follow-up, two-thirds of patients were no longer using analgesics



**Figure 5.** AP radiograph after hindfoot arthrodesis using the SIGN nail.

for ankle pain.<sup>[9]</sup> In a systematic review of TTC arthrodesis using an IM nail, Franceschi et al<sup>[4]</sup> found that the limb salvage rate was 90%.

Clinical studies in the developing world have unique characteristics compared to more economically advanced nations. Access to care can be very challenging in these locales, and many of these patients present with advanced and chronically untreated disease. Long-term follow-up is often irregularly accomplished due to the cost-prohibitive nature of medical care in these resource limited settings.<sup>[8]</sup> Because of difficulties in follow-up and compliance, no patient-reported outcome measures were able to be obtained in our study. The high cost of medical care causes patients to delay seeking treatment and allows disease to progress to an advanced stage before seeking evaluation.

The surgical technique utilized in this study did not include simultaneous arthrodesis of the ipsilateral subtalar joint. Associated subtalar arthritis may well be found in combination with these injury patterns; however, the attending surgeons in this study do not typically address this during these procedures. Anecdotally, these patients did well without subtalar arthrodesis, and the inherent immobilization of the joint due to the hindfoot nail may be adequate to decrease associated subtalar pain. Surgeons should consider arthrodesis of both joints in patients presenting with clear signs of ankle and subtalar arthritis.

Limitations of our study include poor follow-up and lack of objective patient-centric outcome measures. Despite the wide-

**Table 1**

**Indications of surgical procedure in study population**

Indication	Number of patients (%)
Ankle fracture	
With fibulectomy	1 (1.8%)
With posttraumatic arthritis	17 (29.8%)
Dislocated	1 (1.8%)
Without secondary indication	9 (15.8%)
Plafond fracture	
Without secondary indication	4 (7%)
Talar neck fracture	
With avascular necrosis	3 (5.3%)
Dislocated	1 (1.8%)
Without secondary indication	1 (1.8%)
Tibial nonunion	
With lengthening over nail	2 (3.5%)
With lengthening over nail and posttraumatic arthritis	1 (1.8%)
Without secondary indication	3 (5.3%)
Ankle arthritis	
Posttraumatic	4 (7%)
Septic	1 (1.8%)
Posttraumatic and subtalar joint	1 (1.8%)
Without secondary indication	3 (5.3%)
Other indications	
Syndesmotic injury with posttraumatic arthritis	2 (3.5%)
Nonunion of ankle arthrodesis	1 (1.8%)
Avascular necrosis of talus with posttraumatic arthritis	1 (1.8%)
Adult acquired planovalgus	1 (1.8%)

spread availability of cellular service in both locations, requests for patient follow-up information were ineffective. An additional limitation is the retrospective nature of our study.

Of the 57 patients in our study, 49 (86%) were stabilized with the nail placed with the Herzog curve in the apex-posterior position. We found that patients treated with the nail placed in the apex-anterior position tended to struggle with the arthrodesis in a more plantar-flexed position. When the nail was placed with the curve in the apex-posterior position, the surgeons were able to achieve optimal alignment in a far more consistent manner.

In the limited follow-up that we were able to achieve, our study demonstrates that patients with complex foot and ankle pathology can be safely and successfully treated with tibiotalo-calcaneal arthrodesis stabilized with the SIGN IM nail, placed with the Herzog curve apex posterior, in resource-poor areas of the developing world. The SIGN IM nail system was specifically designed to be effective in resource-poor settings similar to our study locations. When tasked with treating complications and deformities resulting from complex ankle fractures in the developing world, the SIGN IM nail system is an effective method of stabilizing patients through solid arthrodesis.

## References

1. World Health Organization Global Status Report on Road Safety 2015. Geneva: World Health Organization; 2015.
2. World Health Organization Global Status Report on Road Safety 2013; supporting a decade of action. Geneva: World Health Organization; 2013.
3. Mathers C, Fat DM, Boerma JT. World Health Organization The Global Burden of Disease: 2004 Update. Geneva: World Health Organization; 2008.
4. Franceschi F, Franceschetti E, Torre G, et al. Tibiotalo-calcaneal arthrodesis using an intramedullary nail: a systematic review. *Knee Surg Sports Traumatol Arthrosc.* 2016;24:1316–1325.

5. What SIGN does. (n.d.). Available at: <https://signfracturecare.org/about/what-sign-does/>. Accessed April 8, 2018.
6. About SIGN's founder. (n.d.). Available at: <https://signfracturecare.org/about/about-sign-founder/>. Accessed April 24, 2018.
7. SIGN fracture care international. (n.d.). Available at: <https://signfracturecare.org/>. Accessed April 24, 2018.
8. Shearer D, Cunningham B, Zirkle L. Population characteristics and clinical outcomes from the SIGN online surgical database. *Tech Orthop*. 2009;24:273–276.
9. Budnar VM, Hepple S, Harries WG, et al. Tibiototalcalcaneal arthrodesis with a curved, interlocking, intramedullary nail. *Foot Ankle Int*. 2010; 31:1085–1092.