

Case Report

# Effects of deep brain stimulation on vocal fold immobility in Parkinson's disease

Elsa V. Arocho-Quinones<sup>1,2</sup>, Michael J. Hammer<sup>3</sup>, Jonathan M. Bock<sup>4</sup>, Peter A. Pahapill<sup>1,2</sup>

<sup>1</sup>Department of Neurosurgery, U.S. Department of Veterans Affairs Medical Center, Milwaukee, <sup>2</sup>Department of Neurosurgery, Medical College of Wisconsin, Milwaukee, <sup>3</sup>Department of Surgery/Division of Otolaryngology, University of Wisconsin, Madison, <sup>4</sup>Department of Otolaryngology and Communication Science, Medical College of Wisconsin, Milwaukee, Wisconsin, USA

E-mail: \*Elsa V. Arocho-Quinones - [earocho@mcw.edu](mailto:earocho@mcw.edu); Michael J. Hammer - [hammer@surgery.wisc.edu](mailto:hammer@surgery.wisc.edu); Jonathan M. Bock - [jbock@mcw.edu](mailto:jbock@mcw.edu); Peter A. Pahapill - [ppahapill@mcw.edu](mailto:ppahapill@mcw.edu)

\*Corresponding author

Received: 26 August 16    Accepted: 13 December 16    Published: 20 February 17

## Abstract

**Background:** Vocal fold (VF) immobility is a rare, potentially fatal complication of advanced Parkinson's disease (PD). Previous reports suggest that subthalamic nucleus deep brain stimulation (STN-DBS) may influence laryngeal function, yet the role of STN-DBS on VF immobility remains unexplored.

**Case Description:** We report a case of a patient with advanced PD and bilateral VF immobility ultimately requiring a tracheostomy. To assess the effects of STN-DBS on vocal cord function and to correlate these effects with peripheral motor symptoms at different stimulation settings, the patient was evaluated before and after initiation of bilateral STN-DBS. Measures included direct observation of VF mobility via transnasal laryngoscopy, levodopa equivalent dose of anti-PD medication, and motor scores. High frequency (150 Hz) STN-DBS resulted in improved motor scores, reduced medication requirement, and modestly improved right VF abduction although insufficient for safe decannulation. Low frequency (60 Hz) stimulation resulted in lower motor scores, but without worsening VF abduction.

**Conclusions:** STN-DBS may play an important role in the neuromodulation of PD-induced laryngeal dysfunction, including VF mobility. Characterization of these axial symptoms is important when programming and evaluating responsiveness to DBS.

**Key Words:** DBS, laryngeal dysfunction, Parkinson's disease, STN, vocal fold immobility

**Access this article online**

**Website:**

[www.surgicalneurologyint.com](http://www.surgicalneurologyint.com)

**DOI:**

10.4103/2152-7806.200580

**Quick Response Code:**



## INTRODUCTION

The role of laryngeal dysfunction in the development of speech disorders in Parkinson's disease (PD) is well recognized.<sup>[1,5,6]</sup> Reports of respiratory stridor and vocal fold (VF) immobility in PD are rare but raise important clinical concerns regarding patient care.<sup>[4,10,12,14,20,21,23]</sup> The potential effects of DBS on VF immobility remain unknown. We report a case of a PD patient with stridor

This is an open access article distributed under the terms of the Creative Commons Attribution-NonCommercial-ShareAlike 3.0 License, which allows others to remix, tweak, and build upon the work non-commercially, as long as the author is credited and the new creations are licensed under the identical terms.

**For reprints contact:** [reprints@medknow.com](mailto:reprints@medknow.com)

**How to cite this article:** Arocho-Quinones EV, Hammer MJ, Bock JM, Pahapill PA. Effects of deep brain stimulation on vocal fold immobility in Parkinson's disease. *Surg Neurol Int* 2017;8:22.

<http://surgicalneurologyint.com/Effects-of-deep-brain-stimulation-on-vocal-fold-immobility-in-Parkinson's-disease/>

secondary to bilateral VF immobility ultimately requiring a tracheostomy. We assessed the effects of STN-DBS on VF mobility and motor symptoms. Our findings raise important questions regarding the role of DBS on peripheral as well as axial motor symptoms.

## CASE REPORT

The patient was a 51-year-old male with progressive idiopathic PD. He was diagnosed with PD at age 41 and his symptoms began with left- greater than right-sided tremor that progressed to grade 2/4. He developed bradykinesia, rigidity, dyskinesias, and balance problems. He experienced speech difficulties which responded to medication and reported a 9-month history of noisy breathing that worsened after the discontinuation of his PD medications. He also reported reflux and mild dysphagia. Medications included amantadine, carbidopa/levodopa, rasagiline, and ropinirole.

### Deep brain stimulation surgery

With the goal of improving his limb symptoms, the patient underwent implantation of subthalamic nucleus deep brain stimulation (STN-DBS) electrodes (Medtronic, model 3389) during separate awake procedures using microelectrode recording, microstimulation, and macrostimulation. The first electrode was placed in the right-STN, and the second in the left-STN 1 month later [Figure 1]. Ten days later, a dual-chamber subclavicular pulse generator was implanted under general endotracheal anesthesia.

### Pulmonary evaluation

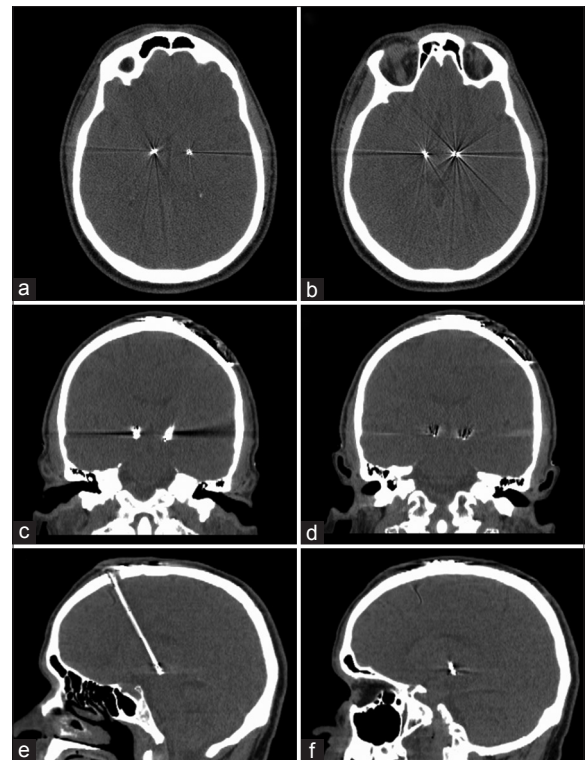
After an uneventful placement of the right-STN electrode and prior to the placement of the left-STN electrode, the patient was referred to a pulmonologist for evaluation of possible obstructive airway disease. Pulmonary function testing revealed mild air trapping, mildly reduced diffusion capacity, and increased airway resistance. Inhaled bronchodilators did not improve these symptoms. Therefore, upper airway obstruction was suspected, and he was referred to Otolaryngology.

### Otolaryngology evaluation

Upper airway evaluation via transnasal laryngoscopy revealed bilateral VF immobility with VFs at the paramedian position [Figure 2]. Computed tomography (CT) scan of the neck revealed no evidence of mass or lymphadenopathy. Given the breathing risk with severe bilateral VF immobility, a tracheostomy was placed under general anesthesia on the same day as the subclavicular pulse generator. Three weeks later, the patient returned to the clinic for initial programming of his STN-DBS system.

### Outcomes with subthalamic nucleus deep brain stimulation

Following initiation of bilateral STN-DBS, the patient was evaluated at several intervals during a period of 11 months [Table 1; Figure 2]. Outcome measures



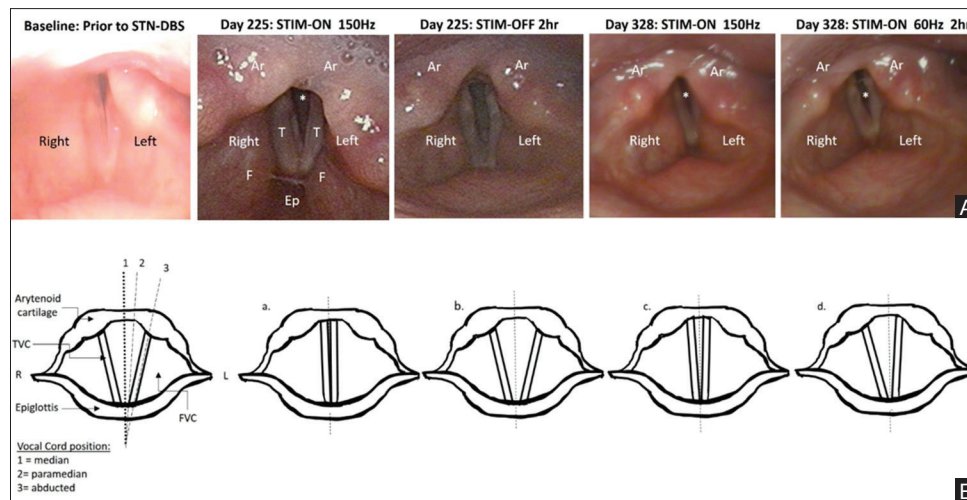
**Figure 1: Computed tomography (CT) post STN-DBS electrode placement. (a) Axial view at the level of the most proximal (top) electrode contacts. (b) Axial view at level of most distal (bottom) electrode contacts. (c) Coronal view at level of most proximal electrode contact. (d) Coronal view at level of most distal contact. (e) Sagittal view showing right STN electrode. (f) Sagittal view showing left STN electrode contacts**

included VF abduction and airway opening, Unified Parkinson's Disease Rating Scale (UPDRS-III) motor scores, and anti-PD medication dose. Standardized scales were used for conversion of anti-PD medication into a levodopa equivalent dose (LED).<sup>[27]</sup> Bilateral high frequency STN-DBS was set at 150 Hz. Stimulation settings: Right-STN lead contacts: C(+)-9(-)-10(-). Left-STN lead contact: C(+)-0(-). Pulse width: 60  $\mu$ S.

At baseline, the anti-PD medication dose totaled 1660 mg LED and the UPDRS-III score was 57. Transnasal laryngoscopy revealed bilateral VF immobility with a maximum airway opening of 4 mm. Improvement in the UPDRS-III score was sustained at each measurement timepoint, with a 70–82% reduction in anti-PD medication with high frequency STN-DBS. While the left VF remained immobile at the paramedian position, the right VF abduction modestly increased with maximum airway opening of 6 mm with STN-DBS [Table 1]. However, airway opening remained 70–75% smaller than that of healthy individuals and was insufficient to permit decannulation of the tracheostomy.

### DBS ON vs. DBS OFF

On day 225 with DBS, the UPDRS-III score was 32, with an 82% reduction in medication. Right VF movement



**Figure 2: (A) Laryngoscopic images of laryngeal airway opening. T = True vocal folds; F = False vocal folds; Ep = Epiglottis; Ar = Arytenoids; \* = Airway (space between vocal folds). (B) Schematic representation of vocal fold mobility. (a) True vocal fold adduction during phonation. (b) Vocal fold abduction during normal inspiration. (c) Vocal folds immobile at the paramedian position. (d) The left vocal fold appears immobile at the paramedian position while the right vocal fold is abducted during inspiration. TVC = True vocal cords/folds; FVC = False vocal cords/folds**

**Table 1: Effects of STN-DBS on airway measurements and motor scores**

Time Since Start of STN-DBS (days)	Baseline	7 days	105 days	148 days	225 days		328 days	
Stimulation Frequency	Off	150 Hz	150 Hz	150 Hz	150 Hz	Off*	150 Hz	60 Hz**
Medication State	Off	On	On	On	On	On	On	On
Levodopa Equivalent Dose (%) from baseline	---	45	18	18	18	18	30	30
UPDRS-III Motor Score	57	20	28	30	32	74	32	65
Right Vocal Fold Abduction (mm)	2	---	2.5	---	3	2	2.5	2.5
Left Vocal Fold Abduction (mm)	0	---	0	---	0	0	0	0
‡ Maximum Airway Opening (mm)	4	---	5	---	6	4	5	5
Airway Improvement from baseline (mm)	---	---	+1 mm	---	+2 mm	---	+1 mm	+1 mm

\*Stimulation off condition: testing occurred 2 hours after the DBS was turned off. \*\*Stimulation at 60 Hz: testing occurred 2 hours after the DBS was set at 60 Hz. † Healthy adult maximum airway opening is about 20 mm

had improved to 3 mm, and maximal airway opening had increased to 6 mm. Speech was relatively clear with only mild dysphonia, no coughing, and no stridor with the tracheostomy capped (UPDRS Speech score: 2). On day 225, we also tested the patient after turning the stimulation off for 2 hours. Without DBS, the UPDRS-III score was 74, markedly worse than baseline of 57 and suggesting rapid disease progression. In addition, right VF movement returned to baseline, with maximal airway opening decreasing from 6 mm to 4 mm. We also observed an overall reduction in the tone of the VFs and increased laryngeal tremor. Without DBS, speech also became more effortful, less precise, and less intelligible (UPDRS Speech score: 4).

### High Frequency (150 Hz) DBS vs. Low Frequency (60 Hz) DBS

On day 328, with high frequency DBS, the UPDRS-III score was 32, with a 70% reduction in medication. Right VF movement was 2.5 mm, and maximum airway opening was 5 mm. On day 328, we also tested this patient after

turning the stimulation frequency to 60 Hz for 2 hours. With low frequency DBS, the UPDRS-III score was 65, markedly worse than that with high frequency DBS. VF movement and maximum airway opening were unchanged with low frequency DBS. We also observed a weaker voice with less intelligible speech (UPDRS Speech score: 3). However, it should be noted that this patient was nearing the time for his next dose of anti-PD medication.

## DISCUSSION

The larynx is important to coordinate the life-sustaining functions of airway protection, cough, and swallow.<sup>[15]</sup> The larynx is also important for vocalization and speech. During breathing, the laryngeal airway is open with the true VFs in the abducted position [Figure 2B-b] to permit efficient ventilation. In contrast, the laryngeal airway is closed with the true VFs in the adducted position during vocalization [Figure 2B-a], and may close more forcefully

for airway protection. Each of these mechanisms can be affected in individuals with PD. Up to 80–90% of PD patients will experience laryngeal sensorimotor deficits affecting airway, speech, and swallow function.<sup>[1,5-7]</sup> Abnormal VF position, movement patterns, and timing of VF adduction/abduction may also have detrimental effects on breathing, vocalization, and speech.<sup>[1,5-7]</sup> The resulting voice may be breathy, less loud, and may include a monotonous, flat pitch pattern. Deficits of laryngeal sensorimotor control can emerge at any stage of the disease and worsen with disease progression. The finding of bilateral VF immobility and respiratory stridor reported here, although rare, is a potentially fatal complication of advanced PD.<sup>[4,10,12,14,20,21,23]</sup> Moreover, the potential effects of neuromodulation on VF immobility are largely unknown.

High frequency STN-DBS has become a neuromodulation treatment of choice for advanced PD and is associated with marked improvements in limb motor function as evaluated by the UPDRS. Previous reports suggest that STN-DBS may influence laryngeal function related to vocalization and speech, yet the results remain controversial.<sup>[8,9,13,19,24,25,29]</sup> Reports of both improvement and deterioration in voice, speech, and airway symptoms with STN-DBS have raised many questions regarding the underlying mechanisms.<sup>[2,3,32]</sup> In particular, the contrasting results between limb and axial laryngeal symptoms may relate to a number of factors including baseline laryngeal function, stimulation parameters such as frequency and pulse width, somatotopic representation of the nuclei and fibers of passage within the stimulation field, and the influence of non-dopaminergic pathways that contribute to axial deficits.<sup>[8,9,28,30]</sup>

High frequency STN-DBS in PD patients has been almost exclusively optimized for limb function. The forces generated by the limb musculature are far greater than those of laryngeal motor control. Therefore, high frequency STN-DBS may be of less benefit for the laryngeal musculature.<sup>[8,9,16]</sup> Laryngeal and respiratory sensorimotor control may benefit more from low frequency STN-DBS. For example, improved swallow function, reduced aspiration, and fewer episodes of freezing gait were reported with low frequency (60 Hz) STN-DBS compared with high frequency (130 Hz) STN-DBS.<sup>[18,22,31]</sup> Newer targets, such as the pedunculopontine nucleus (PPN) have shown improvements in axial signs including gait and postural stability.<sup>[17,26]</sup> Sitti *et al.* demonstrated profound changes in PPN activity with STN stimulation at 60 Hz.<sup>[11]</sup> However, the potential for PPN-DBS to improve laryngeal function remains uncertain. At present, the STN is a primary surgical target for DBS. Therefore, efforts should focus on maximizing patient benefit and minimizing potential decrements in laryngeal function with STN-DBS.

In the present case, our patient exhibited marked improvements in limb motor function with STN-DBS that was accompanied by measurable but modest improvements in VF mobility. Although a rare finding in patients with PD, the mechanisms for VF immobility in PD may initially stem from rigidity of the intrinsic laryngeal muscles and reduced range of motion of the cricoarytenoid joint.<sup>[4-6,10,12,14,20,23]</sup> Over time, the reduced range of movement may result in a less flexible and immobile cricoarytenoid joint that further impairs VF mobility, even in the presence of potential benefit from STN-DBS. Therefore, the inability of the VF to open adequately may stem from a combination of muscle rigidity and reduced cricoarytenoid joint mobility. In future patients, electromyography of the intrinsic laryngeal muscles and intraoperative examination of the cricoarytenoid joint by a laryngologist may help determine the relative contribution of each.

Axial and limb symptoms may appear and progress differently across the midline, and each symptom may progress at different rates. The patient reported here exhibited limb symptoms that were more severe on the left. His impaired VF mobility was also more severe on the left, with the VF remaining immobile. This finding was consistent with laterality of axial symptoms. Therefore, the larynx offers a unique opportunity to compare the extent and laterality of axial and peripheral motor dysfunction in PD patients. Testing after two hours of low frequency STN-DBS resulted in more severe UPDRS scores compared with high frequency STN-DBS. However, the benefit to VF mobility was sustained and similar at each setting. The potential effects of longer intervals of low frequency stimulation on limb and laryngeal function will be important to explore in the future, as will examining the relative contribution of medication and DBS.

## CONCLUSIONS

Bilateral VF immobility and respiratory stridor are potentially fatal complications of advanced PD. To our knowledge, this is the first report demonstrating STN-DBS influence on VF immobility under direct visualization via transnasal laryngoscopy. STN-DBS may influence various aspects of laryngeal sensorimotor control, including potential improvements in VF mobility as reported here. Comprehensive multidisciplinary assessment is critical to identify the complex clinical features in PD patients that may respond to or may result from STN-DBS to maximize the benefit of STN-DBS for both limb and axial sensorimotor symptoms. Detailed characterization of axial motor symptoms, including laryngeal dysfunction, may provide a marker of disease progression and serve as a tool to predict responsiveness to DBS.

## Acknowledgements

Christopher J. Sheridan, RN: Involved in organization of clinic appointments, DBS programming sessions, and clinical examinations.

## Financial support and sponsorship

Dr. Hammer's work is funded by NIH grant DC014519.

## Conflicts of interest

There are no conflicts of interest.

## REFERENCES

- Blumin JH, Pcolinsky DE, Atkins JP. Laryngeal findings in advanced parkinson's disease. *Ann Otol Rhinol Laryngol* 2004;113:253-8.
- Chalif JI, Sitsapesan HA, Pattinson KT, Herigstad M, Aziz TZ, Green AL. Dyspnea as a side effect of subthalamic nucleus deep brain stimulation for parkinson's disease. *Respir Physiol Neurobiol* 2014;192:128-33.
- Fagbami OY, Donato AA. Stridor and dysphagia associated with subthalamic nucleus stimulation in parkinson disease. *J Neurosurg* 2011;115:1005-6.
- Gan EC, Lau DP, Cheah KL. Stridor in parkinson's disease: A case of 'dry drowning'? *J Laryngol Otol* 2010;124:668-73.
- Hammer MJ. Aerodynamic assessment of phonatory onset in parkinson's disease: Evidence of decreased scaling of laryngeal and respiratory control. *J Parkinson's Dis* 2013;3:173-179.
- Hammer MJ, Barlow SM. Laryngeal somatosensory deficits in parkinson's disease: Implications for speech respiratory and phonatory control. *Exp Brain Res* 2010;201:401-9.
- Hammer MJ, Murphy CA, Abrams TM. Airway somatosensory deficits and dysphagia in parkinson's disease. *J Parkinson's Dis* 2013;3:39-44.
- Hammer MJ, Barlow SM, Lyons KE, Pahwa R. Subthalamic nucleus deep brain stimulation changes speech respiratory and laryngeal control in parkinson's disease. *J Neurol* 2010;257:1692-702.
- Hammer MJ, Barlow SM, Lyons KE, Pahwa R. Subthalamic nucleus deep brain stimulation changes velopharyngeal control in parkinson's disease. *J Commun Disord* 2011;44:37-48.
- Holinger LD, Holinger PC, Holinger PH. Etiology of bilateral abductor vocal cord paralysis: A review of 389 cases. *Ann Otol Rhinol Laryngol* 1976;85:428-36.
- Ilkay S, Acar G, Zisakis AK, Ozdemir M, Acar F, Burchiel KJ. Effect of Subthalamic Nucleus Stimulation on Pedunculopontine Nucleus Neural Activity. *Stereotact Funct Neurosurg* 2016;94:54-9.
- Kim HJ, Jeon BS. Acute respiratory failure due to vocal cord paralysis in a patient with parkinson's disease. *Mov Disord* 2009;24:1862-3.
- Klostermann F, Ehlen F, Vesper J, Nubel K, Gross M, Marzinzik F, et al. Effects of subthalamic deep brain stimulation on dysarthrophonia in parkinson's disease. *J Neurol Neurosurg Psychiatry* 2008;79:522-9.
- Lee DH, Lim SC, Lee JK. Bilateral vocal cord paralysis in a patient with parkinson's disease. *B-ENT* 2012;8:141-2.
- Meyer TK. The larynx for neurologists. *Neurologist* 2009;15:313-8.
- Montgomery EB. Deep brain stimulation and speech: A new model of speech function and dysfunction in parkinson's disease. *J Med Speech Lang Pathol* 2007;15:ix-xxv.
- Pahapill PA, Lozano AM. The pedunculopontine nucleus and parkinson's disease. *Brain* 2000;123(Pt 9):1767-83.
- Phibbs FT, Arbogast PG, Davis TL. 60-hz frequency effect on gait in parkinson's disease with subthalamic nucleus deep brain stimulation. *Neuromodulation* 2014;17:17-20.
- Pinto S, Gentil M, Krack P, Sauleau P, Fraix V, Benabid AL, et al. Changes induced by levodopa and subthalamic nucleus stimulation on parkinsonian speech. *Mov Disord* 2005;20:1507-15.
- Plasse HM, Lieberman AN. Bilateral vocal cord paralysis in parkinson's disease. *Arch Otolaryngol* 1981;107:252-3.
- Qayyum A, Mierzwa K, See M, Sharma A, Montgomery PQ. Laser arytenoidectomy for bilateral vocal fold palsy in parkinson's disease. *J Laryngol Otol* 2005;119:831-3.
- Ramdhani RA, Patel A, Swope D, Kopell BH. Early use of 60 hz frequency subthalamic stimulation in parkinson's disease: A case series and review. *Neuromodulation* 2015;18:664-9.
- Read D, Young A. Stridor and parkinsonism. *Postgrad Med J* 1983;59:520-1.
- Skodda S. Effect of deep brain stimulation on speech performance in parkinson's disease. *Parkinsons Dis* 2012;2012:850596.
- Skodda S, Gronheit W, Schlegel U, Sudmeyer M, Schnitzler A, Wojtecki L. Effect of subthalamic stimulation on voice and speech in parkinson's disease: For the better or worse? *Front Neurol* 2014;4:218.
- Stefani A, Lozano AM, Peppe A, Stanzione P, Galati S, Tropepi D, et al. Bilateral deep brain stimulation of the pedunculopontine and subthalamic nuclei in severe parkinson's disease. *Brain* 2007;130:1596-607.
- Tomlinson CL, Stowe R, Patel S, Rick C, Gray R, Clarke CE. Systematic review of levodopa dose equivalency reporting in parkinson's disease. *Mov Disord* 2010;25:2649-53.
- Tornqvist AL, Schalen L, Rehncrona S. Effects of different electrical parameter settings on the intelligibility of speech in patients with parkinson's disease treated with subthalamic deep brain stimulation. *Mov Disord* 2005;20:416-23.
- Tripoliti E, Zrinzo L, Martinez-Torres I, Frost E, Pinto S, Foltynie T, et al. Effects of subthalamic stimulation on speech of consecutive patients with parkinson disease. *Neurology* 2011;76:80-6.
- Tripoliti E, Zrinzo L, Martinez-Torres I, Tisch S, Frost E, Borrell E, et al. Effects of contact location and voltage amplitude on speech and movement in bilateral subthalamic nucleus deep brain stimulation. *Mov Disord* 2008;23:2377-83.
- Xie T, Vigil J, MacCracken E, Gasparaitis A, Young J, Kang W, et al. Low-frequency stimulation of STN-DBS reduces aspiration and freezing of gait in patients with pd. *Neurology* 2015;84:415-420.
- Yanase M, Kataoka H, Kawahara M, Hirabayashi H, Yamanaka T, Hirano M, et al. Fixed epiglottis associated with subthalamic nucleus stimulation in parkinson's disease. *J Neurol Neurosurg Psychiatry* 2008;79:332-3.