


Successful percutaneous closure of aortic root-to-right ventricle fistula after transcatheter aortic valve implantation: a valuable option in high-risk surgical patients

Apostolos Vrettos ¹, Alison Duncan¹, Asrar Ahmed¹, Ee Ling Heng¹, and Vasileios Panoulas^{1,2*}

¹Department of Cardiology, Royal Brompton & Harefield Hospitals, Guy's and St Thomas' NHS Foundation Trust, Hill End Rd, Harefield, Uxbridge UB9 6JH, UK; and ²Faculty of Medicine, Cardiovascular Sciences, National Heart and Lung Institute, Imperial College London, Royal Brompton Campus, Guy Scadding Building, Cale Street, London SW3 6LY, UK

Received 15 September 2021; first decision 27 October 2021; accepted 18 February 2022; online publish-ahead-of-print 22 February 2022

Background

Aortic-to-right ventricle (ARV) fistula is an uncommon complication of transcatheter aortic valve implantation (TAVI). Even though surgical closure is usually the treatment of choice in such communications, percutaneous treatment options are valuable alternatives for these high-risk surgical patients.

Case summary

In this article, we present the percutaneous closure of an ARV fistula after TAVI, in a highly symptomatic patient with recurrent episodes of heart failure decompensation with worsening right ventricular function, who failed conservative medical treatment and was deemed inoperable. Successful closure of the fistula with the use of the Amplatzer atrial septal occluder was performed 6 months post-TAVI, under general anaesthesia and transoesophageal echocardiography (TOE). A detailed multi-modality imaging pre-procedural planning was performed utilizing 4D cardiac computed tomography and echocardiography. The patient has remained asymptomatic and in good health 5 months after the ARV fistula closure, with marked improvement in his clinical picture and echocardiographic parameters.

Discussion

Aortic-to-right ventricle fistulas with significant shunt post-TAVI could lead to biventricular failure and are associated with increased mortality if left untreated. This case demonstrates that TOE-guided percutaneous closure of a TAVI-related ARV fistula, although technically challenging, is feasible, and can be a valuable option for the treatment of symptomatic high-risk surgical patients.

Keywords

Aortic valve • TAVI • Complication • Shunt • Case report

ESC Curriculum

2.2 Echocardiography • 4.2 Aortic stenosis • 6.7 Right heart dysfunction • 7.4 Percutaneous cardiovascular post-procedure • 6.4 Acute heart failure

* Corresponding author. Tel: +44 01895 823737, Email: v.panoulas@imperial.ac.uk

Additional author added in-between revisions.

Handling Editor: Dimitrios A. Vrachatis

Peer-reviewers: Claudio Montalto and Jorge Sanz Sanchez

Compliance Editor: Reshma Amin

Supplementary Material Editor: Katharine Kott

© The Author(s) 2022. Published by Oxford University Press on behalf of the European Society of Cardiology.

This is an Open Access article distributed under the terms of the Creative Commons Attribution-NonCommercial License (<https://creativecommons.org/licenses/by-nc/4.0/>), which permits non-commercial re-use, distribution, and reproduction in any medium, provided the original work is properly cited. For commercial re-use, please contact journals.permissions@oup.com

Learning points

- Aortic root-to-right ventricle (ARV) fistula is a rare complication of transcatheter aortic valve implantation. Echocardiography and right heart catheterization, can facilitate early identification and prompt repair of significant ARV fistulas.
- Evidence of cardiac decompensation and large shunt flow ($Q_p:Q_s > 2$) warrant prompt repair. Small, asymptomatic shunts may be managed conservatively and closely followed up, but there is limited long-term data to support this approach.
- Surgical closure has been the standard method of repair. However, the percutaneous closure represents a safe and feasible option; this can be a valuable option in high- or prohibitive-risk surgical candidates.

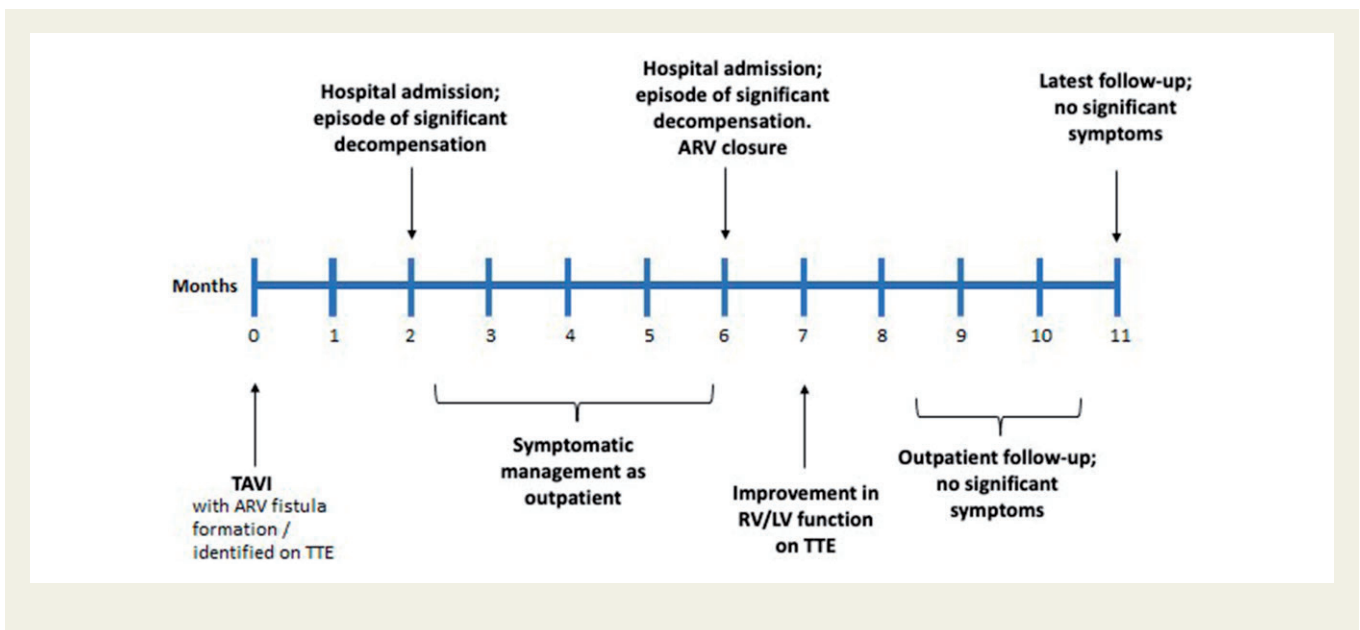
Introduction

With the exponential rise of the number of transcatheter aortic valve implantation (TAVI) procedures, the likelihood of encountering rare complications increases. Patients undergoing TAVI are predominantly at high or prohibitive risk for surgery, therefore it is important to develop percutaneous strategies for managing potential complications that arise from the procedure. Aortic root-to-right ventricle (ARV) fistula is a rare complication of TAVI associated with high mortality, and its percutaneous closure is technically challenging. In this study, we describe a case of ARV fistula post-TAVI that was closed percutaneously using an Amplatzer atrial septal defect (ASD) occluder (St. Jude Medical, St. Paul, MN, USA), utilizing multimodality imaging for diagnosis and pre-procedure planning, as well as intra-procedural transoesophageal echocardiography (TOE).

Case presentation

A 78-year-old man with a medical history of hypertension, hyperlipidaemia, non-flow limiting coronary artery disease, and early Alzheimer's dementia was referred to our centre with class II heart failure symptoms due to severe aortic stenosis. On physical examination, he had a slow rising pulse and auscultation revealed a 3/6 ejection systolic murmur radiating to the carotids, with absent second heart sound. Coronary angiography showed mild coronary artery disease, and a transthoracic echocardiogram (TTE) showed good left ventricular (LV) function with severe aortic stenosis (pressure gradients: 96 mmHg peak/52 mmHg mean, aortic valve area of 0.9 cm^2) with mild aortic regurgitation. There was mild concentric LV hypertrophy with normal biventricular size and function with an LV ejection fraction (EF) of 62%, mild mitral regurgitation, and normal

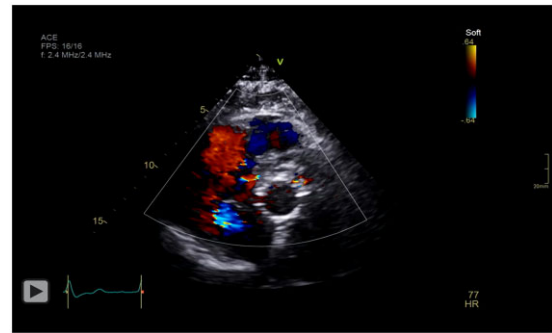
Timeline



estimated resting pulmonary artery systolic pressure (PASP). The proximal ascending aorta had normal diameter. Based on his age, comorbidities and in particular the presence of early dementia, our multidisciplinary valve team decided to offer TAVI. A multi-slice cardiac computed tomography (CT) showed an aortic valve calcium score of 4736, an aortic valve area of 0.7 cm², and perimeter of 95 mm. There was adequate iliofemoral access from either side. A balloon expandable (Edwards SAPIEN 3) 29 mm valve was chosen in order to avoid a significant paravalvular leak due to the high calcium burden.

We performed the transfemoral TAVI according to standard practice. The aortic valve was crossed with an AL1 and a straight wire and the latter was exchanged for a Confida stiff wire. The valve was implanted at optimal height using rapid pacing at 200 beats per minute. On final aortogram, there was mild paravalvular leak. Post-implantation TTE revealed a small, high velocity jet from aortic root to the right ventricular outflow tract (RVOT) suggestive of a possible defect. A departmental TTE (*Figure 1, Video 1*) showed a well-seated TAVI with mild anterior and posterior paravalvular aortic regurgitation, aortic root defect of ~0.4cm² with a continuous shunt to the RVOT, with a peak gradient of 90 mmHg, preserved LV systolic function, mild basal dilatation of the right ventricle (right ventricular basal diameter = 4.3 cm) with preserved function and raised PASP of 60 mmHg. A decision was made to treat the patient conservatively at this stage with furosemide 40 mg daily. He was discharged 5 days after the TAVI procedure with further outpatient follow-up. Two months

later (month 2 on timeline), he re-presented with significant shortness of breath and peripheral oedema and he was treated with intravenous (IV) diuresis. An inpatient TTE was similar as the one post-TAVI, showing mild right ventricular dilatation. A right heart catheterisation showed step-up in oxygen saturations in the right ventricle with Qp:Qs of 1.98. A 4D cardiac CT scan showed a communication between the aortic root and the right ventricle just behind the TAVI struts (*Figure 2*). Given the location of the defect and the relative



Video 1 Parasternal short axis at the aortic valve level transthoracic echocardiogram with colour flow Doppler showing a shunt between the aortic root at 11 o'clock position and the right ventricle.

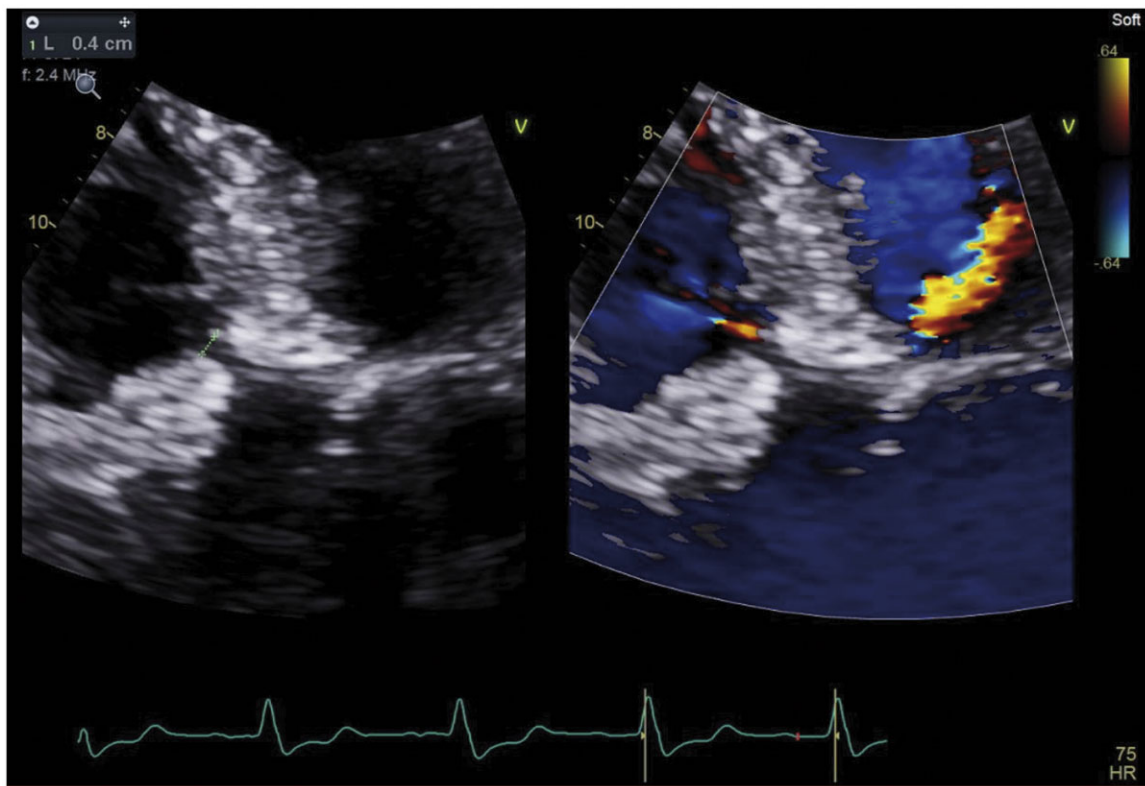


Figure 1 Transthoracic echocardiogram with colour flow Doppler showing a shunt between the aortic root and the right ventricle.

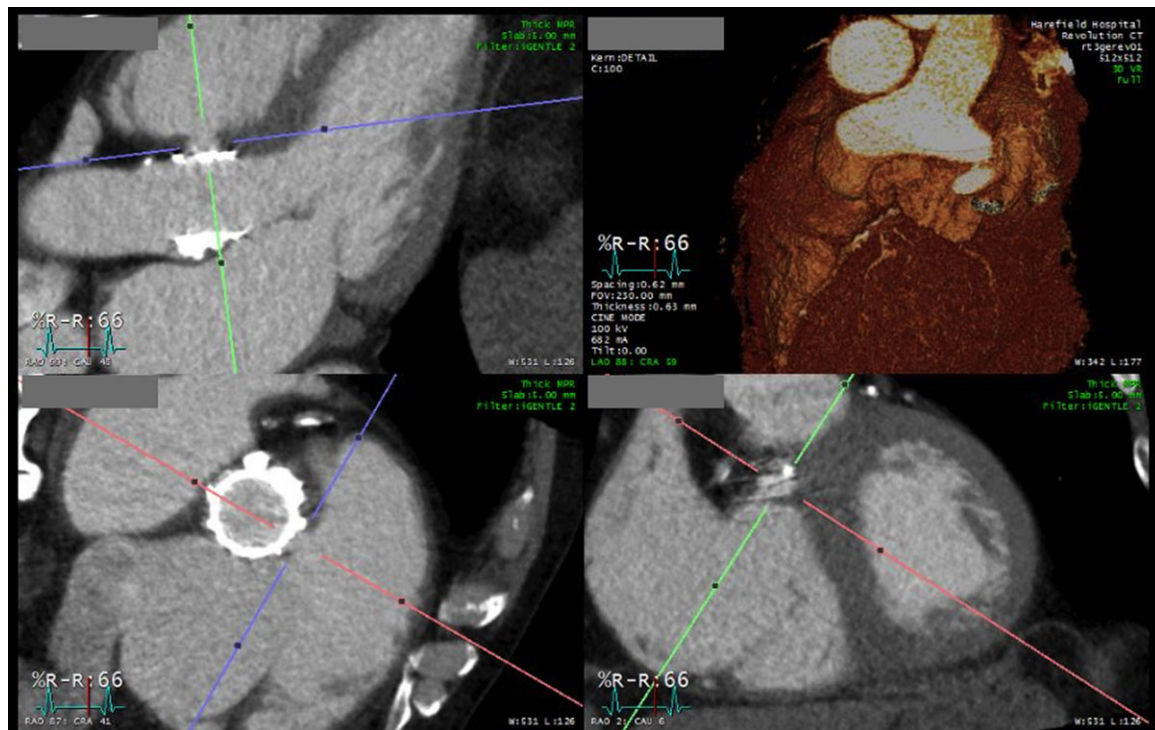
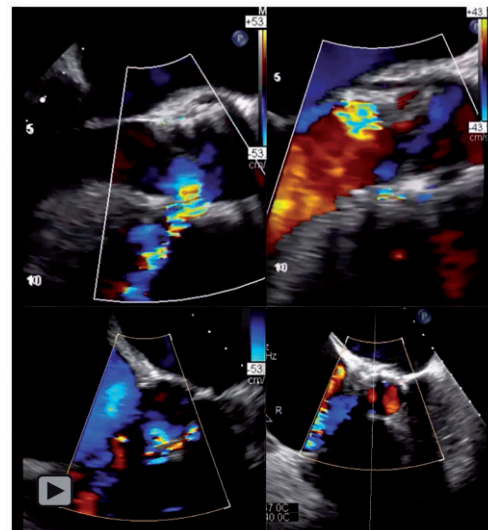
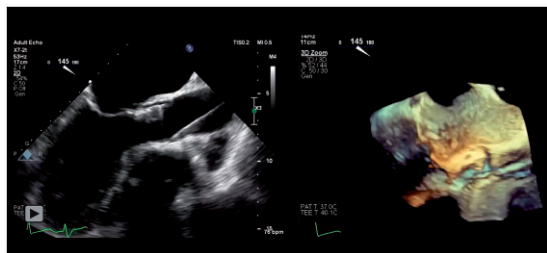


Figure 2 Four-dimensional cardiac computed tomography scan showing a communication between the aortic root and the right ventricle behind the transcatheter aortic valve implantation struts.

frailty of the patient the heart team opted for conservative management (months 2–6 on timeline) uptitrating his furosemide to 40 mg twice daily. However, 4 months later (month 6 on timeline), he re-presented with right sided heart failure symptoms. Whilst an in-patient, he started slowly drifting into multiorgan failure despite IV furosemide infusion and single-agent inotropic support with dobutamine. Following repeat multidisciplinary discussions, in view of the recurrent episodes of decompensation and evidence of progressive biventricular impairment on serial TTEs (LV EF 43%, dilated right ventricle with reduced radial function, right ventricular basal diameter = 6.5 cm, mid right ventricular diameter = 4.3 cm, severe functional tricuspid regurgitation), we decided to proceed with percutaneous closure of the fistula as a salvage procedure. The procedure was undertaken under general anaesthesia with TOE guidance. On intra-procedural TOE, a 5 × 3 mm ARV fistula was visualised above the TAVI annulus (*Video 2*). The defect was readily crossed with a JR4 catheter and Terumo wire, which was exchanged for an Amplatzer stiff wire under fluoroscopic and TOE guidance (*Video 3*, [Supplementary material online, Video S1](#)). A 4 mm Amplatzer ASD occluder was then successfully deployed with no residual fistula or significant shunt seen on intra-procedural TOE (*Video 2*). There was only mild transvalvular aortic regurgitation of the TAVI prosthesis as previously noted. The patient recovered well with improvement in his symptoms and his organ function and was started on bisoprolol 2.5 mg daily, spironolactone 25 mg and ramipril 1.25 mg daily. A repeat TTE 1 month later (month 7 on timeline) showed improvement in right ventricular size and biventricular function ([Supplementary](#)



Video 2 Upper clips: Mid-oesophageal long-axis views. Lower clips: Mid-oesophageal aortic valve short-axis views. Left: Pre-procedural transoesophageal echocardiographies with colour flow Doppler showing shunt across an aortic root-to-right ventricle fistula above the transcatheter aortic valve implantation annulus. Right: Post-procedural transoesophageal echocardiographies with colour flow Doppler after the deployment of the atrial septal defect occluder showing absence of any significant residual shunt.



Video 3 Intra-procedural transoesophageal echocardiography showing crossing of the aortic root-to-right ventricle fistula with a wire in 2D (left) and 3D (right) acquisitions.

material online, [Video S2](#)). The patient remains asymptomatic and in good health 11 months after the TAVI and 5 months after the ARV fistula closure, with the latest TTE showing mild basal right ventricular dilatation and preserved biventricular function.

Discussion

The use of balloon-expandable valves, the depth of prosthesis, larger size devices, excessive post-dilatation are important factors associated with increased risk for aortic annulus rupture, or fistula formation during TAVI.¹ The risk of aortic root rupture increases in the presence of heavy annular or LV outflow tract (LVOT) calcification, and most operators in such cases would opt for self-expanding valves. If the latter needs post-dilatation due to an under-expanded frame, a non-compliant balloon equal to the size of the minimum aortic annulus diameter would be primarily used to avoid 1:1 interaction with the aortic annulus. In our case, however, there was no significant LVOT calcification, which is the conventional risk factor for annular rupture. Indeed the aortic valve itself was heavily calcified; however, this is often the case in patients with aortic stenosis and is not a contraindication for balloon expandable valves. The communication between the aortic root and the right ventricle is rather rare complication in this setting and no particular procedural steps could have avoided its occurrence.


A defect of the aortic wall in the area above the right coronary cusp, where it separates the aorta and RVOT, will create a fistula to the right ventricle with various clinical presentations depending on its size and chronicity. Although there is no consensus on the time of intervention for such communications, if there is a significant shunt with elevated pulmonary pressures and signs of significant right ventricular impairment, prompt closure should be advocated. If the shunt is small with Q_p/Q_s is <2 and there is no immediate, significant compromise, initial conservative therapy may be trialled.¹ In the seven conservatively treated ARV fistula cases reported, three died and four remained asymptomatic at follow-up periods between 9 months to 4 years.²⁻⁸ In the asymptomatic cases, pulmonary (Q_p) to systemic (Q_s) blood flow ratio was $Q_p:Q_s < 1.80$. Annual follow-up of iatrogenic ARV fistulas in asymptomatic patients with small shunts has been proposed.⁹ We feel that due to the rarity of this complication and complexity in planning definitive treatment, these cases should

initially be followed at the 1st, 3rd, and 6th months post-procedure to ensure no clinical or echocardiographic deterioration occurs. If the patients are clinically stable with no signs of right ventricular loading they could then be followed up annually. We advocate that such complex patients be followed up by structural interventional cardiologists and/or heart failure specialists in tertiary centres in the immediate postoperative period and only be discharged to their referring centres after a 6-month period of stability.

Such an approach is sensible considering the lack of long-term data and bearing in mind that ARV fistulas represent defects in the aortic root where spontaneous closure is unlikely. Individual patient characteristics, perceived peri-procedural risk, life expectancy and patient's choice should also be considered when deciding definitive treatment.

Percutaneous closure of a TAVI-related ARV fistula represents a technical challenge due to the variability in size, shape and complexity of the defect, and the fact that closure devices could interfere with the TAVI valve itself. So far, very few relevant cases have been described; four using an occluder device,¹⁰⁻¹³ one with coil embolization,¹⁴ and one with an Amplatzer Vascular Plug (AVP) vascular plug.¹⁵ In our case, multimodality pre-procedural planning with echocardiography and 4D cardiac CT allowed detailed assessment of fistula size and anatomy. TOE guidance facilitated the accurate delivery and deployment of the device, with virtually complete occlusion of the fistula and near elimination of shunt. After interventional management, it is sensible to review the patient with a TTE at 1, 3, 6, and 12 months followed by annual surveillance if they are clinically stable. Our patient has remained asymptomatic 5 months after the procedure, with stable TTE parameters.

Lead author biography



Apostolos Vrettos is a cardiology specialty registrar, subspecializing in advanced heart failure and cardiac imaging at Harefield Hospital in London, UK. He graduated from the University of Athens Medical School in Greece, in 2012. He has completed a Master's degree in Clinical Research and a Postgraduate Certificate in Medical Education and has always tried to be academically productive whilst clinically focused. He is an

echocardiography passionate and biostatistics enthusiast, who enjoys teaching and mentoring of junior colleagues and exploring how advances in imaging techniques could improve patients' outcomes.

Supplementary material

Supplementary material is available at *European Heart Journal - Case Reports* online.

Slide sets: A fully edited slide set detailing this case and suitable for local presentation is available online as [Supplementary data](#).

Consent: The authors confirm that written consent for submission and publication of this case report including images and associated text has been obtained from the patient's relative (next of kin) in line with COPE guidance.

Conflict of interest: V.P. has collected the relevant clinical information and supervised the writing-up of the case as the senior author. A.V. has performed a literature review and along with E.L.H. and A.D. wrote the discussion part of this case collective, each providing their own expertise (imaging/echocardiography, structural interventions, and interventional cardiology, respectively). All authors worked together to format the manuscript appropriately.

Funding: None declared.

References

1. Coughlan JJ, Kiernan T, Mylotte D, Arnous S. Annular rupture during transcatheter aortic valve implantation: predictors, management and outcomes. *Interv Cardiol* 2018;**13**:140–144.
2. Muñoz-García AJ, Rodríguez-Bailón I, Briales JH, Navarro MJ, García JM, de Teresa-Galván E. Aorto-right ventricular fistula after percutaneous aortic valve implantation of a CoreValve prosthesis. *Tex Heart Inst J* 2011;**38**:728–729.
3. Leu H-B, Chang H-H, Wu M-H, Chen Y-H. Four-year follow-up of acquired aorto-right ventricular fistula after transcatheter aortic valve implantation. *Eur Heart J* 2016;**37**:2679–2679.
4. Almanfi A, Qurie A, Strickman N. Aorto-right ventricular shunt after TAVR: rare complication of common procedure. *Case Rep Cardiol* 2017;**2017**:1834394.
5. Shakoor MT, Islam AM, Ayub S. Acquired aorto-right ventricular fistula following transcatheter aortic valve replacement. *Case Rep Cardiol* 2015;**2015**:608539.
6. Leroux L, Dijos M, Peltan J, Casassus F, Seguy B, Natsumeda M et al. Lethal aorto-right ventricular defect after transcatheter aortic valve implantation in a patient with radiation-induced porcelain aorta: notes of caution. *Can J Cardiol* 2016;**32**:135.e9–11.
7. Hagiwara K, Saito N, Yamazaki K, Kimura T. Aorto-right ventricular fistula following transcatheter aortic valve implantation using a 29 mm SAPIEN XT valve. *BMJ Case Rep* 2017;**2017**:bcr2017219247.
8. Konda MK, Kalavakunta JK, Pratt JW, Martin D, Gupta V. Aorto-right ventricular fistula following percutaneous transcatheter aortic valve replacement: case report and literature review. *Heart Views* 2017;**18**:133–136.
9. Najib MQ, Ng D, Vinales KL, Chaliki HP. Aorto-right ventricular fistula: a complication of aortic valve replacement. *Ann Thorac Cardiovasc Surg* 2012;**18**:64–67.
10. Alabbady AM, Sattur S, Bauch TD, Harjai KJ. Aorto-right ventricular fistula and paravalvular leak after transcatheter aortic valve implantation. *JACC Case Rep* 2019;**1**:859–864.
11. Nakamura K, Passeri JJ, Inglessis-Azuaje I. Percutaneous closure of acute aorto-right ventricular fistula following transcatheter bicuspid aortic valve replacement. *Catheter Cardiovasc Interv* 2017;**90**:164–168.
12. Hamandi M, Potluri S. Aorto-right ventricular fistula closure after TAVR guided by intracardiac echocardiography. *Struct Heart* 2019;**3**:252–254.
13. Damman P, de Jong KH, de Geus KF, de Winter RJ. Transcatheter closure of an iatrogenic aorta-right ventricular fistula after transfemoral aortic valve implantation. *Eur Heart J Case Rep* 2017;**1**:ytx019.
14. Pilgrim T, Meier B, Wenaweser P. Aorto-right ventricular fistula after transfemoral aortic valve implantation. *J Invasive Cardiol* 2010;**22**:E30–E31.
15. Vainrib AF, Ibrahim H, Hisamoto K, Staniloae CS, Jilaihawi H, Benenstein RJ et al. Aorto-right ventricular fistula post-transcatheter aortic valve replacement: multimodality imaging of successful percutaneous closure. *CASE (Phila)* 2017;**1**:70–74.