

PEDIATRIC UROLOGY  
ORIGINAL ARTICLE

# Distal extension of the midline urethral-plate incision in the Snodgrass hypospadias repair: An objective assessment of the functional and cosmetic outcomes



Ahmed M. Al-Adl \*, Tarek M. El-Karamany, Ayman S. Bassiouny

*Urology Department, Benha Faculty of Medicine, Egypt*

Received 15 November 2013, Received in revised form 1 February 2014, Accepted 5 February 2014  
Available online 15 March 2014

## KEYWORDS

Hypospadias;  
Tubularised incised  
plate;  
Outcome

## ABBREVIATIONS

HOSE, Hypospadias  
Objective Scoring  
Evaluation;  
TIP, tubularised  
incised-plate;  
 $Q_{max}$ , maximum  
urinary flow rate;

**Abstract Objectives:** To objectively assess the functional and cosmetic outcomes of a modified tubularised incised-plate (TIP) urethroplasty (Snodgrass) technique, with particular attention to the uroflowmetry study and Hypospadias Objective Scoring Evaluation (HOSE) score.

**Patients and methods:** In a prospective case-series study, 43 consecutive patients with primary distal hypospadias were evaluated. The modified Snodgrass technique included an extension of the midline relaxing incision of the urethral plate from within the hypospadiac meatus to the very tip of the glans. The neourethra was tubularised starting at the neomeatus and proceeding proximally. The neourethra was covered with either a single or double dartos flap. In toilet-trained boys, at least 3 months after surgery, the flow pattern, maximum ( $Q_{max}$ ), and mean urinary flow rate ( $Q_{ave}$ ) were recorded, and the results plotted against a recently published flow-rate nomogram from normal children. The postvoid residual urine volume was measured using ultrasonography. The cosmetic outcome was assessed using the HOSE system.

\* Corresponding author. Tel.: +20 966533315415; fax: +20 96627380032.

E-mail addresses: [ameladl@hotmail.com](mailto:ameladl@hotmail.com), [ahmed\\_eladl2002@yahoo.com](mailto:ahmed_eladl2002@yahoo.com) (A.M. Al-Adl).

Peer review under responsibility of Arab Association of Urology.



Production and hosting by Elsevier

$Q_{ave}$ , mean urinary flow rate;  
UCF, urethrocutaneous fistula

**Results:** The native meatus was coronal in 11 (26%), subcoronal in 23 (53%) and distal penile in nine (21%) of the patients. The median (range) age was 4.2 (0.5–14) years. The neourethra was covered by a single dorsal dartos flap in 25 and a double dartos flap in 18 patients. At a median (range) follow-up of 6 (3–24) months, the uroflowmetry findings in 26 uncomplicated toilet-trained boys with a median (range) age of 5.2 (3.3–14) years showed an abnormal  $Q_{max}$  below the fifth percentile in four (15%), with the  $Q_{ave}$  above the fifth percentile in all. The flow pattern was bell-shaped in nine boys (35%), interrupted/intermittent in five (19%), slightly flattened in 10 (39%) and a plateau in two (8%). A vertical slit-like meatus located at the distal glans was created in 39 (91%) boys, and at the proximal glans in four (9%). The urinary stream was single and straight in 39 and angled in four patients. A straight erection was observed in 42 (98%) boys. Four patients had preoperative mild penile torsion of  $<45^\circ$ , that was corrected by surgery. The mean (SD, range) HOSE score was 15.8 (0.6, 13–16). Two patients had a small, single subcoronal fistula.

**Conclusion:** Extending the midline urethral plate-incision in the modified Snodgrass repair to the apical part of the glans can be done safely with a high rate of locating the neomeatus at the glans tip, with no resultant meatal stenosis. The functional and cosmetic results of the procedure are good, but long-term data and comparative studies are required to confirm these results.

© 2014 Production and hosting by Elsevier B.V. on behalf of Arab Association of Urology.

## Introduction

Snodgrass repair [1,2] was introduced in 1994 and has revolutionised the management of distal hypospadias, and is considered the procedure of choice by most surgeons. The technique relies on an incision of the urethral plate to permit a tension-free tubularisation of the neourethra. The mechanism of healing of the incised plate is debatable. Snodgrass [3] postulated that healing occurs by re-epithelialisation, with no evidence of neourethral stenosis or stricture formation, whereas many others consider that it heals by epithelial creeping, which theoretically increases the incidence of complications because of healing by primary intention if allowed to contract [4,5]. This can be prevented by separating the two sides of the gapped urethral wound; therefore, regular daily dilatation of the neourethra was advised to prevent meatal stenosis and fistula formation [6].

In the standard technique, Snodgrass and others [7–9] affirmed that it was better not to incise the apical part of the glans for fear of meatal stenosis. Therefore, the neourethra is sutured to the mid-glans level, and the neomeatus should be generously sized and oval at the same time. This resulted in a higher rate of achieving a slit-like meatus, but a lower rate of locating the meatus in the glans tip [10]. Histological studies under the urethral plate have shown a healthy, vascularised connective subepithelial tissue [11]. Thus, incising the apical part of the glans could be safe, to assign the neomeatus more to the tip of the glans, and suturing the neourethra more distally. Normally, the meatus is located at the glans apex in 94% of boys [12] and the ventral glans closure is equal to or slightly less than the meatal length [13].

In the present study, in a trial to emulate the normal anatomy, we adopted a modification previously proposed by Jayanthi [14] by extending the midline incision to the apical part of the glans. The functional and cosmetic results of the modified technique were objectively assessed with a uroflowmetry study and by the Hypospadias Objective Score Evaluation (HOSE) score [15] (Table 1).

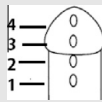
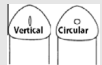
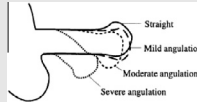

## Patients and methods

Between June 2008 and December 2012, 43 patients with primary distal hypospadias repaired with the modified Snodgrass technique were included in a prospective case-series study. Patients with proximal hypospadias, coronal hypospadias with a mobile urethra, megameatus intact prepuce, and those with a previously failed repair were excluded from the study. None of the patients received preoperative local or systemic androgen therapy. Informed consent was obtained from all patients' sponsors, and the procedure and possible risks were explained thoroughly, according to declaration of Helsinki. The study was approved by the local ethics committee of the Benha Faculty of Medicine.

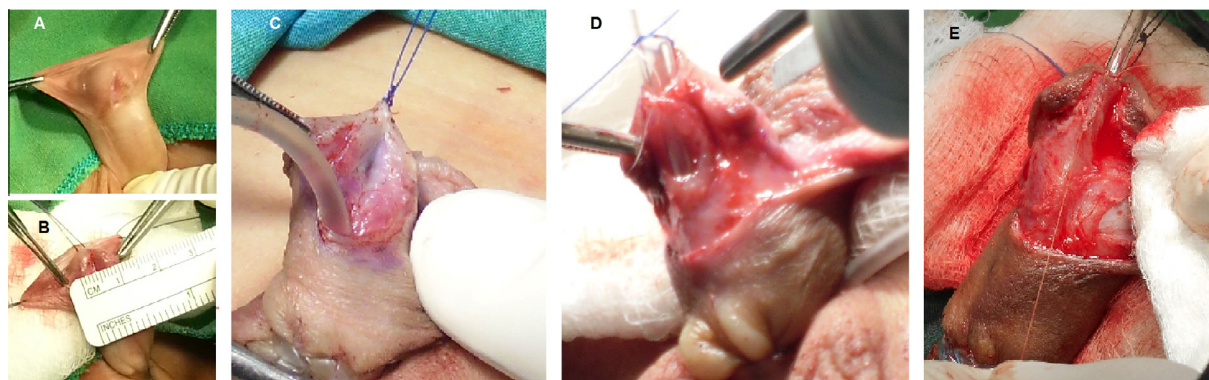
### *Surgical technique*

The urethral plate width and length, and the maximum transverse glans diameter, were measured using a ruler. The procedure was as previously described [7,14]. The vertical midline incision of the urethral plate was made from within the hypospadiac meatus and extended up to the apical part of the glans tip. The urethral plate was tubularised beginning distally at the neomeatus

**Table 1** The HOSE system, from Holland et al. [15], with permission.

Assessor		Patient
Variable	Score and description	
Meatal location	4 → Distal glanular 3 → Proximal glanular 2 → Coronal 1 → Penile shaft	
Meatal shape	2 → Vertical slit 1 → Circular	
Urinary stream	2 → Single 1 → Spray	
Erection	4 → Straight 3 → Mild angulation <math>< 10^\circ</math> 2 → Moderate > <math&gt;10^\circ&lt; &lt;math&gt;&lt;="" 45^\circ&lt;="" but="" math&gt;="" math&gt;<br=""></math&gt;10^\circ&lt;> 1 → Severe > <math&gt;45^\circ&lt; math&gt;<="" td=""> <td></td> </math&gt;45^\circ&lt;>	
Fistula	4 → None 3 → Single subcoronal 2 → Single proximal 1 → Multiple or complex	
Total score		

According to Holland et al. (2001) [15] with permission.



**Figure 1** Coronal hypospadias with a urethral plate 8 mm wide (A and B). The deep midline urethral-plate incision (C). The construction of the neomeatus preceded tubularisation (D). The neourethral tubularisation is completed (E).

after having made an adequate diameter, and was closed in two layers with a 7/0 polyglactin suture. The neomeatus was constructed over a catheter of 2-F larger than that used as a stent. In this method, the creation of the meatus precedes tubularisation (Fig. 1A–E). The dorsal dartos flap was harvested from the prepuce and penile skin, and used for covering the neourethra (Fig. 2A–E). A single dartos flap was button-holed, transposed to the ventral aspect of the penile shaft and tacked to the glanular recess. In cases with double coverage, the dartos flap was made long enough to be rolled ventrally around the penile shaft from either side after being divided vertically. A nearly identical surgical technique using the same suture materials was applied in all patients by the three surgeons in the study (Fig. 3).

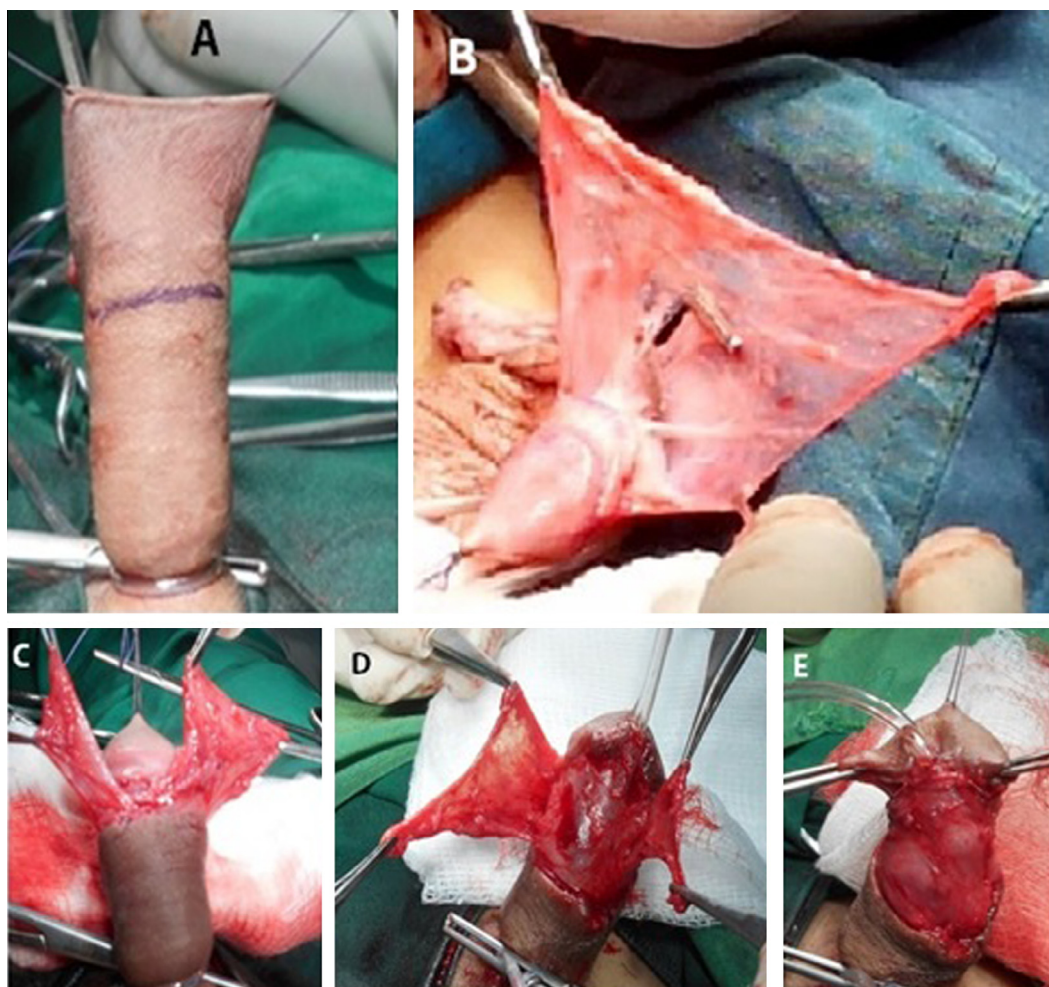
To minimise the risk of visible suture tracks, all skin surfaces were sutured using a subepithelial technique

[16]. An intermittent tourniquet was used for intraoperative haemostasis. An 8- or 10-F urethral stent was left for 7–10 days, with a compressive dressing applied and removed on the second day after surgery. A third-generation cephalosporin was given to all patients until the urethral stent was removed. Patients were examined weekly for 1 month then every month thereafter. The urinary stream was assessed by observation during voiding. If the urinary stream was narrow, or there was an obvious tendency to meatal stenosis, regular meatal dilation was initiated daily for 2 weeks, then weekly for 2 months [4].

#### Objective evaluation

The functional and cosmetic outcomes were assessed at 3 months after surgery. The functional outcome was



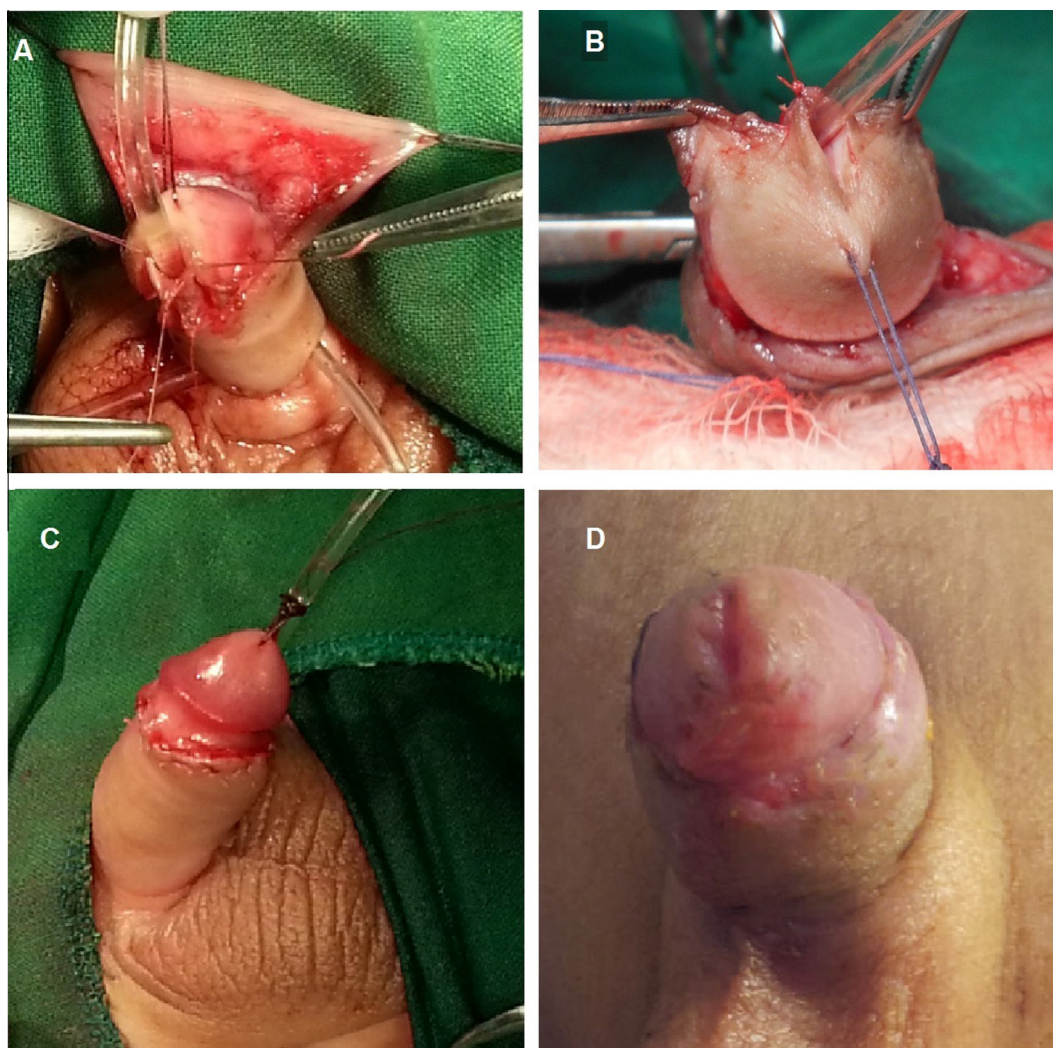


**Figure 2** Harvesting of the dorsal dartos flap, which can be button-holed for single-layer coverage (B) or divided vertically for two-layer coverage (C–E).

assessed by uroflowmetry using a rotating-disk system (Urodyn 1000, Dantec Medical A/S, Skovlunde, Denmark) and ultrasonography was used to estimate the postvoid residual urine volume (PVR). The uroflowmetry was done for toilet-trained boys, excluding those with complications and those who required dilatation. The shape of the flow curve, the maximum ( $Q_{\max}$ ) and average flow rate ( $Q_{\text{ave}}$ ) at a voided volume of  $>50$  mL, the voiding time and time to  $Q_{\max}$  were assessed. The uroflow data were plotted against an age-related flow rate nomogram for normal children aged 5–15 years [17]. The functional outcome was considered unfavourable in the presence of a plateau curve, a  $Q_{\max}$  below the fifth percentile range in the age-related flow rate nomogram, or a PVR of  $>10\%$  of the voided volume [18].

Cosmesis was evaluated using the HOSE score [15] by an independent urological surgeon, or a nurse and one of the parents, all unaware of the operating surgeon. The scoring system was designed so that the minimum total score would be 5, corresponding to a lowest score

for each variable, up to a maximum total of 16, equivalent to the highest score for each variable. A score of  $\geq 14$  was considered acceptable. Two elements of cosmetic importance not included in HOSE score were also assessed, i.e., the shape of the glans and the penile axis (curvature and torsion), evaluated according to the previously reported standards. The normal glans is acorn-shaped with a solid bridge of normal-looking glans tissue proximal to the meatus, with no scars, asymmetry or irregularities [7]; an abnormal glans shape was classified as mild, moderate or severe [19]. The penile axis should be straight with no curvature or torsion. The degree of penile torsion based on the orientation of the urethral meatus relative to the vertical position (usually counter clockwise) was classified as mild ( $<45^\circ$  of torsion), moderate ( $45\text{--}90^\circ$  of torsion) and severe ( $>90^\circ$  of torsion) [20]. In addition to the shape of the glans and penile axis, the direction of the urinary stream was also assessed; misdirection of the urinary stream is probably caused by an ectopic or abnormally shaped meatus, stricture, or fistula [21].



**Figure 3** The construction of a wide neomeatus at the tip of the glans; ventral view (A), top view (B). The intra-operative cosmetic outcome (C). The cosmetic outcome at 3 months after surgery, with a vertical slit-like meatus at the tip of a normal conical symmetrical glans.

Descriptive statistics for continuous variables were expressed as the mean (SD). The age and follow-up period were not normally distributed, and thus data were expressed as the median and interquartile range. Categorical variables were expressed as the number and percentage. Student's *t*-test, the Pearson chi-square test and Fisher's exact test were used to compare continuous and categorical data as appropriate, with  $P < 0.05$  considered to indicate statistical significance, and all statistical tests were two-sided.

### Results

The median age at the time of repair was 4.2 (0.5–14) years. The native meatus was coronal in 11 (26%) patients, subcoronal in 23 (53%) and distal penile in nine (21%). The mean (SD, range) urethral plate length

was 15.7 (2.3, 12–20) mm, the urethral plate width 7.9 (1.2, 5–11) mm and the transverse glans width 14.5 (1.9, 11–22) mm. Eleven patients (26%) had a small glans ( $< 14$  mm) with a mean of 12.5 (0.7, 11–13) mm, while 32 (74%) had a normal width of  $\geq 14$  mm, with a mean of 14.5 (1.9, 14–22) mm. The urethral plate was shallow in 11 of the 43 patients (26%), moderately grooved in 22 (51%) and deeply grooved in 10 (23%). Four patients had chordee that was limited to either the skin, dartos fascia or peri-urethral tissue, and after degloving, the chordee was corrected. A single-layer coverage was applied in 25 (58%) boys, while in 18 (42%) a double-layer coverage was used.

Over a median follow-up of 6 (3–24) months, uroflow data were available in 26 asymptomatic toilet-trained boys, after excluding those using diapers, with complications and those who were lost to follow-up. The median



**Table 2** The functional and cosmetic outcomes as measured by uroflowmetry and HOSE score of the 26 boys assessed.

Variable	Mean (SD, range) or n (%)
<i>Postoperative uroflow (26 boys)</i>	
Voiding time (s)	23 (8.3, 11–40)
Time to $Q_{\max}$ (s)	8.1 (5.3, 3–27)
$Q_{\max}$ (mL/s)	12.5 (3, 7.6–19.5)
$Q_{\text{ave}}$ (mL/s)	7 (1.8, 4.1–10.9)
Voided volume (mL)	166.6 (67.8, 71–344)
PVR (mL)	5.7 (8.1, 0–25)
<i>Postoperative HOSE score (43 boys)</i>	
Meatal location	
Distal glans	39 (91)
Proximal glans	4 (9)
Meatal shape	
Vertical slit	42 (98)
<i>Urinary stream</i>	
Single	43 (100)
<i>Erection</i>	
Straight	42 (98)
Mild angulation < 10°	1 (2)
Fistula (single subcoronal)	2 (5)

(range) age at the time of uroflowmetry was 5.2 (3.3–14) years. The uroflowmetry data are shown in Table 2. The  $Q_{\max}$  and  $Q_{\text{ave}}$  were plotted against the voided volume nomogram for normal children aged 5–15 years old (Fig. 4A and B), and it was apparent that the results tended to cluster below the 50th percentile. Four boys had a  $Q_{\max}$  below the fifth percentile while their  $Q_{\text{ave}}$  was above the fifth percentile. The curves (Fig. 5A–E) were bell-shaped in nine (35%) boys, interrupted or intermittent in five (19%), slightly flattened in 10 (39%) and a plateau in two (8%). Table 3 shows the functional outcomes in the 26 asymptomatic toilet-trained boys. The shape and diameter of the urethral plate were significantly associated with obstructed criteria on the nomogram. The mean (SD) urethral plate width was 6.5 (0.6) mm in obstructed patients and 8.5 (1.1) mm in those above the fifth percentile ( $P = 0.002$ , Student's *t*-test). There was a PVR of > 10% of the voided volume in three boys, but it was insignificantly different in relation to the studied variables.

Acceptable cosmetic results were obtained in 42 (98%) of the boys, with a HOSE score of  $\geq 14$ . The mean (SD, range) HOSE score after surgery was 15.8 (0.6, 13–16). The detailed results for each variable in the 43 patients are shown in Table 2. There was a urethrocutaneous fistula (UCF) in two boys. The fistula was small (2 mm), subcoronal and appeared after removing the stent. One boy had a total HOSE score of 13, with a vertical slit meatus located at the proximal glans, a single urinary stream (although misdirected downward) and mildly angled erection (< 10°). The second boy had a HOSE score of 14, with a vertical slit

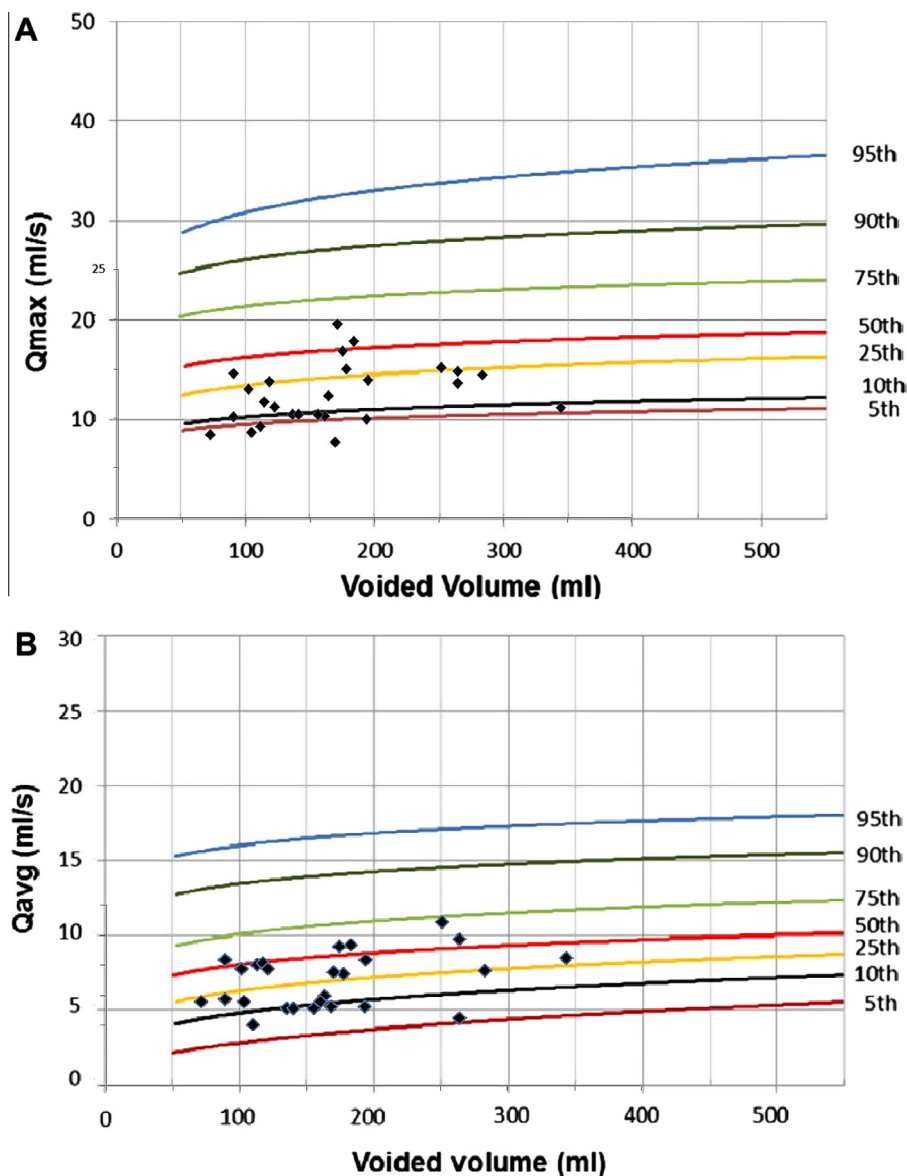
meatus located at the proximal glans, a single urinary stream (also misdirected downward), and a straight erection. Of 11 patients with a shallow plate, the UCF developed in two ( $P = 0.047$ ; Chi-square test). According to the intraoperative situation, a single-layer dorsal dartos flap was used in 25 boys and a double dorsal dartos flap in 18. The UCF occurred in two of the 25 patients with a single-layer coverage. There was no significant difference between these groups ( $P = 0.501$ , Fisher's exact test).

For the additional cosmetic variables assessed, four patients with penile torsion (< 45° of counter-clockwise torsion) were corrected by a single dartos flap rotated and sutured to the penile shaft in the opposite direction to the torsion. One showed a persistent torsion of < 30°. This was slit-like but not vertical nor circular, hence the HOSE score was assigned as 15 for that patient. A glans of acorn shape, symmetrical with no prominent scars or masses, was achieved in all cases when considering the repair of mucosal collars. A forward-directed urinary stream was attained in all boys except four (9%), in whom there was a downward angled stream (misdirected), as the meatus was located at the proximal glans. A small glans and narrow urethral plate was found that required suturing of the plate a little more proximally to create a wide neomeatus.

## Discussion

Most paediatric surgeons now prefer to use the TIP to repair distal and mid-shaft hypospadiac defects [2]. The urethral plate is vascularised tissue with a good muscular backing, a rich nerve supply and able to form periurethral glands, which explains the success of the procedure [22]. Many modifications to the original procedure are reported that could further limit the risk of complications like meatal stenosis and UCF. In the present study we adopted the modified Snodgrass technique introduced by Jayanthi [14]. The midline relaxing incision was not limited to the urethral plate, but extended further distally to the tip of the glans, and the neourethral tubularisation was started from distal to proximal in a way that allows for the construction of a slit-like meatus at the glans tip. This modification was used by Jayanthi [14] in the repair of 110 boys with primary hypospadias, aged 5–60 months. None of the patients had meatal stenosis, but only one had a UCF. To the best of our knowledge, the functional and cosmetic outcomes of this modified technique have not previously been assessed. Uroflowmetry, the HOSE score, and other cosmetic features were used in the present study to assess the functional and cosmetic outcomes of the modified Snodgrass technique.

Snodgrass et al. [7] suggested that the urethral plate incision should not be extended to the tip of the glans, fearing that this could lead to meatal stenosis. However,



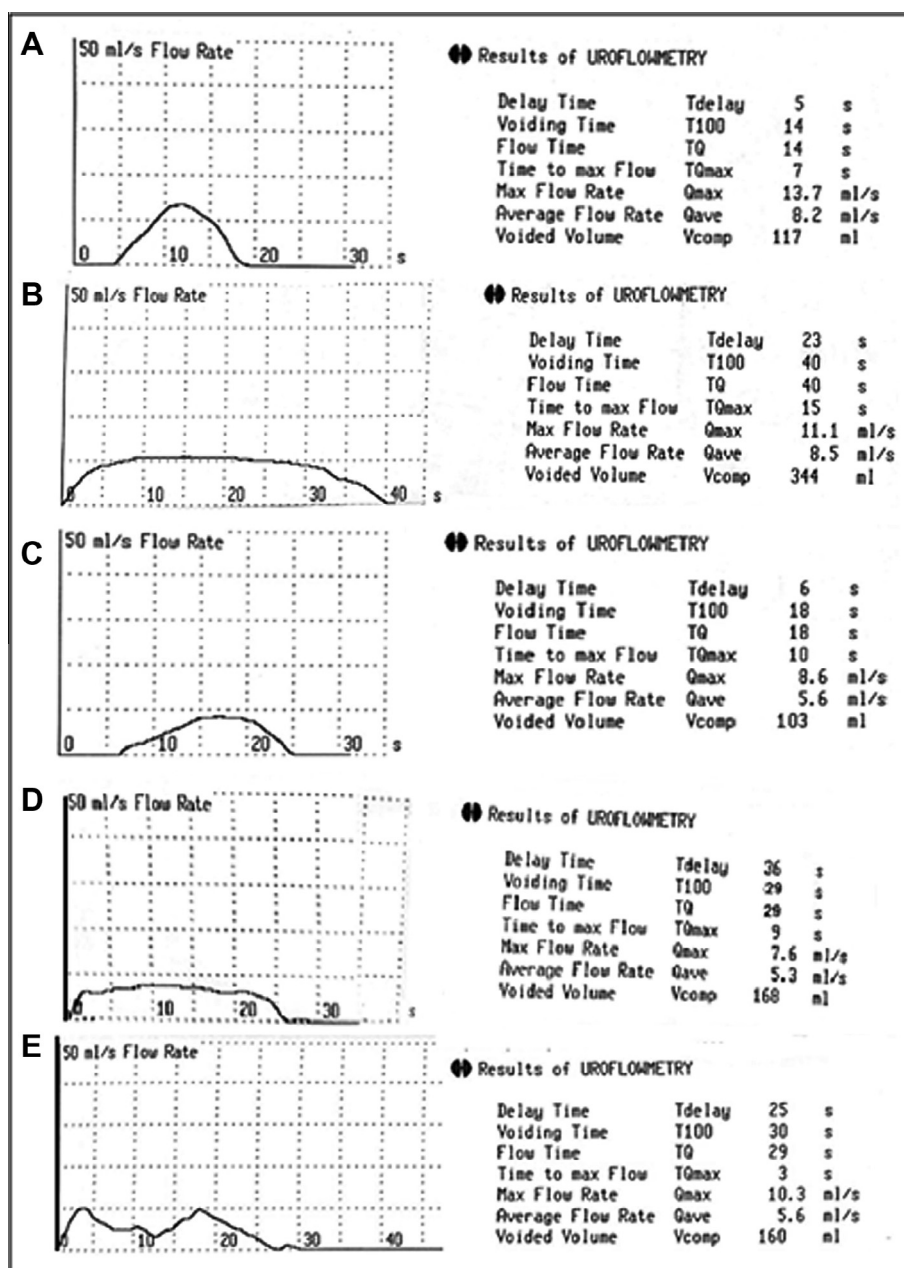
**Figure 4** (A) The  $Q_{max}$  plotted against the voided volume in 26 boys; four were below the fifth percentile, according to the nomogram [18]. (B) The  $Q_{ave}$  plotted against the voided volume, with no patients having values below the fifth percentile.

a histological study showed that under the urethral plate there was healthy, vascularised connective subepithelial tissue [11] and no evidence that subepithelial tissue at the tip of the glans is different from that under the true urethral plate [14].

Holland and Smith [23] suggested that the use of the TIP in boys with inherently narrow urethral plates (<8 mm) leads to a greater risk of complications. They noted that the possibility of a UCF increases with a shallow glans of <8 mm wide, and there was no objective evidence that the relaxing incision actually increased the true width of the final neourethra. Snodgrass [24] stated that a relaxing incision also varies from a deep incision for a shallow groove to no incision for a deep

groove, and that the results of Holland and Smith might be because the relaxing incisions were not made deeply enough. In the present study, the procedure was applied in 11 patients with a shallow (flat) plate, and in two with a narrow plate (6 mm) and a glanular transverse diameter of <14 mm, who subsequently developed a UCF.

Hypospadias repair should be evaluated both functionally and cosmetically. A urinary flow study has gained an important role in the follow-up of hypospadias surgery as a noninvasive tool to assess urethral function [25]. In the present study, 26 patients were eligible for uroflowmetry, with a median (range) age of 5.2 (3.3–14) years at the time of uroflowmetry. The data shown in Table 2 tend to be at the lower limit for normal



**Figure 5** The postoperative uroflow patterns. (A) A bell-shaped curve with a normal  $Q_{\max}$ . (B) A flat curve with a normal  $Q_{\max}$ . (C) An almost bell-shaped curve with an obstructed  $Q_{\max}$  but normal  $Q_{\text{ave}}$ . (D) A plateau curve with an obstructed  $Q_{\max}$  and normal  $Q_{\text{ave}}$ , and a prolonged voiding time. (E) An intermittent curve with a  $Q_{\max}$  at the fifth and  $Q_{\text{ave}}$  at the tenth percentile.

children, as reported by Segura [26] from 1361 uroflowmetry tests obtained from healthy children aged 3–14 years, except for the mean flow time, that was prolonged in the present series.

In a systematic review of reports addressing the importance of uroflowmetry studies after TIP repair, 11 reported obstructive flow in 24.6% of patients (93 of 378) where obstruction was defined as a plateau curve or a  $Q_{\max}$  below the fifth percentile of a standard nomogram [25]. A flow nomogram recently proposed by Gupta et al. [17] was obtained from one of the largest studies that constructed nomograms from boys aged

5–15 years, and allows an interpretation of the  $Q_{\max}$  and  $Q_{\text{ave}}$  at different voided volumes. Hence the  $Q_{\max}$  and  $Q_{\text{ave}}$  values from the present study were plotted on this nomogram for interpretation.

Many authors have addressed the functional outcome after TIP urethroplasty by using uroflowmetry [3,27–29], with different definitions for obstruction and using different nomograms. In a study by Snodgrass [3], 17 patients who were repaired using a TIP urethroplasty (14 distal and three penoscrotal) were followed over a mean period of 45 months; the author reported that all of them had flow rates within the 95th percentile on the



**Table 3** The functional outcomes, as n (%), in relation to transverse glans diameter, urethral plate criteria, and neourethral coverage.

Variable (n)	Nomogram percentile (n)		Flow rate curve (n)				PVR (n)	
	< 5th (4)	> 5th (22)	Bell (9)	Intermittent (5)	Plateau (2)	Flattened (10)	> 10% (3)	< 10% (23)
<i>Transverse glans diameter (mm)</i>								
< 14 (3)	1 (4)	2 (8)	1 (4)	1 (4)	0	1 (4)	1 (4)	2 (8)
≥ 14 (23)	3 (12)	20 (77)	8 (31)	4 (15)	2 (8)	9 (35)	2 (8)	21 (81)
P		0.408 <sup>b</sup>		0.888 <sup>b</sup>				0.319 <sup>b</sup>
<i>Urethral plate</i>								
Shape								
Shallow (9)	4 (15)	5 (19)	4 (15)	1 (4)	1 (4)	3 (12)	1 (4)	8 (31)
Moderate (11)	0	11 (42)	5 (19)	3 (12)	1 (4)	2 (8)	1 (4)	10 (39)
Deep (6)	0	6 (23)	0	1 (4)	0	5 (19)	1 (4)	5 (19)
P		0.012 <sup>a</sup>		0.210 <sup>a</sup>				0.895 <sup>a</sup>
Diameter (mm)								
< 8 (7)	4 (15)	3 (12)	3 (12)	1 (4)	1 (4)	2 (8)	1 (4)	6 (23)
≥ 8 (19)	0	19 (73)	6 (23)	4 (15)	1 (4)	8 (31)	2 (8)	17 (65)
P		0.002 <sup>b</sup>		0.778 <sup>b</sup>			1.0 <sup>b</sup>	
<i>Neourethral coverage</i>								
Single (13)	2 (8)	11 (42)	3 (12)	2 (8)	2 (8)	6 (23)	1 (4)	12 (46)
Double (13)	2 (8)	11 (42)	6 (23)	3 (12)	0	4 (15)	2 (8)	11 (42)
P		1 <sup>b</sup>		0.308 <sup>b</sup>			1 <sup>b</sup>	

<sup>a</sup> Chi-square test.<sup>b</sup> Fisher's exact test.

Gaum nomogram [30]. Marte et al. [27] had two (13%) obstructed cases of 15 with mid-penile hypospadias repaired with a TIP, where obstruction was defined as a  $Q_{\max}$  below the fifth percentile on Toguri nomograms [31]. Their uroflow data showed a  $Q_{\max}$  of 5–18.7 mL/s, a  $Q_{\text{ave}}$  of 3.3–11.8 mL/s, and a voided volume of 64–169 mL, in agreement with data in the present study. In another study, Hammouda et al. [28] found a low  $Q_{\max}$  (two SD below the normal mean for age) using the Gaum nomogram [30], with a flat curve in 15/48 (31%), and after an intermediate follow-up of 2 years. They found a significant PVR of > 10% of the voided volume in two (4.2%) patients. Eassa et al. [29], assessing the repair of 50 boys with distal hypospadias and nine with mid- and proximal penile hypospadias, reported a mean (SD, range)  $Q_{\max}$  of 12 (4.9, 4.5–34.8) mL/s, a voided volume of 156 (70, 86–353) mL and a PVR of 20 (19.5, 0–72) mL. The flow patterns were bell-shaped in 18 (30%), interrupted in eight (14%), slightly flattened in 27 (46%) and a plateau in six (10%). The  $Q_{\max}$  was below the fifth percentile in 15%, using the Gaum nomogram, and there was a significant PVR in 15%. The present results are comparable to those reported by the previous studies [27–29] for the uroflow data obtained after TIP urethroplasty, as is the tendency to cluster in the lower 50th percentile. For unfavourable outcome variables in the present patients, the  $Q_{\max}$  was below the fifth percentile in four (15%) boys, with a plateau curve in two (8%) boys and a PVR of > 10% of voided volume in three (12%). In the two boys with a plateau curve, one had a  $Q_{\max}$  below the fifth percentile, while the other had a

value between the fifth and 10th percentiles. The  $Q_{\text{ave}}$  for all boys was above the fifth percentile (Fig. 4). The transverse glans diameter and neourethral coverage did not affect the functional outcome, while the urethral plate characteristics were the significant factors (Table 3). Similar to the previous studies [27–29], there was a slightly flattened curve in 10 boys (39%), which denotes a prolonged flow time. This was explained by the lower elasticity of the neourethra in the absence of a true stricture and meatal stenosis [32]. In the present study, the functional outcome as assessed by the uroflow data showed that the reconstructed neourethra was functionally normal after using the modified technique.

The HOSE score is a reproducible objective outcome measure after hypospadias surgery, and independent of the initial severity of the defect. The five objective elements of the score were developed to assess the functional outcome, i.e., a single urinary stream, straight penis and absence of fistula, together with the current emphasis on a repair which is also aesthetic, i.e., a vertically orientated, slit-like meatus near the tip of the glans [15]. The functional and cosmetic results in Table 2 show a mean (SD, range) HOSE score of 15.8 (0.6, 13–16). A vertical slit-like meatus was achieved in 42 of the 43 patients (98%) and was at the distal glans in 39 (91%), while in four the meatus was at the proximal glans due to the need to start tubularisation slightly lower down with a shallow urethral groove. Of those boys, two had a UCF soon after surgery that resolved spontaneously after frequent dilatation, with no need for surgical repair. The two boys had a small glans, the tube covered by a single layer, and an early appearance

of the UCF. In one the UCF appeared early after stent removal at 7 days after surgery. Elbakry [33] thoroughly enumerated and explained the many factors that could be responsible for poor healing and UCF formation, e.g., the mechanical and humoral impairment factors, highlighting the technical errors causing tissue ischaemia [34], and any of these factors could be the cause of UCF in the present series. Suture tracks could be a predisposing factor and subcuticular placement or suturing should be used [16]. Edney et al. [35] postulated that the appearance of a fistula soon after surgery was a result of the inward migration of dermal epithelium and outward migration of urethral mucosa. In all boys, there was a single urinary stream, although it was angled in four due to the location of the meatus on the proximal glans.

There are several limitations to the present study. There was no comparison with the standard technique, relatively few patients and a relatively short follow-up. Further studies are required to address these issues.

In conclusion, the modified Snodgrass technique ensures the creation of a vertical slit-like, wide neomeatus located at the tip of the glans, emulating the normal anatomy. The uroflowmetry results showed a normal voiding function with a mean  $Q_{max}$  of 12.5 mL/s and a normal  $Q_{ave}$ . The cosmetic outcome was good, with a mean HOSE score of 15.8. Comparative studies, especially with the standard technique, are required to determine the role of this procedure in repairing distal hypospadias.

### Conflict of interest

None.

### Funding

None.

### References

- [1] Snodgrass WT. Tubularized incised plate urethroplasty for distal hypospadias. *J Urol* 1994;**151**:464–5.
- [2] Cook A, Khoury AE, Neville C, Bagli DJ, Farhat WA, Pippi Salle JL. A multicenter evaluation of technical preferences for primary hypospadias repair. *J Urol* 2005;**174**:2354–7.
- [3] Snodgrass WT. Does tubularized incised plate hypospadias repair create neourethral strictures? *J Urol* 1999;**162**:1159–61.
- [4] Elbakry A. Tubularized-incised urethral plate urethroplasty: is regular dilatation necessary for success? *BJU Int* 1999;**84**:683–6.
- [5] Hayes MCC, Malone PS. The use of dorsal buccal graft with urethral plate incision (Snodgrass) for hypospadias salvage. *BJU Int* 1999;**83**:508–9.
- [6] Elbakry A. Further experience with tubularized incised plate. *BJU Int* 2002;**89**:291–4.
- [7] Snodgrass WT, Nguyen MT. Current technique of tubularized incised plate hypospadias repair. *Urology* 2002;**60**:157–62.
- [8] Snodgrass WT. Snodgrass technique for hypospadias repair. *BJU Int* 2005;**95**:683–93.
- [9] Cheng EY, Vemulapalli N, Kropp BP, Pope 4th JC, Furness 3rd WE, Kaplan WE, et al. Snodgrass hypospadias repair with vascularized flap. The perfect repair for virgin cases of virgin hypospadias? *J Urol* 2002;**168**:1723–6.
- [10] Hayashi Y, Kojima Y, Mizuno K, Kurokawa S, Nakane A, Kohri K. Achieving a natural glanular meatus for distal hypospadias with a narrow and shallow plate: tubularized incised plate versus modified Barcat repair. *Int J Urol* 2008;**15**:616–20.
- [11] Snodgrass WT, Patterson K, Plaire JC, Grady R, Mitchell ME. Histology of the urethral plate: implications for hypospadias repair. *J Urol* 2000;**164**:988–9.
- [12] Genç A, Taner C, Öksel F, Balkan C, Bilgi Y. Analysis of meatal location in 300 boys. *Int Urol Nephrol* 2001;**33**:663–4.
- [13] Hutton KAR, Babu R. Normal anatomy of the external urethral meatus in boys: implications for hypospadias repair. *Br J Urol* 2007;**100**:161–3.
- [14] Jayanthi VR. The modified Snodgrass hypospadias repair: reducing the risk of fistula and meatal stenosis. *J Urol* 2003;**170**:1603–5.
- [15] Holland AJ, Smith GH, Ross FI, Cass DT. HOSE: an objective scoring system for evaluating the results of hypospadias surgery. *BJU Int* 2001;**88**:255–8.
- [16] Snodgrass WT. Suture tract after hypospadias surgery. *BJU Int* 1999;**84**:843–4.
- [17] Gupta DK, Sankhwar SN, Goel A. Uroflowmetry nomograms for healthy children aged between 5 and 15 years. *J Urol* 2013;**190**:1008–14.
- [18] Jayanthi VR, McLorie GA, Khoury AE, Churchill BM. Functional characteristics of the reconstructed neourethra after island flap urethroplasty. *J Urol* 1995;**153**:1657–5.
- [19] van der Toorn F, de Jong TP, de Gier RP, Callewaert PR, van der Horst EH, Steffens MG, et al. Introducing the HOPE (Hypospadias Objective Penile Evaluation) score. A validation study of an objective scoring system for evaluating cosmetic appearance in hypospadias patients. *J Pediatr Urol* 2013;**9**:1006–16.
- [20] Fisher PC, Park JM. Penile torsion repair using dorsal dartos flap rotation. *J Urol* 2004;**171**:1903–4.
- [21] Manzoni G, Bracka A, Palminteri E, Marrocco G. Hypospadias surgery. When, what and by whom? *BJU Int* 2004;**94**:1188–95.
- [22] Erol A, Baskin LS, Li YW, Liu WH. Anatomical studies of the urethral plate: why preservation of the urethral plate is important in hypospadias repair. *BJU Int* 2000;**85**:728–34.
- [23] Holland AJ, Smith GH. Effect of depth and width of the urethral plate on tubularized incised plate urethroplasty. *J Urol* 2000;**164**:489–93.
- [24] Snodgrass WT. Re. Effect of depth and width of the urethral plate on tubularized incised plate urethroplasty. *J Urol* 2001;**166**:633.
- [25] Gonzaliz R, Ludwikowski BM. Importance of urinary flow studies after hypospadias repair: a systematic review. *Int J Urol* 2011;**18**:757–61.
- [26] Segura CG. Urine flow in childhood. a study of flow chart parameters based on 1361 uroflowmetry studies. *J Urol* 1997;**157**:1426–8.
- [27] Marte A, Di Iorio G, De Pasquale M, Cotrufo AM, Di Meglio D. Functional evaluation of tubularized-incised plate repair of midshaft-proximal hypospadias using uroflowmetry. *BJU Int* 2001;**87**:540–3.
- [28] Hammouda HM, El-Ghoneimi A, Bagli DJ, McLorie GA, Khoury AE. Tubularized incised plate repair: functional outcome after intermediate followup. *J Urol* 2003;**169**:331–3.
- [29] Eassa W, Brzezinski A, Capolicchio JP, Jednak R, El-Sherbiny M. How do asymptomatic toilet-trained children void following tubularized incised-plate hypospadias repair? *Can Urol Assoc J* 2012;**6**:238–42.
- [30] Gaum LD, Wese FX, Liu TP, Wong AK, Hardy BE, Churchill BM. Age related flow rate nomograms in a normal pediatric population. *Acta Urol Belg* 1989;**57**:457–66.
- [31] Toguri AG, Uchida T, Bee DE. Pediatric uroflow rate nomograms. *J Urol* 1982;**127**:727–31.

- [32] Braga LH, Pippi Salle JL, Lorenzo AJ, Skeldon S, Dave S, Farhat WA, et al. Comparative analysis of tubularized incised plate versus onlay island flap urethroplasty for penoscrotal hypospadias. *J Urol* 2007;**178**:1451–7.
- [33] Elbakry A. Tissue interposition in hypospadias repair: a mechanical barrier or healing promoter? *Arab J Urol* 2011;127–8.
- [34] Elbakry A. Management of urethrocutaneous fistula after hypospadias repair: 10 years' experience. *BJU Int* 2001;**88**: 590–5.
- [35] Edney MT, Lopes JF, Schned A, Ellsworth PI, Cendron M. Time course and histology of urethrocutaneous fistula formation in a porcine model of urethral healing. *Eur Urol* 2004;**45**:806–10.