



Acute adrenal haemorrhage in two cats with aldosterone-secreting adenocarcinomas

Nicolle Kirkwood, Lara Boland, Laurencie Brunel, Alison Wardman and Vanessa R Barrs

Journal of Feline Medicine and Surgery Open Reports
1–5

© The Author(s) 2019
Article reuse guidelines:
sagepub.com/journals-permissions
DOI: 10.1177/2055116919840828
journals.sagepub.com/home/jfmsopenreports

This paper was handled and processed by the European Editorial Office (ISFM) for publication in *JFMS Open Reports*



Abstract

Case summary Two 13-year-old domestic shorthair cats were diagnosed with unilateral right adrenocortical carcinomas (ACCs) and primary hyperaldosteronism (PHA). Both had polyuria, polydipsia and weight loss, and developed severe anaemia from an episode of acute adrenal haemorrhage. In one case, this occurred during hospitalisation and treatment of severe muscle weakness with cervical ventroflexion, while the other cat had acute collapse at home. A diagnosis of PHA was confirmed in both cases based on measurement of plasma aldosterone and renin activity. In one case, basal progesterone was also measured and was elevated. On ultrasonography and CT in one case, haemorrhage into the right retroperitoneal space was identified. Unilateral adrenalectomy was performed in both cases and there was no evidence of venous tumoral invasion in either. On histopathology of the excised adrenal glands both were ACCs with tumour necrosis, and one had extensive intratumoral haemorrhage. Both cats were diagnosed with International Renal Interest Society stage 2 or 3 chronic kidney disease postoperatively; one survived for 18 months and the other was well 8 months postoperatively.

Relevance and novel information Acute adrenal haemorrhage secondary to adrenal neoplasia has been reported in only one other cat, in which tumour type and function were not specified. Acute adrenal haemorrhage can occur as a consequence of tumour necrosis and rupture and can cause severe hypovolaemia and anaemia in cats with primary hyperaldosteronism.

Keywords: Hyperaldosteronism; adrenocortical carcinoma; haemorrhage

Accepted: 5 March 2019

Introduction

Aldosterone-secreting adrenal tumours are increasingly recognised in cats.^{1–4} Here we report life-threatening acute adrenal haemorrhage in two cats with aldosterone-secreting adrenal carcinomas. Case 1, diagnosed in 2017 is described in detail, while Case 2, diagnosed in 2003, was similar and is presented in summary.

left parasternal systolic murmur was auscultated, the haircoat was unkempt with a heavy flea burden and the abdomen appeared mildly pendulous. Six weeks previously, the cat had presented with pollakiuria and polydipsia. Bacterial cystitis due to *Escherichia coli* was diagnosed and pollakiuria resolved after a single dose of

Case description

Case 1

A 13-year-old female spayed domestic shorthair (DSH) cat was presented for polyphagia, polyuria and polydipsia (PUPD) and weight loss (day 1). The cat weighed 4.3 kg (body condition score 4/9) and had lost 1 kg in body weight over the previous 6 months. A grade II/VI

Valentine Charlton Cat Centre, University Veterinary Teaching Hospital, Sydney School of Veterinary Science, Faculty of Science, University of Sydney, NSW, Australia

Corresponding author:

Vanessa R Barrs BVSc, PhD, MVetClinStud, FANZCVS (Feline Medicine), Sydney School of Veterinary Science, Faculty of Science, University of Sydney, NSW 2006, Australia
Email: vanessa.barrs@sydney.edu.au



Creative Commons Non Commercial CC BY-NC: This article is distributed under the terms of the Creative Commons

Attribution-NonCommercial 4.0 License (<http://www.creativecommons.org/licenses/by-nc/4.0/>) which permits non-commercial use, reproduction and distribution of the work without further permission provided the original work is attributed as specified on the SAGE and Open Access pages (<https://us.sagepub.com/en-us/nam/open-access-at-sage>).

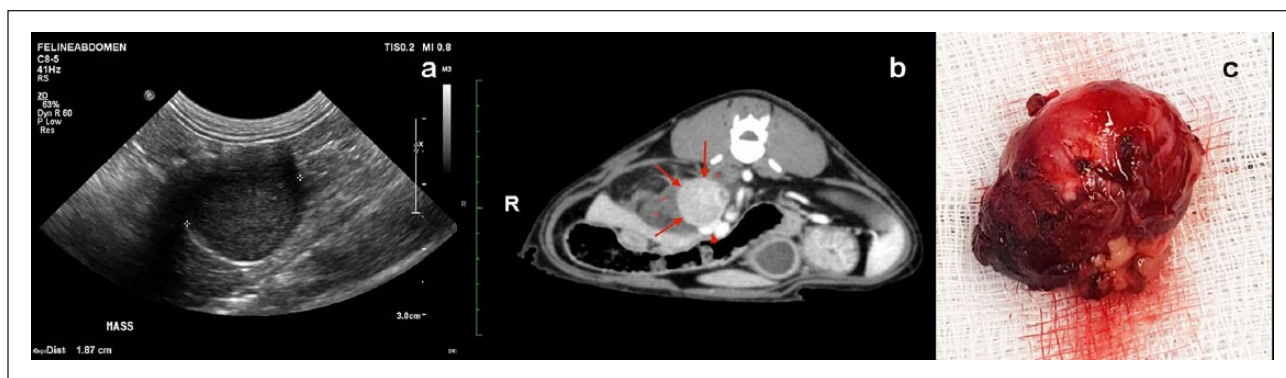


Figure 1 Case 1. (a) Discrete, enlarged, rounded right adrenal gland (18.7 mm), the day before an episode of acute haemorrhage. (b) Preoperative CT examination of the abdomen, post-contrast. A strongly enhancing right adrenal mass (arrows) is surrounded by a poorly defined non-contrast-enhancing area of hypoattenuation (asterisks), extending between the renal fossa of the caudate lobe of the liver to the right renal vein. There is ventral displacement and compression of the caudal vena cava (arrowhead). (c) The excised adrenal gland with an adherent peripheral haematoma

cefevecin subcutaneously (8 mg/kg) (Convenia; Zoetis). At that time, there was mild azotaemia (creatinine 187 $\mu\text{mol/l}$ and urea 11.46 mmol/l; reference intervals [RIs] 90–180 $\mu\text{mol/l}$ and 7.2–10.7 mmol/l, respectively) and hypokalaemia (3.1 mmol/l; RI 4.0–4.6 mmol/l), and urine specific gravity (USG) was 1.014.

Haematology results on day 1 were within the RIs. Abnormalities on serum biochemistry included hypokalaemia (3.1 mmol/l; RI 3.7–5.4 mmol/l), metabolic alkalosis (bicarbonate 25 mmol/l; RI 12–24 mmol/l) and elevated creatinine kinase (CK; 5569 IU/l [RI 64–400 IU/l]). Urea (9.1 mmol/l; RI 5.0–15.0 mmol/l), creatinine (110 $\mu\text{mol/l}$; RI 80–200 $\mu\text{mol/l}$) and symmetrical dimethylarginine (8 $\mu\text{g/dl}$; RI 0–14) were not elevated. Primary hyperaldosteronism was suspected owing to the presence of PUPD, weight loss, persistent hypokalaemia, metabolic alkalosis and elevated CK. Further investigation, including systolic arterial blood pressure (SABP) measurement, abdominal ultrasonography and plasma aldosterone:renin measurement were recommended.

Two days later (day 3), the cat re-presented with marked cervical ventroflexion and was mildly dehydrated (body weight 4.23 kg). SABP (Doppler method) was 150 mmHg and funduscopy was unremarkable. On urinalysis, USG was 1.015 and urine sediment was benign. Blood was collected for basal aldosterone, progesterone and renin assays. On abdominal ultrasonography the right adrenal gland was enlarged, rounded and discrete (19 mm diameter) (Figure 1). The left adrenal gland appeared normal (cranial pole height 3.4 mm, caudal pole height 3.5 mm, length 11 mm).

The cat was hospitalised (day 3) and treatment was commenced with spironolactone (6.25 mg PO q24h) and potassium gluconate (4 mmol PO q12h). Intravenous fluid therapy (IVFT) was not administered owing to financial constraints and the cat ate on

admission to hospital. However, on day 4, weakness and dehydration worsened (body weight 4.1 kg). Despite a stable packed cell volume (PCV; 0.30 l/l [RI 0.30–0.45]), total serum protein (TSP) increased (90 g/l; RI 39–78 g/l), hypernatremia developed (167 mmol/l; RI 147–156 mmol/l) and hypokalaemia worsened (2.9 mmol/l; RI 4.0–4.6 mmol/l). SABP was also elevated at 180 mmHg. Crystalloid IVFT (Hartmann's solution) at 13 ml/h and potassium chloride (KCl) at 0.4 mmol/kg/h IV was commenced. Spironolactone was continued and potassium gluconate was increased to 4 mmol PO q4h. After 4 h, potassium was 3.9 mmol/l and KCl supplementation was reduced to 0.13 mmol/kg/h IV.

On day 5 body weight had increased by 400 g, and the cat became tachycardic (heart rate 260 beats/min) and tachypnoeic (respiratory rate 60 breaths/min). Initially, fluid overload was suspected. However, on physical examination several hours later mucous membranes were pale, PCV (0.13 l/l) and TSP (52 g/l) had decreased markedly, and SABP was 150 mmHg. Serum potassium was 3.6 mmol/l and sodium was 160 mmol/l. Acute haemorrhage from the adrenal mass was suspected. Repeat abdominal ultrasonography revealed a new 5 cm diameter heterogeneous area, in the right retroperitoneal space adjacent to the enlarged right adrenal gland (17 mm diameter). Free fluid was also present in the right retroperitoneal space, and there was scant free fluid between liver lobes. These findings were consistent with a periadrenal haematoma and haemorrhage into the retroperitoneal space and peritoneal cavity. Possible causes were considered to be rupture of the mass or neoplastic invasion of adrenal vessels with erosion of the vessel wall. There was no evidence of coagulopathy – prothrombin and partial thromboplastin times and platelet count were within the RIs.

Blood typing was performed (Quick Test; Alvedia Veterinary Diagnostics) and the cat was blood type B, for which no immediate donor was available. Supportive therapy with IVFT, KCl and spironolactone were continued, and the flea burden was treated with nitenpyram 11.4 mg PO (Capstar; Novartis), then topical imidacloprid (Advocate; Bayer). From days 6 to 8 the cat was clinically stable, cervical ventroflexion resolved, polyphagia returned, SABP ranged from 110–140 mmHg, PCV and TSP increased to 17 l/l and 75 g/l, respectively, and the median serum potassium was 3.8 mmol/l.

Results of endocrine testing confirmed hyperaldosteronism and hyperprogesteronism; plasma aldosterone was 38,100 pmol/l (RI 60–980 pmol/l), plasma renin activity was 422 fmol/l/s (RI 130–2350 fmol/l/s) and the aldosterone:renin ratio was markedly increased (69.9; RI 0.4–1.5). Basal progesterone was also elevated (30.6 nmol/l; RI <2.0 nmol/l).

On day 8, a blood type B donor was sourced, and 52.5 ml of whole blood was administered preoperatively. On day 9, preoperative PCV was 0.28 l/l, potassium was 3.8 mmol/l, sodium was 153 mmol/l and SABP was 145 mmHg. CT of the abdomen and thorax was performed under general anaesthesia. There was ventral displacement and compression of the caudal vena cava by the right adrenal mass and no evidence of vena caval invasion or tumour thrombi. There was a large, localised right retroperitoneal effusion with marked mass effect and no evidence of abdominal or thoracic metastases (Figure 1). At surgery to remove the right adrenal gland (Figure 1), via a ventral midline approach, a haematoma (45 mm diameter) was observed in close proximity to the right adrenal gland, just ventral to the caudal vena cava.

Analgesia consisted of a ketamine constant rate infusion (CRI; 0.5 mg/kg/h IV) and methadone (0.1 mg/kg IV q4h). A hydrocortisone CRI (0.5 mg/kg/h) was administered to manage a potentially hypofunctional left adrenal. Within 8 h postoperatively the cat was eating, and serum potassium was 4.2 mmol/l. On day 11, spironolactone, hydrocortisone and IVFT were ceased and oral prednisolone (1.25 mg q24h) was prescribed until day 50. On day 14 PCV was 0.26 l/l and TSP was 74 g/l. Oral potassium was tapered and ceased on day 15. No further electrolyte abnormalities were documented. The cat was discharged from hospital on day 16.

Histopathology revealed an adrenal adenocarcinoma (ACC) with no evidence of vascular invasion. The periphery of the mass was necrotic and considered the likely site of the haemorrhage. There was no haemorrhage within the tumour.

At rechecks 5 weeks postoperatively body weight, gait, posture, vital signs and serum potassium were normal, and anaemia had resolved. At a recheck 8 months postoperatively the cat was reported to be in good health

by the owner, body weight was stable (4.3 kg) and SABP was 160 mmHg, but International Renal Interest Society (IRIS) stage 2 chronic kidney disease (CKD) was diagnosed (urea 10.01 mmol/l [RI 7.2–10.7 mmol/l], creatinine 181 µmol/l [RI 90–180 µmol/l], USG 1.018).

Case 2

One of the authors (VRB) was presented with a similar case in 2003. A 13-year-old male castrated DSH collapsed acutely indoors one evening, preceded by vomiting once. The cat vocalised continuously after the event, and appeared to be in pain when picked up by its owner, a veterinary nurse. The cat had a history of polyuria, polydipsia and weight loss for several months beforehand.

On clinical examination, the cat was hypothermic (37.0°C), tachycardic and had pale mucous membranes. The cat was stabilised with crystalloid IVFT overnight. On presentation at referral several days later the cat had a body condition score of 3/9, pale mucous membranes and was tachycardic with a IV/VI parasternal systolic heart murmur, SABP of 220 mmHg and normal funduscopy. Abnormalities on haematology and biochemistry included a PCV of 18 l/l, TSP of 59 g/l, serum potassium of 2.17 mmol/l (RI 3.7–5.4 mmol/l), creatinine 468 µmol/l (RI 9–190 µmol/l) and a USG of 1.021. Plasma sodium was within the RI (149 mmol/l; RI 144–157 mmol/l). Abdominal ultrasonography confirmed the presence of an irregular, large right adrenal mass, which measured 5 × 2.7 cm diameter at the largest dimension and displaced the caudal vena cava to the right side. Partial attenuation of the caudal vena cava was assessed to be a consequence of haematoma formation at the site of the adrenal mass, although invasion of the caudal vena cava could not be excluded. Thoracic radiographs were unremarkable.

Spironolactone (6.25 mg PO q24h) and amlodipine (1.25 mg PO q24h) were commenced. Serum aldosterone was elevated (1916 pmol/l; RI 60–980 pmol/l), renin activity was 0 fmol/l/s; RI 130–2350 fmol/l/s), and a diagnosis of hyperaldosteronism was confirmed. An exploratory ventral midline celiotomy was performed 1 week later. The cat was blood typed (type A [Rapid-H; DSM Laboratories]) and given a 50 ml type A blood transfusion preoperatively. At surgery the right adrenal mass was adherent to, but not invading, the vena cava. A right adrenalectomy was performed. The adrenal mass contained a large amount of intratumoral haemorrhage and necrosis on cut section (Figure 2). Histological examination confirmed an ACC arising from the zona glomerulosa with extensive intratumoral necrosis and haemorrhage. The cat recovered well postoperatively.

At a recheck examination 9 months later, the PCV was 32 l/l, TSP was 75 g/l and the cat was diagnosed with IRIS stage 3 CKD. It lived for approximately 18 months after surgery.

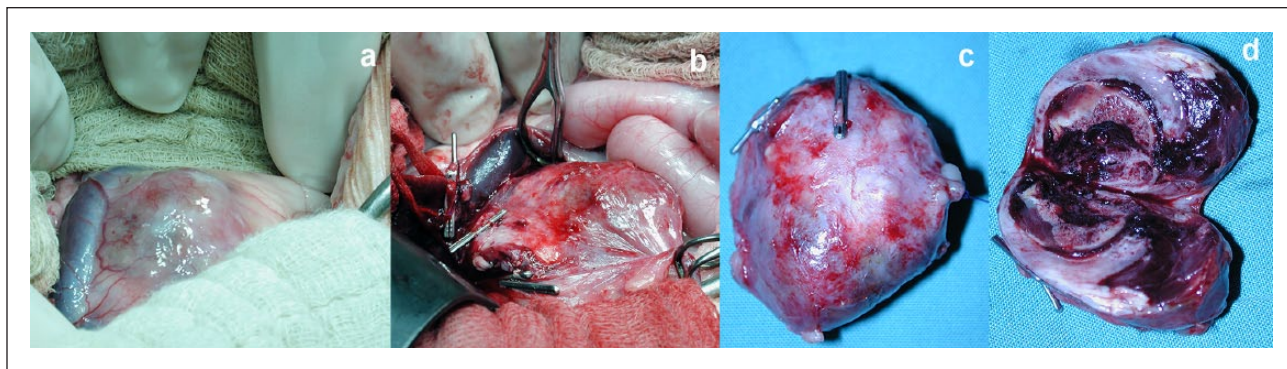


Figure 2 Case 2. (a,b) Right adrenal tumour adherent to, but not invading, the caudal vena cava. (c) The excised adrenal tumour containing (d) extensive areas of intratumoral necrosis and haemorrhage

Discussion

Severe preoperative acute adrenal haemorrhage has been reported rarely in humans with adrenal tumours, most commonly associated with pheochromocytoma (48%) and ACCs or metastases (20%).⁵ Acute adrenal haemorrhage has also been reported in dogs with adrenal disease and is associated with a high perioperative mortality of 50%.⁶ In a report of 60 cases in dogs, on histology 68% were ACCs or adenomas of unknown functional status, 11% were pheochromocytomas and 10% had adrenocortical hyperplasia.⁶ In cats, acute adrenal haemorrhage secondary to adrenal neoplasia has been reported in only one other case, which was described in a case series of 33 cats with adrenal tumours of any origin. Tumour type and whether the tumour was functional were not specified.⁴ Intra- and postoperative haemorrhage have been reported frequently in association with adrenalectomy in cats with adrenal neoplasia.^{2-4,7,8} Risk factors for haemorrhage have not yet been clearly identified but do not appear to be related to tumour type, venous invasion or systemic hypertension.¹

Primary hyperaldosteronism (PHA) results from mineralocorticoid excess arising from autonomous production of aldosterone from the zona glomerulosa of the adrenal cortex. The first reported case in the cat was related to an ACC in 1983.⁹ Since this time increasing numbers of cases have been reported, and it is now considered to be one of the most common adrenal disorders in cats.^{1,10,11} Most cases are associated with either adrenal adenomas or carcinomas.¹⁻⁴ Bilateral hyperplasia of the zona glomerulosa, a more common cause of hyperaldosteronism in people, was thought to be rare in cats; however, it may be more prevalent than originally thought in cats and may have an association with CKD. Cases of PHA may be overlooked as the hypertension and hypokalaemia are often attributed to CKD, whereas the CKD may be the result of PHA.¹²

Case 1 had an average serum potassium of 3.0 mmol/l and was exhibiting signs of profound muscle weakness

with elevated CK before treatment. Although the degree of hypokalaemia in cases of hyperaldosteronism can vary from mild to severe, signs of muscle weakness in cats are usually reported when serum potassium is ≤ 2.5 mmol/l, similar to case 2.^{1,4,10} Muscle weakness has been reported in other cases with potassium concentrations in the low normal-to-mildly decreased range.²⁻⁴ Other factors such as anaemia and subclinical hypoadrenocorticism have been postulated to contribute to muscle weakness in such cases.⁴

Polyuria and polydipsia were noted in case 1 in the absence of azotaemia on day 1. Polyuria and polydipsia can occur due to a combination of systemic hypertension, CKD and secondary nephrogenic diabetes insipidus due to hypokalaemia.¹⁰ Interestingly, 50% of reported cats with PHA are azotaemic, but there is a tendency for phosphorus concentrations to be low to normal due to volume expansion leading to increased fractional clearance of calcium, with development of secondary hyperparathyroidism.^{4,10,11} The presence of azotaemia and hypokalaemia with a normal-to-low serum phosphorus should alert the clinician to the possibility of PHA.

As in case 1, aldosterone-secreting adrenal tumours producing excesses of one or more adrenocortical hormones (often progesterone) have been reported previously, caused by paraneoplastic aberrant steroid synthesis pathways or enzyme deficiencies resulting in proximal hormone precursors accumulating, or being redirected to other pathways.^{8,13-16} A tumour secreting aldosterone may also secrete increased levels of aldosterone intermediates such as progesterone due to an enhanced biosynthetic pathway.¹⁴ Case 1 exhibited abdominal distension, PUPD and was polyphagic initially, so baseline progesterone levels were performed. Levels of other adrenocortical steroid hormones could have been elevated, but only progesterone was measured. Although a post-adrenocorticotrophic hormone stimulation progesterone level was not measured, elevation of basal levels may be sufficient for diagnosis.¹⁴

Adrenal hormone panels measuring cortisol, progesterone, 17-hydroxyprogesterone, androstenedione, oestradiol and testosterone could also have been considered; however, limitations include access to reference laboratories and lack of hormone RIs for cats¹⁴

Conclusions

Acute, severe adrenal haemorrhage can occur in cats with aldosterone-secreting carcinomas associated with spontaneous rupture of the tumour. Haemorrhage can occur both within and external to the tumour, in the retroperitoneal space and abdominal cavity.

Acknowledgements The authors wish to thank the staff and students involved in the care of these patients and benefactors who contribute to the Animals In Need Fund of the Sydney School of Veterinary Science.

Conflict of interest The authors declared no potential conflicts of interest with respect to the research, authorship, and/or publication of this article.

Funding The author(s) disclosed receipt of the following financial support for the research, authorship, and/or publication of this article: The Animals In Need Fund from the Sydney School of Veterinary Science contributed to the treatment costs of case 1.

References

- Djajadiningrat-Laanen SC, Galac S and Kooistra HS. **Primary hyperaldosteronism.** *J Feline Med Surg* 2011; 13: 641–650.
- Ash RA, Harvey AM and Tasker S. **Primary hyperaldosteronism in the cat: a series of 13 cases.** *J Feline Med Surg* 2005; 7: 173–182.
- Lo AJ, Holt DE, Brown DC, et al. **Treatment of aldosterone-secreting adrenocortical tumors in cats by unilateral adrenalectomy: 10 cases (2002–2012).** *J Vet Intern Med.* 2014; 28: 137–143.
- Daniel G, Mahony OM, Markovich JE, et al. **Clinical findings, diagnostics and outcome in 33 cats with adrenal neoplasia (2002–2013).** *J Feline Med Surg* 2016; 18: 77–84.
- Marti JL, Millet J, Sosa JA, et al. **Spontaneous adrenal hemorrhage with associated masses: etiology and management in 6 cases and a review of 133 reported cases.** *World J Surg* 2012; 36: 75–82.
- Lang JM, Schertel E, Kennedy S, et al. **Elective and emergency surgical management of adrenal gland tumors: 60 cases (1999–2006).** *J Am Anim Hosp Assoc* 2011; 47: 428–435.
- Mitchell JW, Mayhew PD, Culp WTN, et al. **Outcome of laparoscopic adrenalectomy for resection of unilateral noninvasive adrenocortical tumors in 11 cats.** *Vet Surg* 2017; 46: 714–721.
- DeClue AE, Breshears LA, Pardo ID, et al. **Hyperaldosteronism and hyperprogesteronism in a cat with an adrenal cortical carcinoma.** *J Vet Intern Med* 2005; 19: 355–358.
- Eger CE, Robinson WF and Huxtable CR. **Primary aldosteronism (Conn's syndrome) in a cat; a case report and review of comparative aspects.** *J Small Anim Pract* 1983; 24: 293–307.
- Cook AK. **Hyperaldosteronism: recognition, diagnosis and management.** Proceedings of the American College of Veterinary Internal Medicine Congress; 2018 June 14–16; Seattle, WA, pp 963–965.
- Refsal KRH and Andrea M. **Feline primary hyperaldosteronism.** In: Twedt DC and Bonagura JD (eds). *Kirk's current veterinary therapy XV.* London: Elsevier Health Sciences, 2014, pp 238–242.
- Javadi S, Djajadiningrat-Laanen SC, Kooistra HS, et al. **Primary hyperaldosteronism, a mediator of progressive renal disease in cats.** *Dom Anim Endocrinol* 2005; 28: 85–104.
- Briscoe K, Barrs VR, Foster DF, et al. **Hyperaldosteronism and hyperprogesteronism in a cat.** *J Feline Med Surg* 2009; 11: 758–762.
- Boland LA and Barrs VR. **Peculiarities of feline hyperadrenocorticism: update on diagnosis and treatment.** *J Feline Med Surg* 2017; 19: 933–947.
- Leshinsky J, Beatty JA, Fawcett A, et al. **Aldosterone and progesterone-secreting adrenocortical adenocarcinoma in a cat with a concurrent meningioma.** *JFMS Open Rep* 2016; 2. DOI: 10.1177/2055116915624448.
- Guerios SD, Souza CHM and Bacon NJ. **Adrenocortical tumor in a cat secreting more than one type of corticosteroid.** *JFMS Open Rep* 2015; 1. DOI: 10.1177/2055116915617970.