



Mini-open Subpectoral Biceps Tenodesis Using a Suture Anchor

Christopher Arena, M.D., and Aman Dhawan, M.D.

Abstract: The long head of the biceps (LHB) tendon is a potential source of shoulder pain encountered by orthopaedic surgeons. A multitude of approaches to addressing LHB tendinopathy have been described. These include various surgical techniques such as tenodesis versus tenotomy, an arthroscopic versus an open approach, and differing methods of tenodesis fixation. Our preferred approach to addressing LHB tendinopathy is through a mini-open approach using a double-loaded 4.5-mm suture anchor. This Technical Note with accompanying video describes our technique for performing this procedure, as well as supporting clinical evidence and technical pearls.

Long head of the biceps (LHB) tendinopathy is a potential source of shoulder pain encountered by orthopaedic surgeons. Isolated biceps tendinopathy involves the extracapsular portion of the tendon in the bicipital groove and accounts for only approximately 5% of LHB tendinopathies. Most biceps tendinopathies (95%) are secondary and are associated with other pathologic shoulder conditions including rotator cuff disorders or SLAP tears.¹ Diagnosing LHB tendinopathy should include a complete orthopaedic history and shoulder-specific physical examination. The patient may present with anterior shoulder pain and tenderness to palpation located over the bicipital groove. Pain may be worse at night or with overhead repetitive activities. Provocative biceps tests including Yergason, Neer, Hawkins, and Speed tests may reproduce pain but are not specific to biceps pathology and may point to an underlying impingement disorder. Glenohumeral arthritis, trauma, SLAP tears,

acromioclavicular joint pathology, and rotator cuff tears should be included in the differential diagnosis when biceps tendinopathy is suggested. Radiographs of the shoulder should be obtained to rule out any fracture and to evaluate for glenohumeral arthritis, acromioclavicular joint pathology, or a subacromial spur suggesting shoulder impingement. Magnetic resonance imaging is excellent in evaluating LHB pathology, labral tears, chondral lesions, and rotator cuff tears.

In the treatment of LHB tendinopathy, biceps tenodesis is preferred to biceps tenotomy because of the ability to maintain the biceps muscle length-tension relation, as well as elbow flexion and supination strength, and to achieve improved cosmesis by avoiding a Popeye deformity.² Both arthroscopic and open approaches have been described in performing LHB tenodesis.²⁻⁴ Arthroscopic LHB tenodesis is accomplished by performing an arthroscopic biceps tenotomy after passing a monofilament suture through the tendon for stabilization. Next, an arthroscopic subacromial portal is established and used to release the tendon from the bicipital groove while preserving the transverse humeral ligament and subscapularis insertion. The tenodesis may be performed by a multitude of fixation methods including osseous fixation (suture anchors, knotless anchors, suture button), intraosseous fixation (interference screws), and soft-tissue tenodesis (rotator cuff, rotator interval, transverse humeral ligament).⁵ Regardless of the fixation method, arthroscopic methods may pose a higher learning curve to the surgeon than the mini-open technique. The mini-open technique uses a small incision to directly visualize the biceps tenotomy and tenodesis location, thus

From the Department of Orthopaedic Surgery, Milton S. Hershey Medical Center, Penn State Health, Hershey, Pennsylvania, U.S.A.

The authors report the following potential conflict of interest or source of funding: C.A. receives support from Penn State University. A.D. receives support from Arthroscopy Journal Associate Editor, Smith & Nephew, Biomet, Penn State Hershey Medical Center, Arthritis National Research Foundation, NIH, Revotek. Full ICMJE author disclosure forms are available for this article online, as [supplementary material](#).

Received February 25, 2017; accepted June 21, 2017.

Address correspondence to Aman Dhawan, M.D., Penn State Hershey Orthopaedics, 30 Hope Dr, Hershey, PA 17033, U.S.A. E-mail: adhawan@pennstatehealth.psu.edu

© 2017 by the Arthroscopy Association of North America. Published by Elsevier. This is an open access article under the CC BY-NC-ND license (<http://creativecommons.org/licenses/by-nc-nd/4.0/>).

2212-6287/17247

<http://dx.doi.org/10.1016/j.eats.2017.06.019>

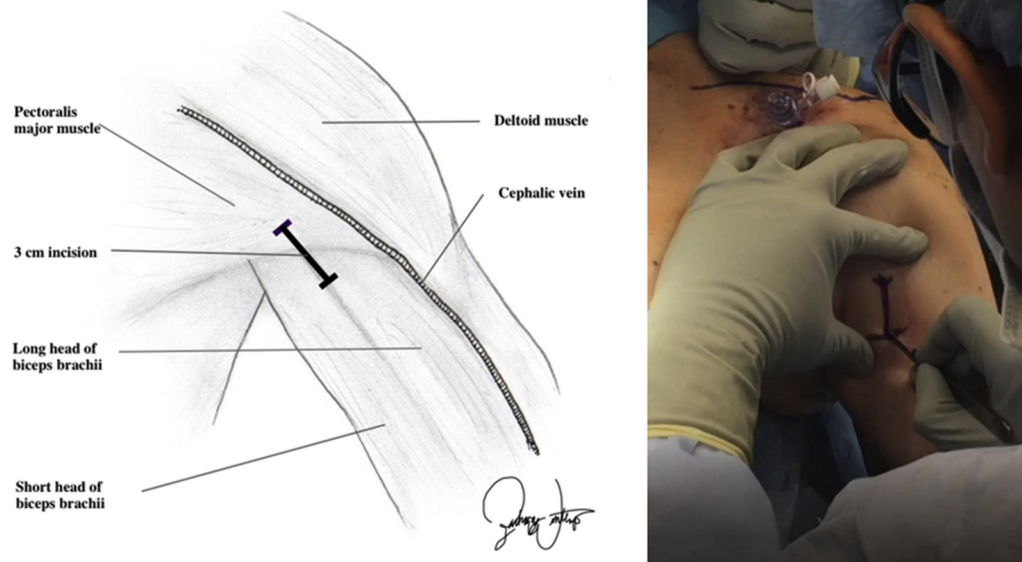


Fig 1. The patient is in the beach-chair position with the operative extremity secured distally in a sterile limb-positioning device. The left anterior shoulder is depicted and relevant surface anatomy highlighted. A 3-cm longitudinal incision is made over the anterior arm at the level of the pectoralis major tendon.

potentially limiting a length-tension relation mismatch or neurovascular injury. A potential pitfall of the mini-open technique is the cosmesis and associated infection risk with an additional incision over the anterior arm. A variety of LHB open fixation techniques and devices have also been described.^{2,3,6} In our opinion, a mini-open subpectoral method with a 4.5-mm double-loaded suture anchor provides data demonstrated biomechanically strong fixation with reproducible results using a safe technique while avoiding the pitfalls of other techniques of fixation, such as a proximal humeral fracture due to a stress riser.⁷⁻¹⁰ This Technical Note describes our approach to addressing LHB tendon pathology with a mini-open subpectoral

biceps tenodesis using a double-loaded 4.5-mm suture anchor ([Video 1](#)).

Surgical Technique

Preoperative Setup

The patient is placed in the beach-chair position under general anesthesia with all bony prominences well padded. Mechanical deep vein thrombosis prophylaxis is used through sequential compressive devices. The operative arm is prepared, draped, and secured in a sterile limb positioner. Preoperative antibiotic prophylaxis is administered, and preoperative imaging is made available for immediate viewing.

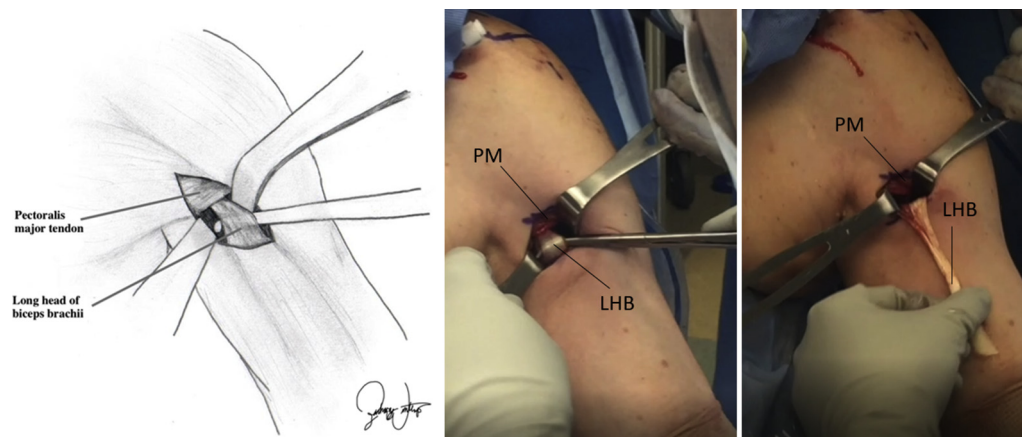


Fig 2. The left anterior shoulder is depicted with the patient in the beach chair position. The fascia immediately inferior to the pectoralis major (PM) tendon is incised 2 cm proximally and distally. The PM tendon is bluntly separated from the biceps brachii and retracted superiorly. Next, the tenotomized long head of the biceps (LHB) tendon is retrieved from the incision as shown.

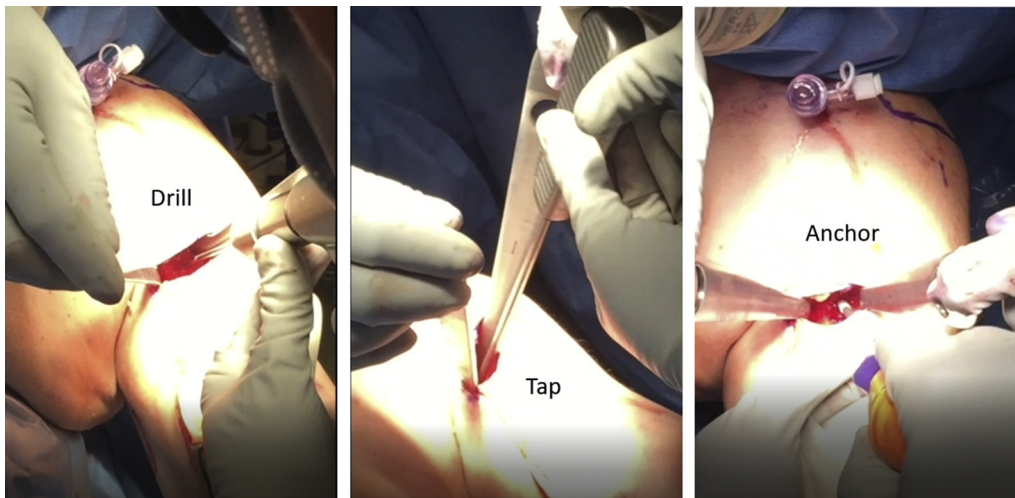


Fig 3. The left anterior shoulder is depicted with the patient in the beach chair position. Two double-bent Homan retractors are placed both laterally and medially across the humerus subperiosteally. A long head of the biceps tendon docking point is selected over the midline anterior humerus 2 cm distal to the pectoralis major tendon along the bicipital groove. A 3.5-mm drill is used to make a unicortical pilot hole in the anterior humerus, followed by a 4.5-mm tap and hand placement of a 4.5-mm Healicoil open-architecture PEEK (polyether ether ketone) double-loaded suture anchor.

Diagnostic Arthroscopy and LHB Tenotomy

Diagnostic shoulder arthroscopy and any glenohumeral procedures are first accomplished including an LHB inspection and tenotomy with the use of a meniscal punch. The mini-open LHB tenodesis is then performed before the subacromial space is entered, and all arthroscopic instruments are removed from the glenohumeral joint. This order of operation is performed to avoid distorted tissue planes due to fluid extravasation from the subacromial space and larger required incisions because of anterior shoulder edema seen after subacromial arthroscopy.

Mini-open Incision and Retrieval of Biceps Tendon

First, the anterior shoulder anatomy is palpated and the inferior border of the pectoralis major tendon identified. A vertical 3-cm skin incision is made over the anterior proximal arm centered over the pectoralis major tendon (Fig 1). The incision is made over the anterior surface of the arm versus medially to avoid the axillary flora and reduce potential infection risk. Bovie cautery (Bovie Medical) is used to dissect the subcutaneous tissues to the level of the pectoralis major fascia. The cephalic vein should not be visualized during this approach and, if encountered, signifies the approach is in error proximally. The fascia immediately inferior to the pectoralis major tendon is incised 2 cm proximally and distally. A finger sweep through the incised fascia is performed to free the pectoralis major muscle, and the LHB tendon is palpated in the bicipital groove. The pectoralis major tendon is retracted superiorly to expose the LHB tendon using an Army-Navy

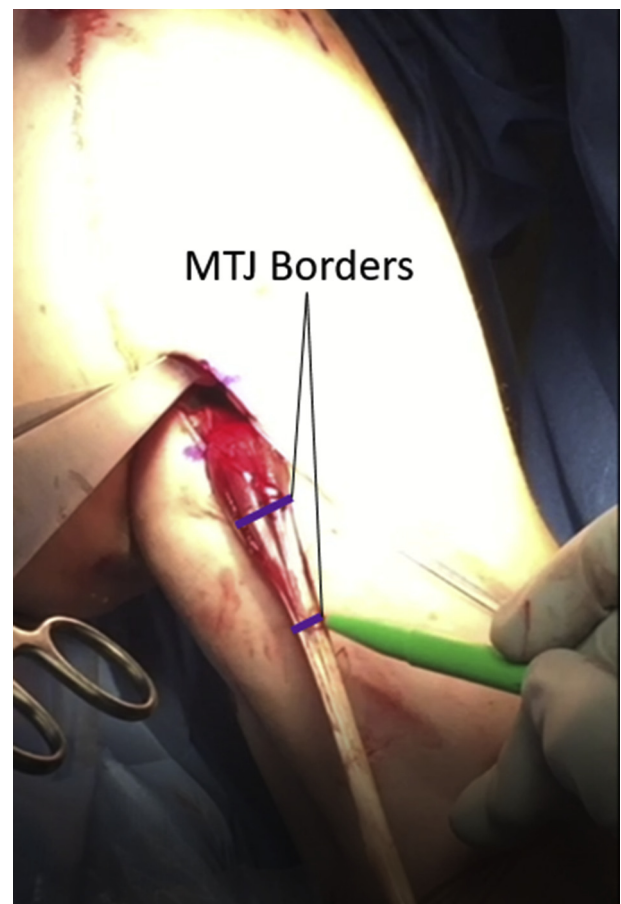


Fig 4. The long head of the biceps tendon retrieved from the wound of the anterior shoulder (left is depicted) is evaluated and marked at the proximal and distal borders of the musculotendinous junction (MTJ) with a sterile marking pen.

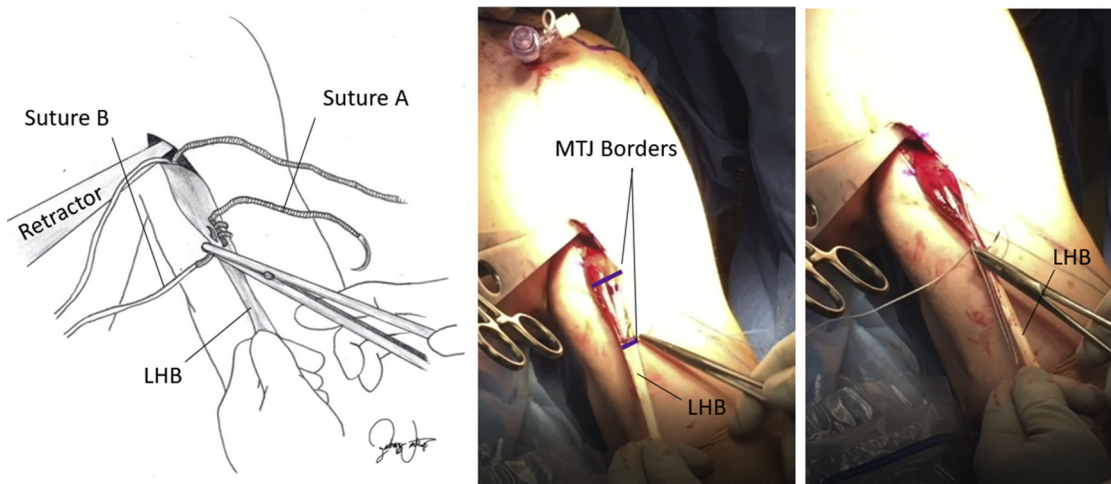


Fig 5. Intraoperative and artist depictions of a left anterior shoulder. The previously marked borders of the long head of the biceps (LHB) tendon musculotendinous junction (MTJ) serve as the boundaries for suture location. A free needle is used to pass 3 running Krackow stitches of suture A through the lateral aspect of the LHB tendon from the anatomic anterior-to-posterior direction, progressing from proximally to distally. Suture B is passed in a similar locking Krackow fashion over the medial LHB tendon, thus securing both strands of the double-loaded suture anchor to the MTJ of the LHB tendon.

retractor, and the previously tenotomized tendon is retrieved through the incision (Fig 2).

Suture Anchor Placement

Next, 2 double-bent Homan retractors are placed both laterally and medially across the humerus strictly subperiosteally. This avoids injury to the axillary nerve laterally and musculocutaneous and medial antebrachial cutaneous nerve medially. A midline humeral docking point is selected 2 cm distal to the pectoralis major tendon proximal insertion along the bicipital groove.¹¹ This corresponds to the distal one-third of the bicipital groove. A 3.5-mm drill bit is used to create a unicortical tunnel perpendicular to the axis of the humerus while avoiding bicortical penetration and risk of axillary nerve injury.¹² A 4.5-mm tap is used to tap the pilot hole, and a double-loaded 4.5-mm Healicoil open-architecture PEEK (poly-ether ether ketone) suture anchor (Smith & Nephew, Andover, MA) is inserted by hand just deep to the anterior surface of the humeral cortex (Fig 3).

LHB Tendon Suture Anchor Fixation

A double-pulley technique is used to secure the tendon.¹³ First, a sterile marker is used to identify and mark the proximal and distal aspects of the musculotendinous junction (MTJ) of the LHB tendon (Fig 4). One suture strand of the double-loaded anchor is used to run 3 locking stitches in Krackow fashion on the lateral aspect of the tendon. This extends from the marked proximal-to-distal ends of the MTJ using a free needle passed in the anatomic anterior-to-posterior direction. Next, the other suture strand, which typically is a different color, is passed in similar fashion over the medial aspect of the tendon with a free needle,

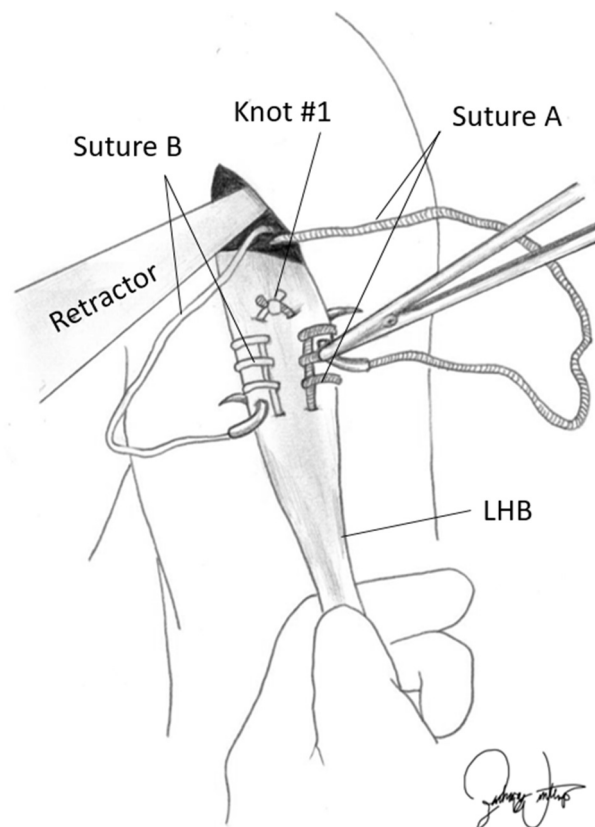


Fig 6. The ends of sutures A and B are tied together and cut after both Krackow stitches are completed to form knot 1, as shown at the anatomic posterior and distal portion of the long head of the biceps (LHB) tendon musculotendinous junction. The remaining ends of the corresponding suture strands of sutures A and B of the double-loaded suture anchor are passed through the Krackow running stitches from the anatomic posterior-to-anterior direction in the LHB tendon.

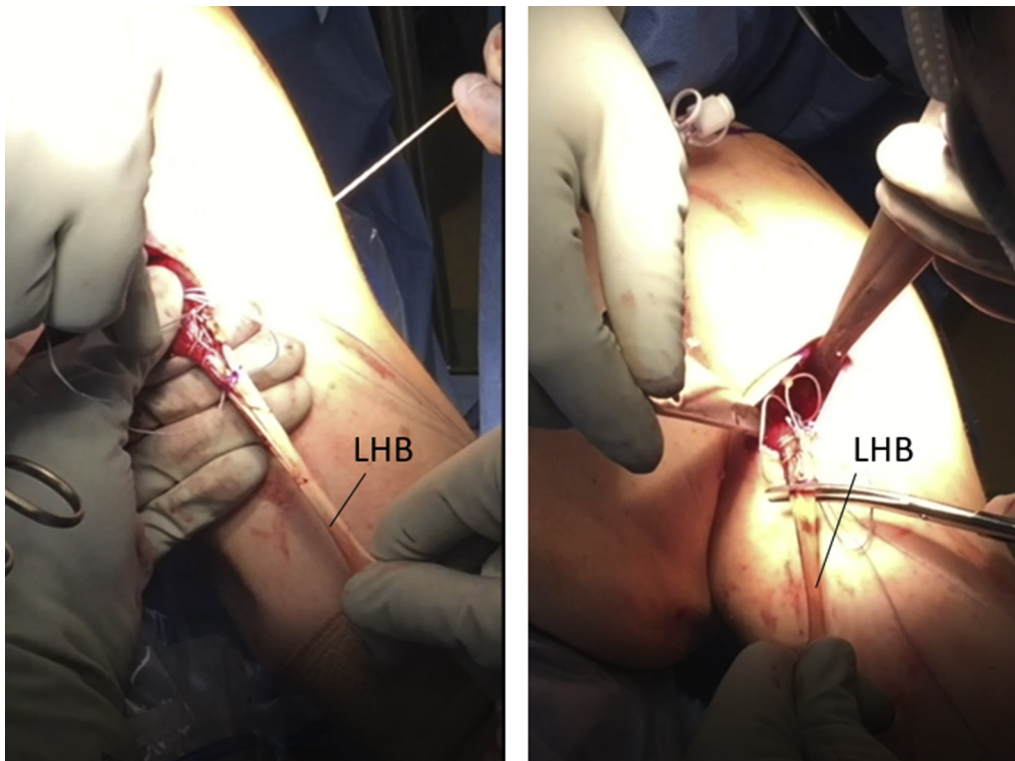


Fig 7. The left anterior shoulder is depicted with the patient in the beach chair position. The diseased proximal portion of the long head of the biceps (LHB) tendon is excised with scissors at the proximal aspect of the musculotendinous junction border.

again from the anatomic anterior-to-posterior direction (Fig 5). The 2 different-colored running sutures are then tied together at the exiting point over the posterior LHB tendon at the distal end of the MTJ. The 2 remaining free ends of the double-loaded suture anchor are next passed through the LHB tendon using a free needle from the anatomic posterior-to-anterior direction through the Krackow loop of the same suture to tie the suture knot on the superficial surface of the tenodesis (Fig 6). This is performed through the

proximal Krackow loop medially and distal loop laterally to provide a rip-stop to prevent the suture from splitting the tendon longitudinally. Next, the proximal diseased portion of the tendon is trimmed off with scissors at the proximal marking and extent of the Krackow suturing (Fig 7).

Securing of LHB Tendon Docking Site

In alternating fashion, tension is applied to each free suture end and the tendon is parachuted down into the

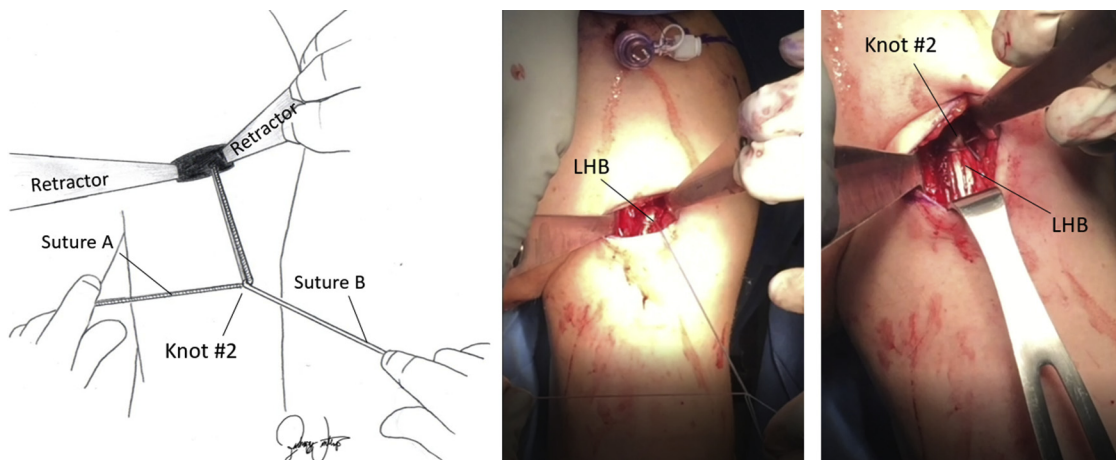


Fig 8. The left anterior shoulder is depicted with the patient in the beach chair position. The remaining suture ends of sutures A and B are used to parachute the long head of the biceps (LHB) tendon into the wound back into the anatomic position and secured to the suture anchor docking site by tying the previously passed sutures on the anterior surface of the LHB tendon, creating knot 2.

wound until reaching the anchor docking site. The free suture ends are tied together and trimmed, securing the LHB tendon in its anatomic position (Fig 8). The wound is copiously irrigated with saline solution, retractors removed, and skin closure performed in 2 layers (subcutaneous and skin) before any subacromial arthroscopic procedures are performed. Wound closure is performed before subacromial work to avoid the potential for contamination from the axillary flora and to achieve improved cosmesis before fluid extravasation and arm swelling.

Postoperative Management

Postoperatively, the patient's operative extremity is placed in an immobilizer for 6 weeks. Range of motion is limited to avoid active elbow flexion or forearm supination for 4 weeks. Physical therapy begins 3 to 5 days after surgery, when the patient may gently extend the elbow to full extension out of the sling. Remaining activity restrictions are dictated by any associated pathologies, such as SLAP tears, or the performance of other repairs, such as rotator cuff tear repair.

Discussion

Performing mini-open subpectoral biceps tenodesis is shown to have advantages over arthroscopic techniques, including a clearly defined anatomy; a reproducible technique with a lower learning curve; removal of most of the LHB tendon and associated synovium, which may cause continued pain; and a lower incidence of stiffness and residual pain.^{4,14} Other techniques for subpectoral biceps tenodesis using a double-loaded suture anchor have been described but with key differences.³ Our technique offers greater biomechanical pullout strength with the use of a 4.5-mm suture anchor versus the smaller 2.9-mm anchor. Moreover, our technique uses a similar sized 3-cm vertical incision but with direct visualization of humeral drilling and docking-site placement. We believe direct visualization, as opposed to blind drilling and anchor placement as previously described, offers a similar wound size and cosmesis but confirmed orientation of drilling and anchor placement perpendicular to the humerus and mitigates the risk of neurovascular injury. In addition, an advantage of an open-architecture design is a potentially better biological environment for soft tissue-to-bone integration. Another technique of subpectoral LHB tenodesis with the use of an interference screw has previously been described; however, the larger-diameter 8-mm humeral defect created with this technique can result in a higher stress riser and, ultimately, pose a higher risk of fracture in comparison with our technique using a 4.5-mm suture anchor docking site.^{6,10} No statistically significant clinical difference between fixation techniques using

interference screws and suture anchor fixation has been shown.⁶⁻⁹ Cortical button fixation for LHB tenodesis has also been described; however, this technique requires bicortical drilling of the anterior and posterior humeral cortex.¹⁵ Although no long-term clinical outcome studies exist, bicortical humeral drilling compared with unicortical drilling required in suture anchor fixation may pose a higher risk of fracture by disrupting a larger surface area of bone and creating a larger stress riser.

For these reasons, mini-open subpectoral biceps tenodesis using a 4.5-mm double-loaded suture anchor under direct visualization is our preferred approach to addressing LHB pathology. Video 1 presents an example of our preferred technique in the hope of providing surgeons with a reproducible procedure with a low learning curve to effectively achieve tenodesis of the LHB tendon.

References

1. Churgay CA. Diagnosis and treatment of biceps tendinitis and tendinosis. *Am Fam Physician* 2009;80:470-476.
2. Mazzocca AD, Noerdlinger MA, Romeo AA. Mini open and sub pectoral biceps tenodesis. *Oper Tech Sports Med* 2003;11:24-31.
3. Scully WF, Wilson DJ, Grassbaugh JA, Branstetter JG, Marchant BG, Arrington ED. A simple surgical technique for subpectoral biceps tenodesis using a double-loaded suture anchor. *Arthrosc Tech* 2013;2:e191-e196.
4. Romeo AA, Mazzocca AD, Provencher MT. Surgical technique: Arthroscopic and subpectoral long head of biceps tenodesis. *Orthop Today*. <https://www.healio.com/orthopedics/arthroscopy/news/print/orthopedics-today/%7B95443cbd-bc23-4f6a-adfb-0f4df8a0330b%7D/surgical-technique-arthroscopic-and-subpectoral-long-head-of-biceps-tenodesis>. Published November 2007. Accessed February 1, 2017.
5. Scheibel M, Schroder R, Chen J, Bartsch M. Arthroscopic soft tissue tenodesis versus bony fixation anchor tenodesis of the long head of the biceps tendon. *Am J Sports Med* 2011;39:1046-1052.
6. Mazzocca AD, Rios CG, Romeo AA, Arciero RA. Subpectoral biceps tenodesis with interference screw fixation. *Arthroscopy* 2005;21:896.e1-896.e7.
7. Mazzocca AD, Bicos J, Santangel S, Romeo AA, Arciero RA. The biomechanical evaluation of four fixation techniques for proximal biceps tenodesis. *Arthroscopy* 2005;21:1296-1306.
8. Millett PJ, Sanders B, Gobezie R, Braun S, Warner JJ. Interference screw vs. suture anchor fixation for open subpectoral biceps tenodesis: Does it matter? *BMC Musculoskelet Disord* 2008;9:121.
9. Tashjian RZ, Henninger HB. Biomechanical evaluation of subpectoral biceps tenodesis: Dual suture anchor versus interference screw fixation. *J Shoulder Elbow Surg* 2013;22:1408-1412.
10. Dein EJ, Huri G, Gordon JC, McFarland EG. A humerus fracture in a baseball pitcher after biceps tenodesis. *Am J Sports Med* 2014;42:877-879.

11. LaFrance R, Madsen W, Yaseen Z, Giordano B, Maloney M, Voloshin I. Relevant anatomic landmarks and measurements for biceps tenodesis. *Am J Sports Med* 2013;41:1395-1399.
12. Sethi PM, Vadasdi K, Greene RT, Vitale MA, Duong M, Miller SR. Safety of open suprapectoral and subpectoral biceps tenodesis: An anatomic assessment of risk for neurologic injury. *J Shoulder Elbow Surg* 2015;24:138-142.
13. Arrigoni P, Brady PC, Burkhart SS. The double-pulley technique for double-row rotator cuff repair. *Arthroscopy* 2007;23:675.e1-675.e4.
14. Werner BC, Pehlivan HC, Hart JM, et al. Increased incidence of postoperative stiffness after arthroscopic compared with open biceps tenodesis. *Arthroscopy* 2014;30:1075-1084.
15. Snir N, Hamula M, Wolfson T, Laible C, Sherman O. Long head of biceps tenodesis with cortical button technique. *Arthrosc Tech* 2013;2:e95-e97.