

Rotator Cuff Sparing Arthroscopic SLAP Repair With Knotless All-Suture Anchors



Travis J. Dekker, M.D., Lucca Lacheta, M.D., Brandon Goldenberg, B.A.,
W. Jeffrey Grantham, M.D., and Peter J. Millett, M.D., M.Sc.

Abstract: Arthroscopic repair of SLAP tears is a common shoulder procedure, especially in overhead athletes. Repair techniques have evolved over the last 20 years, and the optimal technique remains elusive. In many cases, a transrotator cuff portal placed lateral to the acromion is used to access the superior glenoid. However, violating the rotator cuff is not desirable in an overhead athlete, and this approach can be associated with an increased risk of postoperative morbidity. The purpose of this Technical Note is to describe our preferred surgical technique with a rotator cuff–sparing approach for arthroscopic SLAP repair with all-suture anchors.

SLAP tears are a common pathology seen in high-level throwers. With both the identification and incidence of fixing SLAP tears increasing in recent years, various methods have been described to create a stable and anatomic repair while minimizing surrounding soft tissue disruption.^{1,2} Overhead athletes have had mixed results with primary SLAP repair, with only 22% to 64% able to return to their previous level of play.³ Although the exact reasons and mechanisms for failure and dissatisfaction are not known, concern for permanently altered biomechanics or persistent instability have been offered as reasons why throwers may not have restoration of their throwing mechanics.^{4,5}

Traditional SLAP repair with straight drill guides requires the use of the port of Wilmington and/or Neviaser portal, which typically penetrate the rotator cuff complex either through the posterior and/or superior aspect of the supraspinatus or through the interval between the supraspinatus and infraspinatus.^{6,7} This portal has been associated with decreased American Shoulder and Elbow Surgeons scores and patient satisfaction and an increase in postoperative impingement symptoms and night pain.^{8,9} With concern for any rotator cuff compromising intervention in the throwing population, a rotator cuff–sparing SLAP repair technique would be ideal to avoid any morbidity associated with rotator cuff compromise. The purpose of this article is to describe a reliable and simple method to perform a rotator cuff–sparing, arthroscopic SLAP repair with all-suture anchors.

From the Steadman Philippon Research Institute (T.J.D., L.L., B.G., W.J.G., P.J.M.); and The Steadman Clinic (T.J.D., W.J.G., P.J.M.), Vail, Colorado, U.S.A.

The authors report the following potential conflicts of interest or sources of funding: L.L. receives support from Arthrex. P.J.M. is a consultant for and receives royalties from Arthrex, Medbridge, and Springer Publishing; owns stock in GameReady and VuMedi; receives support from Steadman Philippon Research Institute (SPRI) and Vail Valley Medical Center; and has corporate sponsorships for SPRI from Smith and Nephew, Arthrex, Siemens, and Össur. Full ICMJE author disclosure forms are available for this article online, as supplementary material.

Received March 12, 2019; accepted May 6, 2019.

Address correspondence to Peter J. Millett, M.D., M.Sc., The Steadman Clinic, 181 West Meadow Dr, Ste 400, Vail, CO 81657, U.S.A. E-mail: drmillett@thesteadmanclinic.com

© 2019 Published by Elsevier on behalf of the Arthroscopy Association of North America. This is an open access article under the CC BY-NC-ND license (<http://creativecommons.org/licenses/by-nc-nd/4.0/>).

2212-6287/19338

<https://doi.org/10.1016/j.eats.2019.05.009>

Surgical Technique

Positioning and Anesthesia

Regional anesthesia is used with an interscalene nerve block placed under ultrasound guidance. General anesthesia is then induced, and the patient is placed in the beach chair position. The operative extremity is stabilized into a pneumatic arm holder (Tenet T-Max beach chair and spider arm positioner; Smith & Nephew, Memphis, TN). The operative extremity is prepped and draped using a standard sterile technique.

Portal Placement and Diagnostic Arthroscopy

The complete surgical technique is shown in [Video 1](#) and its advantages and disadvantages are presented in

Table 1. Advantages and Disadvantages

Advantages	Disadvantages
Smaller drill holes allow for preservation of glenoid bone stock.	Malpositioning of the anchors, with potential damage to the glenoid cartilage.
Lack of rigid component and curved insertion guide allow anchor positioning through the rotator interval with preservation of the supraspinatus tendon.	Additional portals may be needed with impairment of the supraspinatus-infraspinatus interval.
Anchor placement through the drilling/insertion guide provides simple and faster surgery. Allows percutaneous insertion as well.	Shifting of the guide may need a second drill.
Suture shuttling with PDS suture and the help of a spinal needle in position of the Neviaser portal avoid impairment of the supraspinatus muscle.	Inadequate positioning of the needle can lead to insufficient reduction of the proximal biceps anchor.
Knotless, self-locking.	Knots are inconsistent, take more time, create risk of soft tissue and cartilage abrasion.

Table 1. The procedure is started with a posterior viewing portal that is placed slightly lateral, 1 cm medial, and 3 cm distal to the posterolateral corner of the acromion to optimize the viewing the SLAP lesion. A standard rotator interval midglenoid portal is created, and a diagnostic arthroscopy is performed. The long head of the biceps, biceps-labral complex, glenoid labrum, subscapularis attachment, and undersurface of the rotator cuff are evaluated and treated for concomitant pathologies as indicated. A thorough evaluation of the superior labrum and bicipital root is performed to classify the type of labral tear.

Once the SLAP tear is identified and deemed repairable, an accessory anterosuperolateral portal is created through the rotator interval. A spinal needle is used first to ensure that the appropriate trajectory can be obtained to allow placement of anchors in the superior glenoid, anterior and posterior to the biceps tendon (Fig 1).

The portal is created sharply with a no. 11 blade, and a 5-mm cannula is inserted. The curved cannulated drill guide with teeth for a knotless 1.8-mm all-suture

anchor (KL FiberTak, Arthrex, Naples, FL) is introduced into the joint. The curved guide allows additional access to the glenoid to ensure the appropriate trajectory for drilling and anchor insertion. Using the flexible guide pin, the first pilot hole is drilled just anterior to the biceps tendon at the 1 o'clock position on the apex of the glenoid rim via the anterosuperolateral portal (Fig 2).

A 1.8-mm all-suture anchor (KL FiberTak) is placed. A curved arthroscopic suture shuttling device is passed through the standard midglenoid portal and around the superior labrum (Fig 3).

Care is taken to not include any additional capsular tissue when shuttling the suture around the labrum. The repair suture (blue-white) of the anchor is shuttled through the midglenoid (anteroinferior) portal and then passed back through the working high anterosuperior portal. The repair suture is then placed into the shuttling suture and is shuttled back through the self-locking mechanism of the anchor. The repair is then tensioned appropriately to fixate the anterosuperior labrum (Fig 4). The suture tail is then cut flush.

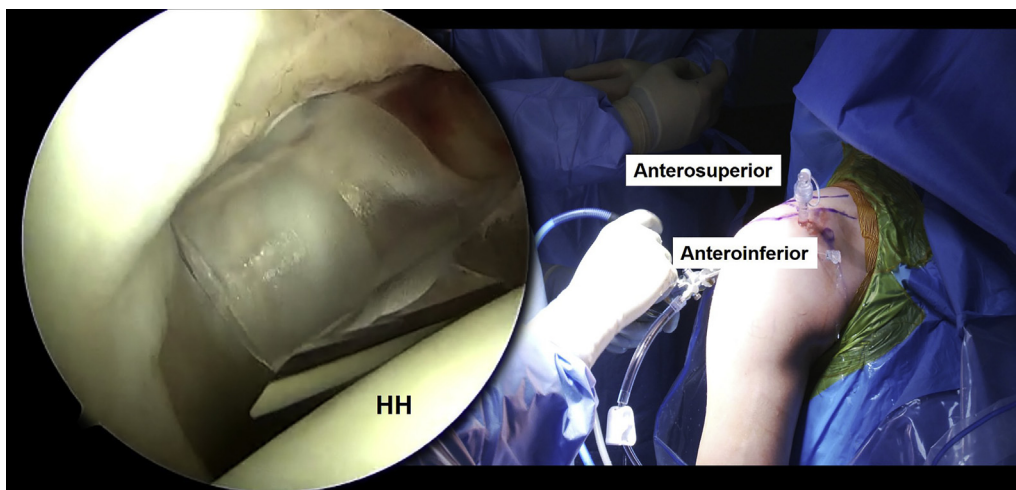
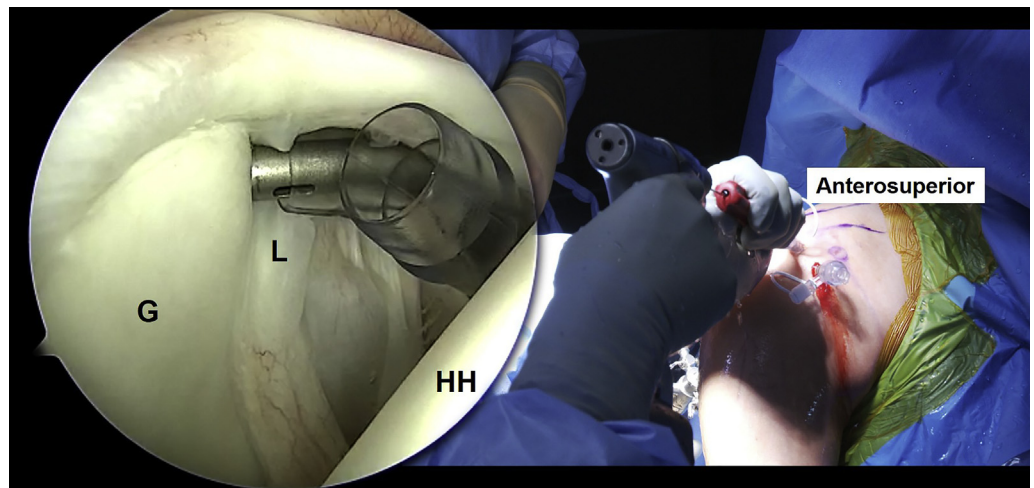


Fig 1. Right shoulder. Operative setup showing the anterosuperior and anteroinferior portals with a cannula placed through the anterosuperolateral portal with the patient placed in the beach chair position. A second cannula is being placed via the anteroinferior portal just above the upper border of the subscapularis tendon. (HH, humeral head.)

Fig 2. Right shoulder. A curved drill sleeve is placed through the anterosuperior portal to the glenoid rim at the 1 o'clock position 1 to 2 mm medial to the apex of the glenoid rim with the patient placed in the beach chair position. (G, glenoid; HH, humeral head; L, labrum.)



Similar steps are performed to place an anchor at the 11 o'clock position on the apex of the glenoid rim with a 1.8-mm all-suture anchor (KL FiberTak). The angle for passing suture around the labrum can be difficult. To shuttle the suture through the superoposterior labrum, a spinal needle is placed in the location of the Neviaser portal (Fig 5).

Care is taken to ensure the needle first enters the joint and then penetrates the posterior labrum. To improve visualization an arthroscopic switching stick can help elevate the superior capsule and rotator cuff and can help manipulate the labrum. It is important to avoid capturing any of the superior capsular tissues as this can lead to stiffness. It is also important to first enter the joint before penetrating the labrum as this allows one to visualize the suture for shuttling. After obtaining visualization of both the tip of the needle and

the shaft of the needle superior to the biceps-labral complex, a no. 2 PDS is placed into the needle and into the joint. The PDS is shuttled out of the high anterosuperior working portal, and the spinal needle is removed. The PDS then acts as a shuttling suture passing the repair suture of the knotless anchor under the labrum and through the superior capsule out through the skin (Fig 6).

The repair suture (blue-white) is shuttled around the labrum and can then be retrieved above the labrum back out through the working anterolateral rotator interval portal (Fig 7).

The repair suture (blue-white) is placed into the knotless shuttling suture (black-white) and is shuttled through the self-locking mechanism of the anchor. The repair suture is then tensioned to fixate the superior glenoid. Once the appropriate

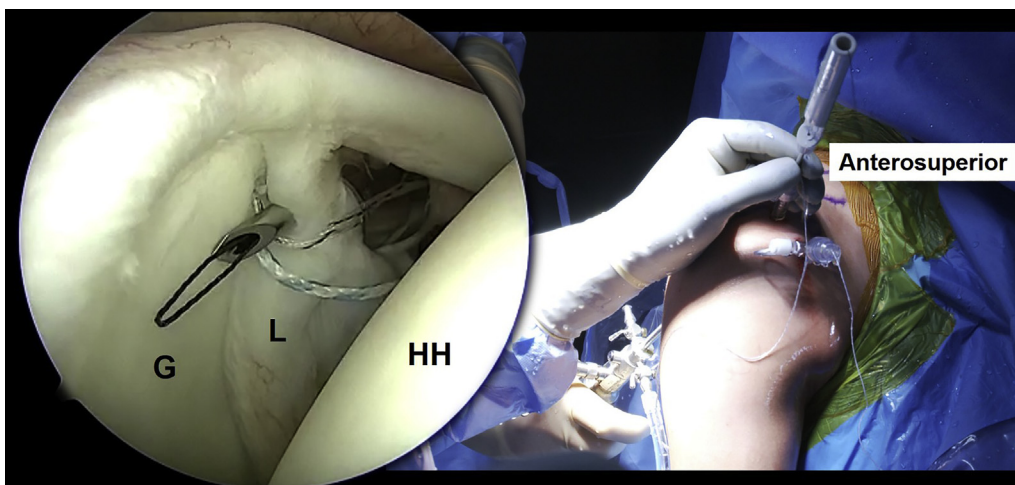


Fig 3. Right shoulder. A curved suture-shuttling device is placed in the anterosuperior cannula and penetrates the labrum ring anteromedial to the glenoid rim and lateral to the anchor with the patient placed in the beach chair position. (G, glenoid; HH, humeral head; L, labrum.)

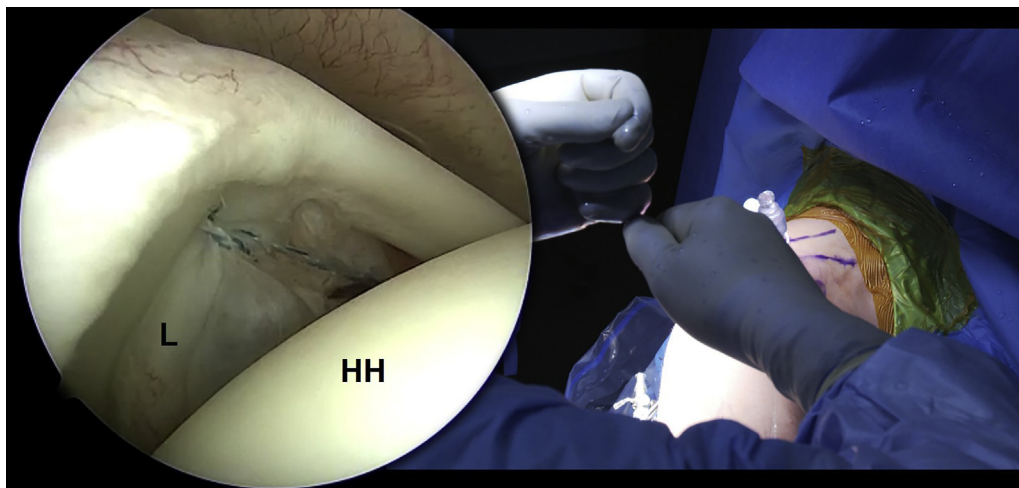


Fig 4. Right shoulder. Once the knotless all-suture anchor is placed, the anchor is tensioned to appropriately fixate the superior anterior labrum with the patient placed in the beach chair position. (L, labrum; HH, humeral head.)

tension is achieved, the tag end of the repair suture can be cut flush with the anchor. The final repair construct is probed to ensure stability of the bicipital root (Fig 8).

Postop Rehabilitation

After surgery, the patient is maintained in a sling for 4 weeks. Full passive range of motion is allowed as tolerated. Biceps loading is avoided. At 4 weeks postop, the patient can begin full active range of motion, and at 6 weeks the patient can start resistance training. When the patient is pain free and full strength is restored—typically by the 4- to 5-month mark—unrestricted return to sports is allowed.

Discussion

This Technical Note describes a surgical technique to repair a superior labrum anteroposterior tear in rotator cuff–sparing fashion. All work is done through the rotator interval. The curved guide helps to facilitate access to the posterior glenoid for placing the anchors. The all-suture, soft anchors can be inserted through a curved guide. Using a spinal needle to pass the sutures around the posterosuperior labrum also obviates the need for any additional transrotator cuff portals. With minimal injury to the surrounding tissue and knotless, bone-preserving all-suture anchors, less scar tissue formation, and postoperative stiffness and better clinical outcomes can be expected.

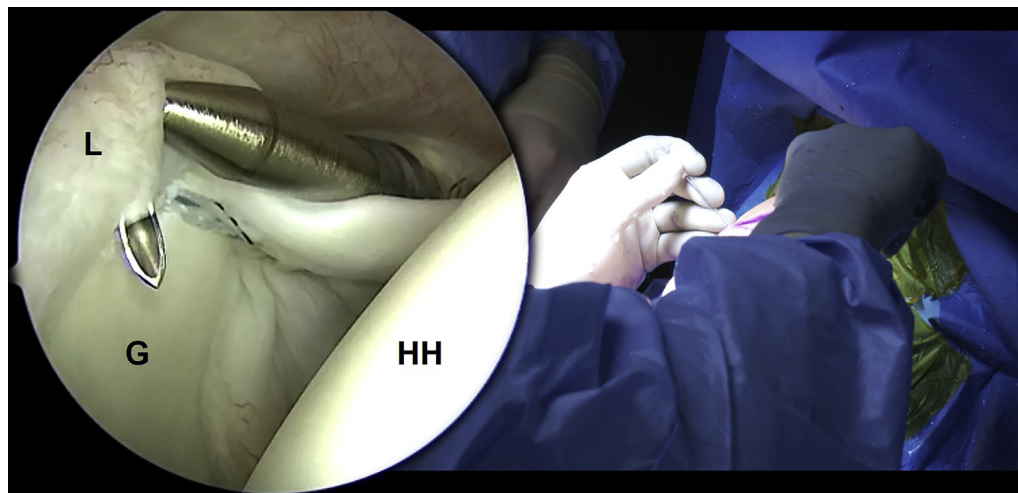
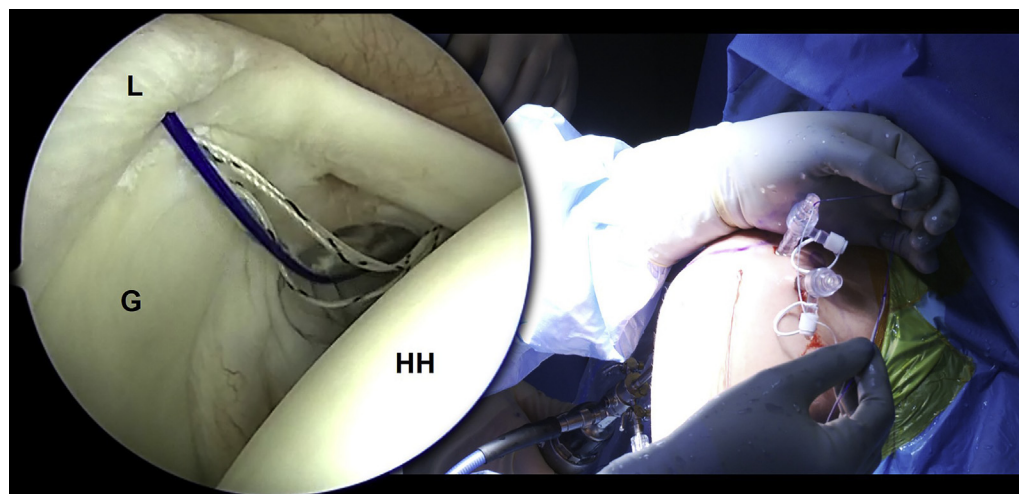


Fig 5. Right shoulder. To shuttle the suture through the superoposterior labrum, a spinal needle is placed in the location of the Neviaser portal, and an arthroscopic switching stick is used to manipulate the labrum ring to ensure correct trajectory with the patient placed in the beach chair position. (G, glenoid; HH, humeral head; L, labrum.)

Fig 6. Right shoulder. The PDS suture acts as a shuttling suture passing the repair suture of the knotless all-suture anchor under the labrum and through the superior capsule out through the skin with the patient placed in the beach chair position. (G, glenoid; HH, humeral head; L, labrum.)



It is the general consensus that young, athletic, high-demand patients with SLAP tears who fail nonoperative management can be treated with a SLAP repair.¹⁰ Outcomes following arthroscopic repair are variable, with 40% to 94% good and excellent results, with return to play ranging from 20% to 94%.³ While modern suture anchor repair has led to greater satisfaction and return to play in overhead athletes, return to play is lower when compared with all athletes in this demographic, with some series reporting rates only at 63%.¹¹

The largest complication from arthroscopic SLAP repair is stiffness, particularly in overhead athletes, in whom shoulder biomechanics may be altered, limiting the patient's return to sport. Brockmeier et al.¹² found that 4 of 47 patients (8.5%) have postoperative stiffness that decreases internal and/or external rotation and decreases patient satisfaction. Attempts to prevent stiffness with a combined biceps tenodesis have shown worse results than SLAP repair or tenodesis alone.¹³ With minimal disruption to the surrounding tissue, not incorporating capsule in the repair, and not placing anchors at the biceps insertion, the goal is to minimize overconstraining the tissue and postoperative stiffness.

Additionally, Lo et al.⁶ and Cohen et al.⁸ have shown that transrotator cuff portals used in traditional SLAP repairs are associated with decreased clinical outcomes, impingement syndrome, and night pain. One advantage of the presented technique is the small size of the all-suture anchors, which allows multiple points of fixation with minimal bone loss. The anchor material is also both small and strong and has the unique ability to tension the repair under direct visualization once the anchor is placed.

Finally, knots impingement can be another concern, particularly with SLAP repairs.^{14,15} The knotless aspect of the repair construct demonstrated in this article eliminates the risk of soft tissue and cartilage abrasion

that can occur with knotted anchors. The technique is also quick to perform. Due to the lack of a rigid component in the anchor, curved drilling and insertion guides can be used, which allow the use of a small, strong, simple, and bone-preserving anchor that can moreover be placed in a rotator cuff-sparing fashion to avoid the aforementioned complications.

In conclusion, this technique provides stabilization of the superior labrum at the biceps attachment with the goal of limiting soft tissue disruption using knotless all-suture anchors in a rotator cuff-sparing approach. These characteristics will improve outcomes and minimize complications. Further outcome studies are needed to better understand the technique's impact on patient outcomes and return to play.

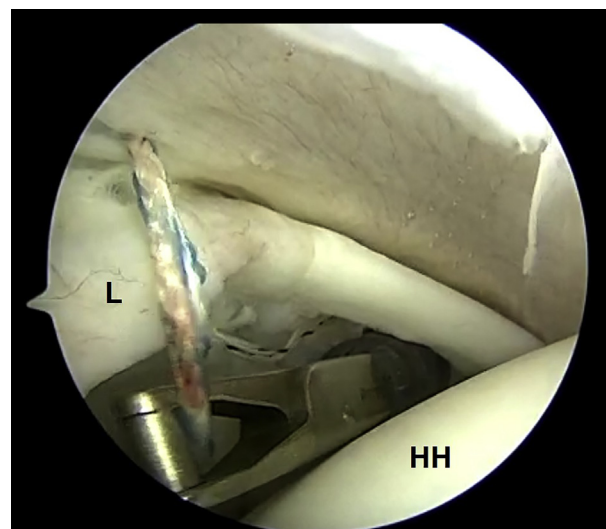


Fig 7. Right shoulder. The arthroscopic retriever grasps the repair suture and retrieves it out of the anterolateral rotator interval portal with the patient placed in the beach chair position. (L, labrum; HH, humeral head.)

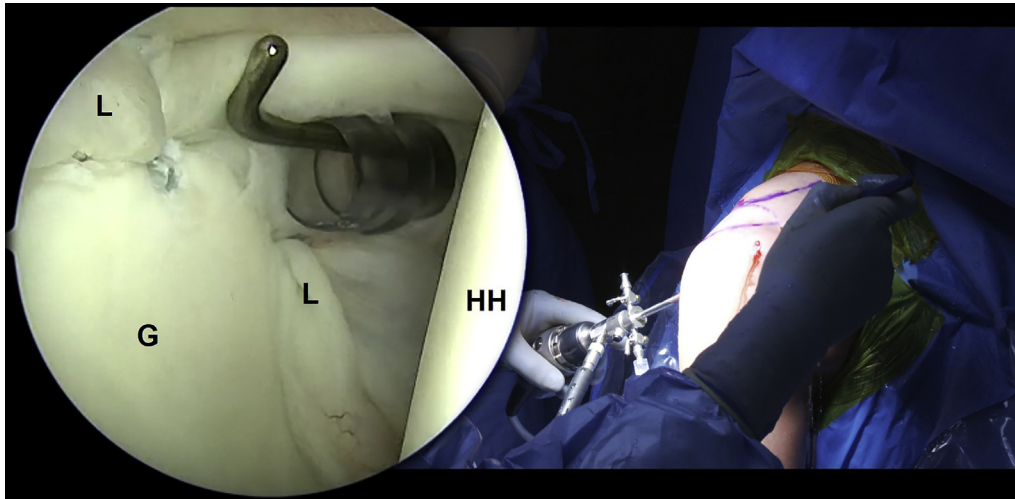


Fig 8. Right shoulder. With the arthroscope in the posterior portal, visualization of the final repair is seen with anchors at the 11 and 1 o'clock positions with the patient placed in the beach chair position. (G, glenoid; HH, humeral head; L, labrum.)

References

1. Onyekwelu I, Khatib O, Zuckerman JD, Rokito AS, Kwon YW. The rising incidence of arthroscopic superior labrum anterior and posterior (SLAP) repairs. *J Shoulder Elbow Surg* 2012;21:728-731.
2. Zhang AL, Kreulen C, Ngo SS, Hame SL, Wang JC, Gamradt SC. Demographic trends in arthroscopic SLAP repair in the United States. *Am J Sports Med* 2012;40:1144-1147.
3. Gorantla K, Gill C, Wright RW. The outcome of type II SLAP repair: A systematic review. *Arthroscopy* 2010;26:537-545.
4. Fleisig GS, Andrews JR, Dillman CJ, Escamilla RF. Kinetics of baseball pitching with implications about injury mechanisms. *Am J Sports Med* 1995;23:233-239.
5. Mihata T, McGarry MH, Tibone JE, Fitzpatrick MJ, Kinoshita M, Lee TQ. Biomechanical assessment of type II superior labral anterior-posterior (SLAP) lesions associated with anterior shoulder capsular laxity as seen in throwers: A cadaveric study. *Am J Sports Med* 2008;36:1604-1610.
6. Lo IK, Lind CC, Burkhart SS. Glenohumeral arthroscopy portals established using an outside-in technique: Neurovascular anatomy at risk. *Arthroscopy* 2004;20:596-602.
7. Yian E, Wang C, Millett PJ, Warner JJ. Arthroscopic repair of SLAP lesions with a bioknotless suture anchor. *Arthroscopy* 2004;20:547-551.
8. Cohen DB, Coleman S, Drakos MC, et al. Outcomes of isolated type II SLAP lesions treated with arthroscopic fixation using a bioabsorbable tack. *Arthroscopy* 2006;22:136-142.
9. O'Brien SJ, Allen AA, Coleman SH, Drakos MC. The trans-rotator cuff approach to SLAP lesions: Technical aspects for repair and a clinical follow-up of 31 patients at a minimum of 2 years. *Arthroscopy* 2002;18:372-377.
10. Charles MD, Christian DR, Cole BJ. An age and activity algorithm for treatment of type II SLAP tears. *Open Orthop J* 2018;12:271-281.
11. Sayde WM, Cohen SB, Ciccotti MG, Dodson CC. Return to play after type II superior labral anterior-posterior lesion repairs in athletes: A systematic review. *Clin Orthop Relat Res* 2012;470:1595-1600.
12. Brockmeier SF, Voos JE, Williams RJ 3rd, et al. Outcomes after arthroscopic repair of type-II SLAP lesions. *J Bone Joint Surg Am* 2009;91:1595-1603.
13. Chalmers PN, Monson B, Frank RM, et al. Combined SLAP repair and biceps tenodesis for superior labral anterior-posterior tears. *Knee Surg Sports Traumatol Arthrosc* 2016;24:3870-3876.
14. Bents EJ, Brady PC, Adams CR, Tokish JM, Higgins LD, Denard PJ. Patient-reported outcomes of knotted and knotless glenohumeral labral repairs are equivalent. *Am J Orthop (Belle Mead NJ)* 2017;46:279-283.
15. Thal R, Nofziger M, Bridges M, Kim JJ. Arthroscopic Bankart repair using knotted or BioKnotless suture anchors: 2- to 7-year results. *Arthroscopy* 2007;23:367-375.