

CASE REPORT

Kushi-yaki-related *Streptococcus suis* meningitis with ventriculitis: A case report

Masaru Kurihara¹  | Michitaka Nasu² | David Itokazu³ | Yasuharu Tokuda⁴

¹Department of Hospital Medicine, Urasoe General Hospital, Okinawa, Japan

²Department of Emergency and Critical Care Medicine, Urasoe General Hospital, Okinawa, Japan

³Okinawa Asia Clinical Investigation Synergy, Okinawa, Japan

⁴Muribushi Okinawa Center for Teaching Hospitals, Okinawa, Japan

Correspondence

Masaru Kurihara, Department of Hospital Medicine, Urasoe General Hospital, Okinawa, Japan.

Email: masarukurihara1025@gmail.com

Abstract

Streptococcus suis causes a zoonotic disease that commonly manifests as meningitis. People handle pork or its derivatives are at a high risk of infection. Handwashing and donning personal protective equipment are the practical preventive measures.

KEYWORD

Streptococcus suis, infectious disease, ventriculitis

1 | INTRODUCTION

This report describes *Streptococcus suis* meningitis with ventriculitis in a 66-year-old kushi-yaki chef, who presented with fever and meningeal irritation signs. Cerebrospinal fluid testing revealed increased cell counts and protein levels, and the presence of gram-positive cocci. Kushi-yaki chefs are at high risk of this infection, and prophylaxis should be considered.

Streptococcus suis, a gram-positive, facultative anaerobic bacterium, is an emerging zoonotic pathogen.¹ *Streptococcus suis* is endemic in the upper respiratory tract of pigs, particularly in the tonsils and nasal cavity, but it can also be found in the genitalia and gastrointestinal tract.^{2,3} Although multiple serotypes can infect pigs, *S. suis* serotype 2 is the most common human pathogen.^{2,3} As of 2012, 1584 human cases of *S. suis* serotype 2 have been reported.⁴ *Streptococcus suis* infections are more prevalent in South-East Asia owing to the high consumption of pork and frequent small-scale pig rearing.⁵⁻⁷ People with occupations that involve contact with pigs or pork, such as slaughterhouse workers and butchers, are at a particularly high risk of *S. suis* infection.⁸

The characteristic clinical manifestation of *S. suis* infection in human beings is meningitis.^{4,9} Irreversible hearing loss and vestibular dysfunction are well-known complications of *S. suis* meningitis,^{4,10} and its causes, treatments, and predictive scores have been investigated.¹¹ However, the underlying causes of less frequent complications, such as ventriculitis, are poorly understood.^{4,10} Herein, we report a case of meningitis with pyogenic ventriculitis associated with *S. suis* infection.

2 | CASE HISTORY

A 66-year-old Japanese man presented to the hospital with a 4-day history of chills, fever, nausea, vomiting, and a medical history of type 2 diabetes mellitus. The patient was a kushi-yaki (skewered foods) chef and handled pork while cooking without gloves or other personal protective equipment. He had no travel history. We obtained informed consent from the patient for the publication of this case report. Ethics approval was not required per the relevant review board.

This is an open access article under the terms of the Creative Commons Attribution-NonCommercial-NoDerivs License, which permits use and distribution in any medium, provided the original work is properly cited, the use is non-commercial and no modifications or adaptations are made.

© 2021 The Authors. *Clinical Case Reports* published by John Wiley & Sons Ltd.

2.1 | Examination and investigations

Upon admission, he was disoriented; his vital signs were as follows: body temperature, 38.1°C; heart rate, 100/min; blood pressure, 168/98 mm Hg; and respiratory rate, 16/min. He had signs of nuchal rigidity. He had no anisocoria, intact light reflexes, and no pain on sinus tapping. Other physical examination findings were normal. Laboratory findings on admission were as follows (Table 1): white blood cells, 16 200/ μ L; hemoglobin, 17.3 g/dL; and platelets, 4.6×10^4 / μ L. Liver enzyme levels were elevated: aspartate aminotransferase, 123 IU/L and alanine aminotransferase, 114 IU/L. Renal function was also exacerbated: blood urea nitrogen, 28.1 mg/dL and creatinine, 1.23 mg/dL. The C-reactive protein level and erythrocyte sedimentation rate were 24.1 mg/L and 17 mm/h, respectively. Anti-HIV antibodies were absent, and the HbA1c level was 7.3%.

Head computed tomography showed no evidence of brain herniation. We identified positive signs of meningeal irritation and conducted a fluid test. Cerebrospinal fluid (CSF) had a cloudy appearance, and analysis revealed a pressure of 24 cm CSF, a cell count of 496 cells/ μ L (84% neutrophils and 16% lymphocytes), protein levels of 417 mg/dL, and sugar levels of 1 mg/dL. Gram staining on the CSF revealed gram-positive cocci.

2.2 | Differential diagnosis and treatment

These findings led us to diagnose bacterial meningitis caused by gram-positive bacteria. Ceftriaxone (2.0 g in 12-hour intervals), vancomycin (1.0 g in 8-hour intervals), ampicillin (2.0 g in 4-hour intervals), and dexamethasone (9.9 mg in 6-hour intervals) were administered. On day 2, the fever subsided, but the patient experienced a generalized seizure. Levetiracetam 1000 mg was administered to control the seizure. Head diffusion-weighted magnetic resonance imaging (MRI) showed a high signal in the bilateral lateral ventricular triangles, indicating ventriculitis (Figure 1), and *S. suis* serotype 2 was identified in CSF culture by agglutination with antisera. A careful physical examination revealed two small scars in the patient's left hand (Figure 2). A family member mentioned that the patient often accidentally pointed the skewer at his hand when cooking pork on a spit.

2.3 | Outcome and follow-up

Altogether, our findings suggested that *S. suis* infected the patient through the scars in his hands, causing meningitis, ventriculitis, and inner ear dysfunction. The antibiotic treatment was changed from ceftriaxone, vancomycin, and ampicillin

TABLE 1 Laboratory data of the patient

Variable	Reference range	Value on admission
Red blood cell (per μ L)	3 860 000-4 920 000	4 910 000
Hemoglobin (g/dL)	11.6-14.8	17.3
Hematocrit (%)	35.1-44.4	47.8
White blood cell (per μ L)	3300-8600	16 200
Differential blood count (per μ L)		
Neutrophils (%)	0.0-2.5	39.0
Lymphocytes (%)	16.5-49.5	43.8
Monocytes (%)	2.0-10.0	14.1
Eosinophil (%)	0.0-8.5	2.8
Basophil (%)	0.0-2.5	0.3
Platelets (per μ L)	158 000-348 000	46 000
Sodium (mmol/L)	135-145	138
Potassium (mmol/L)	3.6-4.8	3.4
Chloride (mmol/L)	101-108	100
Urea nitrogen (mg/dL)	8.0-20.0	28.1
Creatinine (mg/dL)	0.46-0.79	1.23
Alanine aminotransferase (U/L)	13-30	114
Aspartate aminotransferase (U/L)	7-23	123
Alkaline phosphatase (U/L)	106-322	223
Creatine kinase (U/L)	41-153	140
Lactate dehydrogenase (U/L)	124-222	264
C-reactive protein (mg/dL)	0.0-0.1	24.1
Erythrocyte sedimentation rate (mm/h)	1-7	17
Glycated hemoglobin (%)	4.6-6.2	7.3

to penicillin G (150 000 units/kg/day in 4-hour intervals) according to antimicrobial susceptibility results (Table 2).

Despite dexamethasone treatment for 4 days, the patient had a persistent hearing impairment. Hearing tests revealed a decrease of 110 dB on the right and left sides. Auditory brainstem response assessment showed a value of 100 dB without a bilateral response. On day 6, contrast MRI showed right cochlea enhancement, suggesting right labyrinthitis. We concluded that the patient had sensorineural hearing loss owing to inner ear damage. Therefore, corticosteroid therapy was administered. Intravenous methylprednisolone (250 mg/day) was initiated; the dose was tapered to 125 mg/day on day 8, 60 mg/day on day 10, and 40 mg/day on day 12.

FIGURE 1 (A) Diffusion-weighted magnetic resonance images showing high signals in the bilateral ventricles (arrow) and (B) apparent diffusion coefficient maps showing low signals

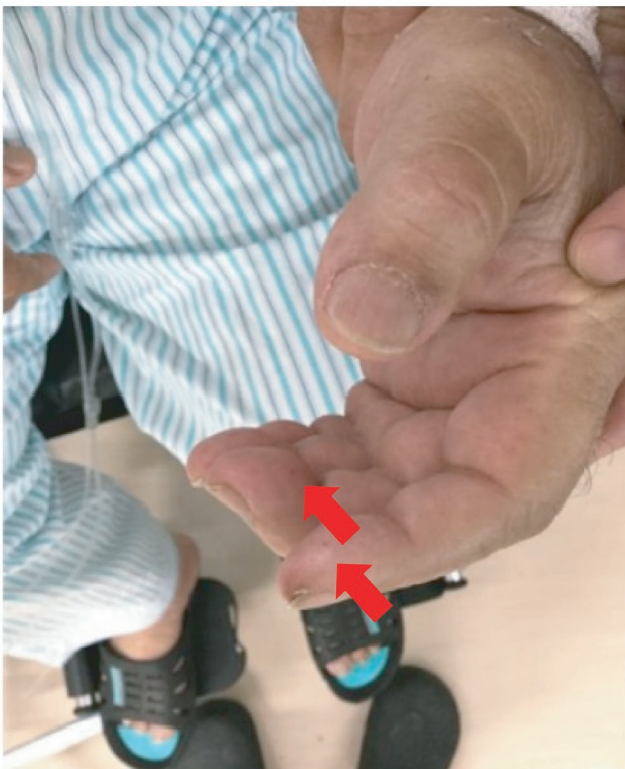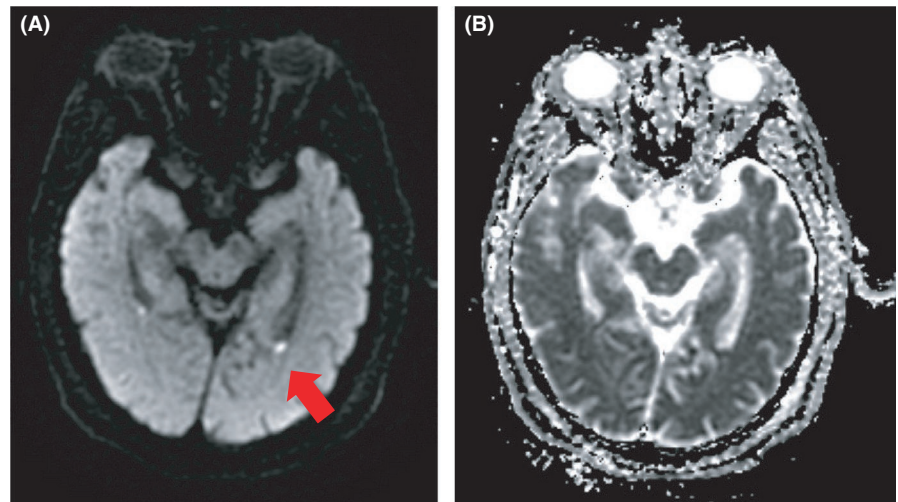


FIGURE 2 A photograph of the patient's hand. A small scar can be seen on the left hand, which may have been accidentally caused by a skewer (arrow)

On day 6, the patient's general condition improved, and CSF examination revealed improved pressure (16 cm CSF). Laboratory values also improved as follows: cell count, 44 cells/ μ L; protein level, 84 mg/dL; and plasma glucose level, 180 mg/dL. On day 20, MRI showed improvement in ventriculitis, and penicillin G was administered for 22 days. After treatment completion, the patient showed no signs of recurrent meningitis and was discharged on day 40. Inner ear dysfunction did not improve, and cochlear implant surgery

TABLE 2 Antimicrobial susceptibility test results

	MIC (μ g/mL)	MIC value
Penicillin G	≤ 0.03	S
Ampicillin	≤ 0.12	S
Cefazoline	≤ 0.25	S
Cefotiam	0.5	S
Cefotaxime	≤ 0.06	S
Ceftriaxone	≤ 0.06	S
Imipenem hydrate/cilastatin	≤ 0.12	S
Erythromycin	> 8	R
Clindamycin	> 4	R
Minocycline	> 8	R
Levofloxacin	1	S
Vancomycin	≤ 1	S
Teicoplanin	≤ 1	S

Note: The antimicrobial susceptibility of *S suis* strains was determined by Clinical and Laboratory Standards Institute (CLSI).²⁵

Abbreviations: MIC, minimum inhibitory concentration; R, resistance; S, sensitive.

was performed 4 months after disease onset. The patient gradually improved and recovered without relapse.

3 | DISCUSSION

We reported a rare case of pyogenic ventriculitis associated with *S. suis* infection. People who handle pork or its derivative products are at a high risk of *S. suis* infection¹ since the route of entry of the organism into human beings is via small skin wounds.¹² However, recent studies have shown that only 20% of patients reported having skin wounds when handling pork.¹³ Kushiyaki is a traditional Japanese dish in

which bite-sized pieces of chicken or pork are skewered and grilled over an open fire. In this case, the patient was a kushiyaki chef who handled pork with his bare hands. Since there were small scars on his hands, probably linked to cooking kushiyaki, we considered that to be the route of his infection. Kushiyaki chefs may be at a higher risk of infection than people engaging in other activities involving pigs. As there is no *S. suis* vaccine for human beings,¹⁴ handwashing and wearing personal protection equipment are the most practical preventive measures.

Several patients with *S. suis* meningitis successfully recovered following a treatment scheme similar to that used for pneumococcal meningitis.¹⁵ However, other patients with *S. suis* meningitis showed relapse 2 weeks post-treatment completion and required prolonged therapy (4-6 weeks).¹⁶ DeJace et al suggested that treatment should be tailored to clinical and laboratory findings.¹⁷ A recent review found that the antimicrobial treatment duration ranged from 7 to 42 days in cases of meningitis, spondylitis, and endocarditis.¹ In this case, *S. suis* infection only led to meningitis and pyogenic ventriculitis. Ventriculitis is a rare condition secondary to meningitis¹⁸ that can cause persistent infection and treatment failure.^{19,20} Additionally, if meningitis is associated with ventriculitis, prolonged antibiotic treatment might be required. Only one case of *S. suis* meningitis associated with ventriculitis has been reported so far; the patient required longer antibiotic treatment than the usual 24-day course for bacterial meningitis.²¹ However, few studies have reported ventriculitis in cases involving long-term antimicrobial treatment for *S. suis* meningitis, suggesting that ventriculitis might be an underlying cause for disease recurrence.²² Furthermore, although our patient was treated for a longer period because of the presence of ventriculitis, the recommended treatment duration for *S. suis*-associated ventriculitis has not been determined²³; thus, further studies are needed. As ventriculitis is most frequently detected based on diffusion-weighted MRI findings,²⁴ MRI should be performed in cases of suspected ventriculitis, especially in cases of *S. suis* meningitis involving a poor response to treatment.

4 | CONCLUSION

We reported a rare case of pyogenic ventriculitis associated with *S. suis* infection. The patient's occupation as a kushiyaki chef may be linked to a high infection risk because it involves handling pork. Therefore, preventive measures should be taken to avoid infection. Additionally, MRI should be performed for patients with *S. suis* ventriculitis to ensure suitable and effective treatment. Since the appropriate treatment duration has not yet been determined, further reports of *S. suis* ventriculitis are needed.

CONFLICT OF INTEREST

None declared.

AUTHOR CONTRIBUTIONS

All authors critically revised the report, commented on drafts of the manuscript, and approved the final report.

ETHICAL APPROVAL

We have obtained informed consent from the patient for publication of this case report.

DATA AVAILABILITY STATEMENT

The datasets used and/or analyzed during the current study are available from the corresponding author on reasonable request.

ORCID

Masaru Kurihara  <https://orcid.org/0000-0001-9195-4202>

REFERENCES

1. Rayanakorn A, Goh BH, Lee LH, Khan TM, Saokaew S. Risk factors for *Streptococcus suis* infection: a systematic review and meta-analysis. *Sci Rep*. 2018;8(1):1-9. <https://doi.org/10.1038/s41598-018-31598-w>
2. Zheng JX, Li Y, Zhang H, Fan HJ, Lu CP. Identification and characterization of a novel hemolysis-related gene in *Streptococcus suis* serotype 2. *PLoS ONE*. 2013;8(9):e74674. <https://doi.org/10.1371/journal.pone.0074674>. eCollection 2013.
3. Yu H, Jing H, Chen Z, et al. Human *Streptococcus suis* outbreak, Sichuan, China. *Emerg Infect Dis*. 2006;12(6):914-920. <https://doi.org/10.3201/eid1206.051194>
4. Huong VTL, Ha N, Huy NT, et al. Epidemiology, clinical manifestations, and outcomes of *Streptococcus suis* infection in humans. *Emerg Infect Dis*. 2014;20(7):1105-1114. <https://doi.org/10.3201/eid2007.131594>
5. Suankratay C, Intalapaporn P, Nunthapisud P, Arunyingmongkol K, Wilde H. *Streptococcus suis* meningitis in Thailand. *Southeast Asian J Trop Med Public Health*. 2004;35(4):868-876.
6. Wertheim HF, Nguyen HN, Taylor W, et al. *Streptococcus suis*, an important cause of adult bacterial meningitis in Northern Vietnam. *PLoS ONE*. 2009;4(6):e5973. <https://doi.org/10.1371/journal.pone.0005973>
7. Feng Y, Zhang H, Ma Y, Gao GF. Uncovering newly emerging variants of *Streptococcus suis*, an important zoonotic agent. *Trends Microbiol*. 2010;18(3):124-131. <https://doi.org/10.1016/j.tim.2009.12.003>
8. Wertheim HF, Nghia HD, Taylor W, Schultsz C. *Streptococcus suis*: an emerging human pathogen. *Clin Infect Dis*. 2009;48(5):617-625. <https://doi.org/10.1556/030.2020.01123>
9. Ágoston Z, Terhes G, Hannauer P, Gajdács M, Urbán E. Fatal case of bacteremia caused by *Streptococcus suis* in a splenectomized man and a review of the European literature. *Acta Microbiol Immunol Hung*. 2020;67(3):148-155. <https://doi.org/10.1556/030.2020.01123>
10. Navacharoen N, Chantharochavong V, Hanprasertpong C, Kangsanarak J, Lekagul S. Hearing and vestibular loss in

- Streptococcus suis* infection from swine and traditional raw pork exposure in northern Thailand. *J Laryngol Otol.* 2009;123(8):857-862. <https://doi.org/10.1017/S0022215109004939>
11. Rayanakorn A, Katip W, Goh BH, Oberdorfer P, Lee LH. A risk scoring system for predicting *Streptococcus suis* hearing loss: a 13-year retrospective cohort study. *PLoS ONE.* 2020;15(2):e0228488. <https://doi.org/10.1371/journal.pone.0228488>
 12. Segura M, Calzas C, Grenier D, Gottschalk M. Initial steps of the pathogenesis of the infection caused by *Streptococcus suis*: fighting against nonspecific defenses. *FEBS Lett.* 2016;590(21):3772-3799. <https://doi.org/10.1002/1873-3468.12364>
 13. van Samkar A, Brouwer MC, Schultsz C, van der Ende A, van de Beek D. *Streptococcus suis* meningitis: a systematic review and meta-analysis. *PLoS Negl Trop Dis.* 2015;9(10):e0004191. <https://doi.org/10.1371/journal.pntd.0004191>
 14. Rieckmann K, Pendzialek SM, Vahlenkamp T, Baums CG. A critical review speculating on the protective efficacies of autogenous *Streptococcus suis* bacterins as used in Europe. *Porcine Health Manag.* 2020;6:12. <https://doi.org/10.1186/s40813-020-00150-6>
 15. Mai NTH, Hoa NT, Nga TVT, et al. *Streptococcus suis* meningitis in adults in Vietnam. *Clin Infect Dis.* 2008;46(5):659-667. <https://doi.org/10.1086/527385>
 16. Gottschalk M, Segura M, Xu J. *Streptococcus suis* infections in humans: the Chinese experience and the situation in North America. *Animal Health Res Rev.* 2020;8(1):29-45. <https://doi.org/10.1017/S1466252307001247>
 17. Dejace J, Bagley P, Wood E. *Streptococcus suis* meningitis can require a prolonged treatment course. *Int J Infect Dis.* 2017;65:34-36. <https://doi.org/10.1016/j.ijid.2017.09.011>
 18. Gronthoud F, Hassan I, Newton P. Primary pyogenic ventriculitis caused by *Neisseria meningitidis*: case report and review of the literature. *JMM Case Rep.* 2017;4(1):e005078. <https://doi.org/10.1099/jmmcr.0.005078>
 19. Jayendrakumar CI, Ganesan DB, Thampi SJ, Natarajan V. Primary pyogenic ventriculitis caused by *Streptococcal pneumoniae* in adults. *J Family Med Prim Care.* 2019;8(11):3745-3747. https://doi.org/10.4103/jfmmpc.jfmmpc_688_19
 20. Hazany S, Go JL, Law M. Magnetic resonance imaging of infectious meningitis and ventriculitis in adults. *Top Magn Reson Imaging.* 2014;23(5):315-325. <https://doi.org/10.1097/RMR.00000000000000034>
 21. Yanase T, Morii D, Kamio S, et al. The first report of human meningitis and pyogenic ventriculitis caused by *Streptococcus suis*: a case report. *J Infect Chemother.* 2018;24(8):669-673. <https://doi.org/10.1016/j.jiac.2018.01.009>
 22. Huong VT, Long HB, Kinh NV, et al. Long-term outcomes of patients with *Streptococcus suis* infection in Viet Nam: a case-control study. *J Infect.* 2018;76(2):159-167.
 23. Chaudhuri A, Martin P, Kennedy P, et al. EFNS guideline on the management of community-acquired bacterial meningitis: report of an EFNS Task Force on acute bacterial meningitis in older children and adults. *Eur J Neurol.* 2008;15(7):649-659. <https://doi.org/10.1111/j.1468-1331.2008.02193.x>
 24. Fukui MB, Williams RL, Mudigonda S. CT and MR imaging features of pyogenic ventriculitis. *AJNR Am J Neuroradiol.* 2001;22(8):1510-1516.
 25. Patel JB, Weinstein M, Eliopoulos G, Jenkins S, Lewis J, Limbago B. *M100 Performance standards for antimicrobial susceptibility testing.* Annapolis Junction, MD: Clinical and Laboratory Standards Institute; 2017:240.

How to cite this article: Kurihara M, Nasu M, Itokazu D, Tokuda Y. Kushiya-related *Streptococcus suis* meningitis with ventriculitis: A case report. *Clin Case Rep.* 2021;9:e04108. <https://doi.org/10.1002/ccr3.4108>: