

# Is video laryngoscopy easier than direct laryngoscopy for intubation in patients with contracture neck?

## ABSTRACT

**Background and Objective:** Postburn contracture (PBC) of the neck is commonly seen after acute burn in the face and neck region. Managing the airway is a challenge due to functional and anatomical deformities. We compared the ease of intubation using video and direct laryngoscopes.

**Material and Methods:** Eighty patients, 18–60 years of age with ASA physical status I/II with Onah's types 1 and 2 contracture of the neck were randomized in this study. Group DL were intubated by direct laryngoscopy (DL) using Macintosh blade and Group VL by video laryngoscopy (VL) using King Vision. The outcome measures were ease of intubation (EOI), Cormack-Lehane (CL) grading, and associated complications if any.

**Results:** EOI score was significantly lower in group VL ( $0.42 \pm 0.84$ ) as compared to group DL ( $0.85 \pm 1.21$ ) ( $P = 0.048$ ) as was the use of external maneuvers (group VL: 17.5%; group DL: 42.5%;  $P = 0.015$ ), and the use of stylet (group VL: 0%; group DL: 20%,  $P = 0.005$ ). CL grading improved significantly in group VL ( $P < 0.001$ ). Occurrence of complications was negligible in both the groups. A single failure in group DL needed rescue intubation.

**Conclusion:** Intubation with a video laryngoscope was easier than with DL in patients with mild-to-moderate contracture neck with mouth opening  $>3$  cm and MPG I/II.

**Key words:** Contracture neck; direct laryngoscopy; ease of intubation; video laryngoscopy

## Introduction

Securing the airway is the primary job of an anesthesiologist. Intubation failure is an important cause of morbidity and mortality during anaesthesia. Patients with postburn contracture (PBC) of the face and neck region usually have a difficult airway, and airway management of these patients (PBC neck) requires expertise. Scarring or fibrosis after burns may result in decreased mouth opening and the oropharyngeal cavity, blocked nasal passages, restricted movement of atlantooccipital joint and a flexed neck, trachea which may


be deviated/pulled or compressed, and a noncompliant submandibular space. Alignment of the oral, pharyngeal, and the laryngeal axes is required for direct laryngoscopy (DL), hence the above features can make direct laryngoscopy difficult.<sup>[1]</sup>

Awake intubation with a fiberoptic bronchoscope is the gold standard in airway management.<sup>[2]</sup> It requires time, technical expertise, and patient cooperation. It also has a long learning curve. Giving local anesthesia may be difficult because of anatomical abnormalities due to scarring. Therefore, it is

This is an open access journal, and articles are distributed under the terms of the Creative Commons Attribution-NonCommercial-ShareAlike 4.0 License, which allows others to remix, tweak, and build upon the work non-commercially, as long as appropriate credit is given and the new creations are licensed under the identical terms.

**For reprints contact:** reprints@medknow.com

**How to cite this article:** Gupta R, Sahni A. Is video laryngoscopy easier than direct laryngoscopy for intubation in patients with contracture neck?. Saudi J Anaesth 2020;14:206-11.

Access this article online	
<b>Website:</b> www.saudija.org	<b>Quick Response Code</b> 
<b>DOI:</b> 10.4103/sja.SJA_808_19	

## ROOPALI GUPTA, AMEETA SAHNI

Department of Anesthesia and Intensive Care, Vardhman Mahavir Medical College and Safdarjung Hospital, New Delhi, India

**Address for correspondence:** Dr. Roopali Gupta, Department of Anesthesia and Intensive Care, Vardhman Mahavir Medical College and Safdarjung Hospital, New Delhi, India. E-mail: gupta.rpali@gmail.com

**Submitted:** 25-Dec-2019, **Accepted:** 16-Jan-2020, **Published:** 05-Mar-2020

necessary to have other simple, reliable, safe, and effective equipment for intubation.

Other methods include anesthesia with face mask ventilation or ketamine with the release of scar of contracture neck under local anaesthesia (LA), tumescent anaesthesia followed by intubation, or using Laryngeal Mask Airway (LMA) as a conduit for intubation. A surgical airway may be needed where the above options are not possible as an emergency.

Over the past few years, a number of video laryngoscopes (VL) have become available for clinical use.<sup>[3]</sup> They offer many advantages, especially where there is difficult laryngeal visualization and decreased neck movement. They have a shorter learning curve and better portability as compared to fiber-optic bronchoscopy.<sup>[4]</sup> With VL, the alignment of the 3 axes is not required.

We compared the ease of intubation using King Vision VL (channelled blade) with Macintosh DL in patients of mild or moderate PBC neck.

### Materials and Methods

We did a prospective randomized controlled trial in the Department of Anaesthesia and Intensive Care, Vardhman Mahavir Medical College and Safdarjung Hospital, New Delhi, after obtaining approval from the Hospital Ethics Committee and registering the trial. (CTRI/2017/06/008822).

After obtaining informed consent, 80 ASA physical status I or II patients, 18–60 years of age, having mild or moderate contracture of the neck (Onah’s classification<sup>[5]</sup> Type 1 and Type 2) [Appendix A], with Mallampatti grade I or II and a mouth opening of at least 3 cm, planned for elective surgery under general anesthesia, were included. Patients who had a neck pathology other than the scar, body mass index (BMI) >30 kg/m<sup>2</sup>, reactive airway, gastroesophageal reflux disease, or neck circumference >40 cm, and pregnant patients were excluded. They were randomized using a computer-generated random number and the sealed envelope technique to two groups: group DL and group VL. For group DL patients, we used the Macintosh DL and for group VL, we used the King Vision VL (channelled blade) [Figure 1].

Preoperatively, demographics (age, sex, height, weight, BMI) and airway parameters (neck circumference, mouth opening, Mallampatti grade, degree of neck extension, thyromental distance, hyomental distance, mentosternal distance, horizontal length of mandible, jaw protrusion, and upper lip bite test) were recorded. In the operating room, pulse

oximeter, NIBP, ECG, and capnography were attached. After premedication with inj. glycopyrrolate 0.2 mg IV and inj. fentanyl 2 µg/kg, patients were preoxygenated for 3 min. Anesthesia was induced with inj. propofol at 2–3 mg/kg body weight, till loss of verbal contact. After ensuring bag and mask ventilation, inj. vecuronium 0.1 mg/kg IV was given. Laryngoscopy and intubation were done after ventilating for 4 min with oxygen and isoflurane (0.8%–1.0%) using the designated laryngoscope in the respective group. Successful intubation confirmed by continuous-wave capnography was the primary endpoint of the study. The single anesthesiologist who intubated was experienced (with a minimum of 50 laryngoscopies prior to this).<sup>[6]</sup> Each time the laryngoscope entered the oral cavity was counted as an attempt. If oxygen saturation fell below 92%, laryngoscope was removed and patient ventilated with 100% oxygen. Only two attempts were allowed with each laryngoscope. After two unsuccessful attempts, patients were intubated using Intubating Laryngeal Mask Airway (ILMA) and this was labelled as a failed attempt.

The following parameters were recorded:

- A. The laryngeal view described according to Cormack–Lehane (CL) score<sup>[7]</sup>
- B. Ease of intubation (EOI): This was an objective score,

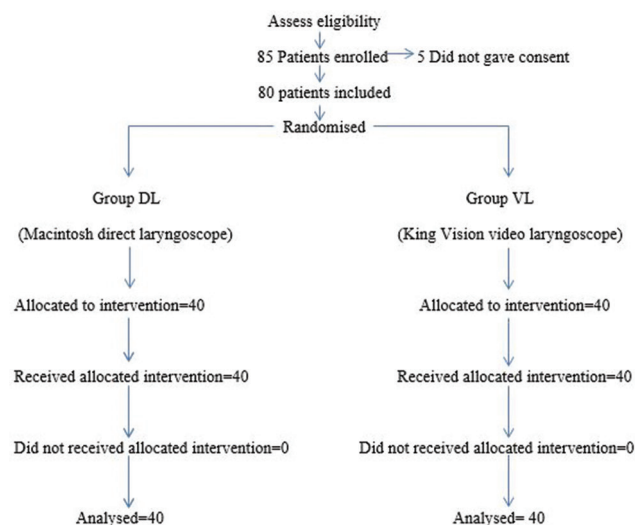


Figure 1: Consort design and recruitment of participants

Table 1: Ease of intubation (EOI) score

	0	1
Use of External Maneuvers	No	Yes
Use of Stylet	Not used	Used
Use of Bougie	Not used	Used
Time taken to intubate (TTI)	≤30 s	>30 s
Number of attempts	One	Two

Total score: 0 - Very easy intubation, 1 - Easy intubation, 2 - Moderately easy intubation, 3 - Moderately difficult intubation, 4 - Difficult intubation, 5 - Very difficult intubation

with a value of 0 or 1, using five parameters [Table 1] The total score ranged from 0–5, with 0 being very easy and 5 being very difficult

Time taken to intubate (TTI), in seconds, was calculated from the entry of laryngoscope in the oral cavity to the first capnography waveform on the monitor. In the case of two attempts, TTI was taken for the successful attempt

- C. Any adverse event or a technical snag with the equipment was recorded.

### Statistical analysis

A study by Jungbauer *et al.* compared VL to DL and the optimizing manoeuvres were reduced (1.2 vs 0.5) in VL as compared to DL.<sup>[4]</sup> Taking these values as reference the minimum required sample size with 80% power of study and 5% level of significance was 35 patients in each study group. Assuming the attrition to be 10%, we studied a total of 80 patients.

Data were analyzed using statistical package for social sciences (SPSS) latest version. The Kolmogorov-Smirnov test was used to ascertain that the data was normally distributed. If the normality was rejected then non parametric test was used. For intergroup comparison, quantitative variables were compared using unpaired *t*-test/Mann-Whitney test (when the data sets were not normally distributed) and the qualitative variable was compared using Chi-square test/Fisher's exact test.  $P < 0.05$  was considered statistically significant.

### Results

The two groups were similar in patient demographics and airway assessment parameters [Table 2].

#### Intraoperative parameters

##### Ease of intubation

The ease of intubation score (EOI) was reduced significantly in group VL ( $0.42 \pm 0.84$ ) as compared to group DL ( $0.85 \pm 1.21$ ) ( $P$ -value- 0.048) [Table 3]. The use of external maneuvers (VL-17.5%, DL-42.5%,  $P$  value = 0.015) and the use of stylet (VL- 0%, DL-20%,  $P$  value = 0.005) was also significantly reduced in the VL group.

However, no significant difference was seen in the use of bougie ( $P$ -value = 1.000), number of attempts ( $P$ -value = 1.000) and time of intubation (mean time taken for intubation was  $25.12 \pm 17.07$  s in group DL vs  $22.78 \pm 10.05$  s in group VL,  $P$  value = 0.790) in both the groups.

##### Associated complications

No patient had a drop in saturation below 95% in both the

groups. One patient in group DL (2.5%) had mucosal trauma which was insignificant. ( $P$ -value = 1.000).

#### Cormack-Lehane grade

CL grading was significantly better in group VL compared to DL. All patients in group VL (100%) had CL grade I compared to 40% cases in group DL. ( $P$ -value  $< 0.001$ ) [Figure 2].

### Discussion

There is number of case reports where VL are used in difficult airway including mentosternal contractures.<sup>[2,8-11]</sup> There are

**Table 2: Showing demographic and airway parameters of the patients of both the groups**

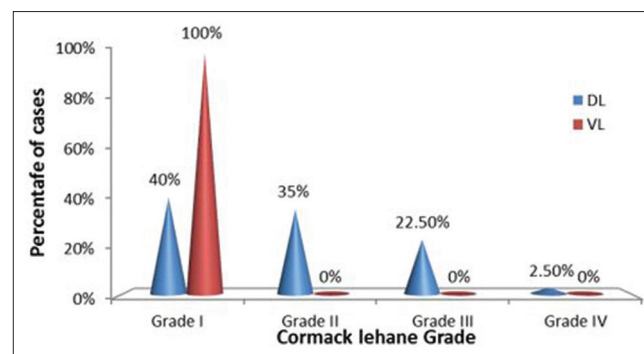
	DL (n=40)	VL (n=40)	P
Age (years)	25.75 (6.19)	26.55 (8.96)	0.791
Sex (M/F)	15/25	14/26	0.424
Height (cm)	158.3 (7.79)	156.9 (7.37)	0.133
Weight (kg)	55.02 (11.78)	55.35 (11.13)	0.623
BMI (kg/m <sup>2</sup> )	21.81 (3.61)	22.32 (3.48)	0.548
Neck Circumference (cm)	35.33 (3.74)	35.35 (3.7)	0.965
Mouth Opening (cm)	3.88 (0.51)	3.78 (0.61)	0.338
Mallampatti Grade (I/II)	10/30	6/34	0.264
Neck Extension (°)	22.85 (8.53)	23.8 (8.03)	0.437
Thyromental Distance (cm)	5.85 (1.4)	5.9 (1.41)	0.873
Hyomental Distance (cm)	4.3 (1.14)	4.32 (1.16)	0.994
Mentosternal Distance (cm)	11.56 (2.69)	11.7 (2.67)	0.426
Horizontal length of Mandible (cm)	9.72 (0.84)	9.65 (0.71)	0.786

Data are presented as mean (SD) or numbers (/)

**Table 3: Shows ease of intubation characteristics in both the groups**

	DL (n=40)	VL (n=40)	P
1. Use of external maneuvers (Y/N)	42.5%/57.5%	17.5%/82.5%	0.015
2. Use of stylet (Y/N)	20%/80%	0%/100%	0.005
3. Use of bougie (Y/N)	5%/95%	5%/95%	1.000
4. Number of attempts (1/2)	95%/5%	97.5%/2.5%	1.000
5. Time taken to intubate (mean±SD)	25.12±17.07	22.78±10.05	0.790
Ease of intubation score (mean±SD)	0.85±1.21	0.42±0.84	0.048

Y=Yes, N=NO,  $P < 0.05$ =Significant



**Figure 2: Distribution of cases according to Cormack-Lehane grading in both the groups**

randomized trials in patients and manikin in normal and difficult airway scenarios but hardly any in patients with PBC neck. Park *et al.*<sup>[9]</sup> had used the GlideScope in a patient with severe mentosternal contracture. Gaszynska and Gaszynski<sup>[8]</sup> published two cases wherein awake intubation was done for patients who had pharyngeal and laryngeal tumors with King Vision video laryngoscope.

The degree of contracture has been described by Onah<sup>[5]</sup> in four groups depending on the position of the contracture band of tissue and also the extension or flexion possible away from the anatomical position. Each group is further divided into three subclasses based on the width of the contracted segment. We included patients with mild-to-moderate contracture neck belonging to Onah's 1 and 2.

Kumar *et al.*<sup>[12]</sup> conducted a study in 30 patients with postburn contracture and found that the predictors leading to difficult intubation in such patients were sternomental distance and Mallampatti grading. They also found that the burn contracture affected the sternomental distance.

Our results suggest that VL showed improved EOI scores and the CL view was significantly better with the DL. While CL grade I in VL group was 100%, in the DL group CL grade I, II, III and IV visualization was obtained in 16 (40%), 14 (35%), 9 (22.5%), and 1 (2.5%) patients. In concordance with our study, Stroumpoulis *et al.*<sup>[13]</sup> found that the VL increased the CL I and II views from 63.4% to 90.2% ( $P < 0.0005$ ) as compared to conventional laryngoscopy, whereas CL III and IV views declined from 36.6% to 9.8% ( $P < 0.0005$ ). Also, Murphy *et al.*<sup>[14]</sup> in a study on manikin found that both CL grading and POGO was better with KVVL as compared to DL in the simulated normal and difficult airway.

The success at first attempt was the same in both groups at 95% with DL and 97.55% with VL. One patient in group DL had a failed attempt where the rescue technique was used. While Gaszynska *et al.*<sup>[15]</sup> found first attempt successful intubation was comparable in King Vision VL and DL for intubation in manikin during CPR ( $P = 0.9032$ ), Malik *et al.*<sup>[16]</sup> also found that first attempt successful intubation was 88% with GlideScope, 72% with Pentax AWX compared to only 68% with Macintosh direct laryngoscope in 75 patients with predicted difficult intubation.

Though the time taken to intubation (TTI) was more in DL compared to VL ( $25.12 \pm 17.07$  sec in group DL vs  $22.78 \pm 10.05$  sec in group VL,  $P$  value = 0.790), it was statistically not significant. Gaszynska *et al.*<sup>[15]</sup> compared KVVL with Macintosh blade in a manikin where both laryngoscopes

showed similar mean intubation time: 17.91 s versus 16.6 s for the King Vision VL and Macintosh laryngoscope, respectively ( $P = 0.1888$ ). Akihisa *et al.*<sup>[17]</sup> in a study on manikin also found that the overall median intubation times were comparable with Macintosh laryngoscope (16.9 s, range 8.0–60.0) and King Vision channelled blade (20.5, range 7.2–60.0). Murphy *et al.*<sup>[14]</sup> studied manikin and cadavers with normal and simulated difficult airway and found that TTI was significantly reduced with King Vision VL (KVVL) in normal manikin airway and difficult cadaveric airway scenarios (3.4 s faster in normal manikin airway and 11.3 s faster in difficult cadaveric airway scenario). This contrasting result could be because the patient profile in both studies was entirely different.

Adnet *et al.*<sup>[18]</sup> proposed a score to predict difficult intubation which was termed as the intubation difficulty scale (IDS). We did not include Cormack Lehane grading, lifting force during intubation, number of supplementary operators, alternative techniques, and mobility of cords. CL grading and lifting force during intubation was not used because it would have led to bias in the study as two different types of laryngoscopic techniques were compared. KVVL does not need a lifting force and intubation is possible only if there is a good glottic view. Since, we had an experienced single anesthesiologist for the procedure, using supplementary operators, and alternative techniques were considered as a failed attempt. All the patients were paralyzed, therefore cords were immobile. We included TTI in our EOI score as difficulty in introducing and aligning to get a good glottic view would enhance the time taken and worsen the EOI score. TTI would also depend on the expertise of the anesthesiologist which we eliminated by having a single experienced one.

Thus, we used a 5-point scoring system for determining the ease of intubation. Each parameter was given a score of 0–1: time is taken to intubate, a number of attempts, use of a stylet, use of bougie, and the use of external maneuvers. While a score of 0 was very easy intubation, 5 implied very difficult intubation.

Ease of intubation score was significantly reduced in group VL ( $0.42 \pm 0.84$ ) as compared to group DL ( $0.85 \pm 1.21$ ) ( $P$ -value- 0.048), making intubation easier with VL. Similarly, Akihisa *et al.*<sup>[17]</sup> compared the Grading Scale of Intubation Difficulty (GSID, a 5 –point scale) in which they found that median GSID was 4 (range 2–5) with King Vision Non-Channelled (KVNC) blade as compared to 2 (1–5) with the King Vision Channelled (KVC) blade making it significantly lower with KVC ( $P < 0.001$ ).

In difficult airway situations, certain devices such as stylets, bougie, and external laryngeal manipulation, can make the laryngeal view better and aid intubation. With the use of VL, the use of such optimizing maneuvers can be reduced. In our study, the use of external maneuvers and stylet during laryngoscopy was significantly reduced in group VL compared to DL (17.5% vs 42.5%,  $P$  value = 0.015 and 0% vs 20%,  $P$  value = 0.005). However, little difference was observed with the use of bougie in both groups. In concordance with our results, Jungbauer *et al.*<sup>[4]</sup> also found that the use of optimizing maneuvers (use of a stylet, use of external laryngeal manipulation) in difficult airway scenario was significantly reduced with VL compared to DL (0.5 vs 1.2,  $P$  value <0.001).

Although minor trauma during the procedure was lower with KVVL, it was not statistically significant.<sup>[19]</sup> Al-Ghamdi *et al.*<sup>[20]</sup> compared the Macintosh, King Vision™, Airtraq® and GlideScope® laryngoscopes for normal airway management in 86 patients wherein channelled VL (King Vision VL, Airtraq) caused less mucosal trauma ( $P = 0.006$ ). However Alvis *et al.*<sup>[21]</sup> found that the fall in saturation below 90% was more in KVVL vs McGrath group in 66 adult patients posted for surgery (3 vs 0;  $P < 0.034$ ).

There were a few limitations to our study. In patients with contracture neck, there may be structural changes in the oral cavity which are not visible, resulting in difficulty in lifting the structures with a laryngoscope. Thus, this difficulty could have been included in EOI score. Hemodynamic changes associated with laryngoscopy could have been studied. Moreover, blinding was not possible in our study.

## Conclusion

With a VL, the laryngeal structures were better visualized (with better EOI scores and an improved Cormack-Lehane view) which facilitated intubation. Moreover, the need for optimizing manoeuvres and adjuncts (stylet) was reduced with VL as compared to DL in patients with mild-to-moderate contracture neck.

## Financial support and sponsorship

Nil.

## Conflicts of interest

There are no conflicts of interest.

## References

- Prakash S, Mullick P. Airway management in patients with post burn contractures of the neck. *Burns* 2015;41:1627-35.
- Ali QE, Siddiqui OA, Amir SH, Ahmad S, Jamil S. King Vision video laryngoscope for severe post burn contracture neck: An encouraging experience. *Rev Bras Anesthesiol* 2016. doi: 10.1016/j.bjane. 2014.10.006.
- Sakles JC, Mosier J, Chiu S, Cosentino M, Kalin L. A comparison of the C-Mac videolaryngoscope to the Macintosh direct laryngoscopy for intubation in the emergency department. *Ann Emerg Med* 2012;60:739-48.
- Jungbauer A, Schumann M, Brunkhorst V, Borgers A, Groeben H. Expected difficult tracheal intubation: A prospective comparison of direct laryngoscopy and videolaryngoscopy in 200 patients. *Br J Anaesthesia* 2009;102:546-50.
- Onah II. A classification system for post burn mentosternal contracture. *Arch Surg* 2005;140:671-5.
- Mulcaster J, Mills J, Hung O, MacQuarrie K, Law J, Pytka S, *et al.* Laryngoscopic intubation. *Anesthesiology* 2003;98:23-7.
- Cormack RS, Lehane J. Difficult tracheal intubation in obstetrics. *Anaesthesia* 1984;39:1105-11.
- Gaszynska E, Gaszynska T. The King Vision videolaryngoscope for awake intubation: Series of cases and literature review. *Ther Clin Risk Manag* 2014;10:475-8.
- Park CD, Lee HK, Yim JY, Kang IH. Anaesthetic management for a patient with severe mento sterna contracture: Difficult airway and scarce venous access-A case report. *Korean J Anesthesiol* 2013;64:61-4.
- Ali QE, Amir SH, Siddiqui OA, Jamil S. Airway management in severe post- burn contracture of the neck using Airtraq: A case series. *Indian J Anaesth* 2013;57:620-2.
- Gaszynski T. The use of the C-MAC videolaryngoscope for awake intubation in patients with a predicted extremely difficult airway: Case series. *Ther Clin Risk Manag* 2018;14:539-42.
- Kumar V, Powar R, Patil MC, Chaitra. Predictive factors of difficult intubation in post burn neck contracture- A study of 30 consecutive cases. *J Evid Based Med Healthc* 2015;2:3747-55.
- Stroumpoulis K, Pagoulatou A, Violari M, Ikonoumou I, Kalantzi N, Kastrinaki K, *et al.* Videolaryngoscopy in the management of the difficult airway: A comparison with the Macintosh blade. *Eur J Anaesthesiol* 2009;26:218-22.
- Murphy LD, Kovacs GJ, Reardon PM, Law JA. Comparison of the king vision video laryngoscope with the Macintosh laryngoscope. *J Emerg Med* 2014;47:239-46.
- Gaszynski E, Gaszynski T. Endotracheal intubation using the Macintosh laryngoscope or King vision video laryngoscope during uninterrupted chest compression. *Biomed Res Int* 2014;2014:250820.
- Malik MA, Subramaniam R, Maharaj CH, Harte BH, Laffey JG. Randomized controlled trial of the Pentax AWS, Glidescope, and Macintosh laryngoscopes in predicted difficult intubation. *Br J Anaesth* 2009;103:761-8.
- Akihisa Y, Maruyama K, Koyama Y, Yamada R, Ogura A, Andoh T. Comparison of intubation performance between the King Vision and Macintosh laryngoscopes in novice personnel: A randomised, crossover manikin study. *J Anaesthesia* 2014;28:51-7.
- Adnet F, Borron SW, Racine SX, Clemessy JL, Fournier JL, Plaisance P, *et al.* The intubation difficulty scale (IDS): Proposal and evaluation of a new score characterizing the complexity of endotracheal intubation. *Anesthesiology* 1997;87:1290-7.
- Howard-Quijano KJ, Huang YM, Matevosian R, Kaplan MB, Steadman RH. Video-assisted instruction improves the success rate for tracheal intubation by novices. *Br J Anaesth* 2008;101:568-72.
- Al-Ghamdi AA, El Tahan MR, Khidr AM. Comparison of the Macintosh, GlideScope®, Airtraq®, and King Vision™ laryngoscopes in routine airway management. *Minerva Anesthesiol* 2016;82:1278-87.
- Alvis BD, Hester D, Watson D, Higgins M, St Jacques P. Randomised controlled trial comparing the McGrath MAC video laryngoscope with the King Vision video laryngoscope in adult patients. *Minerva Anesthesiol* 2016;82:32-5.

## Appendices

### Appendix A: Onah's classification for mentosternal contracture

#### Type 1. Mild Anterior Contracture:

- Can flex neck
- Can bring neck and jaw in anatomical position
- The limited extension is possible away from anatomical position
- Cannot see an object located in the roof ( $180^\circ$  in erect position or  $90^\circ$  to the floor in sitting position).

It can be-

- a. The mature contracting band is narrow  $<2$  fingerbreadth
- b. The band is broad  $>2$  fingerbreadth
- c. Band covering most of the neck area including mento sternal.

#### Type 2. Moderate Anterior Contracture

- Can flex the neck
  - Can bring neck and jaw in anatomical position while erect
  - On extending the neck away from anatomical position, the lower lip which is not involved gets pulled.
- Can be a, b, or c.

#### Type 3. Severe Anterior Contracture

- The neck is contracted in the flex position
  - Chin (and sometimes the lower lip) gets tethered to the front of the chest
  - Cannot reach the anatomical position of neck and jaw
- Maybe a, b, or c.

#### Type 4. Posterior

Can be a, b, or c.