

## Original Article

### Effect of plasma-rich in platelet-derived growth factors on peri-implant bone healing: An experimental study in canines

Reza Birang<sup>1</sup>, Alireza Torabi<sup>2</sup>, Mohammad Shahabooui<sup>1</sup>, Mansour Rismanchian<sup>1</sup>

<sup>1</sup>Department of Periodontics and Torabinejad Dental Research Center, School of Dentistry, Isfahan University of Medical Sciences, Isfahan,

<sup>2</sup>Periodontist, Dental School, Islamic Azad of Tehran university, Tehran, Iran

#### ABSTRACT

**Background:** Tissue engineering principles can be exploited to enhance alveolar and peri-implant bone reconstruction by applying such biological factors as platelet-derived growth factors. The objective of the present study is to investigate the effect of autologous plasma-rich in growth factors (on the healing of peri-implant bone in canine mandible).

**Materials and Methods:** In this prospective experimental animal study, two healthy canines of the Iranian mix breed were selected. Three months after removing their premolar teeth on both sides of the mandible, 12 implants of the Osteo Implant Corporationsystem, 5 mm in diameter and 10 mm in length, were selected to be implanted. Plasma rich in growth factors (PRGF) were applied on six implants while the other six were used as plain implants without the plasma. The implants were installed in osteotomy sites on both sides of the mandible to be removed after 4 weeks with the surrounding bones using a trephine bur. Mesio-distal sections and implant blocks, 50  $\mu$  in diameter containing the peri-implant bone, were prepared by basic fuchin toluidine-blue for histological and histomorphometric evaluation by optical microscope. The data were analyzed using Mann-Whitney Test ( $P < 0.05$ ).

**Results:** The bone trabeculae and the type of bone generation in PRGF and control groups had no statistically significant differences ( $P = 0.261$ ,  $P = 0.2$ ) although the parameters showed higher measured values in the PRGF group. However, compared to the control, application of PRGF had significantly increased bone-to-implant contact ( $P = 0.028$ ).

**Conclusion:** Based on the results, it may be concluded that application of PRGF on the surface of implant may enhance bone-to-implant contact.

**Key Words:** Bone-to-implant contact, histological, histomorphometric, platelet-rich plasma growth factor

Received: May 2011

Accepted: September 2011

#### Address for correspondence:

Prof. Mohammad Shahabooui,  
Department of Periodontics,  
Isfahan Dental School and  
Torabinejad Dental Research  
Center, Isfahan University  
of Medical Science,  
Isfahan-8174673461, Iran.  
E-mail: shahabooui@dnt.  
mui.ac.ir

## INTRODUCTION

Regenerative therapies such as guided tissue regeneration (GTR) and guided bone regeneration (GBR) are universally accepted as surgical treatments not only for the repair and reconstruction of degraded

periodontal tissues but also for quantitative and qualitative enhancement of host bones in localized defects of the alveolar bone.<sup>[1]</sup> Going beyond the conventional GTR or GBR methods, researchers are nowadays investing their efforts in employing tissue engineering principles to achieve better alveolar bone reconstruction or periodontal attachment by inducing the capability for reconstruction in these tissues assisted by such effective biological regulators as enamel matrix derivatives (EMD), bone morphogenic proteins (BPs), or other similar growth factors.<sup>[2]</sup> Among the biological factors under investigation, growth factors are of special importance in modern research.

#### Access this article online

Quick Response Code:



Website: [www.drj.ir](http://www.drj.ir)

DOI: 10.4103/1735-3327.92961

One of the best sources of growth factors in the body is blood platelets. Growth factors such as platelet-derived growth factor (PDGF) and transforming growth factor- $\beta$  (TGF- $\beta$ ), contained in the  $\alpha$ -granules of platelets and released at sites of injury, have been shown to be important in the normal healing of bone, gingiva, and skin.<sup>[3]</sup> Ever since Marx *et al.* first introduced in 1998 the technique of platelet concentration to create the first autologous platelet-rich plasma (PRP) for use in dental surgery,<sup>[4]</sup> it has proved to be an effective osteopromoter in several standard bone regeneration<sup>[5,6]</sup> and osseointegration techniques.<sup>[7]</sup> In addition to a wound-healing enhancer in numerous soft tissue applications<sup>[8]</sup> PRP and PRGF have also found wider applications across more specialties of medicine and dentistry than any other source of growth factors.<sup>[9]</sup>

The growing application of dental implants to replace lost teeth coupled with the demand by patients to shorten the healing period following implant installation have also led to vast efforts by researchers to improve the quality of biomaterials and to develop dental implant surfaces with improved macroscopic and microscopic structures that allow enhanced osseointegration.<sup>[10]</sup> Moreover, some researchers have tried to enhance osteogenesis rate in the peri-implant bones by employing biological factors, especially PDGFs which are typically delivered as PRP or plasma rich in growth factor (PRGF).<sup>[11-13]</sup>

In contrast to the studies mentioned above, there are those that have challenged the efficiency and effectiveness of PDGFs used for improved osseointegration. A number of researchers have claimed that such growth factors are practically of no significant effect and have questioned their application for enhanced bone reconstruction.<sup>[14-18]</sup> The present study aims to investigate the effect of one of the most known autologous growth factors, i.e., PRGF, on peri-implant bone reconstruction in canine mandibles.

## MATERIALS AND METHODS

In this prospective experimental animal study, two male canines of the Iranian mix breed (mean 2-year old) were selected for investigation. The selection, management, preparation, and surgical protocols were accomplished as described in Wikesjo *et al.*<sup>[19]</sup> and in accordance with instructions by the Medical Ethics and Institutional Animal Care Committee of Isfahan University of Medical Sciences.

## Surgical procedure

Three months after premolars on both sides of the mandible had been removed in the canines, each was weighed. As the anesthetic, a mixture of 10% Ketamin (40 mg/kg) and 2% Xylazine (5 mg/kg) (Alfason Worden-Holland) was administered by deep muscular injection. The incubation tube including a combination of oxygen and 15% halothane was used to maintain the anesthetic effect. Immediately after the anesthetic took effect, blood samples were taken from the first canine from the tibia and transferred to the centrifuge unit. While the blood sample was under preparation, the surgeon took crestal incisions from the edentulous area on each side of the mandible and used reflection and flap to create three osteotomy sites of 5 mm across and 10-mm long. Using the submerged method, the surgeon would then place three of the OIC (Osteo Implant Corporation, USA fixtures) fixtures inside the osteotomy sites on the right mandible thus created. The flap edges would then be sutured using the interrupted method. For the opposite (left) side of the mandible, all the fixtures would be installed inside the osteotomy sites after PRGF application on the surface of implants.

The same procedure was repeated for the second canine except that this time the PRGF applied on the surface of implants were installed on the right side of the mandible. During the first 2 weeks after the surgery, the canines' mouths were washed (chlorhexidine 0.2%) and the animals were fed with soft feeds rich in supplementary vitamins.

## PRGF preparation

From the Safenous vein in the tibia, 20cc of blood sample was taken to be transferred to the PRGF system (BTI Biotechnology, San Antonio, Spain). The system used a low-speed (460G), one-stage centrifuge technique over a period of 15-20 minutes at ambient temperature. Sterile tubes containing sodium citrate 3.8% were used to prevent blood coagulation. For activation and aggregation of platelets, 50 ml of calcium chloride 10% was used for each 1cc of PRGF. After the blood sample had been centrifuged and plasma had been separated from red and white globules, the plasma in each tube was fractionated into three distinct fractions. PRGF is the designation for fraction 3 which immediately lies on a layer of white blood cells and contains a considerable amount of platelet GFs.

## Histological preparations

In the second surgery performed 4 weeks after the

installation of implants, biopsy blocks containing the implants and the peri-implant bone, were removed using the Trepine bur No. 8 (Meisinger, Neuss, Germany). Each specimen was placed in a coded package containing formalin 10% and dehydrated by alcohol. Samples transferred to acid formic 20% for decalcification, they remained in 72 hours. Then, they transferred to lithium carbonate 20% for naturalization in 5 minutes. After 10 days, each specimen was transferred into a transparent acrylic resin [Figure 1]. The ground histological sections were prepared to obtain mesio-distal sections 50- $\mu$  thick and further prepared by Donath<sup>[20]</sup> for histological and histomorphometric evaluation by optical microscope Using basic fuchin-toluidine blue staining. The sections were finally examined by an oral pathologist under the Olympus-BX51 optical microscope (Olympus Co., Tokyo, Japan). The following parameters were recorded for each section examined: 1) inflammation rate; 2) type of osteogenesis; 3) thickness of bone trabeculae; and (4) bone-to-implant contact (BIC) percentage. BIC is a histological concept traditionally evaluated by calculating the amount of the implant surface directly attached to mineralized bone without the interposition of soft connective tissue.<sup>[21]</sup> The data were ultimately subjected to statistical analysis using the Mann-Whitney Test and SPSS, Ver.11.5 ( $P < 0.05$ ).

**Research findings**

In this experiment, healing proceeded with no difficulty such that no infection or implant and bone exposure was observed in any of the implant sites.

Comparisons between the inflammation rates in the two PRGF and control groups revealed no statistically significant difference ( $P=0.57$ ) [Table 1].

Bone maturity exhibited a higher value in the PRGF group than that in the control; however, the difference was not statistically significant ( $P=0.2$ ) [Table 2 and Figures 2 and 3].

The thicknesses of the bone trabeculae were compared between the two experimental and control groups to observe no statistically significant differences ( $P=0.261$ ) [Table 3].

Comparisons were also made between the two experimental and control groups in terms of BIC percent. BIC percent had a higher value in the PRGF group [Figure 4], so statistically significant differences were observed ( $P=0.028$ ) [Figure 1].

**Table 1: Frequency of inflammation rate in the study groups**

Inflammation rate study group	0	I	II
PRFG	2 (33.3)	4 (66.6)	0
Control	3 (50)	3 (50)	0

Grade 0: No inflammation, Grade I: Few and sporadic inflamed cells, Grade II: Inflamed cells as many as 5-10 focal numbers, PRFG: Plasma rich in growth factors

**Table 2: Frequency of type of regenerated bone in the study groups**

Type of bone study group	I	II	III
PRFG	1 (16.6)	5 (83.3)	0
Control	0	4 (66.6)	2 (33.3)

Grade I: Lamellar bone, Grade II: Lamellar and woven bone, Grade III: Woven bone, PRFG: Plasma rich in growth factors

**Table 3: Frequency of bone trabeculae regenerated in the study groups**

Thickness of trabeculae study group	I	II	III
PRFG	2 (33.3)	3 (50)	1 (16.6)
Control	1 (16.6)	2 (33.3)	3 (50)


Grade I: Higher than 60  $\mu$  (thick), Grade II: 20-60  $\mu$  (medium), Grade III: Less than 20  $\mu$  (thin), PRFG: Plasma rich in growth factors

**DISCUSSION**

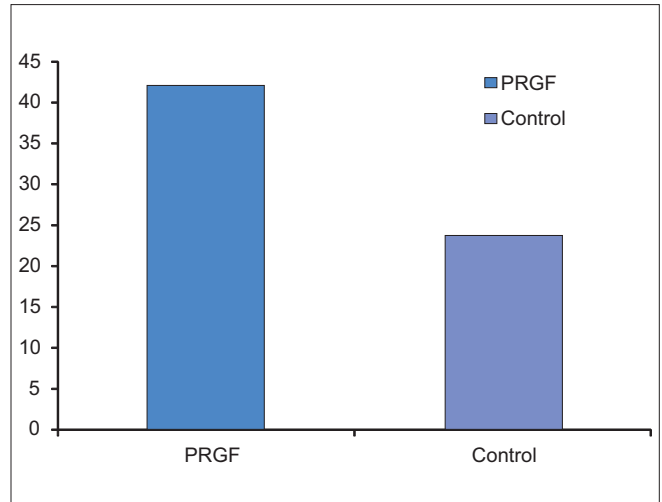
In the present study, the effect of PRGF application on the healing process of the peri-implant bones in dental implants inside osteotomy sites of canine mandible was investigated. The parameters evaluated consisted of inflammation, bone trabecular thickness, type of osteogenesis, and BIC percent. The inflammation rate in the PRGF group exceeded that of the control within the first 4 weeks of surgery but the difference was not statistically significant ( $P=0.57$ ). The severity of the inflammation created in most cases was evaluated as Grade I (mid). This finding is in agreement with the findings of most similar studies reported in the literature.<sup>[12,22-24]</sup>

Based on the results obtained from this experiment, the types of regenerated bones and thicknesses of the bone trabeculae surrounding the implants were different in the two experimental and control groups. The maturity of the neo-osteogenesis in the two groups was also investigated after 4 weeks but no significant differences were observed [Figures 2 and 3]. The quantities of Grade I (lamellar) and Grade II (lamellar+woven) bones were far higher in the PRGF group while the control exhibited more of Grade III (woven) bone. These differences, however, were not found statistically significant ( $P=0.2$ ). This finding though showed the higher maturity of bones

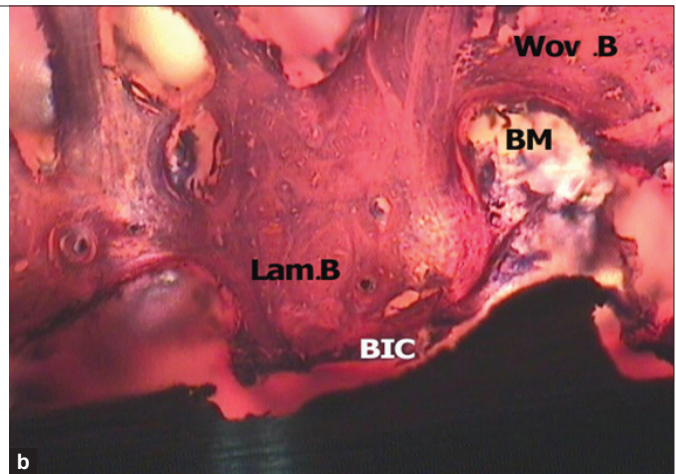
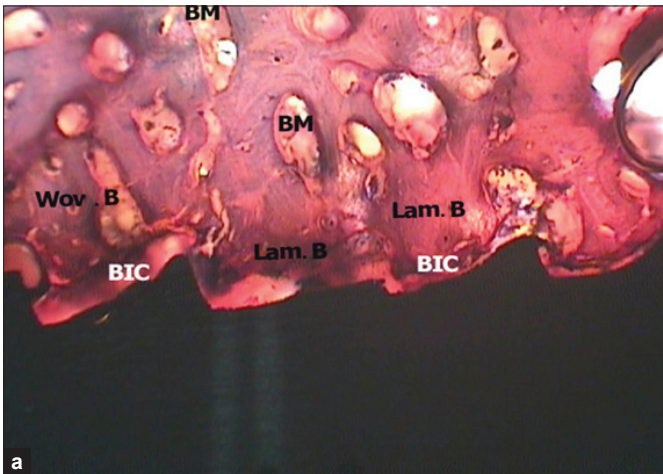




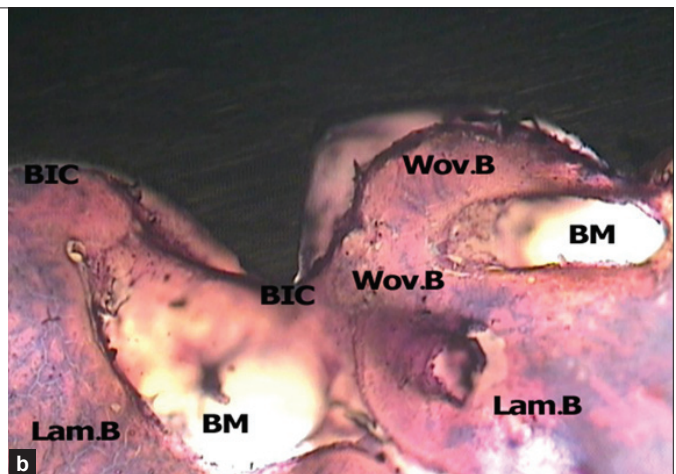
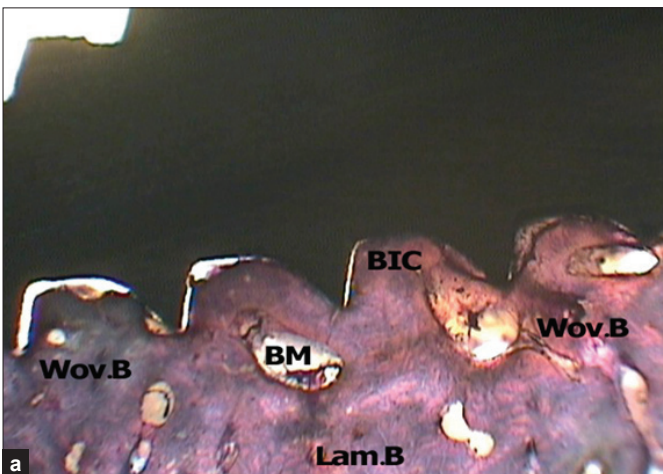
**Figure 1:** PRGF sample (right) and control sample (left) with in the cold resin (40x magnification)



**Figure 2:** Mean of BIC Percent in the study groups



**Figure 3:** It is possible to see new bone formation in the PRGF sample after 4 weeks, a (40x) and b (100x), (basic fuchsin-toluidine bleu staining); Lam. B=Lamellar bone; Wov. B: Woven bone; BM: Bone marrow; BIC: Bone-to-Implant contact



**Figure 4:** Control group after 4 weeks. a (40x) and b (100x). (Basic fuchin-toluidine blue staining); Lam. B: Lamellar bone; Wov.B: Woven bone; BM: Bone marrow; BIC: Bone-to-Implant contact

in the PRGF group compared to that in the control.

The regenerated bone trabeculae exhibited higher thicknesses in the PRGF group than those in the control although the difference was not statistically significant ( $P=0.261$ ). It seems, however, that application of PRGF had been capable of greatly enhancing the maturity of thick bone trabeculae (Grades I and II) at the implant surface. These findings agree well with those reported by Wojtowicz *et al.*<sup>[25]</sup> and Fuerst *et al.*<sup>[6]</sup> But contrary to our results, Butterfield *et al.*<sup>[26]</sup> Schlegel *et al.*<sup>[27]</sup> and Russy *et al.*<sup>[22]</sup> have reported different results.

As revealed in Figures 4, application of PRGF on the implant surface not only enhances the healing process of the peri-implant bone compared to the control, but also enhances BIC percent in the PRGF group ( $42.2\pm 3.8$ ) which is a statistically significant difference ( $P=0.028$ ) from that of the control ( $24\pm 2.7$ ). This finding agrees well with those reported in most previous studies including Fontana *et al.*<sup>[12]</sup> Kim *et al.*<sup>[13]</sup> and Furest *et al.*<sup>[6]</sup> The latter researchers installed implants on the two sides of a Minipig's mandible. In their study, PDGFs had been applied to one of the implants while the other was installed without the growth factors. They measured BIC after a period of 4 to 8 weeks and reported a BIC value of 55.3% for the implant rinsed in the growth factor and a BIC value of 38.91% for the control. They reported that implant anchorage could be strengthened in the mandible bone by applying PDGFs. Their finding is in agreement with the finding of the present study. However, other studies using PDGFs for bone grafts or bone substitutes did not report any considerable achievements in terms of osteogenesis in bone defects or on implant surfaces.<sup>[14-18]</sup> Arpornmaeklong *et al.*<sup>[28]</sup> compared the effects of *in vitro* PRP and BMP-2. They reported that high concentrations of PRP controlled the activity of alkaline phosphatase, thus having no induction effects on the osteogenesis process. They claimed this as the ineffectiveness of PRP in bone reconstruction. They further claimed that the useful clinical effects observed in applications of PRP may have been due to one of the following two causes:

1. Formation of an autologous fibrin gel which may have given rise to the stabilization of the graft material and the blood coagulate due to its adhesive strength.
2. PRP is a strong mitogen for soft tissue cells

which improves reconstruction treatments due to the associated faster repair process and reduced likelihood of wound dehiscence.

Schmitz and Hollinger<sup>[29]</sup> have also raised doubts as to the effectiveness of PRP and maintain that the PDGF present in PRP inhibits regeneration by osteoblasts when steadily in contact with these cells, leading to bone loss. They also claimed the formation of a fibrin gel leading to the stabilization of the graft material as the likely cause for the useful effect of PRP.

Despite the agreement found between the results obtained in the present study and those of many previous ones pointing to PRP-PRGF effectiveness in bone healing, the following may be claimed as possible reasons for the controversial results reported elsewhere:

1. Improper application of anticoagulants, differences in the results obtained from one-stage and two-stage centrifuge units, and failure to accurately observe centrifugal time and rates. Additionally, as platelets present in PRP-PRGF secrete their growth factors only after clotting, it is, therefore, essential to apply PRP-PRGF during their clotting process; otherwise, they will not contribute to the wound or graft healing process.<sup>[30]</sup>
2. Based on the studies carried out so far, reduplication and differentiation of mesenchymal stem cells or bone marrow cells seem to be directly proportional to the concentration of platelets. There is a very narrow range of platelet concentration in PRP-PRGF (around one million in 1  $\mu$ l) that leads to positive results so that any values below or above this may lead to inhibitory effects.<sup>[15,24]</sup>
3. Most evidence on PRP-PRGF clinical potentials are only reported in case series or case reports whose results are not definitive. It is, therefore, necessary to conduct well-controlled randomized clinical studies to obtain reliable results.<sup>[31]</sup>

## CONCLUSIONS

It may be concluded from the results obtained in this study that application of PRGF on the implant surface may enhance bone healing process as well as bone-implant contact.

## ACKNOWLEDGMENT

The authors would like to express their sincere gratitude to Torabinejad Dental Research Center for their support.



Dr. Mousavi, Dr. Adibi, Mr. Alijanpour, Miss Ghobadi and Miss Heidari from the School of Dentistry, Isfahan University of Medical Sciences, also deserve our special thanks.

## REFERENCES

1. Hammerle CH, Karring T. Guided bone regeneration at oral implant sites. *Periodontol* 2000 1998;17:151-75.
2. Marx RE. Application of tissue engineering principles to clinical practice. In: Lynch SE, Marx RE, Nevins M, Leslie A, editor. *Wise r – Lynch. Tissue engineering applications in maxillofacial surgery and peridontics*. 2<sup>nd</sup> ed. Quintessence publishing: Hanover park; 2008. p. 47-63.
3. Lynch SE. Bone regeneration techniques in the orofacial region. In: Lieberman JR, Friedlaender GE, editors. *Bone regeneration and repair biology and clinical applications*. Totowa: Humana; 2005. p. 359-90.
4. Marx RE, Carlson ER, Eichstaedt RM, Schimmele SR, Strauss JE, Georgeff KR. Platelet-rich plasma growth factor-enhancement for bone grafts. *Oral Surg Oral Med Oral Pathol Oral Radiol Endod* 1998;85:638-46.
5. Oyama T, Nishimoto S, Tsugawa T, Shimizu F. Efficacy of platelet rich plasma in alveolar bone grafting. *J Oral Maxillofac Surg* 2004;62:555-8.
6. Fuerst G, Gruber R, Tangl S, Sanroman F, Watzed G. Enhanced bone-to-implant contact by platelet-released growth factors in mandibular cortical bone: A histomorphometric study in minipigs. *Int J Oral Maxillofac Implants* 2003;18:685-90.
7. Sanchez AR, Eckert SE, Sheridan PJ, Weaver AL. Influence of platelet-rich plasma added to xenogenic bone grafts on bone mineral density associated with dental implants. *Int J Oral Maxillofac Implants* 2005;20:526-32.
8. Anitua E, Andea I, Ardanza B, Nunden P, Nurden AT. Autologous platelets as a source of proteins for healing and tissue regeneration. *Thromb Haemost* 2004;91:4-15.
9. Marx RE. PRP and BMP: A comparison of their use and efficacy in sinus grafting. In: Jensen OT, editor. *The sinus Bone Graft*, 2<sup>nd</sup> ed. Chicago: Quintessence; 2006. p. 289-304.
10. Misch CE. Rationale for Dental implants. In: Misch CE, editor. *Contemporary Implants Dentistry*. 3<sup>rd</sup> ed. St. Louis: Mosby Elsevier; 2008. p. 3-25.
11. Mazor Z, Peleg M, Garg AK, Luboshitz J. Platelet-rich plasma for bone graft enhancement in sinus floor augmentation with simultaneous implant placement: Patient series study. *Implant Dent* 2004;13:65-72.
12. Fontana S, Olmedo DO, Linares JA, Guglielmotti MB, Crosa ME. Effect of platelet-rich plasma on the peri-implant bone response: An experimental study. *Implant Dent* 2004; 13:73-8.
13. Kim SG, Kim WK, Park JC, Kim HJ. A comparative study of osseointegration of Avana implants in a demineralized freeze-dried bone alone or with platelet rich plasma. *J Oral Maxillofac Surg* 2002;60:1018-25.
14. Aghaloo TL, Moy PK, Freymiller EG. Evaluation of platelet-rich plasma in combination with freeze-dried bone in the rabbit cranium. A pilot study. *Clin Oral Implants Res* 2005; 16:250-7.
15. Weibrich G, Hansen T, Kleis W, Buch R, Hitzler WE. Effect of platelet concentration In platelet-rich plasma on peri-implant bone regeneration. *Bone* 2004;34:665-71.
16. Choi BH, Im CJ, Huh JY, Suh JJ, Lee SH. Effect of platelet-rich plasma on bone regeneration in autogenous bone graft. *Int J Oral Maxillofac Surg* 2004;33:56-9.
17. Jensen TB, Rahbek O, Overgaard S, Soballe K. No effect of platelet-rich plasma with frozen or processed bone allograft around noncemented implants. *Int Orthop* 2005;29:67-72.
18. Giovanini AF, Gonzaga CC, Zielak JC, Deliberador TM, Kuczera J, Göringer I, *et al.* Platelet-rich plasma (PRP) impairs the craniofacial bone repair associated with its elevated TGF- $\beta$  levels and modulates the co-expression between collagen III and  $\alpha$  smooth muscle action. *J Orthop Res* 2011; 29:457-63.
19. Wikesjo UM, Kean CJ, Zimmerman GJ. Periodontal repair in dogs: Supra alveolar defect models for evaluation of safety and efficacy of periodontal reconstructive therapy. *J Periodontol* 1994;65:1151-7.
20. Krüger W, Donath K, Mayer H. Bone replacement materials with growth factor additive: A new approach to the regeneration of periodontal bone defects? Induced bone regeneration in animal experiments. *Dtsch Zahnarztl Z* 1988;43:709-12.
21. Trisi P, Lazzara R, Rao W, Reboudi A. Bone implant contact and Bone quality: Evaluation of expected and actual bone contact on machined and osseotite implant surface. *Int J Periodontics Restorative Dent* 2002;22:535-45.
22. Russy Y, Bertrand Duchesne MP, Gagnon G. Activation of human platelet-rich plasmas: Effect on growth factors release, cell division and *in vivo* bone formation. *Clin Oral Implant Res* 2007;18:639-48.
23. van den Dolder J, Mooren R, Vloon AP, Stoelinga PJ, Jansen JA. Platelet-rich plasma: Quantification of growth factor levels and the effect on growth and differentiation of rat bone marrow cells. *Tissue Eng* 2006;12:3007-73.
24. Han J, Meng HX, Tang MJ, Li SL, Tang Y, Chen ZB. The effect of different platelet rich plasma concentrations on proliferation and differentiation of human periodontal ligament cell *in vitro*. *Cell Prolif* 2007;40:241-52.
25. Wojtowicz A, Chaberek S, urbanowska E, Ostrowski k. Comparison of efficiency of platelet rich plasma, hematopoietic stem cells and bone marrow in augmentation of mandibular bone defects. *NY State Dent J* 2007;73:41-5.
26. Butterfield KJ, Bennett J, Gronowicz G, Adams D. Effect of platelet-rich plasma with autogenous bone graft for maxillary sinus augmentation in a rabbit model. *J Oral Maxillofac Surg* 2005;63:370-6.
27. Schlegel KA, Kloss FR, Kessler P, Schultze-Mosgau S, Nkenke E, Wiltfang J. Bone conditioning to enhance implant osseointegration: An experimental study in pigs. *Int J Oral Maxillofac Implants* 2003;18:505-11.
28. Arpornmaeklong P, Kochel M, Depprich R, Kubler NR, Wurzlner KK. Influence of platelet-rich plasma (PRP) on osteogenic differentiation of rat bone marrow stromal cells. An *in vitro* study. *Int J Oral Maxillofac Surg* 2004;33:60-70.
29. Schmitz JP, Hollinger JO. The biology of platelet-rich plasma. *J Oral Maxillofac Surg* 2001;59:1119-21.

30. Marx RE. Use of PRP in oral and maxillofacial surgery and periodontology. In: Lynch SE, Marx RE, Nevins M, Leslie A, Wisner Lynch. Tissue engineering applications in maxillofacial surgery and periodontics. 2<sup>nd</sup> ed. Hanover Park: Quintessence publishing; 2008. p. 132-44.
31. Sanchez AR, Sheridan PJ, Kupp LI. Is platelet-rich plasma the perfect enhancement factor? A current Review. *Int J Oral Maxillofac Implants* 2003;18:93-103.

**How to cite this article:** Birang R, Torabi A, Shahabooei M, Rismanchian M. Effect of plasma-rich in platelet-derived growth factors on peri-implant bone healing: An experimental study in canines. *Dent Res J* 2012;9:93-9.

**Source of Support:** This study was financially supported and approved by Isfahan University of Medical Sciences, Isfahan, Iran. This report is based on a thesis which was submitted to the School of Dentistry, Isfahan University of Medical Sciences, in partial fulfillment of the requirements for the MSc degree in Periodontics (#386388), **Conflict of Interest:** None declared.