

Methotrexate encephalopathy: Two cases in adult cancer patients, who recovered with pathophysiologically based therapy

SAGE Open Medical Case Reports
Volume 5: 1–4
© The Author(s) 2017
Reprints and permissions:
sagepub.co.uk/journalsPermissions.nav
DOI: 10.1177/2050313X17706875
journals.sagepub.com/home/sco



Shodeinde A Coker^{1,2}, David A Pastel³, Melissa C Davis^{1,2},
Elizabeth M Bengtson^{1,2}, Camilo E Fadul⁴ and Lionel D Lewis^{1,2,5}

Abstract

Background/Objectives: Neurotoxicity is a serious and sometimes fatal adverse effect that can occur following methotrexate treatment. We describe two adult patients with hematological malignancies with methotrexate encephalopathy who recovered with dextromethorphan therapy.

Results: *Case 1:* A 24-year-old male with acute lymphoblastic leukemia developed the acute onset of bilateral facial weakness and slurred speech after his first treatment with high-dose intravenous methotrexate. The clinical scenario and a head magnetic resonance imaging supported a diagnosis of methotrexate encephalopathy. Treatment with dextromethorphan was coincident with recovery. *Case 2:* A 65-year-old female with recurrent diffuse large B-cell lymphoma was treated with high-dose intravenous methotrexate. Two weeks after a cycle, she developed hypoactive delirium, marked lethargy, ocular ataxia, and a right-sided facial weakness. Within 2 days of starting dextromethorphan, there was improvement with clinical recovery.

Conclusions: These two cases suggest that *N*-methyl *D*-aspartate receptor activation by homocysteine may play an important role in the pathogenesis of methotrexate neurotoxicity.

Keywords

Methotrexate, encephalopathy, *N*-methyl *D*-aspartate receptor antagonism, dextromethorphan

Date received: 9 January 2017; accepted: 3 April 2017

Introduction

Methotrexate (MTX) is a folate antimetabolite used to treat malignancies and certain auto-immune diseases. In the pediatric oncology population, neurotoxicity may occur after high doses of intravenous and standard doses of intrathecal MTX with a spectrum of manifestations ranging from asymptomatic head magnetic resonance imaging (MRI) abnormalities to an acute encephalopathy.^{1–5} Although discontinuing MTX and supportive measures including the addition of corticosteroids and folinic acid frequently result in resolution of symptoms, progression to death has been reported.^{1,6,7} Dextromethorphan (DXM), a mu (μ) agonist and weak antagonist of the *N*-methyl *D*-aspartate (NMDA) receptor, may alleviate symptoms of MTX neurotoxicity.^{4,5,8} Two adult cancer patients, who verbally consented to publication of their de-identified medical information, developed MTX-related encephalopathy that only improved following initiation of treatment with DXM.

Case reports

Case 1

A previously healthy, 91 kg, 24-year-old Caucasian male received induction therapy with intrathecal cytarabine,

¹Section of Hematology and Oncology, The Norris Cotton Cancer Center, Lebanon, NH, USA

²Department of Medicine, Dartmouth-Hitchcock Medical Center, Lebanon, NH, USA

³Department of Radiology, Dartmouth-Hitchcock Medical Center, Lebanon, NH, USA

⁴Division of Neuro-Oncology, Department of Neurology, University of Virginia, Charlottesville, VA, USA

⁵Section of Clinical Pharmacology, Department of Medicine, Dartmouth-Hitchcock Medical Center, Lebanon, NH, USA

Corresponding author:

Shodeinde A Coker, Department of Medicine, Dartmouth-Hitchcock Medical Center, One Medical Center Drive, Lebanon, NH 03756, USA.
Email: Shodeinde.A.Coker@Dartmouth.edu



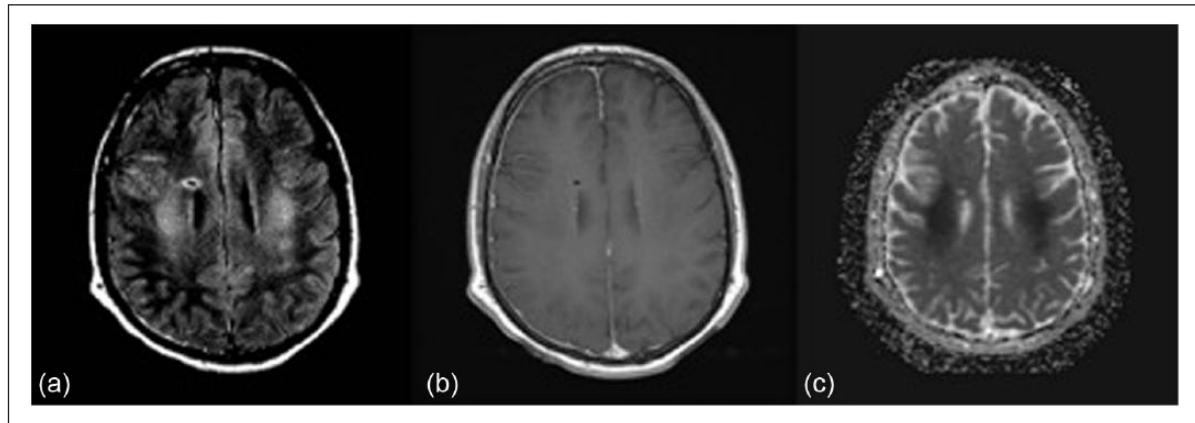


Figure 1. Composite fluid-attenuated inverse recovery (FLAIR), T1-weighted post-contrast, and apparent diffusion coefficient (ADC) map images from MRI of Case 1 at initial presentation: (a) FLAIR sequence demonstrates symmetric periventricular T2 signal hyperintensity, (b) T1 post-contrast shows absence of enhancement, and (c) ADC map indicates presence of restricted diffusion (dark signal) within the periventricular white matter corresponding to the distribution of signal alteration on the FLAIR sequence.

intravenous vincristine, daunorubicin, pegasparaginase, and oral prednisone after diagnosis of acute lymphoblastic leukemia in September 2012. In January 2013, he started maintenance intravenous high-dose MTX, dosed at 5 g/m² for a total of 10 g. Prior to the start of MTX, urine alkalinization to a pH of 8.5 was achieved and maintained with oral sodium bicarbonate. Intravenous folinic acid 50 mg was given 30 h after the start of MTX and continued at 25 mg every 6 h until plasma MTX concentration at 72 h post MTX dosing was less than 0.1 μmol/L. Eight days after receiving the first high dose of MTX, the patient developed the acute onset of bilateral facial drooping, slurred speech, and lethargy. Over the next 24 h, he developed left upper extremity weakness. On examination, the patient was mute and unable to open his mouth to command. He had bilateral ptosis, but could open his eyes. He required elective intubation for airway protection because of progressive oropharyngeal muscle weakness. At this time, his MTX plasma concentration was <0.01 μmol/L and a complete blood count, comprehensive metabolic laboratory panel, and coagulation profile were normal. Neither folate nor homocysteine concentrations in cerebrospinal fluid (CSF) were measured. A contrast-enhanced head MRI showed symmetric, confluent areas of T2 hyperintensity in the bilateral deep white matter on the fluid-attenuated inverse recovery (FLAIR) sequence. These areas did not enhance and demonstrated restricted diffusion on the apparent diffusion coefficient (ADC) map not corresponding to a discrete arterial distribution (Figure 1). A repeat MRI of the head performed 24 h later showed interval worsening of the restricted diffusion within the supratentorial white matter.

He had no improvement in symptoms or neurological examination with supportive treatment over the next 48 h. On the third day of hospitalization, oral DXM 90 mg (via nasogastric (NG) tube) daily was started. After 2 days of DXM treatment, there was significant improvement in left upper extremity strength. He was extubated on hospital day

5 with normal mental status and subsequently discharged from the hospital on day 6 with a normal neurological examination and discontinuation of DXM. Repeat MRI showed interval resolution of the previously noted abnormalities. Subsequent chemotherapy regimen omitted MTX. He is disease free without recurrence of his neurological symptoms 3 years after this clinical episode.

Case 2

A 65-year-old Caucasian female presented with a recurrent diffuse large B-cell primary central nervous system lymphoma (PCNSL) in February 2014 after being in clinical remission for 9 years. Her head MRI revealed a new enhancing left basal ganglia mass. Weighing 93 kg, she started treatment with rituximab, MTX (3.5 g/m², for a total dose of 6.8 g), procarbazine, and intrathecal MTX (12 mg) in 14-day cycles. She completed two cycles uneventfully with standard urine alkalinization prior to each dose of MTX as well as intravenous folinic acid 50 mg, given 24 h after the start of MTX and maintained at 25 mg every 6 h until plasma MTX concentration was less than 0.1 μmol/L. The plasma MTX concentration was below 0.1 μmol/L at 72 h with each cycle. In March 2014, she received her third cycle of MTX but clearance was delayed, evidenced by a plasma MTX concentration of 0.23 μmol/L, 72 h post-dosing and elevated liver enzymes. Plasma concentrations were below 0.1 μmol/L on Day 6 post MTX administration. Two weeks after this third dose of high-dose MTX, she presented to the hospital with hypoactive delirium. She was disoriented to time, person, or place, and her physical examination was notable for marked lethargy, ocular ataxia, and a right-sided facial weakness. Laboratory studies at this time showed a white blood cell count of 12,700/μL with a neutrophil predominance and mild thrombocytopenia (95,000/μL), with normal metabolic and coagulation profiles. Neither CSF folate nor homocysteine

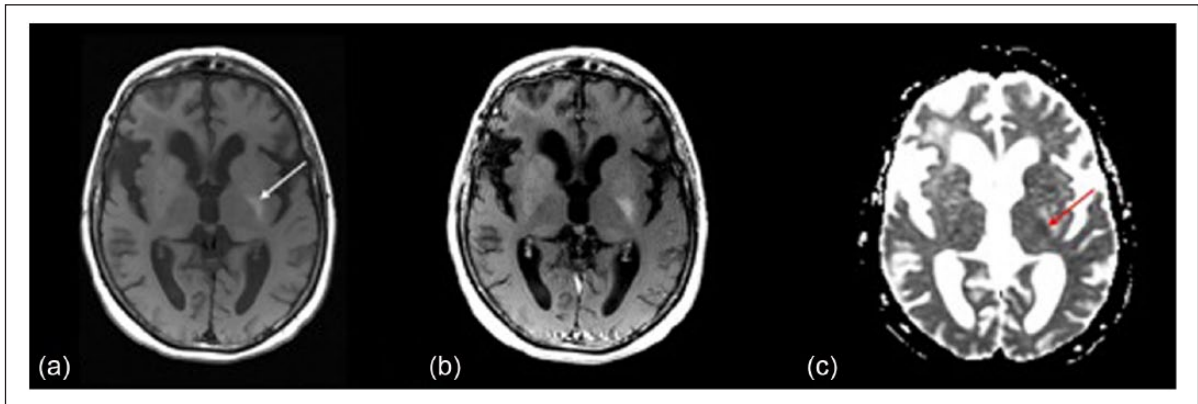


Figure 2. Composite T1-weighted pre-contrast, T1-weighted post-contrast, and apparent diffusion coefficient (ADC) images from MRI of Case 2 at onset of delirium (post MTX therapy): (a) T1-weighted pre-contrast image shows a small area of T1 hyperintense signal with the left basal ganglia (arrow), (b) No significant enhancement on the T1-weighted post-contrast sequence, and (c) ADC map shows restricted diffusion (arrow) at site of T1 hyperintensity in the left basal ganglia.

concentrations were measured. Her electroencephalogram (EEG) was abnormal with generalized slowing. A repeat head MRI revealed near-complete interval resolution of the enhancing left basal ganglia mass, but interval development of a small area of restricted diffusion at the site of previous enhancement in the left basal ganglia (Figure 2).

The patient's delirium continued for 11 days post admission. DXM 60mg, orally twice daily, was started on day 12 of hospitalization. Within 2 days of starting DXM, marked improvement in her mental status occurred with the patient becoming oriented to self, year, and place. She began answering questions in full sentences and showed the first signs of insight into her neurological condition. She continued to improve, being discharged from the hospital after 3 days of DXM treatment. She did not receive further doses of intravenous or intrathecal MTX. She remains without recurrence of neurological symptoms or lymphoma more than 3 years after hospital admission.

Conclusion

The appearance of neurological symptoms 2–14 days post high-dose MTX administration in both cases is consistent with the known time course for subacute MTX neurotoxicity.^{5,9} Both cases receive a score of 7 on the Naranjo Probability Scale for adverse drug effects, which categorizes the diagnosis of MTX encephalopathy as probable.¹⁰ MTX-associated encephalopathy is usually incapacitating, may follow an unpredictable course, and is potentially fatal.^{1,6,9}

The pathogenesis of subacute encephalopathy is postulated to relate to multiple perturbed neuronal biochemical processes in addition to a potential direct neurotoxic effect of MTX.¹¹ In these cases, the improvement after the administration of DXM, an NMDA receptor antagonist, suggests a common pathophysiology.

One proposed mechanism of MTX neurotoxicity is the reduction of the neuronal concentration of 5-methyltetrahydrofolate (5-methyl-THF)—necessary to methylate homocysteine

to methionine resulting in increased concentrations of homocysteine.¹² Homocysteine has excitatory effects on the NMDA receptor, and also causes local and regional neuronal death by the activation of NADPH oxidase 2 (NOX2) that increases concentrations of superoxide and resultant oxidative stress.^{13,14} High plasma homocysteine and low pretreatment plasma folate concentrations have been suggested to be biomarkers of MTX neurotoxicity;¹¹ however, the development of encephalopathy in spite of folinic acid supplementation in both our cases suggests these plasma biomarkers may not be relevant here.

DXM, a lipophilic amine and a NMDA receptor antagonist, crosses the blood–brain barrier.¹⁵ Theoretically, it may attenuate the neurotoxic effects of homocysteine and other excitotoxic glutamate analogs in the brain.^{5,8,16} There are several reports of the use and benefit of DXM treatment in the symptomatic management of MTX neurotoxicity.^{4,5,8} Based on these reports and the lack of improvement in spite of other medical interventions including aggressive folinic acid administration, we treated our patients with non-weight-based dosing of DXM. Both patients had complete resolution of symptoms within 48–72 h after starting DXM. While the timeframe and course of this recovery is similar to the previously described time course to resolution of MTX neurotoxicity symptoms with DXM, a gradual and spontaneous resolution of neurotoxicity symptoms with only supportive care has also been reported. There is no Food and Drug Administration (FDA)-approved indication or dose for DXM in the treatment of MTX neurotoxicity, and there are no prospective clinical studies at this time to support a recommendation for its routine use for this indication. A randomized, double-blind study of DXM in the prevention and treatment of MTX neurotoxicity was recently terminated prior to completion on account of slow accrual.¹⁷ DXM has the potential for abuse and addiction;¹⁸ however, the short duration of treatment using DXM for MTX neurotoxicity may not increase this risk. Other drugs with NMDA receptor

antagonist properties including memantine and gabapentin may theoretically be used for the treatment of MTX neurotoxicity. In vitro and animal studies suggest that memantine is able to protect neurons from glutamate analog neurotoxicity; however, our review of the literature suggests that DXM has the most clinical experience.^{19,20} Some authors report successful rechallenge of pediatric patients with MTX neurotoxicity without recurrence of symptoms.⁴ We did not rechallenge either of our patients with further MTX treatment and neither patient has had a recurrence of their neurological symptoms.

Acknowledgements

The authors would like to thank both patients for their willingness to allow use of their medical information in this manuscript.

Declaration of conflicting interests

The author(s) declared no potential conflicts of interest with respect to the research, authorship, and/or publication of this article.

Ethical approval

Our institution does not require ethical approval for reporting individual cases or case series.

Funding

The author(s) received no financial support for the research, authorship, and/or publication of this article.

Informed consent

Written informed consent was obtained from the patient(s) for their anonymized information to be published in this article.

References

- Asada Y, Kohga S, Sumiyoshi A, et al. Disseminated necrotizing encephalopathy induced by methotrexate therapy alone. *Acta Pathol Jpn* 1988; 38(10): 1305–1312.
- Ebner F, Ranner G, Slavc I, et al. MR findings in methotrexate-induced CNS abnormalities. *AJNR Am J Neuroradiol* 1989; 10(5): 959–964.
- Yap SM, MacEneaney P, Ryan C, et al. Alternating hemiparesis and orolingual apraxia as manifestations of methotrexate neurotoxicity in a paediatric case of acute lymphoblastic leukaemia. *BMJ Case Rep* 2016; 2016. DOI: 10.1136/bcr-2016-214677.
- Afshar M, Birnbaum D and Golden C. Review of dextromethorphan administration in 18 patients with subacute methotrexate central nervous system toxicity. *Pediatr Neurol* 2014; 50(6): 625–629.
- Drachtman RA, Cole PD, Golden CB, et al. Dextromethorphan is effective in the treatment of subacute methotrexate neurotoxicity. *Pediatr Hematol Oncol* 2002; 19(5): 319–327.
- Brock S and Jennings HR. Fatal acute encephalomyelitis after a single dose of intrathecal methotrexate. *Pharmacotherapy* 2004; 24(5): 673–676.
- Kay HE, Knapton PJ, O’Sullivan JP, et al. Encephalopathy in acute leukaemia associated with methotrexate therapy. *Arch Dis Child* 1972; 47(253): 344–354.
- Bettachi CJ, Kamen BA and Cush JJ. Post-methotrexate (MTX) CNS toxicity: symptom reduction with dextromethorphan. *Arthritis Rheum* 1999; 42: S164.
- Salkade PR and Lim TA. Methotrexate-induced acute toxic leukoencephalopathy. *J Cancer Res Ther* 2012; 8(2): 292–296.
- Naranjo CA, Busto U, Sellers EM, et al. A method for estimating the probability of adverse drug reactions. *Clin Pharmacol Ther* 1981; 30(2): 239–245.
- Vezmar S, Becker A, Bode U, et al. Biochemical and clinical aspects of methotrexate neurotoxicity. *Chemotherapy* 2003; 49(1–2): 92–104.
- Becker A, Vezmar S, Linnebank M, et al. Marked elevation in homocysteine and homocysteine sulfinic acid in the cerebrospinal fluid of lymphoma patients receiving intensive treatment with methotrexate. *Int J Clin Pharmacol Ther* 2007; 45(9): 504–515.
- Lipton SA, Kim WK, Choi YB, et al. Neurotoxicity associated with dual actions of homocysteine at the N-methyl-D-aspartate receptor. *Proc Natl Acad Sci U S A* 1997; 94(11): 5923–5928.
- Boldyrev AA. Homocysteine acid causes oxidative stress in lymphocytes by potentiating toxic effect of NMDA. *Bull Exp Biol Med* 2005; 140(1): 33–37.
- Choi DW, Peters S and Viseskul V. Dextromethorphan and levorphanol selectively block N-methyl-D-aspartate receptor-mediated neurotoxicity on cortical neurons. *J Pharmacol Exp Ther* 1987; 242(2): 713–720.
- Vijayanathan V, Gulinello M, Ali N, et al. Persistent cognitive deficits, induced by intrathecal methotrexate, are associated with elevated CSF concentrations of excitotoxic glutamate analogs and can be reversed by an NMDA antagonist. *Behaviour Brain Res* 2011; 225(2): 491–497.
- A pilot study of dextromethorphan for the prevention and treatment of methotrexate neurotoxicity—full text view—ClinicalTrials.gov 2017, <https://clinicaltrials.gov/ct2/show/NCT00176553?term=dextromethorphan+methotrexate&rank=1>
- Spangler DC, Loyd CM and Skor EE. Dextromethorphan: a case study on addressing abuse of a safe and effective drug. *Subst Abuse Treat Prevent Policy* 2016; 11(1): 22.
- Cole PD, Vijayanathan V, Ali NF, et al. Memantine protects rats treated with intrathecal methotrexate from developing spatial memory deficits. *Clin Cancer Res* 2013; 19(16): 4446–4454.
- Kornhuber J, Weller M, Schoppmeyer K, et al. Amantadine and memantine are NMDA receptor antagonists with neuroprotective properties. *J Neural Trans Supplementum* 1994; 43: 91–104.