

## Definition of the Role of Somatostatin Receptor Scintigraphy in Gastrointestinal Neuroendocrine Tumor Localization

Robert T. Jensen<sup>a</sup>, Fathia Gibril and Basel Termanini

*Digestive Diseases Branch, National Institute of Diabetes and  
Digestive and Kidney Diseases, National Institutes of Health, Bethesda, Maryland*

(Received January 30, 1997; returned for revision February 16, 1998; accepted March 10, 1998)

---

There are six major steps in the management of patients with neuroendocrine tumors (NETs) (carcinoids and pancreatic endocrine tumors). One of the steps that is increasing in its importance is the need to assess primary tumor location and tumor extent in these patients. Without such information, it is not possible to adequately manage these patients. Conventional imaging studies (CT scan, MRI, ultrasound, angiography), functional localization studies measuring hormonal gradients, endoscopic ultrasound, and most recently, somatostatin receptor scintigraphy (SRS) with [<sup>125</sup>I-DTPA-DPhe<sup>1</sup>]-octreotide have all been advocated to localize NETs in different studies. Whereas it is now established that for all NETs, except insulinomas, SRS has the greatest sensitivity, it remains unclear whether this increased sensitivity translates into increased clinical usefulness. It, therefore, remains unclear based on fiscal and clinical considerations what should be the recommended algorithm for the use of the different localization methods. To address this issue, we have recently performed two prospective studies on patients with gastrinomas. In this paper, the methods and results of each are summarized and based on these results, an algorithm for localization studies in NETs is proposed. One study assessed the role of SRS in management in 122 patients and shows that the use of SRS changed management in 47 percent of patients according to six different criteria when the patients were stratified according to their principal management problem. Determining whether liver metastases were present is one of the major goals of tumor localization studies and is frequently a source of confusion because of the difficulty in distinguishing small NETs liver metastases from hemangiomas. In the second study, the ability of SRS and other tumor localization methods to distinguish these two possibilities was assessed in 15 patients with small hemangiomas and 15 patients with small hepatic metastases (mean size 1.3 cm). SRS correctly identified 93 percent of the patients with liver metastases and was not positive in any patient with a hemangioma, suggesting it was not a liver metastases. SRS had greater negative and positive predictive value than conventional studies. Based on these two studies, and SRS's greater sensitivity and fiscal considerations, it is proposed that SRS should be the initial tumor imaging study in all NETs except insulinomas, and algorithms for the use of other localization studies in both NETs and insulinomas are proposed.

---

### INTRODUCTION

Carcinoid tumors and pancreatic endocrine tumors (PETs)<sup>b</sup> can both be considered together as gastrointestinal neuroendocrine tumors (NETs) because of their common features. These tumors have indistinguishable histologic features; are similar in their ability

---

<sup>a</sup> To whom all correspondence should be addressed: Robert T. Jensen, NIH/NIDDK/DDT, Building 10, Room 9C-103, 10 CENTER DR MSC 1804, Bethesda, MD 20892-1804. Tel.: 301-496-4201; Fax: 301-402-0600; E-mail: robertj@bdg10.niddk.nih.gov.

<sup>b</sup> Abbreviations: PET, pancreatic endocrine tumor; NET, neuroendocrine tumor; SRS, somatostatin receptor scintigraphy; EUS, endoscopic ultrasound.

to synthesize multiple peptides; they both synthesize shared secreted proteins and cytoplasmic proteins such as chromogranin, synaptophysin and neuron-specific enolase; they have similar biologic behavior, and the management considerations are similar with each. [1-5]. The shared similar steps in management of NETs are summarized in Table 1. All require the establishment of the diagnosis and determination of whether the tumor is associated with a functional syndrome (i.e., gastrinoma, VIPoma, carcinoid syndrome, etc.). Tumor localization and tumor extent are essential for planning the proper course of management [1, 6] and will be discussed in detail below. Recently, it has become increasingly apparent that inherited syndromes can be associated with either carcinoids (von Recklinghausen's syndrome, multiple endocrine neoplasia-type I [MEN-I]) or PETs (MEN-I, von Hippel-Landau disease, tuberous sclerosis, von Recklinghausen's syndrome), and their recognition is important because it alters management [7-9]. All patients that have NETs have two treatment problems in that if the tumors are functional, treatment must be directed at the hormone excess state and because most are malignant, treatment must be directed at the tumor itself [1, 8-10] (Table 1). Lastly, all patients with NETs require long-term follow-up because in many cases, even though the rate of growth is slow, the true recurrence rate is unclear. For each of the management steps in Table 1, an algorithm and fiscal comparison using different approaches could be done. In this article, the analysis will be restricted to such considerations in NET tumor localization and extent.

### **PURPOSE OF NET LOCALIZATION STUDIES AND LOCALIZATION METHODS USED**

NET tumor localization studies are necessary for three primary reasons: first, to determine resectability by determining if surgical resection is indicated, by excluding extensive metastatic disease [6, 11-13]; second, to localize the primary tumor to increase the likelihood of surgical resection [6, 14,15]; third, to assess tumor progression by determining growth to select the appropriate therapy [2, 6].

- Numerous imaging modalities have been widely used to localize NETs including conventional imaging studies (ultrasound, computed tomographic scanning [CT scan], magnetic resonance imaging [MRI] and selective angiography) [6, 16], and functional localization by measuring hormonal gradients either by portal venous sampling, or in hepatic venous samples under basal conditions, or after secretin or calcium intra-arterial infusion [17-19]. Recently, two newer methodologies, endoscopic ultrasound (EUS) [20] and somatostatin receptor scintigraphy (SRS) [21-23] have been used. In terms of the purposes of imaging studies, the different modalities have varying utility. To determine resectability, which is necessary in 95-100 percent of all patients with NETs, either conventional imaging studies or SRS is useful. To determine primary tumor location, which is important in all patients without extensive metastatic disease (90-95 percent of insulinomas [9],

**Table 1. Steps in the management of neuroendocrine tumors (NETs).**

- 
1. Make diagnosis (functional, etc.)
  2. Determine tumor localization and extent
  3. Establish presence or absence of inherited syndrome  
(MEN-I, von Recklinghausen's disease, von Hippel-Landau disease, etc.)
  4. Treatment of hormone-excess state (medical, surgical)
  5. Treatment directed against tumor itself
  6. Long-term follow-up
-

**Table 2. Cost of various studies used in localization of neuroendocrine tumors.**

	Washington, D.C. area	University of Michigan	Average
<b>Study:</b>			
CT scan	\$1000	\$1948	\$950-1000
MRI	1300	—	1300
Angiography	—	2294	2294
Portal venous sampling	—	3257	3257
Intra-operative ultrasound	—	400	400
Endoscopic ultrasound	2500	\$1130	1815
SRS	\$1984	—	\$1984

University of Michigan data are from Reference [42].

20-50 percent of other PETs [2, 9, 10]), conventional imaging studies, EUS, SRS, or hormonal gradients are commonly used [6, 17, 20, 21, 23, 24]. To assess tumor growth or recurrence in patients with localized intra-abdominal recurrences (50 percent, Zollinger-Ellison syndrome [25], 10 percent, other PETs [9, 10, 26]) conventional imaging studies, EUS, or SRS can be used whereas to assess metastatic disease, which is required in 40 percent of patients with Zollinger-Ellison syndrome and 30-90 percent of patients with PETs other than insulinomas, either conventional imaging or SRS are generally used [6, 21, 23, 27]. EUS or functional localization is, therefore, of potential use in less than half of all patients with PETs in which identification of the primary or of a localized recurrence is an issue. In contrast, conventional imaging or SRS is of potential use in all patients where localization studies are needed for either resectability, primary tumor localization or assessment of growth/recurrence.

### CONSIDERATIONS IN CHOOSING A GENERAL LOCALIZATION STUDY

Because EUS or functional location using sampling for hormonal gradients are useful in only a subset of the indications for tumor localization studies, they will not be discussed further. Recent studies demonstrate that SRS is the most sensitive modality to localize primary or metastatic carcinoid tumors and all PETs except insulinomas [21-23, 27-30]. However, for a number of reasons, it is difficult for the physician to define the potential role of SRS in the management of a patient with a NET. First, increased sensitivity cannot necessarily be equated with increased value. The detection of additional metastases in a patient with numerous metastases may not change management, but increases sensitivity. Similarly, the detection of a primary tumor in a nonoperative patient, while increasing sensitivity, likely will not change management or have any clinical benefit. Second, localization is performed for different purposes depending on the clinical setting and, therefore, to evaluate its usefulness, the sensitivity needs to be assessed in different settings, which it rarely has been in different studies. For example, patients with or without metastatic liver disease or with or without MEN-I undergo localization studies for different reasons [23, 31, 32]. Patients with liver metastases undergo imaging to determine whether cytoreductive surgery should be considered [11, 33], tumoricidal treatment begun

[2, 34, 35], liver transplantation considered [36-38], or to determine the response of some tumoricidal treatment [2]. In contrast, in patients without hepatic metastases, imaging studies are usually performed to localize a possible primary tumor that could be resected [6, 39]. Patients with MEN-I with a functional PET that is not a gastrinoma undergo localization studies to find which of numerous tumors is the functional one [17, 32]. In contrast, in patients with MEN-I with a nonfunctional PET or gastrinoma, some groups recommend routine surgery only if the tumor is greater than 2.5 cm [32, 40, 41]. Therefore, imaging needs to be used that clearly establishes the size of the lesion. Third, the different localization methods vary considerably in cost [42] (Table 2), and, therefore, fiscal considerations are becoming increasingly a factor in which studies or combinations may be done [31, 42]. In general, SRS costs twice as much as a CT scan and, in some cases MRI, and generally costs slightly less than angiography (Table 2). The recent large NIH study [23] in patients with gastrinomas demonstrated that the SRS was equal in sensitivity to the combination of all conventional imaging studies (ultrasound, CT scan, MRI, angiography; total cost: \$5500). Therefore, if SRS is also equally effective in management in these situations, it would also be more cost-effective than this combination of conventional imaging studies. In practice, for SRS to be completely cost-effective it must just be equal or superior to a combination of two localization studies. Generally, only two localization studies are performed in most patients with NETs. In the past, these studies usually were ultrasound or CT and MRI or angiography and more recently, ultrasound, CT or MRI and EUS [22, 29, 30, 43-46].

Whereas numerous studies have established the sensitivity of SRS, few studies have attempted to assess the usefulness of SRS in clinical management in sufficient numbers of patients to allow a clear definition of its value compared to other conventional localization methods [23, 47, 48]. Recently two studies have been performed at the National Institutes

**Table 3. NIH prospective study on effect of SRS on clinical management.**

---

**A. Clinical categories of patients:**

- I. Patients undergoing an initial evaluation (preoperative initial evaluation category [n = 17]).
- II. Patients who had undergone a previous gastrinoma resection and were disease-free and were undergoing yearly evaluation for possible recurrence (cured post-surgery category [n = 18]).
- III. Patients who had undergone resection but were not disease-free (not cured post-resection [n = 48]).
- IV. Patients who had not undergone surgical exploration either because of concomitant medical conditions that either limited life expectancy or increased surgical risk (n = 7) or because of associated MEN-I (n = 5) (no surgery category [n = 12]).
- V. Patients with proven metastatic liver disease (metastatic liver disease category [n = 27]).

**B. Criteria altering clinical management:**

SRS changed management if SRS was:

- I. The only imaging test identifying liver metastases.
  - II. The only study identifying liver metastases in more than one lobe.
  - III. The only study identifying a possible primary tumor in a patient who was a surgical candidate or its detection changed management.
  - IV. The only study identifying bone metastases that changed treatment.
  - V. The only study identifying additional distant metastases that changed management.
  - VI. Useful in clarifying equivocal lesion(s) seen on conventional imaging studies that resulted in altered management.
-

of Health on patients with gastrinomas that address these issues. The remainder of this paper will briefly review these studies and present an algorithm for tumor localization studies based on extrapolation of these results and those from other studies on neuroendocrine tumors.

## **NIH PROSPECTIVE STUDY ON THE ABILITY OF SRS TO ALTER MANAGEMENT IN PATIENTS WITH GASTRINOMAS**

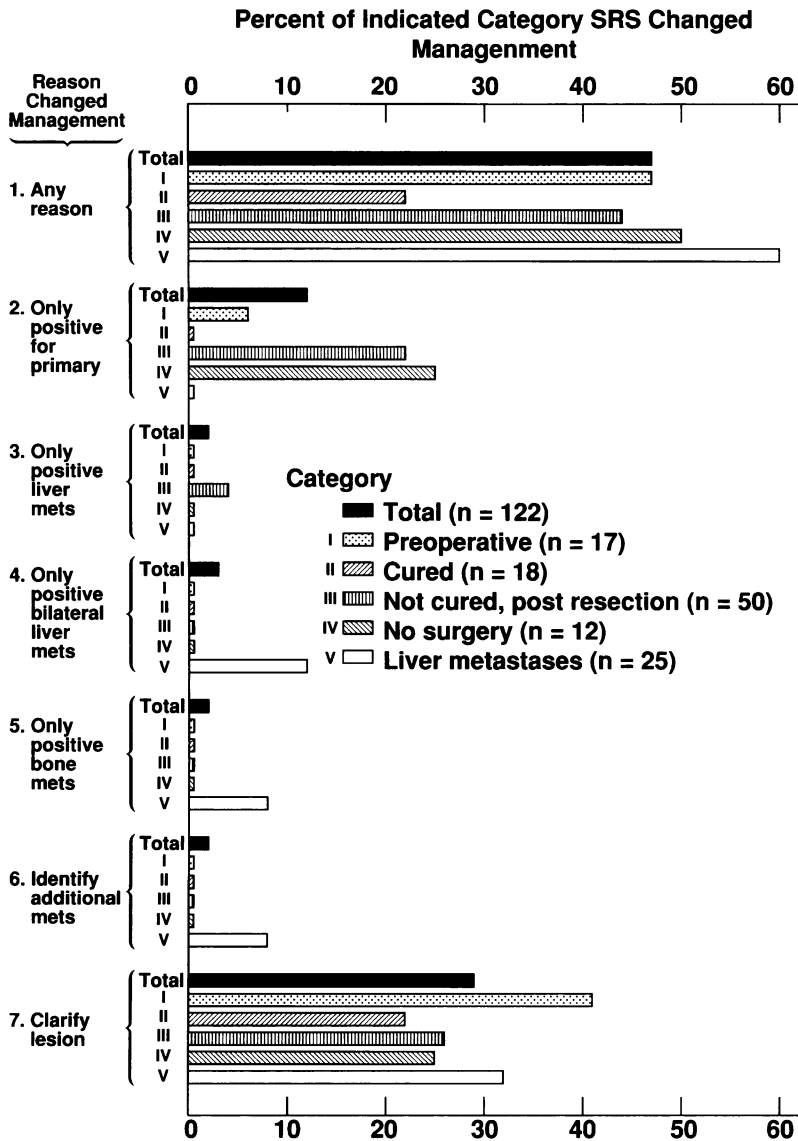
### *Methods in SRS management study*

One hundred twenty-two consecutive patients with Zollinger-Ellison syndrome were studied in this NIH prospective study [31]. Each patient was assigned to one of five different clinical categories (Table 3), because the rationale for doing localization studies varies in different clinical situations. All patients first underwent conventional imaging studies (ultrasound, CT, MRI, angiography, bone scan), and the clinical management was decided. The SRS was then performed and clinical management redetermined. Based on the six different criteria listed in Table 3, it was determined whether the SRS had changed the clinical management in each of the five different clinical categories [31].

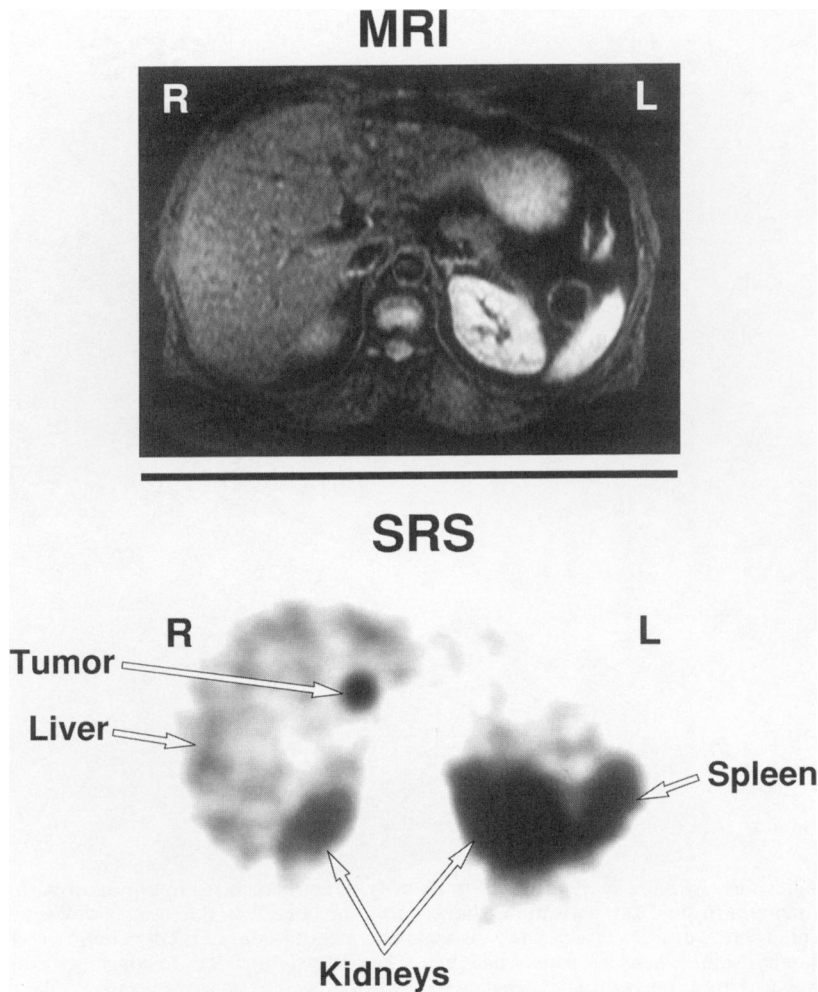
### *Results of SRS management study*

In all patients, CT demonstrated a lesion in 39 percent, MRI in 50 percent, any conventional study including angiography in 62 percent, SRS in 62 percent and only SRS in 14 percent. The sensitivity of SRS varied from 0 percent in the cured group (category II, Table 2) to 100 percent in the patients with metastatic liver disease (category V, Table 2). The results for the ability of SRS to alter management in all patients ( $n = 122$ ) and according to the five different clinical categories are shown in Figure 1 stratified by the reason that SRS changed clinical management. SRS changed management overall in 47 percent of the patients (Figure 1 – top, any reason) and approximately equally affected each of the clinical categories except the cured category (category II, Table 2).

The basis for SRS altering clinical management varied depending on the clinical category (Figure 1). In patients in clinical category I for preoperative evaluation, SRS primarily changed management by clarifying equivocal lesions (41 percent) or being the only study to identify a primary lesion (6 percent). Figure 2 shows an example of such a patient in whom the MRI and all other imaging studies were negative preoperatively; however, the SRS showed a pancreatic head lesion, and at surgery, the patient was cured after removal of a 0.5 cm gastrinoma in a pancreatic head lymph node. In clinical category II (cured patients), SRS changed management by clarifying equivocal lesions (22 percent) from conventional imaging studies that could represent metastases or recurrence. A number of these lesions were questionable liver metastases, and one aspect of this is dealt with in the second NIH study discussed below. SRS altered clinical management in 44 percent of patients in clinical category III (not cured post-surgery) with the reasons being clarification of equivocal findings of conventional imaging studies (26 percent), the only study to identify a recurrent gastrinoma leading to repeat exploration (22 percent), and identifying new liver metastases in 4 percent. In clinical category IV (patients with no previous surgery), SRS altered management in 50 percent by clarifying equivocal conventional imaging studies (25 percent) or being the only study to demonstrate a primary lesion that altered management. SRS altered management in 60 percent of the patients in the metastatic liver disease category, primarily by clarifying equivocal lesions for conventional imaging studies (32 percent), being the only modality to identify bilateral liver metastases whose identification precluded surgery; being the only modality to identify any bone metastases that led to institution of anti-tumor therapy (8 percent); and being the only



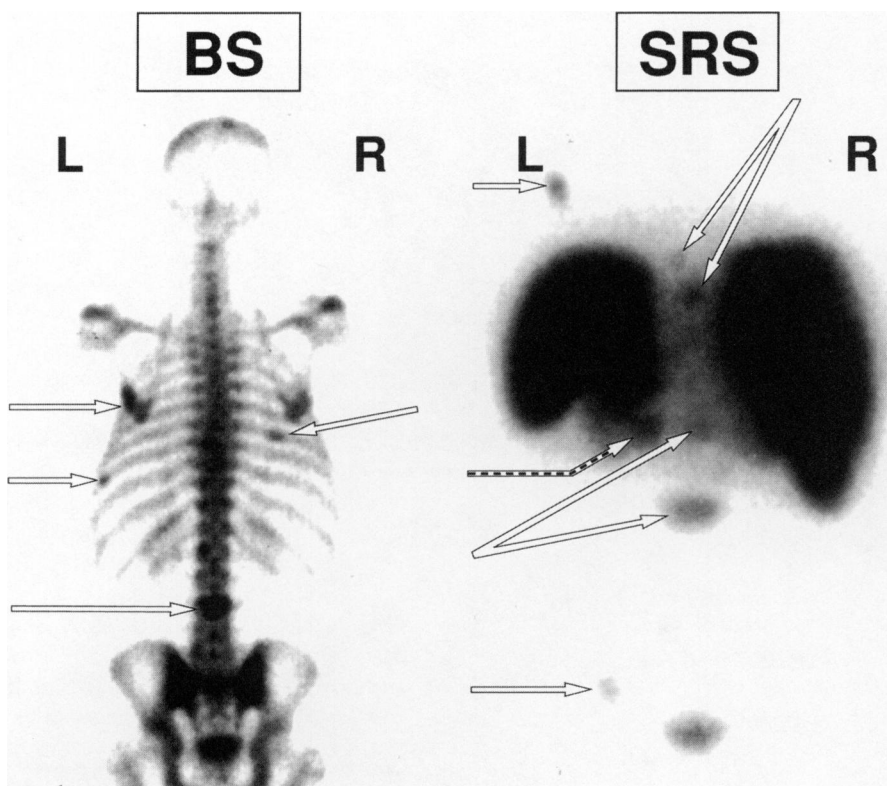
**Figure 1. Ability of SRS to change management in 122 patients with gastrinoma.** One hundred twenty-two consecutive patients with Zollinger-Ellison syndrome were divided into five different clinical categories depending on the stage of their disease. The five categories were: Category I: 17 new patients evaluated preoperatively; Category II: 18 patients previously cured by gastrinoma resection and undergoing yearly re-evaluation for recurrence; Category III: 50 patients post noncurative resection undergoing yearly re-evaluation; Category IV: 12 patients who did not undergo surgery either because of accompanying medical conditions or who had MEN-I; Category V: 25 patients with liver metastases. Each patient first underwent conventional imaging studies (CT, MRI, angiography and ultrasound) and the management was decided. SRS was then performed and based on the six different reasons (Table 3) shown it was determined whether SRS had changed management. With each of the six different reasons for possibly changing management, the proportion of patients in each clinical category in which management was changed is indicated. Data are from Reference [31].



**Figure 2. MRI and SRS in a patient with Zollinger-Ellison syndrome prior to surgery.** The MRI (top) was negative as were the other conventional imaging studies; however, SRS showed a pancreatic head tumor (lower) which was subsequently removed at surgery. This patient is an example of SRS changing management in that it was the only localization study showing the gastrinoma prior to surgery (Reason #1, Figure 1; Table 3).

modality to identify additional metastases that altered management (8 percent). An example of the latter category is shown in Figure 3 for a patient complaining of upper back pain with metastatic gastrinoma. The bone scan showed L-3, rib and left scapula metastases but no thoracic spine metastases or upper lumbar vertebral metastases that could explain the upper back pain. SRS demonstrates thoracic and L-1 vertebral metastases. The patient was treated with local radiation, and the chemotherapy was changed.

Patients in whom SRS changed management ( $n = 57$ ) did not differ from patients in whom it did not change management ( $n = 65$ ) in various demographic features (age, gender, MEN-I present, disease duration), whether it was the initial patient evaluation or not,



**Figure 3. Ability of bone scan and SRS to identify bone metastases in a patient with metastatic gastrinoma to the liver with upper back pain.** The bone scan (left panel) showed (arrows) a left scapula and two rib metastases as well as a bone metastasis in L-3, but none in the thoracic or upper lumbar spine where the patient had pain. The SRS (right panel) demonstrates both thoracic and upper and lower lumbar spine metastases (arrows) as well as bone metastases to the left scapula and left pelvis. The primary tumor was also seen in the pancreatic tail (broken arrow) as well as the large numbers of liver metastases. The patient was treated with radiation to the area of the thoracic and L-1 spinal metastases, and the chemotherapy was changed. This patient represents an example of SRS altering management by identification of additional metastases which changed clinical management (Reason #5, Figure 1; Table 3).

laboratory characteristics (BAO, MAO, fasting gastrin level), in whether the patients had or had not undergone a previous gastrinoma resection, or whether liver metastases were present or absent ( $p = .06$ ). SRS was more likely to change management in patients with any positive conventional imaging study ( $p < .001$ ), a possible primary lesion on a conventional imaging study ( $p < .001$ ) or possible liver metastases on conventional imaging studies ( $p < .0001$ ).

### CONCLUSIONS OF THE NIH SRS MANAGEMENT STUDY

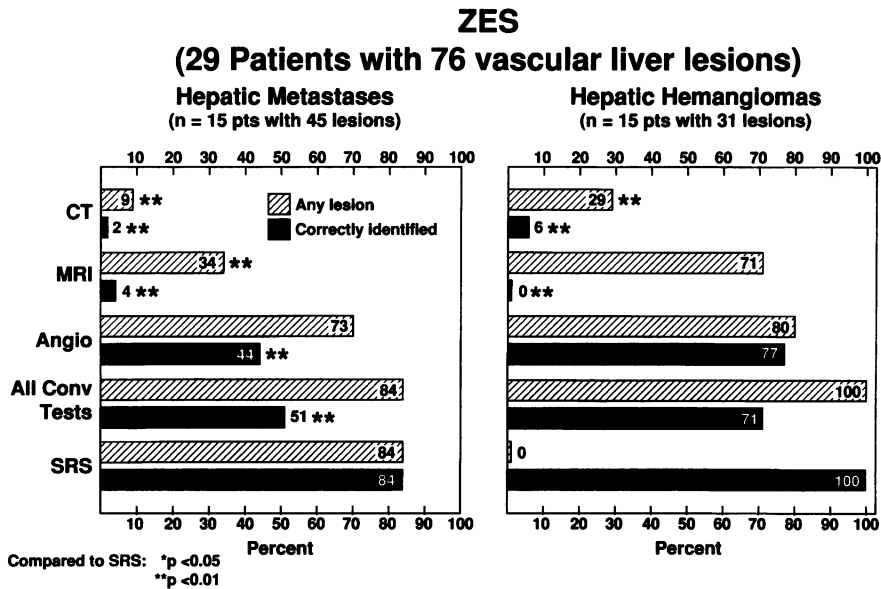
It was concluded that SRS, because of its ability to alter clinical management combined with its high sensitivity shown both in this study [31] and in previous studies [21-



23, 28, 29, 45, 46, 49-51], high specificity [21, 23, 27], and simplicity and ability to image the entire body, should be the initial imaging modality for patients with gastrinoma. Because SRS is as sensitive as all conventional imaging studies combined, and two conventional studies are usually performed, the initial use of SRS based on sensitivity alone is cost-effective. Furthermore, because somatostatin receptor density is similarly high in all other NETs except insulinomas [21, 22, 27, 52] and because of their similar biologic behavior to gastrinomas [1, 2], it is likely that these conclusions also apply to less common PETs and carcinoid tumors [31]. A recent review [53], presents data from a few studies that demonstrate SRS did not detect a number of small metastases in the liver in patients with metastatic carcinoids. Whether this result is due to the small size of the metastases or is specific for carcinoid tumors is presently unknown.

In the above NIH study, the main reason for SRS changing clinical management was the clarification of equivocal lesions on conventional imaging studies (29 percent). This was more than twice as common a reason for changing management than any other factor and made up more than 50 percent of the changes in management in each clinical category (Figure 1). One of the main lesions requiring clarification was the question of possible liver metastases identified on CT, MRI (particularly the STIR images [short T1 inversion-recovery pulse sequences]) or angiography. One of the main reasons for this confusion is that liver metastases from NETs are highly vascular [16], may be few in number and in many patients are small when first discovered (<1-2 cm); therefore, they may be very difficult to differentiate from other small vascular tumors of the liver, particularly hemangiomas, using the standard imaging techniques (MRI, CT, angiography) [54-56].

Cavernous hemangiomas of the liver are the most common benign tumor of the liver, occurring in 7.5-15 percent of autopsy cases [57, 58]. Cavernous hemangiomas can be difficult to distinguish from small metastases in patients with malignant NETs because they also are hypervascular and may be multiple in 10-50 percent of cases [57, 59]. Investigations such as  $^{99m}\text{Tc}$ -labeled red blood cell scintigraphy, heavily T2-weighted MRI, and dynamic bolus-enhanced CT or MRI are frequently falsely negative in hemangiomas less than 1.5 cm in diameter [54, 56, 60-63]. For example, in one recent study  $^{99m}\text{Tc}$  RBC scanning with SPECT imaging only detected 58 percent of 24 hemangiomas 1-1.9 cm in diameter [54]. There have been a number of reports of patients thought to have hepatic hemangiomas that later proved to be NETs [64-66]. In our study on the role of SRS in management presented above, one patient had both a liver metastasis and a hepatic hemangioma verified at surgical exploration, and although both were seen on MRI and angiography, only the metastasis was seen on the SRS. This case raised the possibility that the SRS might not generally identify hepatic hemangiomas, why it would identify almost all liver metastases and, thus, might be able to distinguish these two vascular abnormalities. High densities of somatostatin receptors are found in intestinal veins in patients with inflammatory bowel disease and in peritumoral veins, but not in normal veins or other vascular structures [67, 68]; however, it is unknown if an increased density of somatostatin receptors occurred in hemangiomas. To examine this possibility and to determine whether SRS was superior to other imaging studies in distinguishing whether small hepatic vascular lesions in patients with gastrinomas were metastases or hemangiomas, an additional study was performed [56].

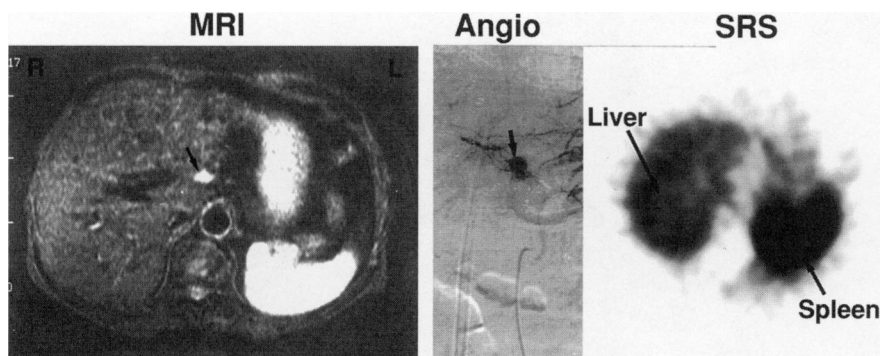


**Figure 4.** Ability of conventional imaging studies (CT, MRI, angiography) or SRS to either identify any hepatic lesion or correctly identify it as a metastasis or hemangioma in 15 patients with hepatic metastases and 15 patients with hepatic hemangiomas. All patients had Zollinger-Ellison syndrome. There were 76 vascular hepatic lesions in these 29 patients including 45 metastases and 31 hemangiomas. One patient had both a hemangioma and a hepatic metastasis. Results are the percent of lesions examined with the indicated imaging study which were positive in the indicated category. Zero percent of the hepatic hemangiomas gave a positive SRS result; therefore, 100 percent were correctly identified as not metastases. Results are from [56].

#### NIH STUDY OF THE ABILITY OF SRS AND CONVENTIONAL IMAGING STUDIES (CT, MRI, ANGIOGRAPHY) TO DISTINGUISH HEPATIC HEMANGIOMAS FROM METASTASES IN PATIENTS WITH GASTRINOMAS

##### *Methods for NIH SRS hemangioma study.*

Of 137 consecutive patients with gastrinoma admitted to the NIH, 29 patients were found to have small hypervascular liver lesions (< 3 cm diameter; mean: 1.3 cm) with less than five lesions per hepatic lobe or nine lesions per liver, and these patients were included in this study. Twenty-six of these patients had multiple previous NIH admissions (mean: seven admissions), and three patients were being investigated for the first time. Fifteen patients including three new patients were determined to have hepatic hemangiomas by the presence of one or more of the following: hemangioma observed during surgery (n = 3), by biochemical evidence of cure of the Zollinger-Ellison syndrome after resection of an extrahepatic gastrinoma (n = 7) or by the absence of growth of the lesion on standard imaging studies after a mean follow-up of four years (n = 5). In 15 patients, the hepatic lesions were shown to be metastatic tumor histologically by a CT- or ultrasound-guided percutaneous liver biopsy or during laparotomy. One patient was found to have both a hepatic hemangioma and a single liver metastasis. Each of the 29 patients

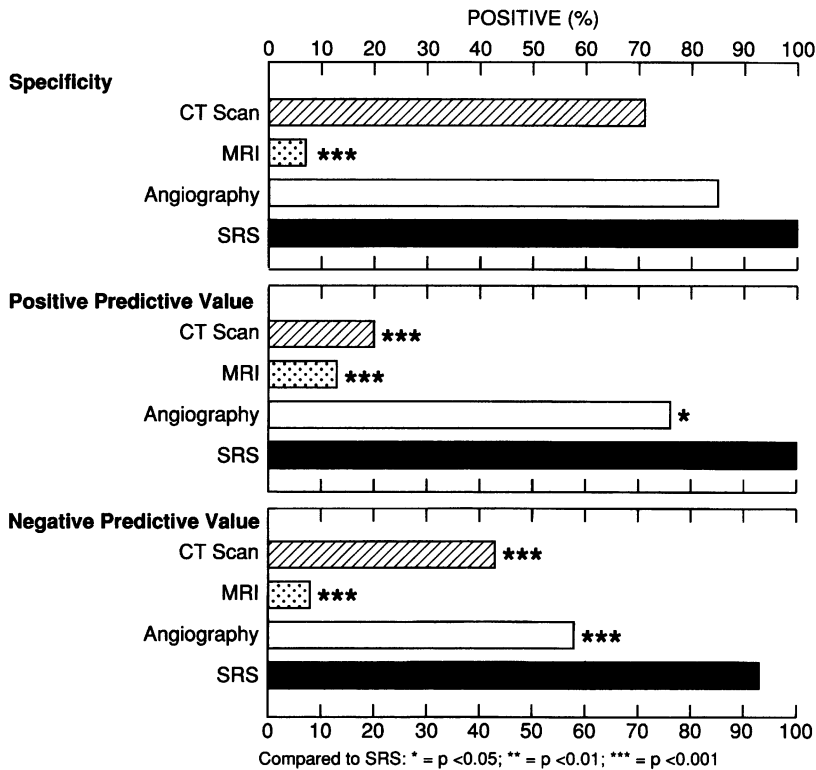


**Figure 5.** MRI, angiography and SRS in a patient with Zollinger-Ellison syndrome. The MRI (left panel) and angiography (middle panel) show a hepatic vascular lesion (arrows) that could represent a metastasis from the gastrinoma. The SRS (right panel) was negative. This hepatic lesion was determined to represent a hemangioma because with long-term follow-up it did not increase in size and the patient remained cured post resection of a duodenal tumor with normal fasting gastrin levels and a negative secretin test [97].

underwent a CT scan, MRI, selective angiography and SRS. A single radiologist who did not know the diagnosis read each film, determining whether any hepatic lesion could be seen and whether it was a hemangioma, metastasis, or whether it could not be determined which of the two vascular lesions it was. The CT criteria [60, 61, 69-71] and selective angiography criteria [72-74] were those previously described. On MRI both metastases and hemangiomas were of low signal intensity on T1-weighted images and bright on STIR images. Extreme brightness compared to the kidney or spleen was more suggestive of hemangioma.

#### *Results of SRS hemangioma study*

There were 31 hemangiomas in the 15 patients with a mean number of 2.1/patient (range: 1-9) with a mean size of  $1.3 \pm 0.1$  cm (range: 0.5 - 2.8 cm) with 60 percent less than 1 cm. There were 45 metastases in 15 patients with a mean of 2.5 lesions/patient (range: 1-8), with a mean size of  $1.3 \pm 0.1$  (range: 0.5 - 3 cm) (Figure 4). The data, whether analyzed on a per patient basis or a per lesion basis (Figure 4), showed similar results. SRS detected a hepatic metastases in 93 percent of patients with liver metastases. In patients with metastases, SRS and angiography were not significantly different in identifying the number of lesions, and both were significantly better than CT or MRI (Figure 4, left panel). However, for correctly identifying a lesion as a metastasis, the SRS correctly identified 84 percent of all metastases in 93 percent of the patients and was significantly better than any of the other studies or a combination of all of the studies ( $p < .01$ ) (Figure 4, left). In contrast, SRS was negative in all 15 patients with hemangiomas. Angiography and MRI both identified hepatic vascular lesions in over 70 percent of patients with hepatic hemangiomas. In contrast, angiography correctly identified 77 percent as hemangiomas, whereas CT and MRI correctly identified less than 10 percent (Figure 4, right panel). Figure 5 shows an example of such a patient in which the MRI and angiogram both demonstrate a possible hepatic metastasis, whereas the SRS was negative. This patient



**Figure 6.** Specificity, positive and negative predictive values of different imaging modalities in detecting liver metastases in 29 patients with Zollinger-Ellison syndrome and hypervascular hepatic lesions seen on any imaging study which could be either metastases or hemangiomas. The specificity, positive and negative predictive values are based on the lesion correctly identified in Figure 4. Data are from [56].

was biochemically cured post-gastrinoma resection and has remained disease-free for two years, confirming that the hepatic vascular lesion is a hemangioma.

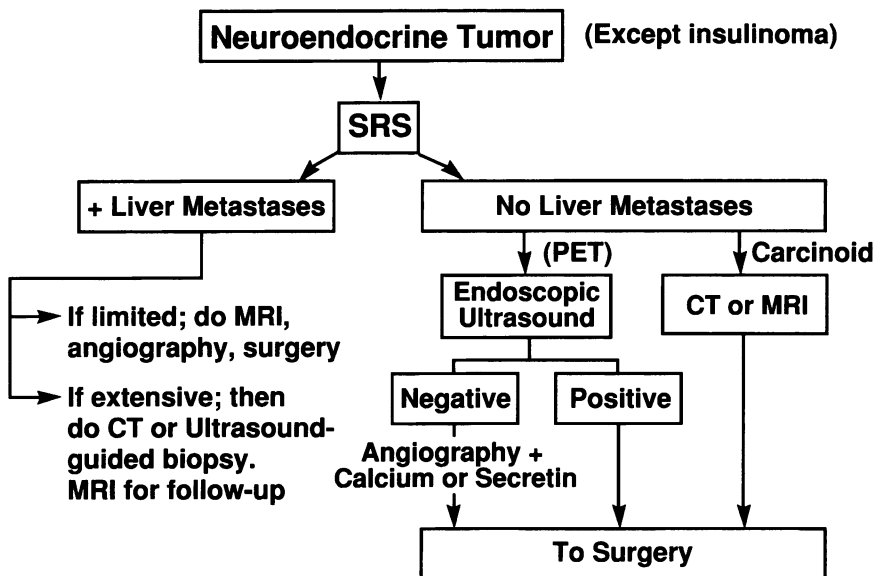
SRS was superior to all of the other studies for negative and positive predictive values and equal to CT scanning and angiography in terms of specificity (Figure 6).

#### *Conclusions of NIH SRS hemangioma study*

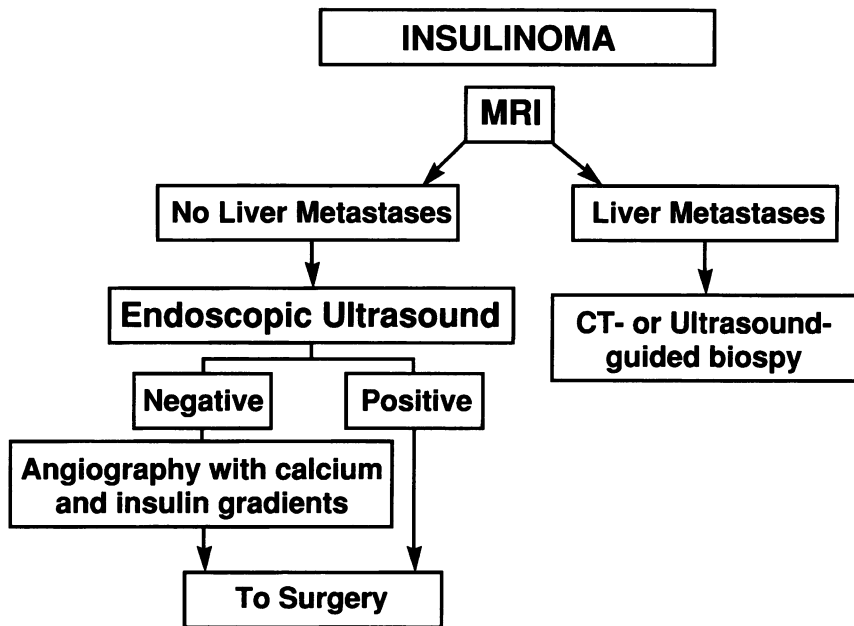
SRS is an excellent imaging modality for distinguishing small vascular hepatic metastases in patients with gastrinomas from small hemangiomas. Because hepatic metastases in patients with gastrinoma are similar in terms of density of somatostatin receptors, hypervascularity and CT, MRI and angiographic appearance of those occurring in other malignant NETs, SRS will likely be similarly useful in these syndromes. The practical ability of SRS to make this distinction and affect clinical management was shown in the previous study in which more than 50 percent of all the changes in management caused by SRS were due to clarification of equivocal lesions and at least 50 percent of these were related to equivocal hepatic vascular lesions.

**CONCLUSIONS FROM THE NIH SRS STUDIES AND PROPOSAL OF AN  
ALGORITHM FOR TUMOR LOCALIZATION IN PATIENTS WITH  
NEUROENDOCRINE TUMORS (EXCEPT INSULINOMAS)  
AND IN PATIENTS WITH INSULINOMAS**

The two NIH studies presented above clearly establish that the use of SRS affects clinical management in 47 percent of the cases [31] and is particularly helpful in clarifying equivocal results from conventional imaging studies, especially in regard to the identity of small vascular metastasis in the liver [56]. In the management study, the nearly one-half of all cases in which SRS altered management represents a measure of the clinical gain over existing conventional imaging studies by the use of SRS. In numerous studies in patients with different NETs except insulinomas, SRS has been shown to have either greater sensitivity than any conventional imaging study (i.e., ultrasound, CT scan, MRI, selective angiography) or is at least equal or better than all imaging studies combined [21, 23, 28-31, 44, 48, 56]. Therefore, performing just the SRS would be a much more cost-effective approach than performing each of the conventional imaging studies (Table 2) [31, 42]. Because of its increased sensitivity and ability to image the entire body, SRS gives information on the location of the primary tumor, possible regional tumor metastases and distal metastases. Therefore, it provides at least equal information to the conventional imaging studies in patients in which it did not change management, as well as the additional information it gives in patients in which it did change management. Lastly, the specificity



**Figure 7.** Algorithm for tumor localization in a patient with a neuroendocrine tumor (pancreatic endocrine tumor [PET], carcinoid tumor) that is not an insulinoma. Abbreviations: SRS, somatostatin receptor scintigraphy (see text for full explanation).



**Figure 8.** Algorithm for tumor localization in a patient with an insulinoma (see text for full explanation).

of SRS appears generally excellent [21, 23, 27] although it has not been carefully studied. SRS has been reported to be positive in various thyroid diseases [21, 27, 75], granulomatous diseases [21, 27, 76], and some arthrides [21, 27, 77]; however, this appears not to limit its usefulness in patients with NETs in various large studies [21, 23, 28, 31]. The conclusions drawn from the studies of gastrinoma can likely be extended to other PETs except insulinomas and also to carcinoid tumors because of the similar rate of occurrence of somatostatin receptors in these different tumors and their similar biologic behavior [1, 2, 7, 8]. Insulinomas are excluded because only 70 percent have somatostatin receptors [21, 22], and they also may possess somatostatin receptors that do not bind octreotide, especially subtypes sst1 and sst4, and only 14-50 percent are localized by SRS in some studies [22, 27, 30]. Each of the other neuroendocrine tumors can be malignant [21, 22, 78], and the treatment decisions are similar to that for gastrinomas in similar stages of their management [1, 2, 8, 26, 79]. Based on these considerations, the tumor localization approach as shown in Figure 7 for all NETs except insulinomas is recommended; and for insulinomas, the algorithm shown in Figure 8 is recommended.

For all NETs except insulinomas the SRS should be the initial localization study based on its sensitivity, specificity, ability to image the entire body and cost-effectiveness. If liver metastases are seen on the SRS and if they are extensive in both lobes, which is the case in 80-90 percent of patients with hepatic metastases, then surgical resection is not generally a consideration [1, 2, 8, 11-13, 33, 80]. To confirm the diagnosis, a CT- or ultrasound-guided biopsy can be performed (Figure 7). It is not yet established how changes in size or intensity of the SRS image relates to change in tumor size assessed by measuring tumor growth with conventional imaging studies; therefore, we recommend that if liver metastases are seen on SRS, a conventional imaging study be performed to facilitate

follow-up assessment of tumor growth. In our experience, the MRI, especially the STIR images, gives the best results and is the most sensitive [6, 55]. If the metastases are limited and cytoreductive surgery is considered [1, 2, 8, 11-13, 33, 80], we would recommend selective angiography and MRI to define the relationship of the metastases to the vasculature and clearly define the tumor size and location (Figure 7). A recent study [24] demonstrates that the use of the intra-arterial injection of secretin during angiography with hepatic venous sampling can be useful and will change management in 22 percent of cases with limited or equivocal hepatic lesions in patients with gastrinomas. This study [24] did not include the use of SRS, and it is unclear whether intra-arterial secretin with hepatic venous gastrin gradients would be as useful if the SRS did not clarify the situation. Therefore, until this study is done it is not recommended routinely.

If SRS does not show liver metastases in a non-insulinoma NET, no other imaging studies need to be performed to exclude liver metastases because the SRS detected 92 percent of patients with liver metastases, and the addition of all conventional imaging studies only increased the sensitivity by 4 percent in one large study [23]. However, additional studies to localize the primary tumor may be indicated (Figure 7). If the primary tumor is not localized on SRS in patients with a PET, endoscopic ultrasound should be the next procedure performed. EUS localizes almost all pancreatic PETs although it may miss as high as 50 percent of duodenal PETs [43, 81, 82]. If it is negative, angiography with selective intra-arterial injection of secretin or calcium and hepatic venous sampling should be performed [17-19]. At surgery, intraoperative ultrasound [14, 83] should be used and in the case of gastrinomas a duodenal exploration with duodenotomy [84, 85] is essential, with prior transillumination of the duodenum to assist in the placement of the duodenotomy and tumor localization [86]. In a patient with a carcinoid tumor with no liver metastases, CT or MRI are indicated to localize the primary tumor and its extent (Figure 7).

In patients with insulinomas, MRI should be the initial imaging study to exclude liver metastases that occur in 5-15 percent of patients with insulinomas in different series [9, 87-91]. In the algorithm (Figure 8), we have recommended an MRI be done because we find it easier to see PET metastases to the liver on the STIR sequences than with CT. If no liver metastases are seen, the localization study of choice is endoscopic ultrasound, which is reported to identify an insulinoma in 77-93 percent of patients [20, 30, 92, 93]. If this is negative, angiography with intra-arterial calcium injection with hepatic venous sampling for insulin gradients should be performed, because it is recently reported to be positive in 83-88 percent of cases [19, 94, 95]. At surgery, intra-operative ultrasound has been shown to be particularly helpful in localizing intrapancreatic endocrine tumors such as insulinomas and should be used [14, 80, 83, 96].

## REFERENCES

1. Jensen, R.T. and Norton, J.A. Carcinoid tumors and the carcinoid syndrome. In: DeVita, V.T., Jr., Hellman, S., and Rosenberg, S.A., eds. *Cancer: Principles and Practice of Oncology*. Philadelphia: Lippincott-Raven; 1997, pp. 1704-1723.
2. Norton, J.A., Levin, B., and Jensen, R.T. Cancer of the endocrine system. In: DeVita, V.T., Jr., Hellman, S., and Rosenberg, S.A., eds. *Cancer: Principles and Practice of Oncology*. Philadelphia: J.B. Lippincott; 1993, pp. 1333-1435.
3. Kloppel, G., Schroder, S., and Heitz, P.U. Histopathology and immunopathology of pancreatic endocrine tumors. In: Mignon, M. and Jensen, R.T. eds. *Endocrine Tumors of the Pancreas: Recent Advances in Research and Management*. Series: *Frontiers of Gastrointestinal Research*. Basel, Switzerland: S. Karger; 1995, pp. 99-120.
4. Kloppel, G. and Heitz, P.U. Classification of normal and neoplastic neuroendocrine cells. *Ann. N.Y. Acad. Sci.* 733:18-23, 1994.
5. Langley, K. The neuroendocrine concept today. *Ann. N.Y. Acad. Sci.* 733:1-17, 1994.
6. Orbuch, M., Doppman, J.L., Strader, D.B., Fishbeyn, V.A., Benya, R.V., Metz, D.C., and Jensen, R.T. Imaging for pancreatic endocrine tumor localization: recent advances. In: Mignon, M. and

- Jensen, R.T., eds. *Endocrine Tumors of the Pancreas: Recent Advances in Research and Management*. Series: *Frontiers of Gastrointestinal Research*. Basel, Switzerland: S. Karger; 1995, pp. 268-281.
7. Weber, H.C. and Jensen, R.T. Pancreatic endocrine tumors and carcinoid tumors: recent insights from genetic and molecular biologic studies. In: Dervenis, C.G., ed. *Advances in Pancreatic Disease: Molecular Biology, Diagnosis and Treatment*. Stuttgart, New York: Georg Thieme Verlag; 1996, pp. 55-75.
  8. Jensen, R.T. and Gardner, J.D. Gastrinoma. In: Go, V.L.W., DiMagno, E.P., Gardner, J.D., Lebenthal, E., Reber, H.A., and Scheele, G.A., eds. *The Pancreas: Biology, Pathobiology and Disease*. New York: Raven Press; 1993, pp. 931-978.
  9. Jensen, R.T. and Norton, J.A. Endocrine tumors of the pancreas. In: Yamada, T., Alpers, B.H., Owyang, C., Powell, D.W., and Silverstein, F.E., eds. *Textbook of Gastroenterology*. Second Edition. Philadelphia: J.B. Lippincott; 1995, pp. 2131-2166.
  10. Mignon, M. and Jensen, R.T., eds. *Endocrine Tumors of the Pancreas: Recent Advances in Research and Management*. In: *Frontiers of Gastrointestinal Research*, Vol. 23. Basel, Switzerland: S. Karger; 1995, pp. 1-477.
  11. Nagorney, D.M. and Que, F.G. Cytoreductive hepatic surgery for metastatic gastrointestinal neuroendocrine tumors. In: Mignon, M., and Jensen, R.T., eds. *Endocrine Tumors of the Pancreas: Recent Advances in Research and Management*. Series: *Frontiers of Gastrointestinal Research*. Basel, Switzerland: S. Karger; 1995, pp. 416-430.
  12. Carty, S.E., Jensen, R.T., and Norton, J.A. Prospective study of aggressive resection of metastatic pancreatic endocrine tumors. *Surgery* 112:1024-1031, 1992.
  13. Que, F.G., Nagorney, D.M., Batts, K.P., Linz, L.J., and Kvols, L.K. Hepatic resection for metastatic neuroendocrine carcinomas. *Am. J. Surg.* 169:36-43, 1995.
  14. Norton, J.A. Surgical treatment of islet cell tumors with special emphasis on operative ultrasound. In: Mignon, M., and Jensen, R.T., eds. *Endocrine Tumors of the Pancreas: Recent Advances in Research and Management*. Series: *Frontiers of Gastrointestinal Research*. Basel, Switzerland: S. Karger; 1995, pp. 309-332.
  15. Norton, J.A. Neuroendocrine tumors of the pancreas and duodenum. *Curr. Probl. Surg.* 31:1-156, 1994.
  16. Doppman, J.D., Shawker, T.H., and Miller, D.C. Localization of islet cell tumors. *Gastroenterol. Clin. North. Am.* 18:793-804, 1989.
  17. Strader, D.B., Doppman, J.L., Orbuch, M., Fishbeyn, V.A., Benya, R.V., Jensen, R.T., and Met, D.C. Functional localization of pancreatic endocrine tumors. In: Mignon, M. and Jensen, R.T., eds. *Endocrine Tumors of the Pancreas: Recent Advances in Research and Management*. Series: *Frontiers of Gastrointestinal Research*. Basel, Switzerland: S. Karger; 1995, pp. 282-297.
  18. Thom, A.K., Norton, J.A., Doppman, J.L., Chang, R., Miller, D.L., and Jensen, R.T. Prospective study of the use of intraarterial secretin injection and portal venous sampling to localize duodenal gastrinomas. *Surgery* 112(#6):1002-1008, 1992.
  19. Doppman, J.L., Chang, R., Fraker, D.L., Norton, J.A., Alexander, R., Miller, D.L., Collier, E., Skarulis, M.C., and Gorden, P. Localization of insulinomas to regions of the pancreas by intraarterial stimulation with calcium. *Ann. Intern. Med.* 123:269-273, 1995.
  20. Ruzsiewicz, P., Amouyal, P., Amouyal, G., Cadiot, G., Mignon, M., and Bernades, P. Endocrine tumors of the pancreatic area: localization by endoscopic ultrasonography. In: Mignon, M. and Jensen, R.T., eds. *Endocrine Tumors of the Pancreas: Recent Advances in Research and Management*. Series: *Frontiers of Gastrointestinal Research*. Basel, Switzerland: S. Karger; 1995, pp. 258-267.
  21. Krenning, E.P., Kwekkeboom, D.J., Bakker, W.H., Breeman, W.A.P., Kooij, P.P.M., Oei, H.Y., van Hagen, M., Postema, P.T.E., de Jong, M., Reubi, J.C., Visser, T.J., Reijs, A.E.M., Hofland, L.J., Koper, J.W., and Lamberts, S.W.J. Somatostatin receptor scintigraphy with [<sup>111</sup>In-DTPA-D-Phe<sup>1</sup>]- and [<sup>123</sup>I-Tyr<sup>3</sup>]-octreotide: the Rotterdam experience with more than 1000 patients. *Eur. J. Nucl. Med.* 20:716-731, 1993.
  22. Krenning, E.P., Kwekkeboom, D.J., Oei, H.Y., de Jong, R.J.B., Dop, F.J., Reubi, J.C., and Lamberts, S.W.J. Somatostatin-receptor scintigraphy in gastroenteropancreatic tumors. *Ann. N. Y. Acad. Sci.* 733:416-424, 1994.
  23. Gibril, F., Reynolds, J.C., Doppman, J.L., Chen, C.C., Venzon, D.J., Termanini, B., Weber, H.C., Stewart, C.A., and Jensen, R.T. Somatostatin receptor scintigraphy: its sensitivity compared with that of other imaging methods in detecting primary and metastatic gastrinomas: a prospective study. *Ann. Intern. Med.* 125:26-34, 1996.



24. Gibril, F., Doppman, J.L., Chang, R., Weber, H.C., Termanini, B., and Jensen, R.T. Metastatic gastrinomas: localization with selective arterial injection of secretin. *Radiology* 198:77-84, 1996.
25. Norton, J.A., Doppman, J.L., Collen, M.J., Harmon, J.W., Maton, P.N., Gardner, J.D., and Jensen, R.T. Prospective study of gastrinoma localization and resection in patients with Zollinger-Ellison syndrome. *Ann. Surg.* 204:468-479, 1986.
26. Fraker, D.L. and Jensen, R.T. Pancreatic endocrine tumors. In: DeVita, V.T., Hellman, S., and Rosenberg, S.A., eds. *Cancer: Principles and Practice of Oncology*. Philadelphia: Lippincott-Raven Publishers; 1997, pp. 1678-1704.
27. Jensen, R.T. Peptide therapy. Recent advances in the use of somatostatin and other peptide receptor agonists and antagonists. In: Lewis, J.H. and Dubois, A., eds. *Current Clinical Topics in Gastrointestinal Pharmacology*. Malden, MA: Blackwell Science, Inc.; 1997, pp. 144-223.
28. de Kervier, E., Cadot, G., Lebtahi, R., Faraggi, M., le Guludec, D., and Mignon, M. Somatostatin receptor scintigraphy in forty-eight patients with the Zollinger-Ellison syndrome. *Eur. J. Nucl. Med.* 21:1191-1197, 1994.
29. Scherubl, H., Bader, M., Fett, U., Hamm, B., Schmidt-Gayk, H., Koppenhagen, K., Dop, F.J., Riecken, E.O., and Wiedenmann, B. Somatostatin-receptor imaging of neuroendocrine gastroenteropancreatic tumors. *Gastroenterology* 105:1705-1709, 1993.
30. Zimmer, T., Stolzel, U., Bader, M., Koppenhagen, K., Hamm, B., Buhr, H., Riecken, E.O., and Wiedenmann, B. Endoscopic ultrasonography and somatostatin receptor scintigraphy in the pre-operative localization of insulinomas and gastrinomas. *Gut* 39:562-568, 1996.
31. Termanini, B., Gibril, F., Reynolds, J.C., Doppman, J.L., Chen, C.C., Stewart, C.A., Sutliff, V., and Jensen, R.T. Value of somatostatin receptor scintigraphy: A prospective study in gastrinoma of its effect on clinical management. *Gastroenterology* 112:335-347, 1997.
32. Metz, D.C., Jensen, R.T., Bale, A.E., Skarulis, M.C., Eastman, R.C., Nieman, L., Norton, J.A., Friedman, E., Larsson, C., Amorosi, A., Brandi, M.L., and Marx, S.J. Multiple endocrine neoplasia type 1: clinical features and management. In: Bilezikian, J.P., Levine, M.A., and Marcus, R., eds. *The Parathyroids*. New York: Raven Press; 1994, pp. 591-646.
33. Norton, J.A., Sugarbaker, P.H., Doppman, J.L., Wesley, R.A., Maton, P.N., Gardner, J.D., and Jensen, R.T. Aggressive resection of metastatic disease in selected patients with malignant gastrinoma. *Ann. Surg.* 203:352-359, 1986.
34. Arnold, R. and Frank, M. Systemic chemotherapy for endocrine tumors of the pancreas: recent advances. In: Mignon, M. and Jensen, R.T., eds. *Endocrine Tumors of the Pancreas: Recent Advances in Research and Management*. Series: *Frontiers of Gastrointestinal Research*. Basel, Switzerland: S. Karger; 1995, pp. 431-438.
35. Oberg, K. The use of chemotherapy in the management of neuroendocrine tumors. *Endocrinol. Metab. Clin. North Am.* 22:941-952, 1993.
36. Azoulay, D. and Bismuth, H. Role of liver surgery and transplantation in patients with hepatic metastases from pancreatic endocrine tumors. In: Mignon, M. and Jensen, R.T., eds. *Endocrine Tumors of the Pancreas: Recent Advances in Research and Management*. Series: *Frontiers of Gastrointestinal Research*. Basel, Switzerland: S. Karger; 1995, pp. 461-476.
37. Jensen, R.T. Pancreatic endocrine tumors. *Curr. Opin. Gastroenterol.* 11:423-429, 1995.
38. Bechstein, W.O. and Neuhaus, P. Liver transplantation for hepatic metastases of neuroendocrine tumors. *Ann. N. Y. Acad. Sci.* 733:507-514, 1994.
39. Jensen, R.T. and Fraker, D.L. Zollinger-Ellison syndrome: Advances in treatment of the gastric hypersecretion and the gastrinoma. *JAMA* 271:1-7, 1994.
40. MacFarlane, M.P., Fraker, D.L., Alexander, H.R., Norton, J.A., and Jensen, R.T. A prospective study of surgical resection of duodenal and pancreatic gastrinomas in multiple endocrine neoplasia-Type 1. *Surgery* 118:973-980, 1995.
41. Sheppard, B.C., Norton, J.A., Doppman, J.L., Maton, P.N., Gardner, J.D., and Jensen, R.T. Management of islet cell tumors in patients with Multiple Endocrine Neoplasia: A Prospective Study. *Surgery* 106:1108-1117, 1989.
42. Bansal, R., Carpenter, S.L., Tierney, W.M., Nostrant, T.T., Elta, G.H., Thompson, N., and Scheiman, J.M. Cost effectiveness of endoscopic ultrasound for pre-operative localization of pancreatic endocrine tumors: a case-control study. *Gastroenterology* 110:A3, 1996 (Abstract).
43. Ruzniewski, P., Amouyal, P., Amouyal, G., Grange, J.D., Mignon, M., Bouch, O., and Bernades, P. Localization of gastrinomas by endoscopic ultrasonography in patients with Zollinger-Ellison syndrome. *Surgery* 117:629-635, 1995.
44. Kisker, O., Weinel, R.J., Geks, J., Zacara, F., Joseph, K., and Rothmund, M. Value of somatostatin receptor scintigraphy for preoperative localization of carcinoids. *World J. Surg.* 20:162-167, 1996.

45. Joseph, K., Stapp, J., Reinecke, J., Skamel, H.J., Höffken, H., Neuhaus, C., Lenze, H., Trautmann, M.E., and Arnold, R. Receptor scintigraphy with <sup>111</sup>In-Pentetreotide for endocrine gastroenteropancreatic tumors. *Horm. Metab. Res.* 27(suppl):28-35, 1993.
46. Hammond, P.J., Arka, A., Peters, A.M., Bloom, S.R., and Gilbey, S.G. Localization of metastatic gastroenteropancreatic tumours by somatostatin receptor scintigraphy with [<sup>111</sup>In-DTPA-D-Phe<sup>1</sup>]-octreotide. *Q. J. Med.* 87:83-88, 1994.
47. Pauwels, S., Leners, N., Fiasse, R., and Jamar, F. Localization of gastroenteropancreatic neuroendocrine tumors with <sup>111</sup>Indium-pentetreotide scintigraphy. *Semin. Oncol.* 21:15-20, 1994.
48. Jamar, F., Fiasse, R., Leners, N., and Pauwels, S. Somatostatin receptor imaging with indium-<sup>111</sup>-pentetreotide in gastroenteropancreatic neuroendocrine tumors: safety, efficacy and impact on patient management. *J. Nucl. Med.* 36:542-549, 1995.
49. Kvols, L.K. Somatostatin-receptor imaging of human malignancies: a new era in the localization, staging, and treatment of tumors. *Gastroenterology* 105:1909-1914, 1993.
50. Weinel, R.J., Neuhaus, C., Stapp, J., Klotter, H.J., Trautmann, M.E., Joseph, K., Arnold, R., and Rothmund, M. Preoperative localization of gastrointestinal endocrine tumors using somatostatin-receptor scintigraphy. *Ann. Surg.* 218:640-645, 1993.
51. Zimmer, T., Ziegler, K., Bader, M., Fett, U., Hamm, B., Riecken, E.O., and Wiedenmann, B. Localization of neuroendocrine tumours of the upper gastrointestinal tract. *Gut* 35:471-475, 1994.
52. Reubi, J.C., Laissue, J., Waser, B., Horisberger, U., and Schaefer, J.C. Expression of somatostatin receptors in normal, inflamed, and neoplastic human gastrointestinal tissues. *Ann. N. Y. Acad. Sci.* 733:122-137, 1994.
53. Valkema, R., Steens, J., Cleton, F.J., and Pauwels, E.K.J. The diagnostic utility of somatostatin receptor scintigraphy in oncology. *Cancer Res. Clin. Oncol.* 122:513-532, 1996.
54. Birnbaum, B.A., Weinreb, J.C., Megibow, A.J., Sanger, J.J., Lubat, E., Kanamuller, H., Noz, M.E., and Bosniak, M.A. Definitive diagnosis of hepatic hemangiomas: MR imaging versus Tc-<sup>99m</sup>-labeled red blood cell SPECT. *Radiology* 176:95-101, 1990.
55. Pisegna, J.R., Doppman, J.L., Norton, J.A., Metz, D.C., and Jensen, R.T. Prospective comparative study of ability of MR imaging and other imaging modalities to localize tumors in patients with Zollinger-Ellison syndrome. *Dig. Dis. Sci.* 38:1318-1328, 1993.
56. Termanini, B., Gibril, F., Doppman, J.L., Reynolds, J.C., Stewart, C.A., Sutliff, V.E., Venzon, D.J., and Jensen, R.T. Distinguishing small hepatic hemangiomas from vascular liver metastases in patients with gastrinoma: use of a somatostatin-receptor scintigraphic agent. *Radiology* 202:151-158, 1997.
57. Ishak, K.G. and Rabin, L. Benign tumors of the liver. *Med. Clin. North Am.* 59:995-1013, 1975.
58. Moriura, S., Ikeda, S., Hirai, M., Naiki, K., Fujioka, T., Yokochi, K., and Gotou, S. Hepatic gastrinoma. *Cancer* 72:1547-1550, 1993.
59. Karhunen, P.J. Benign hepatic tumours and tumour like conditions in men. *J. Clin. Pathol.* 39:183-188, 1986.
60. Itai, Y., Ohtomo, K., Furui, S., Iio, M., and Atomi, Y. Computed tomography and sonography of cavernous hemangioma of the liver. *Am. J. Roentgenol.* 141:315-320, 1983.
61. Itai, Y., Ohtomo, K., Furui, S., Yamauchi, T., Minami, M., and Yashiro, N. Noninvasive diagnosis of small cavernous hemangioma of the liver: advantage of MRI. *Am. J. Roentgenol.* 145:1195-1199, 1985.
62. Bonanno, N., Baldari, S., Cerrito, A., Zimbaro, G., Restifo, G., Blandino, A., and Freni, O. Diagnosis of hepatic hemangiomas with <sup>99m</sup>Tc-labeled red blood cell scanning: value of SPECT. *J. Nucl. Biol. Med.* 35:135-140, 1991.
63. Li, K.C., Glazer, G.M., Quint, L.E., Francis, I.R., Aisen, A.M., Ensminger, W.D., and Bookstein, F.L. Distinction of hepatic cavernous hemangioma from hepatic metastases with MR imaging. *Radiology* 169:409-415, 1988.
64. Farlow, D.C., Little, M., Gruenewald, S.M., Antico, V.F., and O'Neill, P. A case of metastatic malignancy masquerading as a hepatic hemangioma on labeled red blood cell scintigraphy. *J. Nucl. Med.* 34:1172-1174, 1993.
65. Soyer, P., Gueye, C., Somveille, E., Laissy, J.P., and Scherrer, A. MR diagnosis of hepatic metastases from neuroendocrine tumors versus hemangiomas: relative merits of dynamic gadolinium chelate—enhanced gradient-recalled echo and unenhanced spin-echo images. *Am. J. Roentgenol.* 165:1407-1413, 1995.
66. Dai, W., Shi, Y., and Cai, L. Report of a case of glucagonoma as misdiagnosed. *Chinese Journal of Internal Medicine* 34:190-192, 1995.
67. Reubi, J.C., Horisberger, U., and Laissue, J. High density of somatostatin receptors in veins surrounding human cancer tissue: role in tumor-host interaction? *Int. J. Cancer* 56:681-688, 1994.

68. Reubi, J.C., Mazzucchelli, L., and Laissue, J.A. Intestinal vessels express a high density of somatostatin receptors in human inflammatory bowel disease. *Gastroenterology* 106:951-959, 1994.
69. Freeny, P.C. and Marks, W.M. Hepatic hemangioma: dynamic bolus CT. *Am. J. Roentgenol.* 147:711-719, 1986.
70. Leslie, D.F., Johnson, C.D., Johnson, C.M., Ilstrup, D.M., and Harmsen, W.S. Distinction between cavernous hemangiomas of the liver and hepatic metastases on CT: value of contrast enhancement patterns. *Am. J. Roentgenol.* 164:625-629, 1995.
71. Quinn, S.F. and Benjamin, G.G. Hepatic cavernous hemangiomas: simple diagnostic sign with dynamic bolus CT. *Radiology* 182:545-548, 1992.
72. Johnson, C.M., Sheedy, P.F., Stanson, A.W., Stephens, D.H., Hattery, R.R., and Adson, M.A. Computed tomography and angiography of cavernous hemangiomas of the liver. *Radiology* 138:115-121, 1981.
73. Pollard, J.J., Fleischli, D.J., and Nebesar, R.A. Angiography of hepatic neoplasms. *Radiol. Clin. North Am.* 8:31-41, 1970.
74. McLoughlin, M.J. Angiography in cavernous hemangioma of the liver. *Am. J. Roentgenol.* 113:50-55, 1971.
75. Becker, W., Schrell, U., Buchfelder, M., Hensen, J., Wendler, J., Gramatzki, M., and Wolf, F. Somatostatin receptor expression in the thyroid demonstrated with <sup>111</sup>In-octreotide scintigraphy. *Nuklearmedizin* 34:100-103, 1995.
76. Vanhagen, P.M., Krenning, E.P., Reubi, J.C., Kwekkeboom, D.J., Bakker, W.H., Mulder, A.H., Laissue, I., Hoogstede, H.C., and Lamberts, S.W. Somatostatin analogue scintigraphy in granulomatous diseases. *Eur. J. Nucl. Med.* 21:497-502, 1994.
77. Vanhagen, P.M., Markusse, H.M., Lamberts, S.W., Kwekkeboom, D.J., Reubi, J.C., and Krenning, E.P. Somatostatin receptor imaging: the presence of somatostatin receptors in rheumatoid arthritis. *Arthritis Rheum.* 37:1521-1527, 1994.
78. Krenning, E.P., Kwekkeboom, D.J., Reubi, J.C., van Hagen, P.M., van Eijck, C.H.J., Oei, H.Y., and Lamberts, S.W.J. <sup>111</sup>In-octreotide scintigraphy in oncology. *Digestion* 54(suppl 1):84-87, 1993.
79. Miller, L.S., Doppman, J., Maton, P.N., Gardner, J.D., and Jensen, R.T. Zollinger-Ellison syndrome. *Advances in diagnosis and treatment. Handbk. Exper. Pharmacol.* 99:349-400, 1991.
80. Jensen, R.T. and Norton, J.A. Endocrine tumors of the pancreas. In: Feldman, M., Scharschmidt, B.F., and Sleisenger, M.H. eds. *Gastrointestinal and Liver Disease.* Philadelphia: W.B. Saunders; 1998, pp. 871-894.
81. Cadiot, G., Lebtahi, R., Sarda, L., Bonnaud, G., Marmuse, J.P., Vissuzaine, C., Ruszniewski, P., le Guludec, D., and Mignon, M. Preoperative detection of duodenal gastrinomas and peripancreatic lymph nodes by somatostatin receptor scintigraphy. *Gastroenterology* 111:845-854, 1996.
82. Thompson, N.W., Czako, P.F., Fritts, L.L., Bude, R., Bansal, R., Nostrant, T.T., and Scheiman, J.M. Role of endoscopic ultrasonography in the localization of insulinomas and gastrinomas. *Surgery* 116:1131-1138, 1994.
83. Norton, J.A., Cromack, D.T., Shawker, T.H., Doppman, J.L., Comi, R., Gorden, P., Maton, P.N., Gardner, J.D., and Jensen, R.T. Intraoperative ultrasonographic localization of islet cell tumors. A prospective comparison to palpation. *Ann. Surg.* 207:160-168, 1988.
84. Sugg, S.L., Norton, J.A., Fraker, D.L., Metz, D.C., Pisegna, J.R., Fishbeyn, V., Benya, R.V., Shawker, T.H., Doppman, J.L., and Jensen, R.T. A prospective study of intraoperative methods to diagnose and resect duodenal gastrinomas. *Ann. Surg.* 218:138-144, 1993.
85. Jensen, R.T. Gastrin-producing tumors. *Cancer Treat. Res.* 89:293-334, 1997.
86. Frucht, H., Norton, J.A., London, J.F., Vinayek, R., Doppman, J.L., Gardner, J.D., Jensen, R.T., and Maton, P.N. Detection of duodenal gastrinomas by operative endoscopic transillumination: a prospective study. *Gastroenterology* 99:1622-1627, 1990.
87. Stefanini, P., Carboni, M., Patrassi, N., and Basoli, A. Beta-islet cell tumors of the pancreas: results of a study on 1,067 cases. *Surgery* 75:597-609, 1974.
88. Service, F.J., Dale, A.J., Elveback, L.R., and Jiang, N.S. Insulinoma: clinical and diagnostic features of 60 consecutive cases. *Mayo Clin. Proc.* 51:417-429, 1976.
89. Jensen, R.T. Pancreatic endocrine tumors. Recent advances. In: Sleisenger, M.H., and Fordtran, J.S. eds. *Gastrointestinal Disease. Pathophysiology, Diagnosis and Management.* Philadelphia: W.B. Saunders; 1995, pp. 1-17.

90. Creutzfeldt, W. Insulinomas: Clinical presentation, diagnosis, and advances in management. In: Mignon, M., and Jensen, R.T. eds. *Endocrine Tumors of the Pancreas: Recent Advances in Research and Management*. Series: *Frontiers of Gastrointestinal Research*. Basel, Switzerland: S. Karger; 1995, pp. 148-165.
91. Comi, R.J., Gorden, P., and Doppman, J.L. Insulinoma. In: Go, V.L.W., Lebenthal, E., DiMagno, E.P., Reber, H.A., Gardner, J.D., and Scheele, G.A. eds. *The Pancreas: Biology, Pathobiology, and Disease*. New York: Raven Press; 1993, pp. 979-996.
92. Rosch, T., Lightdale, C.J., Botet, J.F., Boyce, G.A., Sivak, M.V., Jr., Yasuda, K., Heyder, N., Palazzo, L., Dancygier, H., and Schusdziarra, V. Localization of pancreatic endocrine tumors by endoscopic ultrasonography. *N. Engl. J. Med.* 326:1721-1726, 1992.
93. Palazzo, L., Roseau, G., and Salmeron, M. Endoscopic ultrasonography in the preoperative localization of pancreatic endocrine tumors. *Endoscopy* 24:350-353, 1992.
94. Doppman, J.L., Miller, D.L., Chang, R., Shawker, T.H., Gorden, P., and Norton, J.A. Insulinomas: localization with selective intraarterial injection of calcium [published erratum appears in *Radiology* 1993 Jun; 187(3):880]. *Radiology* 178:237-241, 1991.
95. O'Shea, D., Rohrer-Theus, A.W., Lynn, J.A., Jackson, J.E., and Bloom, S.R. Localization of insulinomas by selective intraarterial calcium injection. *J. Clin. Endocrinol. Metab.* 81:1623-1627, 1996.
96. Norton, J.A., Shawker, T.H., Doppman, J.L., Miller, D.L., Fraker, D.L., Cromack, D.T., Gorden, P., and Jensen, R.T. Localization and surgical treatment of occult insulinomas. *Ann. Surg.* 212:615-620, 1990.
97. Fishbeyn, V.A., Norton, J.A., Benya, R.V., Pisegna, J.R., Venzon, D.J., Metz, D.C., and Jensen, R.T. Assessment and prediction of long-term cure in patients with Zollinger-Ellison syndrome: the best approach. *Ann. Intern. Med.* 119:199-206, 1993.