

Available online at [www.sciencedirect.com](http://www.sciencedirect.com)

ScienceDirect

journal homepage: [www.elsevier.com/locate/radcr](http://www.elsevier.com/locate/radcr)

## Case Report

# Spigelian-cryptorchidism syndrome: Lesson based on a case report ☆☆☆★

Renato Farina, MD<sup>a,\*</sup>, Monica Pennisi, MD<sup>a</sup>, Carla Desiderio, MD<sup>a</sup>, Pietro Valerio Foti, PhD<sup>a</sup>, Mattia D'Urso, MD<sup>a</sup>, Corrado Inì, MD<sup>a</sup>, Claudia Motta, MD<sup>a</sup>, Sebastiano Galioto, MD<sup>a</sup>, Alfredo Garofalo, MD<sup>a</sup>, Mariangela Clemenza, MD<sup>a</sup>, Adriana Ilardi, MD<sup>a</sup>, Salvatore Lavallo, PhD<sup>b</sup>, Antonio Basile, PhD<sup>a</sup>

<sup>a</sup> Department of Medical and Surgical Sciences and Advanced Technologies "GF Ingrassia", University of Catania, Italy

<sup>b</sup> Università degli Studi di Enna, Kore, Italy

## ARTICLE INFO

## Article history:

Received 19 February 2024

Revised 22 April 2024

Accepted 25 April 2024

## Keywords:

Congenital anomalies

Spigelian hernia

Ultrasound

Criptorchidism

## ABSTRACT

The Spigelian hernia is a abdominal wall hernia that originates from a discontinuity of the Spigelian fascia located lateral to the rectus abdominis muscle. It can be acquired in adults or congenital in newborns. In very rare cases in male it can be associated with cryptorchidism, in which case it is known as "Spigellian-Cryptorchidism Syndrome". It can be clinically highlighted with abdominal swelling wall along the semilunar line and intestinal obstruction. The diagnosis, as in all pediatric emergencies, must be timely and the method of choice is ultrasound which allows a rapid localization of the hernia breach and herniated structures. The treatment of choice is surgical with hernioplasty and repositioning of the testicle into the scrotal sac, or orchipexy in cases of testicular necrosis. We describe ultrasound characteristics of Spigellian-cryptorchidism syndrome presenting with acute intestinal obstruction in a newborn.

© 2024 Published by Elsevier Inc. on behalf of University of Washington.

This is an open access article under the CC BY-NC-ND license (<http://creativecommons.org/licenses/by-nc-nd/4.0/>)

## Introduction

Spigelian hernia (SH) [1] is a rare ventral hernia with an incidence of 0.12% among all abdominal hernias [2], it can

be congenital or acquired. The acquired form is typical of adults [3] and is usually due to trauma or high abdominal pressure which causes the leakage of a viscera through the Spigelian fascia which is a continuation of the transversus

☆ Acknowledgments: There are no sources of funding for the research.

☆☆ Competing Interests: The authors declare that they have no known competing financial interests or personal relationships that could have appeared to influence the work reported in this paper.

\* Ethical approval: "All procedures performed in studies involving human participants were in accordance with the ethical standards of the institutional and/or national research committee and with the 1964 Helsinki declaration and its later amendments or comparable ethical standards.

\* Corresponding author.

E-mail address: [radfaro@hotmail.com](mailto:radfaro@hotmail.com) (R. Farina).

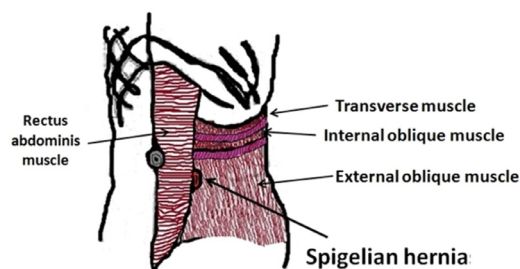
<https://doi.org/10.1016/j.radcr.2024.04.080>

1930-0433/© 2024 Published by Elsevier Inc. on behalf of University of Washington. This is an open access article under the CC BY-NC-ND license (<http://creativecommons.org/licenses/by-nc-nd/4.0/>)

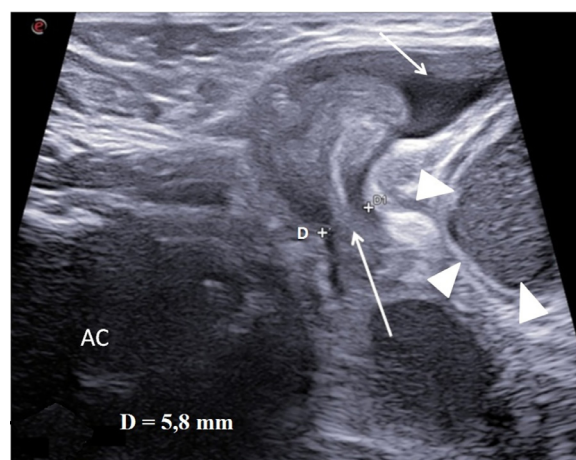
muscle aponeurosis, delimited laterally by the semilunar line and medially by the lateral border of the rectus muscle. The linea semilunaris is the vertical fibrous band located lateral to the rectus abdominis muscle, originating from the union of the rectus sheath with the band of the transversus, internal oblique and external oblique muscles. These hernia can be high or low depending on whether they are located superolaterally to the inferior epigastric vessels or medially and inferiorly (Fig. 1). Congenital SH [4] are due to the Spigelian fascia breach, through which the leak of extraperitoneal or intraperitoneal fat, peritoneum, viscera, and abdominal organs can occur. In male newborns, a very rare syndrome is given by the association between SH and cryptorchidism, mono or bilateral [5], where there is involvement of not only the abdominal viscera but also undescended testicle (cryptorchidism) due to gubernacular canal aplasia or peritoneal-vaginal duct patency. The gubernacular canal originates from a fibromuscular cord which in the male unites the lower pole of the Wolff body to the portion of inguinal peritoneum which gives rise to the vaginal process. The “Gubernaculum testis” becomes adherent to the testicle when it begins its descent towards the scrotal sac and it joins via the cord and the vaginal process to the lining of the genital swelling, thus forming the path of descent from the abdominal cavity crossing the wall of internal oblique and transversus muscles from where the testicle reaches the scrotal sac. Around the twenty-eighth week of pregnancy, the closure of peritoneal-vaginal duct begins and normally ends in the first month of life. Failure to close of peritoneal-vaginal duct in males can cause various pathologies including congenital inguinal hernia [6], communicating hydrocele [7], cord cyst [8], and cryptorchidism [9]. SH with associated cryptorchidism was first reported in 1895 by Schoofs and later called “Spigelian-Cryptorchidism syndrome” (SCS) by Raveenthiran [10] and subsequently reported by other authors [11,12]. In 87% of cases the testicle is located inside the hernia sac. The diagnosis is clinical and instrumental. Ultrasound (US) is the first level exam and generally concludes the diagnostic process. The treatment of choice is surgical. We describe a rare case of SCS presenting with acute intestinal obstruction in a newborn.

### Case presentation

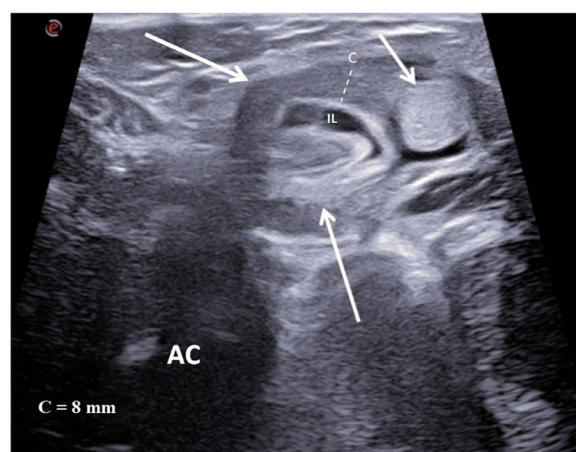
A 4 month old male born full term, healthy he arrived at our emergency Department for acute intestinal obstruction and appearance of abdominal wall swelling in right periumbilical region. He underwent abdominal US with Aplio Nine device (Esaote Biomedica Genova) equipped with a 7-15 MHz linear probe and a 5-8 MHz convex probe. The US was performed by an operator with twenty years of experience. US scans of the abdomen, scrotum, left inguinal canal, and abdominal wall were performed. The abdominal wall examination revealed: a 5,8 mm hernia breach (Fig. 2) containing a sac with colon loop, adipose tissue, fluid collection and a 10 mm round homogeneous mass (testicle) (Fig. 3) (Video). The incarcerated intestine had a wall thickness of 8 mm and caliber of 22 mm. Subsequently, US scans of the scrotum and left inguinal canal they highlighted absence of left testicle. Abdominal cavity US were



**Fig. 1 – Spigelian hernia.** Diagram showing the anatomical relationships of the main structures involved in this pathology.



**Fig. 2 – Abdominal wall ultrasound.** In this scan the width of the hernia breach (D) (long arrow) were measured. Fluid collection (short arrow). Ileal dilatation upstream of the hernia (arrow heads). Abdominal cavity (AC).



**Fig. 3 – Abdominal wall ultrasound.** The scan performed with linear probe in the abdominal wall swelling highlighted a breach of abdominal wall with colon (long arrows) and testicle (short arrow) involvement. Intestinal fluid (IL). Intestinal caliper (C). Abdominal Cavity (AC).

performed which did not reveal any pathologies. The patient then underwent emergency surgery which confirmed the US data. Hernioplexy and testicle repositioning in the scrotal sac was performed. After surgery, the intestinal obstruction has resolved without complications.

---

## Discussion

Acute intestinal obstruction is a pediatric emergency and therefore requires rapid diagnosis and treatment to avoid serious complications, especially in newborns. The pathologies that can cause acute intestinal obstruction in newborns are most frequently: intussusception, inguinal hernia or abdominal wall hernia (periumbilical, umbilical, spigelian). The US examination must therefore include the study of the abdominal cavity, inguinal canal and of abdominal wall. The appearance of the abdominal swelling in newborns is an element that facilitates the diagnosis of Spigelian hernia, but the absence of this sign does not exclude it therefore it is always necessary to carefully examine the entire abdominal wall with linear probe in search of the hernia breach. The swelling of the abdominal wall is typically located laterally and below to the navel, along the semilunar line and is usually very painful on palpation. As with all neonatal intestinal obstructions, diagnosis and treatment must be timely to avoid serious complications such as intestinal perforation or intestinal necrosis. Among the serious complications of SCS, in addition to ischemia of the incarcerated intestinal loop, there may be ischemia and/or necrosis of the incarcerated testicle and this occurs especially when the hernial breach is very narrow, causing significant testicular vessels stenosis; in this case it is necessary to evaluate the US testicle appearance also carrying out a comparative study with the contralateral testicle, as is generally done in testicular torsion. When the incarcerated testicle appears increased in volume and inhomogeneous compared to the contralateral one, this may be a sign of ischemic suffering and/or necrosis. In this case, in addition to hernioplexy, orchipexy may be necessary. The choice of the most suitable instrumental method must always take into consideration the age and risks associated with ionizing radiation administration, therefore the use of second level methods must be very limited only to selected cases for which MRI examination is preferable. US is the first level exam, it is highly sensitive, rapid, available, repeatable and well tolerated by patients [13]; it allows us to easily highlight abdominal wall hernias, measure the hernia breach diameter, identify the sac contents, detect the “Bulb-Like” sign (when a hyperechoic layer of mesenteric fat is visible within the incarcerated intestinal loop, while fluid is visible around, this multilayered appearance resembles a “bulb-like” sign) [14]. US also allows you to identify the undescended testicle and any signs of ischemia or necrosis. US also allows us to highlight signs relating to the intestinal obstruction degree such as the upstream intestinal loops dilatation, the mobility absence of incarcerated loop and thickness increase of intestinal wall. In males, the finding of rounded mass inside the hernia must lead to combination with cryptorchidism, in which case it is necessary to extend the US study to the scrotal sac and the ipsilat-

eral inguinal canal to verify the testicle absence. The US examination must however be extended to the abdominal cavity as it cannot exclude other concomitant causes of intestinal obstruction such as intussusception. After diagnosis, treatment must be timely and surgical, with hernioplexy and repositioning of the testicle into the scrotal cavity, or orchipexy, when the testicle shows clear signs of ischemic suffering or necrosis [15].

---

## Author contributions

RF Study design/planning collected data, preparation of manuscript, data analysis/statistics, data interpretation and involved in project development, literature analysis/search MP, CD, PVF, MD, CI, CM, SG, AG, MC, and AI collected data, wrote the manuscript, literature analysis/search. RF, SL, and AB: wrote the manuscript.

---

## Patient consent

The consent was obtained from the patient for the publication of this case report and accompanying images.

---

## Supplementary materials

Supplementary material associated with this article can be found, in the online version, at [doi:10.1016/j.radcr.2024.04.080](https://doi.org/10.1016/j.radcr.2024.04.080).

---

## REFERENCES

- [1] Jones BC, Hutson JM. The syndrome of Spigelian hernia and cryptorchidism: a review of paediatric literature. *J Pediatr Surg* 2015;50(2):325–30. doi:10.1016/j.jpedsurg.2014.10.059.
- [2] Mittal T, Kumar V, Khullar R, et al. Diagnosis and management of Spigelian hernia: a review of literature and our experience. *J Minim Access Surg* 2008;4:95–8. doi:10.4103/0972-9941.45204.
- [3] Sanae A, Kaoutar I, Hind S, et al. Complicated abdominal wall hernia mimicking an abdominal wall abscess: a case report. *Radiol Case Rep* 2021;16(6):1451–3. doi:10.1016/j.radcr.2021.03.037.
- [4] Durham MM, Ricketts RR. Congenital spigelian hernias and cryptorchidism. *J Pediatr Surg* 2006;41:1814–17. doi:10.1016/j.jpedsurg.2006.06.043.
- [5] Levy G, Nagar H, Blachar A, et al. Pre-operative sonographic diagnosis of incarcerated neonatal spigelian hernia containing the testis. *Pediatr Radiol* 2003;33:407–9. doi:10.1007/s00247-003-0879-8.
- [6] Johnson KN, Criss CN, Hirschl RB, et al. Ultrasound-guided pediatric inguinal hernia repair. *J Pediatr Surg* 2021;56(7):1240–5. doi:10.1016/j.jpedsurg.2021.02.053.
- [7] Patoulas I, Koutsogiannis E, Panopoulos I, et al. Hydrocele in pediatric population. *Acta Medica (Hradec Kralove)* 2020;63(2):57–62. doi:10.14712/18059694.2020.17.
- [8] Fahim M, Oyewole B, Heatley N, et al. Walthard cyst of spermatic cord in the right inguinal hernia. *BMJ Case Rep* 2022;15(6):e247963. doi:10.1136/bcr-2021-247963.

- [9] Tasian GE, Copp HL. Diagnostic performance of ultrasound in nonpalpable cryptorchidism: a systematic review and meta-analysis. *Pediatrics* 2011;127(1):119–28. doi:[10.1542/peds.2010-1800](https://doi.org/10.1542/peds.2010-1800).
- [10] Raveenthiran V. Congenital Spigelian hernia with cryptorchidism: probably a new syndrome. *Hernia* 2005;9(4):378–80. doi:[10.1007/s10029-005-0316-z](https://doi.org/10.1007/s10029-005-0316-z).
- [11] Parihar D, Kadian YS, Raikwar P, et al. Congenital spigelian hernia and cryptorchidism: another case of new syndrome. *APSP J Case Rep* 2013;4(3):41.
- [12] Adil ML, Alvi M, Shabbir A, et al. An unusual presentation of cryptorchidism: a case report of Spigelian-cryptorchidism syndrome. *Int J Surg Case Rep* 2023;107:108350. doi:[10.1016/j.ijscr.2023.108350](https://doi.org/10.1016/j.ijscr.2023.108350).
- [13] Shaahinfar A, Ghazi-Askar ZM. Procedural applications of point-of-care ultrasound in pediatric emergency medicine. *Emerg Med Clin North Am* 2021;39(3):529–54. doi:[10.1016/j.emc.2021.04.006](https://doi.org/10.1016/j.emc.2021.04.006).
- [14] Cesaro E, Rocco C, Rosano N, et al. Bulb-like" sign: small bowel closed loop obstruction in incarcerated Spigelian hernia. *Radiol Case Rep* 2020;16(3):520–3. doi:[10.1016/j.radcr.2020.12.038](https://doi.org/10.1016/j.radcr.2020.12.038).
- [15] Bilici S, Güneş M, Göksu M, et al. Undescended testis accompanying congenital spigelian hernia: is it a reason, a result, or a new syndrome? *Eur J Pediatr Surg* 2012;22(02):157–61. doi:[10.1055/s-0032-1308702](https://doi.org/10.1055/s-0032-1308702).