

Case for diagnosis*

Rogério Nabor Kondo¹

Rubens Pontello Júnior²

Ricardo Pontello³

Jefferson Crespigio⁴

DOI: <http://dx.doi.org/10.1590/abd1806-4841.20142614>

CASE REPORT

A 55-year-old female, who had had a kidney transplant 3 years ago and from then on, had been taking prednisone, tacrolimus and azathioprine with initial doses of 60, 150, and 2 mg/day, respectively. These doses had been reduced and she is currently taking 10 mg prednisone, 100 mg azathioprine, and 1 mg tacrolimus daily. Two months ago while using the same drug doses she presented asymptomatic lesions on the dorsum of her left hand without a history of local trauma.

Dermatological examination revealed a violet erythematous nodule and 2 other erythematous exulcerated papules on the dorsum of the left hand (Figure 1).

An excisional biopsy of the nodule was performed for diagnosis. Histopathology showed chronic granulomatous inflammation and the presence of dark wall yeast structures compatible with dematiaceous fungus (Figure 2).

The other two lesions were also removed and the wound was closed with a double advancement flap (Figure 3).

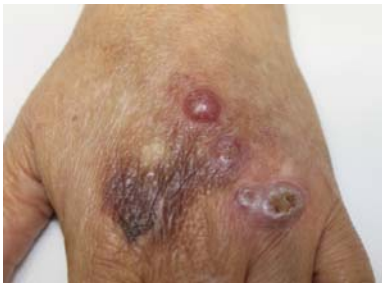

FIGURE 1: Violet Erythematous nodule and 2 other exulcerated erythematous papules on the back of the left hand

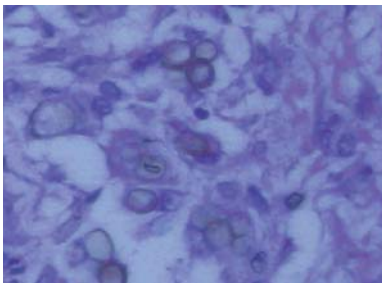


FIGURE 2: The presence of brownish stained yeast-like organisms

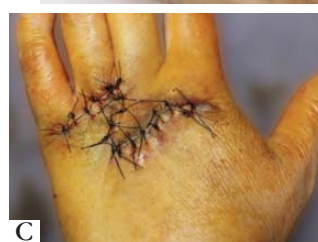
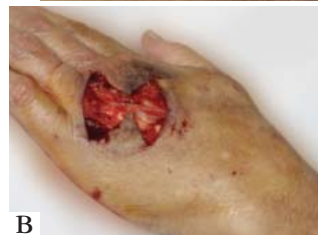
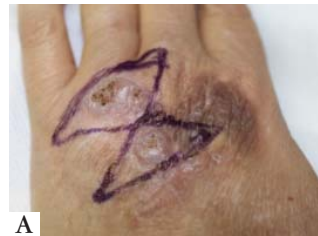FIGURE 3: A - Marking lesion to be removed. B - Removal of injuries and surgical defects caused. C - Flap positioned

Received on 13.03.2013.

Approved by the Advisory Board and accepted for publication on 15.05.2013.

* Work performed at the Dermatology Service, of North Paraná Regional University, Londrina State University (HURNP-UEL) – Londrina, PR, Brazil

Conflict of interest: None
Financial funding: None

¹ Assistant Professor of Dermatology, North Paraná Regional University, Londrina State University (HURNP-UEL) – Londrina, PR, Brazil.

² Doctor dermatologist, studying Masters in Experimental Pathology at Londrina State University (UEL). Assistant professor, Disciple of Dermatology, Medicine Course at Londrina State University (UEL) – Londrina, PR, Brazil.

³ Resident in Dermatology at the Hospital Federal de Bonsucesso (HFB) – Rio de Janeiro (RJ), Brazil

⁴ Doctor Pathologist – Private Laboratory – Londrina, PR, Brazil.

DISCUSSION

Phaeohyphomycosis was diagnosed based on clinical and histopathological findings.

The term Phaeohyphomycosis (PHM) was coined in 1974 by Ajello et al. to designate all cutaneous, subcutaneous, and systemic fungal infections which may be present in a host in any combination in the form of dark wall hyphae or pseudohyphae, hence dematiaceous fungus.^{1,2}

Current prevalence is unknown, but in recent years the number of cases has increased in immunosuppressed patients: chemotherapy, diabetes, and AIDS patients, and in transplant patients treated with immunosuppressive drugs, such as corticosteroids.³⁻⁷ However, it can also occur in immunocompetent individuals.²

It can take the following clinical forms: superficial, subcutaneous, allergic, and invasive or systemic. Subcutaneous PHM is the most common presenting with subcutaneous nodules or cysts without systemic symptoms, preferentially located in the extremities, associated with a history of trauma, and in both immunosuppressed and non-immunosuppressed patients.¹⁻⁸

This case was one of subcutaneous PHM where diagnosis was made by clinic examination and histopathology. Dematiaceous fungal elements were seen indicating deep mycosis caused by a pigment-producing agent (Figure 2). Direct mycology exam and lesion cultures (surgical samples from this case) were negative and we were unable to identify the causal fungus.

A history of trauma cannot always be seen in PHM, as in this case. There is doubt whether fungi are latent in the host and only develop into lesions when there is a reduction in immunity, as mentioned by Cunha Filho RR et al.⁹

Differential diagnosis for subcutaneous PHM include: lipomas, epidermal cysts, fibroids, foreign body granuloma, bacterial abscesses, and squamous cell carcinoma.^{1,2} In this case, we added the hypothesis of amelanotic melanoma and cutaneous histiocytic sarcoma.

The treatment of choice for localized PHM is complete surgical lesion resection. The lesions were removed and the wound closed with a double advancement flap. Associated to surgical management, as recommended by Ferreira LM et al, 200 mg/day of itraconazole was prescribed for 6 months, without any evidence of recurrence until now.⁶ □

Abstract: Subcutaneous phaeohyphomycosis is an infection caused by dematiaceous fungi which mainly affects immunosuppressed patients. We report a case of subcutaneous phaeohyphomycosis on the back of the left hand in a kidney transplant patient who had been taking prednisone, tacrolimus, and azathioprine daily for 3 years.

Keywords: Dermatofungaloses; Immunosuppression; Kidney transplant; Mycoses

REFERENCES

1. Lacaz CS, Porto E, Martins JEC, Hiens-Vaccari EM, Melo NT. Feo-hifomicose. In: Lacaz CS. Tratado de Micologia Médica. 9. ed. São Paulo: Sarvier; 2002. p.520-61.
2. Reis CMS, Schechtman RC, DR Azulay. Micoses subcutâneas. In: Azulay RD, Azulay DR, Azulay-Abulafia L. Dermatologia. 5. ed. Rio de Janeiro: Guanabara Koogan; 2011.p.445-6.
3. Geyer AS, Fox LP, Husain S, Della-Latta P, Grossman ME. Acremonium mycetoma in a heart transplant recipient. J Am Acad Dermatol. 2006;55:1095-100.
4. McCown HF, Sahn EE. Subcutaneous phaeohyphomycosis and nocardiosis in a kidney transplant patient. J Am Acad Dermatol. 1997;36:863-6.
5. Patel U, Chu J, Patel R, Meehan S. Subcutaneous dematiaceous fungal infection. Dermatol Online J. 2011;17:19.
6. Ferreira LM, Pereira RN, Diniz LM, Souza Filho JB. Caso para diagnóstico. Feo-hifomicose. An Bras Dermatol. 2006;81:291-3.
7. Rossetto AL, Dellatorre G, Pérsio RA, Romeiro JC, Cruz RC. Subcutaneous phaeohyphomycosis on the scrotum caused by Exophiala jeanselmei: case report. An Bras Dermatol. 2010;85:517-20.
8. Fernandes NC, Nacif D, Akiti T, Cuzzi T. Feohifomicose subcutânea causada por Cladophialophora sp.: relato de caso. Rev Inst Med Trop Sao Paulo. 2007;49:109-12.
9. Cunha Filho RR, Schwartz J, Rehn M, Vettotato G, Resende MA. Feo-hifomicose causada por Veronaea bothryosa: relato de dois casos. An Bras Dermatol. 2005;80:45-8.

MAILING ADDRESS:

Rogério Nabor Kondo
Rua Paes Leme, 1186
Jardim Ipiranga
86010-610 Londrina, PR, Brazil
Email: rkondo@onda.com.br

How to cite this article: Kondo RN, Pontello R Jr, Pontello R, Crespigio J. Case for diagnosis. Subcutaneous phaeohyphomycosis. An Bras Dermatol. 2014;89(1):169-70.