



## Delayed manifestation of proliferative retinopathy associated with chronic myeloid leukemia

Alan Chew Bonilla<sup>\*</sup>, Paulina Bueno Zarazúa, Jaime Rosales Padron, Emiliano Fulda Graue, Federico Graue Wiechers

Retina Department, Institute of Ophthalmology Fundación Conde de Valenciana, Chimalpopoca 14, Colonia Obrera, Mexico City, 06800, Mexico

### ARTICLE INFO

#### Keywords:

Chronic myeloid leukemia  
Late-onset proliferative retinopathy

### ABSTRACT

**Purpose:** This report highlights a rare case of delayed manifestation of proliferative retinopathy associated with chronic myeloid leukemia (CML) during remission.

**Observations:** Case report and review of the literature; In this case report, we outline the delayed manifestation and clinical progression of proliferative retinopathy in a 52-year-old male patient with a history of CML diagnosed in 2001. Initially, the patient presented with a white blood cell count (WBC) of 402,200/ $\mu$ l, and the leukocytosis persisted until 2005. Thereafter, the patient remained in remission for over 15 years without any visual complaints until 2022. At that time, the patient sought medical attention due to a ten-day history of left eye visual impairment, leading to the discovery of peripheral neovascularization in both eyes and vitreous hemorrhage in the left eye during fundus examination. The WBC count at the time of presentation to the Emergency Department was 10,460/ $\mu$ l. The patient was treated with fluorescein angiography guided panretinal photocoagulation to the areas of ischemic retina. Subsequent follow-up after eight months demonstrated regression of neovascularization.

**Conclusions and Importance:** Our findings highlight the occurrence of proliferative retinopathy in the context of CML, uniquely manifesting during remission. This case emphasizes the importance of ophthalmological assessments not only at the time of CML diagnosis but also during subsequent follow-ups, recognizing the potential for delayed presentation of ocular complications.

### 1. Introduction

Chronic myeloid leukemia (CML) is a myeloproliferative disorder affecting hematopoietic stem cells, driven by the reciprocal translocation t(9;22)(q34;q11), resulting in the oncogene BCR-ABL1 (Philadelphia chromosome). This aberration codes for an abnormal constitutively active tyrosine kinase.<sup>1</sup>

CML primarily affects hematopoietic stem cells, with repercussions that extend beyond the hematopoietic system, revealing distinctive ocular manifestations. Ocular involvement in patients with leukemia is observed in up to 50% of cases and typically manifests during the stages of leukocytosis.<sup>2</sup> Proliferative retinopathy associated with CML, first described by Duke et al., in 1968, is characterized by hyperviscosity, which leads to peripheral nonperfusion, ischemia, and the formation of retinal neovascularization with a staghorn pattern.<sup>3</sup> However, the majority of patients with CML exhibit nonproliferative retinopathy.

While few cases of proliferative retinopathy due to CML are reported, even fewer occur in the absence of hyperviscosity. Nobacht et al. reported a similar case in which peripheral retinal neovascularization was incidentally identified two years after leukocytosis in a patient with CML.<sup>4</sup>

Diabetes is the most common cause of proliferative retinopathy; nondiabetic proliferative retinopathy can be seen with ocular conditions including retinal vein occlusion, retinal vasculitis, familial exudative vitreoretinopathy, retinopathy of prematurity, as well as systemic conditions including sickle cell disease, hypertension, carotid stenosis, sarcoidosis, and systemic vasculitis. Proliferative retinopathy can also be seen as a complication of radiation retinopathy.<sup>5</sup>

### 2. Case report

A 52-year-old male arrived at the emergency room with a 10-day

<sup>\*</sup> Corresponding author. Chimalpopoca 14, Colonia Obrera, Mexico City, 06800, Mexico.

E-mail address: [alanchewbonilla@gmail.com](mailto:alanchewbonilla@gmail.com) (A. Chew Bonilla).

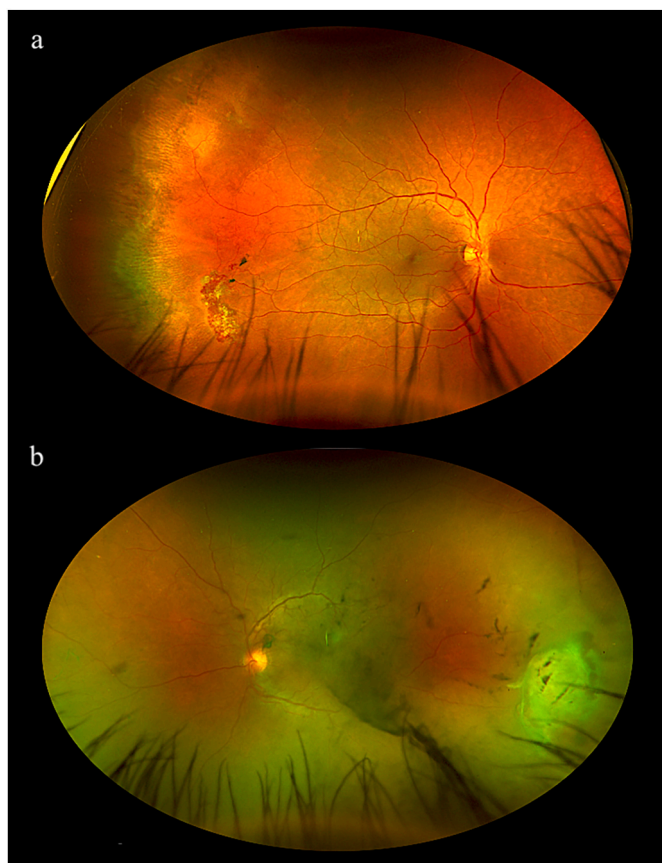history of visual loss of the left eye (OS). He was diagnosed with CML (BCR/ABL positive) in 2001 and has been previously treated with hydroxyurea and multiple tyrosine kinase inhibitors. He was currently on nilotinib treatment and has been in remission for more than 15 years. At the time of initial diagnosis in 2001, the patient originally presented a white blood cell count of 402,200/ $\mu\text{l}$ , with leukocytosis persisting until 2005 when a count of 10,250/ $\mu\text{l}$  was reported. The WBC count obtained in the Emergency Department the day that ophthalmology diagnosed the proliferative disease was 10,460/ $\mu\text{l}$ .

The best corrected visual acuity was 20/20 in the right eye (OD) and 20/70 in OS. Slit lamp examination revealed no alterations in both eyes (OU). Fundus examination of OD revealed peripheral neovascularization (PN) in the temporal quadrant with a staghorn pattern (Fig. 1A), as well as vitreous hemorrhage and PN in OS (Fig. 1B).

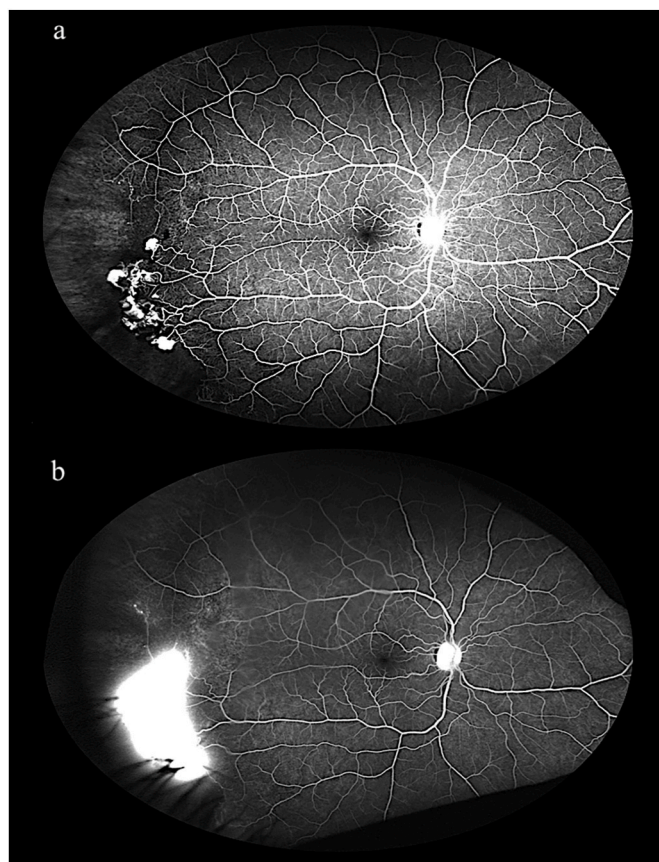
Ultra-wide field fluorescein angiography (FA) showed hyper-fluorescent areas of leakage surrounded by areas of capillary non-perfusion in OD (Fig. 2A and B). In OS, diffuse blocking due to vitreous hemorrhage and peripheral changes similar to those described in OD were observed, with larger areas of capillary non-perfusion (Fig. 3A and B). In OU, microaneurysms and abnormal arteriovenous connections were noted.

Screening studies were conducted to rule out other possible causes of proliferative retinopathy. These included a complete blood count, total blood proteins, prothrombin time, activated partial thromboplastin time, HbA1c, rheumatoid factor, serum protein electrophoresis, urine protein electrophoresis, lupus anticoagulant, and carotid Doppler; all results were within normal parameters.

The patient was treated with retinal scatter photocoagulation targeting areas of peripheral ischemia identified on the FA. A follow-up



**Fig. 1.** Ultra-wide field color fundus photographs. A. Peripheral neovascularization at the temporal quadrant with a staghorn pattern in the right eye B. Mild vitreous hemorrhage and peripheral neovascularization at the temporal quadrant in the left eye.



**Fig. 2.** Ultra-wide fluorescein angiography of the right eye. A. Peripheral retinal nonperfusion with sea fan neovascularization. B. Hyperfluorescent areas of leakage.

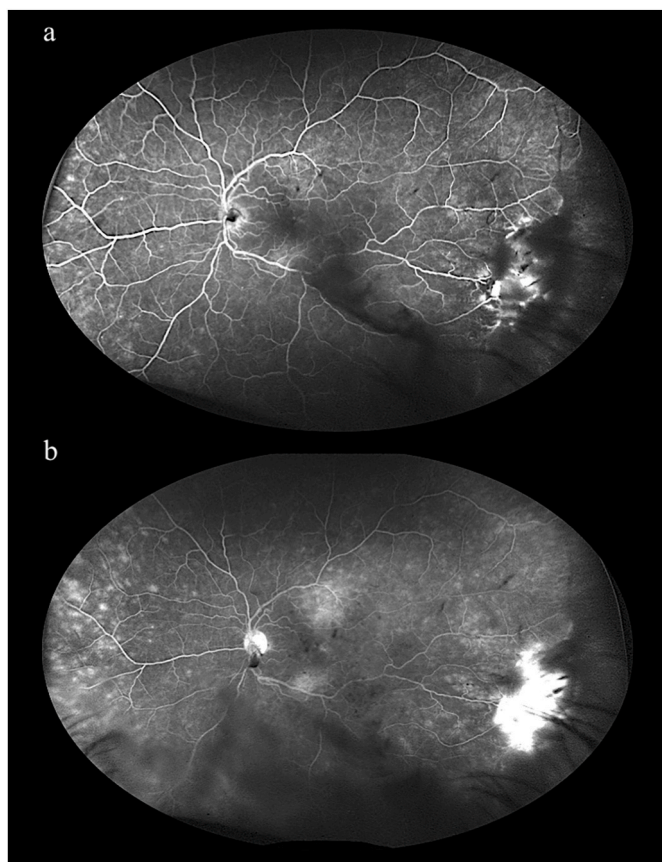
exam with ultra-wide field FA was performed eight months later to assess the regression of neovascularization. During that visit, the patient had a visual acuity of 20/25 in OS (Fig. 4A, B, Fig. 5A, B).

### 3. Discussion

CML has no pathognomonic ocular manifestations; however, leukemic retinopathy is the most common presentation. This can include Roth spots, cotton wool spots, retinal hemorrhages, microaneurysms, dilated and tortuous veins, vascular sheathing, hyperemia of the optic disc and leukemic infiltrates. Another finding is proliferative retinopathy in the periphery with a staghorn pattern.<sup>3,6,7</sup> According to Almeida et al., proliferative retinopathy in the posterior pole is less frequent. Proliferative retinopathy can be severe and evolve to vitreous hemorrhage and tractional retinal detachment.<sup>8</sup> Other possible findings, although less frequent are vitritis, choroidal infiltrates, serous retinal detachment, optic nerve infiltration, and retinal venous occlusion.<sup>9</sup>

There are nine reported cases of proliferative retinopathy due to CML. Retinal neovascularization was located at the periphery in five patients, three in the optic disc, and one had a tractional retinal detachment. The findings were bilateral in all cases, with five patients experiencing vitreous hemorrhage.<sup>4,6-8,10-17</sup> Singer et al. noted a predilection for neovascularization in the temporal region of the peripheral retina, where the distance between perfused and non-perfused retina is greatest.<sup>18</sup> The presence of neovascularization in the temporal peripheral retina in this case is similar to the case published by Nobacht et al.<sup>4</sup>

Authors conducted a literature review of “CML” and “proliferative retinopathy”; the majority of previously reported cases of proliferative retinopathy were identified in CML patients with leukocytosis (WBC range 50,000–699,000/ $\mu\text{l}$ ). Only a single case report of proliferative



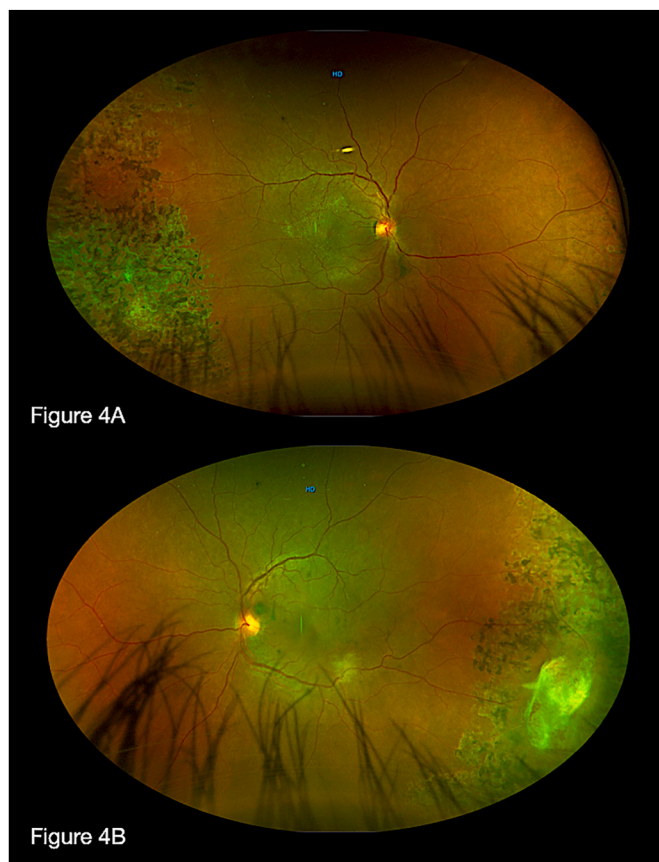**Fig. 3.** Ultra-wide fluorescein angiography of the left eye. **A.** Diffuse hypofluorescence due to vitreous hemorrhage and peripheral retinal nonperfusion with sea fan neovascularization. **B.** Hyperfluorescent areas of leakage.

retinopathy diagnosed in a patient with CML in remission (WBC count = 4400/ $\mu$ l) reported by Nobacht et al. This 24-year old patient was incidentally found to have proliferative retinopathy 2 years following CML remission.<sup>4</sup>

The importance of ultra-wide field images using fluorescein angiography is highlighted in this case for detecting neovascularization and ischemic areas necessary for retinal photocoagulation treatment, since the patient had a 1-week previous fluorescein angiography taken with 55-degree photos, and this retinal neovascularization was not visible.

Regarding ophthalmological treatment, if proliferative retinopathy is present, the treatment is retinal photocoagulation as in the case of our patient.<sup>8</sup> Pars plana vitrectomy will be necessary in case of vitreous hemorrhage that does not resolve, and tractional retinal detachment.<sup>10,11</sup> Antiangiogenic agents are indicated in cases of macular edema or vitreous hemorrhage that hinders the application of photocoagulation which was not present in our case because retinal photocoagulation was possible due a mild vitreous hemorrhage.<sup>19</sup>

All patients diagnosed with leukemia should be referred to an ophthalmologist for a baseline eye exam to screen for retinopathy, which was not the case with our patient. Patients should continue to have periodic eye exams until their leukemia is in remission. Ultra-wide field FA should be performed to evaluate for occult retinal ischemia and/or neovascularization, as these findings may be missed on a dilated fundus exam or conventional 55-degree FA. Although ocular damage does not affect the patient's prognosis,<sup>20</sup> it can impact quality of life due to more severe ophthalmological complications associated with prolonged leukocytosis.<sup>21</sup>



**Fig. 4.** Ultra-wide field color fundus photographs at eight months follow-up. **A.** Peripheral retinal scarring following photocoagulation in the temporal quadrant with no neovascularization evidence in the right eye **B.** Peripheral retinal scarring following photocoagulation in the temporal quadrant with gliosis and no neovascularization in the left eye.

#### 4. Conclusions

Peripheral retinal nonperfusion with retinal neovascularization is identified as a potential complication of CML. In contrast to prior reports, our patient did not manifest a recurrence of myeloid leukemia and did not display other typical retinal signs associated with CML. Instead, bilateral peripheral retinal nonperfusion with sea fan neovascularization was observed. This underscores the importance of ophthalmological examinations at the initial diagnosis and during subsequent follow-up care.

#### Patient consent

Consent to publish the case report was not obtained. This report does not contain any personal information that could lead to the identification of the patient.

#### Acknowledgments and disclosures

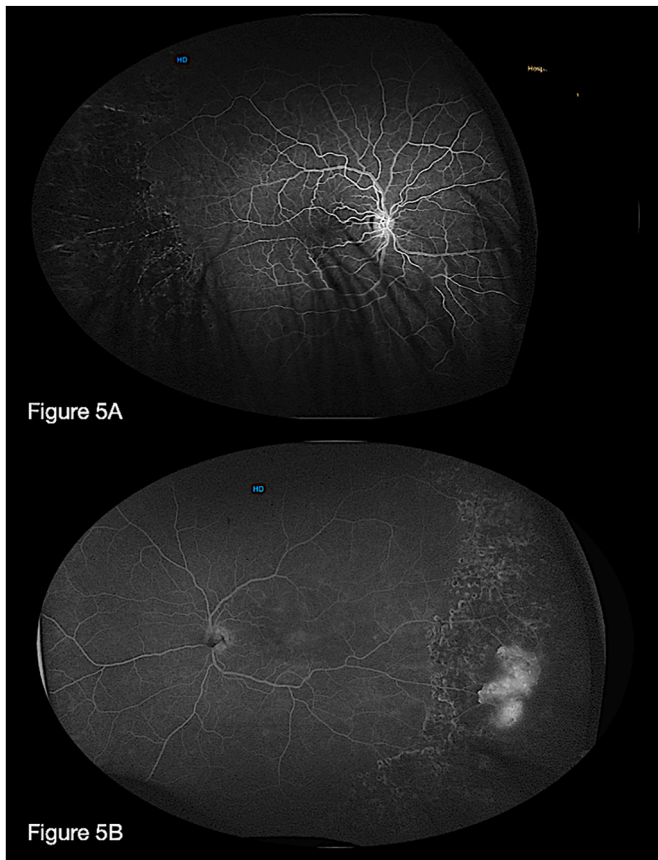
The authors declare no conflict of interest in this article.

#### Funding

No funding or grant support

#### Authorship

All authors attest that they meet the current ICMJE criteria for



**Figure 5.** Ultra-wide field FA at eight months follow-up. **A and B.** Peripheral retinal scarring following photocoagulation in the temporal quadrant with no evidence of leakage due to neovascularization.

#### Authorship.

#### CRediT authorship contribution statement

**Alan Chew Bonilla:** Writing – review & editing, Writing – original draft, Supervision, Investigation, Conceptualization. **Paulina Bueno Zarazúa:** Resources, Investigation. **Jaime Rosales Padron:** Writing – original draft, Data curation. **Emiliano Fulda Graue:** Writing – review & editing. **Federico Graue Wiechers:** Writing – review & editing, Supervision.

#### Declaration of competing interest

The authors declare that they have no known competing financial

interests or personal relationships that could have appeared to influence the work reported in this paper.

The authors have no conflict of interest.

#### Acknowledgements

None.

#### References

1. Sawyers CL. Chronic myeloid leukemia. *N Engl J Med.* 1999;340(17):1330–1340.
2. Schachat AP, Markowitz JA, Guyer DR, Burke PJ, Karp JE, Graham ML. Ophthalmic manifestations of leukemia. *Arch Ophthalmol.* 1989;107(5):697–700.
3. Duke JR, Wilkinson CP, Sigelman S. Retinal microaneurysms in leukaemia. *Br J Ophthalmol.* 1968;52(5):368–374.
4. Nobacht S, Vandoninck KFK, Deutman AF, Klevering BJ. Peripheral retinal nonperfusion associated with chronic myeloid leukemia. *Am J Ophthalmol.* 2003;135(3):404–406.
5. Yanoff M, Duker JS, Retinopathies Proliferative, Mathura JR, Bearely S, Jampo LM. *Ophthalmology.* 2019:575–579.
6. Frank RN, Ryan Jr SJ. Peripheral retinal neovascularization with chronic myelogenous leukemia. *Arch Ophthalmol.* 1972;87(5):585–589.
7. Morse PH, McCready JL. Peripheral retinal neovascularization in chronic myelocytic leukemia. *Am J Ophthalmol.* 1971;72(5):975–978.
8. Almeida DRP, Chin EK, Grant LW. Chronic myelogenous leukemia presenting with bilateral optic disc neovascularization. *Can J Ophthalmol.* 2014;49(3):e68–e70.
9. Goel N, Pangtey B, Thakar M, Raina UK, Gosh B. Chronic myeloid leukemia presenting with bilateral central retinal vein occlusion and massive retinal infiltrates. *J AAPOS.* 2012;16(4):406–408.
10. Mandava N, Costakos D, Bartlett HM. Chronic myelogenous leukemia manifested as bilateral proliferative retinopathy. *Arch Ophthalmol.* 2005;123(4):576–577.
11. Macedo MSF, Figueiredo ARM, Ferreira NN, et al. Bilateral proliferative retinopathy as the initial presentation of chronic myeloid leukemia. *Middle East Afr J Ophthalmol.* 2013;20(4):353–356.
12. Huynh TH, Johnson MW, Hackel RE. Bilateral proliferative retinopathy in chronic myelogenous leukemia. *Retina.* 2007;27(1):124–125.
13. Hasanreisoglu B, Or M, Atmaca LS, Haznedar R. Pars plana vitrectomy in chronic myelogenous leukemia with vitreous hemorrhage. *Jpn J Ophthalmol.* 1988;32(3):304–309.
14. Priya BV, Jain K, Mahendradas P, Shetty BK. “String of beads” appearance on fundus fluorescein angiography as a clinical clue for leukemia-related proliferative retinopathy. *Indian J Ophthalmol.* 2019;67:2049.
15. Chen B, Yan X, Zhang X, Yang H. Leukostasis retinopathy: an uncommon visual threatening complication of chronic myeloid leukemia with severe hyperleukocytosis - a case report and review of the literature. *Indian J Ophthalmol.* 2018;66(12):1871–1874.
16. Awh CC, Miller JB, Wu DM, Elliott D. Leukostasis retinopathy: a new clinical manifestation of chronic myeloid leukemia with severe hyperleukocytosis. *Ophthalmic Surg Laser.* 2015;46(7):768–770.
17. Yassin MA, Ata F, Mohamed SF, et al. Ophthalmologic manifestations as the initial presentation of chronic myeloid leukemia: a review. *Surv Ophthalmol.* 2021;18:48.
18. Singer M, Sagong M, van Hemert J, Kuehlewein L, Bell D, Satta SR. Ultra-widefield imaging of the peripheral retinal vasculature in normal subjects. *Ophthalmology.* 2016;123(5):1053–1059.
19. Narang S, Gupta P, Sharma A, Snood S, Palta A, Goyal S. Bilateral central retinal vein occlusion as presenting feature of chronic myeloid leukemia. *Middle East Afr J Ophthalmol.* 2016;23(3):253–255.
20. Mahneke A, Videbaek A. ON changes in the optic fundus in leukaemia. Aetiology, diagnostic and prognostic role. *Acta Ophthalmol.* 1964;42:201–210.
21. Gokce M, Unal S, Bayrakçı B, Tuncer M. Chronic myeloid leukemia presenting with visual and auditory impairment in an adolescent: an insight to management strategies. *Indian J Hematol Blood Transfus.* 2010;26(3):96–98.