



Contents lists available at ScienceDirect

International Journal of Surgery Case Reports

journal homepage: www.casereports.com

Follicular adenoma in ectopic thyroid. A case-report



Vincenzo Consalvo^{a,b,*}, Gerarda Barbieri^a, Amalia Rosaria Rita Rossetti^a,
Mafalda Romano^a, Rosaria Contieri^a, Salvatore Tramontano^a, Carmela Rescigno^a,
Massimo Infranzi^a, Domenico Lombardi^c

^a Università degli Studi di Salerno, Italy^b Collaborator of Clinique du Parc Montpellier, France^c Hospital of Cava de' Tirreni, Università degli studi di Salerno, Italy

ARTICLE INFO

Article history:

Received 25 May 2017

Received in revised form

11 September 2017

Accepted 12 September 2017

Available online 14 September 2017

Keywords:

Ectopic thyroid adenoma

Ectopic thyroid management

Aberrant thyroid surgery

ABSTRACT

INTRODUCTION: The term ectopic thyroid refers to the presence of thyroid tissue located far from its usual anatomic placement and with no vascular connection to the main gland. The presence of swelling in atypical locations is diagnostically differentiated from other pathologies like pleomorphic adenoma or carcinoma, inflammatory lesions like sialadenitis, neurogenic tumors, paraganglioma, fibrolipoma and lymphadenopathies of diverse etiologies.

PRESENTATION OF CASE: Here we present the case of a submandibular ectopic thyroid in a 67 year old woman. She came to our attention for a left submandibular swelling. The anamnesis did not show related pathologies, as well as blood tests. Diagnostic image studies and a FNAC were performed. The mass was surgically removed and histopathology showed a follicular adenoma in the contest of the capsulated lesion. **DISCUSSION:** It is important to not underestimate these types of lesions and proceed with hematocemical, instrumental tests and above all surgery that can eliminate any diagnostic uncertainty and on the whole be therapeutic.

CONCLUSION: It should not be forgotten that ectopic thyroid tissue can be a site for adenoma or papillary carcinoma and thus any watch and wait strategy should be avoided.

© 2017 The Author(s). Published by Elsevier Ltd on behalf of IJS Publishing Group Ltd. This is an open access article under the CC BY-NC-ND license (<http://creativecommons.org/licenses/by-nc-nd/4.0/>).

1. Introduction

The term ectopic thyroid tissue is used to define thyroid tissue that is not located in the usual anterior region of the neck, in the pretracheal space, between the second and third cartilage rings [1]. The presence of thyroid tissue in other areas is characterized by the absence of anatomic and above all vascular connections with the main gland. This condition is referred to as “aberrant thyroid” [1].

In the domain of thyroid dysgenesis, an important distinction must be made with the much more frequent “accessory thyroid” (90% vs 10%), which is related to the presence of excessive thyroid formations that maintain a connection to a normally positioned main gland [1].

Its incidence is of 1 per 300000–400000 and is more frequent in females [2].

According to the dysembryonic theory, the abnormal or aberrant descent of primitive thyroid structures during intrauterine life is the underlying cause of ectopic thyroid, which is therefore a consequence of anomalous cell migration or endoderm cell differentiation [2].

The most common location is the lingual area [3] while other cases of ectopic thyroid have been reported in the esophagus, lungs, adrenal gland, pancreas, gallbladder, ovary (struma ovarii) and heart (struma cordis) [4].

Depending on placement, thyroid ectopies are currently classified as:

- medial ectopies
- lateral ectopies
- mixed ectopies

A) Medial ectopies – lingual thyroid: (the most common type, about 90% of all ectopies); – ectopies caused by persistent thyroglossal duct residues (which can be divided in suprahyoid or sublingual, intrahyoid or juxtahyoid ectopies); – intrathyroid (in the trachea), mediastinal (true mediastinal goitre) and endotracheal (heart, pericardium and diaphragm) ectopies;

B) Lateral ectopies (lateral cervical). Divided in parajugular, paracarotid and submandibular;

* Corresponding author at: Università degli Studi di Salerno, Italy.

E-mail addresses: vincenzoconsalvo@hotmail.it (V. Consalvo),

barbieri.dina@gmail.com (G. Barbieri), amaliarosariarita.rossetti@gmail.com

(A.R.R. Rossetti), mafalda_romano@hotmail.it (M. Romano), rosycontieri@hotmail.it

(R. Contieri), salvytra@libero.it (S. Tramontano), rescignocarmela@libero.it

(C. Rescigno), massimo.infranzi@sangiovannieruggi.it (M. Infranzi),

dlombardi@unisa.it (D. Lombardi).

C) Mixed ectopies. The rare cases of so-called “dual ectopy” (24 cases in medical literature, of which only 1 with no ectopic thyroid) and “scattered thyroid” (multiple sites of thyroid parenchyma dispersed in the prethyroid muscles on the medial cervical fascia, in parajugular location and with no lymph nodal involvement) [8].

Ectopic thyroid tissue can suffer from colloid cystic dysplastic degeneration phenomena that are not histologically distinguishable from similar processes in a normal thyroid. Primordial neoplastic forms have a 2–3% influence on the ectopic mass and are seen in 80% of papillary carcinoma cases [5]. In most cases the symptoms are related to a form of hypothyroidism, hyperfunction syndromes are rarely observed [6]. Some patients can present coughing, dysphagia, dyspnea, screeching and dysphonia linked to the compression of adjacent structures [7].

Ectopic thyroid diagnosis is based on clinical, laboratory and instrumental tests. Every clinician must evaluate, depending on the patient's symptoms, whether he or she suffers from hyper or hypo thyroidism, the exams will confirm the case. Instrumental tests (diagnostic sonography, TC, MRI) are required for topographic and morphologic studies of the ectopic thyroid.

The Fnac, especially in thyroglossal duct cysts, leads to a diagnosis in less than 50% of the cases (needle aspiration hypocellularity, degenerative parietal phenomena, dilution with cystic liquid and blood) [8]. Scintigraphy is still the main exam when studying thyroid dysgenesis as it can reveal direct information regarding the location and functionality of the tissue, (limitation by incidence of false negatives due to the lack of tracer detection from the ectopic tissue, which is reduced by the presence of a normally functioning gland) [9].

Surgery can also be effective for asymptomatic patients in light of the possible onset of compressive phenomena, possible hemorrhages, degenerative neoplastic phenomena. Depending on the placement of the ectopy, strategies and means of access may vary [9].

We propose a scientific approach to similar ectopic thyroid cases.

2. Ethical and administrative informations

The patients gave her consent to the publication of scientific data. The author's declare there will not be any communication to third part for the respect of her privacy.

This study was written respecting the ethical principles for medical research involving human subjects (declaration of Helsinki). This article was written according to SCARE 2016 guidelines [14] on case-report writing. Since other few cases have been reported, it was not necessary to publish on a public registry.

2.1. Patient informations

M.A.M. a 67 year old female patient under our observation displayed left submandibular swelling and a light pain perception below the lump, no other symptoms were reported. The patient reported an history of rising swelling who started about 12 months before the first consultation with the general practitioner. The anamnesis did not show related pathologies, arterial hypertension or medicine allergies. Alterations to her general condition, abnormal weight loss, dysphonia, coughing o hyperthermia were not detected. The swelling and gradual asymptomatic growth had been noticed by the patient a few months before.

During physical examination it was possible to feel a bulky mass under the left mandibular arcade, in proximity of the submandibular gland. All laboratory test were normal and also thyroid values.

Diagnostic sonography showed a normally sized and placed thyroid with intact morphology, glandular parenchyma characterized

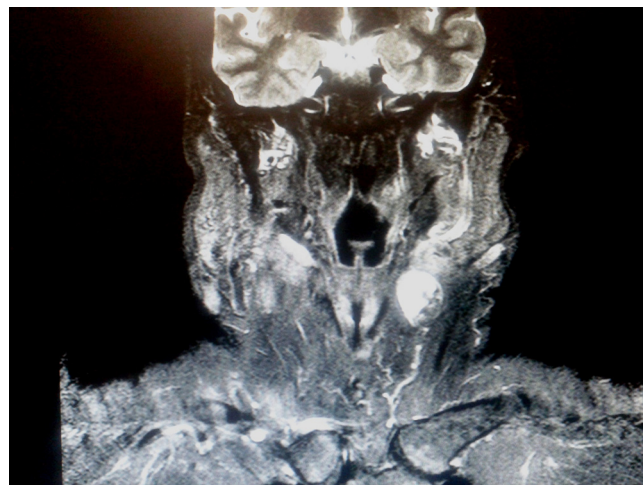


Fig. 1. Neck MRI frontal projection.

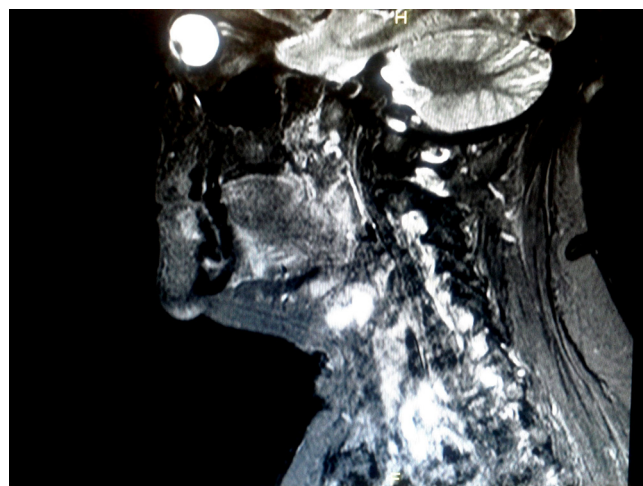


Fig. 2. Neck MRI lateral projection.

by an irregular structural pattern, intact echogenicity, visible minor fibrotic phenomena and two nodular 12 mm and 6 mm nodular formations on the right lobe.

A vascularized, iso hypo-echoic, 28,7 × 26,8 mm solid formation with anechoic spaces found behind the left submandibular gland required MRI evaluation exams. No scintigraphy was performed.

The above-mentioned swelling was therefore examined with a neck MRI, which detected an oval formation (25 × 19 × 23 mm diam.) with irregular T1 signal caused by the presence of a slightly hyperintense central area that increased in intensity in T2 and peripheral zone signal tissue which was not clearly dissociable from the submandibular gland (Figs. 1 and 2,). These findings were attributable to a prestyloid space formation (exophytic pleomorphic adenoma, neurogenic, lymphadenopathy) that required FNAC tests.

The FNAC test report described a normally placed and slightly undersized thyroid with irregular signal and lateral cervical lymph nodal reactive micronodulations. The final histological report described a thyroid parenchyma with nodular structure and evident capsule composed of follicles of varying dimensions with regular epithelial covering tissue. Hemorrhage areas and cholesterol crystals were observable in the stroma, which is compatible evidence with the clinical picture of follicular adenoma.

2.2. Intervention

Based on the solid swelling differential diagnosis, we decided to surgically remove the mass. The patient was operated under general anesthesia, with a left submandibular incision of 5 cm. It was not necessary to pay particular attention to blood vessels and nerves because the mass capsulated and superficial. For the same reason we didn't use any nuclear medicine test in order to identify the nodule. The neoformation was completely excised and we suspected a possible parotid origin because of the consistency and placement. The post-operative was uneventful. Only anti-inflammatory drugs were prescribed. No drug reaction were detected and no reinterventions were required. The patient was discharged one day after the surgical intervention.

2.3. Follow-up

The follow-up was specially designed for this patient. Ambulatory consultations were programmed at 1 week, 2, 4, 8, 12 weeks after the interventions. The symptoms were completely remised after 1 week and didn't show up again.

3. Discussion

The presence of ectopic thyroid tissue is rarely observed and often an accidental event [10]. The semiologic challenge for the clinician is to distinguish it from different forms of swelling related to other pathologies: pleomorphic adenoma or carcinoma, inflammatory lesions like sialadenitis, neurogenic tumors, paraganglioma, fibrolipoma and lymphadenopathies of diverse etiologies [11]. In these cases, in addition to clinical tests, instrumental exams like diagnostic sonography, FNAC, TC and the gold standard Technetium-99m scintigraphy become important. We would like also like to add surgery, that can reduce case duration and diagnostic uncertainties which can be eliminated in the consequent histological exam. Moreover, one must add that surgery can be effective when treating pathologies like adenoma or papillary carcinoma hidden in sites of ectopic thyroid. Other cases of submandibular ectopic thyroid have been described [13] and furthermore Kanaya et al. [12] have reported the case of an ectopic thyroid tissue adenoma in a 53 year old woman who had been operated for total thyroidectomy thirty years before.

4. Conclusions

It is of fundamental importance to always consider the possibility of ectopic or dystopic thyroid in order to avoid the postponement of surgery, which can be delayed and consequently more aggressive.

Limit of the study

We want to underline that this is only a case report of a rare pathology and for this reason, conclusion couldn't be definitive. It would be necessary to analyze a wider pool of studies (observational or randomized controlled trial) in order to have definitive data concerning this pathology management.

Conflicts of interest

None.

Open Access

This article is published Open Access at sciedirect.com. It is distributed under the [IJSCR Supplemental terms and conditions](#), which permits unrestricted non commercial use, distribution, and reproduction in any medium, provided the original authors and source are credited.

Funding source

None.

Ethical approval

Not necessary.

Consent

Yes, patient gave and signed her consent to scientific publication

Author contribution

Consalvo Vincenzo (corresponding author) Wrote the article
 Barbieri Gerarda = reviewed bibliography
 Rossetti Amalia Rosaria Rita = data collection
 Romano Mafalda = data collection
 Contieri Rosaria = data analysis
 Tramontano Salvatore = follow-up of patient
 Infranzi Massimo = study design
 Rescigno Carmela = data collection
 Lombardi Domenico = Performed surgical interventions

Guarantor

Vincenzo Consalvo

References

- [1] J. Besik, O. Szarszoi, A. Bartonova, et al., Intracardiac ectopic thyroid (struma cordis), *J. Card. Surg.* 29 (2014) 155–158.
- [2] N. Ghanem, T. Bley, C. Althoefer, et al., Ectopic thyroid gland in the porta hepatis and lingua, *Thyroid* 13 (2003) 503–507.
- [3] M.P. Abdallah-Matta, P.H. Dubarry, J.J. Pessey, P. Caron, Lingual thyroid and hyperthyroidism: a new case and review of the literature, *J. Endocrinol. Invest.* 25 (3) (2002) 264–267.
- [4] G. Noussios, P. Anagnostis, D.G. Goulis, et al., Ectopic thyroid tissue: anatomical, clinical, and surgical implications of a rare entity, *Eur. J. Endocrinol.* 165 (2011) 375–382.
- [5] V. Mondin, et al., Thyroglossal duct cyst: personal experience and literature review, *Auris Nasus Larynx* 35 (2008) 11–25.
- [6] F.M. Cunha, E. Rodrigues, J. Oliveira, A. Saavedra, L.S. Vinhas, D. Carvalho, Graves' disease in a mediastinal mass presenting after total thyroidectomy for nontoxic multinodular goiter: a case report, *J. Med. Case Rep.* 10 (1) (2016) (article 878).
- [7] M. Salvatori, V. Rufini, S.M. Corsello, et al., Thyrotoxicosis due to ectopic retrotracheal adenoma treated with radioiodine, *J. Nucl. Biol. Med.* 37 (2) (1993) 69–72.
- [8] M. De Falco, G. Oliva, G. Santangelo, S. Del Giudice, U. Parmeggiani L'ectopia tiroidea: problemi di diagnosi e terapia.
- [9] A. Gandhi, K. K.Wong, M.D. Gross, A.M. Avram, Lingual thyroid ectopia: diagnostic SPECT/CT imaging and radioactive iodine treatment, *Thyroid* 26 (4) (2016) 573–579.
- [10] M. Bongiovanni, S. Suriano, F. Fasolini, L. Giovannella Storia clinica tumore tiroide ectopico 7 Maggio 2012 *Tribuna Medica Ticinese* 201 Patologia In Pillole Nr. 71.
- [11] Submandibular ectopic thyroid gland. Zieren J, Paul M, Scharfenberg M, Menenakos C.
- [12] H. Kanaya, Y. Tanigaito, N. Shyono, H. Hirabayashi, K. Baba, A rare case of ectopic, normally functioning thyroid tissue presenting as a left submandibular mass, *Nihon Jibiinkoka Gakkai Kaiho* 108 (2005) 850–853.
- [13] H.A. Amoodi, F. Makki, M. Taylor, J. Trites, M. Bullock, R.D. Hart, Lateral ectopic thyroid goiter with a normally located thyroid, *Thyroid* 20 (2010) 217–220.
- [14] R.A. Agha, A.J. Fowler, A. Saetta, I. Barai, S. Rajmohan, D.P. Orgill, for the SCARE group, the SCARE statement: consensus-based surgical case report guidelines, *Int. J. Surg.* (2016).