

# Prompt Diagnosis and Treatment of Japanese Spotted Fever with an Atypical Triad of Clinical Symptoms: A Case Report

Haoyi Wang\*, Zhen Ni , Yinghao Chang

Department of Infectious Disease, The General Hospital of Western Theater Command, Chengdu, 610083 People's Republic of China

\*These authors contributed equally to this work

Correspondence: Yinghao Chang, Department of Infectious Disease, The General Hospital of Western Theater Command, Chengdu, 610083, People's Republic of China, Email cyh19920913@126.com

**Abstract:** Japanese spotted fever (JSF) is a neglected and potentially fatal infectious disease. Delays in diagnosis and treatment of JSF are important causes of poor prognosis. We report a case of JSF in a 75-year-old farmer who, following autumn field work in Sichuan, China, presented with an atypical triad of clinical symptoms: high fever, petechial rash, and notably no eschar. Without appropriate diagnosis and treatment, she developed septic shock and acute respiratory distress syndrome. The diagnosis of JSF was confirmed by the identification of *Rickettsia japonica* by metagenomic next-generation sequencing (mNGS) of the blood. After one week of treatment with doxycycline, the patient's clinical symptoms subsided without any complaints of discomfort.

**Keywords:** atypical triad of clinical symptoms of Japanese spotted fever, *Rickettsia japonica*, mNGS

## Introduction

Japanese spotted fever (JSF) is a rickettsiosis of the spotted fever group caused by *Rickettsia japonica*, which is transmitted by the bite of arthropods (mainly ticks) and was first diagnosed in Japan in 1984.<sup>1</sup> In recent years, the incidence of tick-borne rickettsioses in China has gradually increased,<sup>2,3</sup> and JSF has shown a tendency to disseminate and its geographic distribution has continued to expand, suggesting that the prevalence of *Rickettsia japonica* in China may be more widespread than previously thought.

JSF is often thought to cause mild symptoms, and with limited knowledge of the epidemiology of JSF and insufficient recognition of potential cases, the incidence and potential lethality may be grossly underestimated, posing a serious risk to human health. High fever, petechial rash, and eschar are the triad of clinical symptoms of JSF,<sup>4</sup> and thrombocytopenia, elevated CRP, and eosinophilia are found in most patients. A retrospective study conducted by the National Institute of Infectious Diseases in Japan showed that,<sup>5</sup> compared to high fever (99%) and rash (94%), eschar (67%) are not universally present, and subsequent studies have been consistent with this finding.<sup>6–8</sup> The lack of evidence of eschar and the limitations of molecular diagnostic techniques in the laboratory usually lead to delays in the diagnosis and treatment of JSF and the development of multiple complications, such as disseminated intravascular coagulation, syndrome, phagocytosis lymphohistiocytosis, and multiorgan failure, which can cause death.<sup>9</sup>

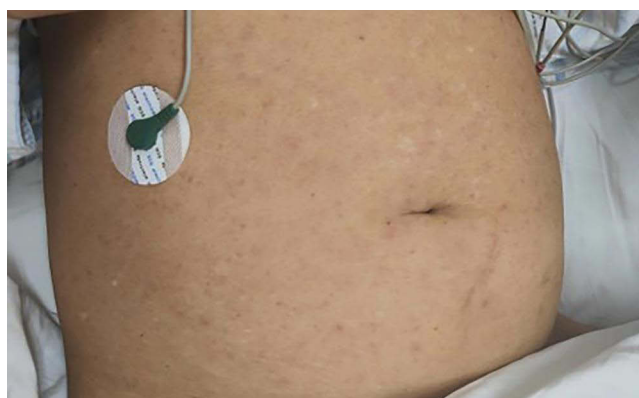This article reports a critical case of Japanese spotted fever in an elderly woman in Sichuan, China, who was misdiagnosed with “pulmonary infection and drug allergy” due to a lack of evidence of eschar and who was promptly diagnosed pathogenetically by metagenomic next-generation sequencing (mNGS), letting her be appropriately treated with doxycycline antibiotics, after which she had no complaints of discomfort.

## Case Report

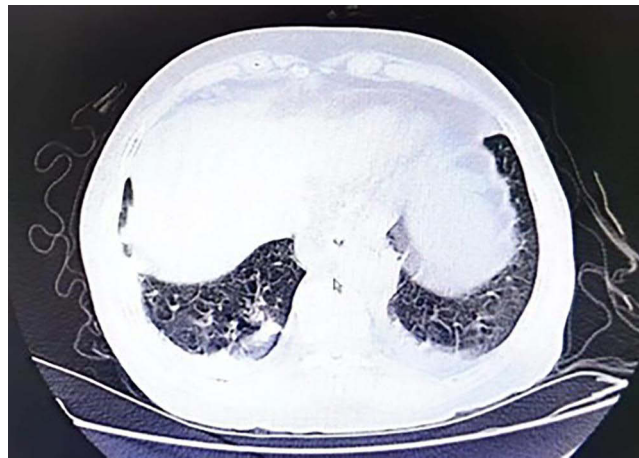A 75-year-old female, Guangyuan, Sichuan Province, with no history of chronic disease, developed fever on August 25, 2023 after working in the field (max temperature 40.5°C), which was restored to normal for a short period of time by antipyretic drugs. Fever was accompanied by dizziness, fatigue, swelling and pain in the forehead, nausea, and vomiting, and it was aggravated by petechial rash and respiratory distress after 2 days. The primary hospital diagnosed the patient with “lung infection and drug allergy”. Blood culture, respiratory throat swabs, and bronchoalveolar lavage fluid from bronchoscopy were negative. She was given (successively, empirically) penicillin, ceftriaxone, meropenem and other anti-infective agents; methylprednisone, which is an anti-inflammatory agent; and other treatments. However, she did not improve and went into shock. The petechial rash spread from her abdomen to her limbs and palms, with more on the abdomen and less on the limbs and palms. The rash was not raised above the skin surface, did not discolor when pressed, did not itch, and was not painful or bleeding. The skin was normal between the petechial rash spots. She denied a history of close contact with pets or poultry or insect bites.

On August 31, she was transferred to the Department of Infectious Diseases of the General Hospital for acute respiratory distress syndrome. Physical examination: body temperature 39.4°C, heart rate 124/min, respiration 26/min, blood pressure 82/50 mmHg, PaO<sub>2</sub> 86%, sequential organ failure assessment (SOFA) score 6. Drowsiness, acute illness, turbidity on percussion in both lower lungs, coarse breath sounds in both lungs, and distinct wet rales were heard. A petechial rash was visible on the abdomen and extremities that did not fade with pressure (Figure 1). She had mild generalized depressed edema, but no eschar.

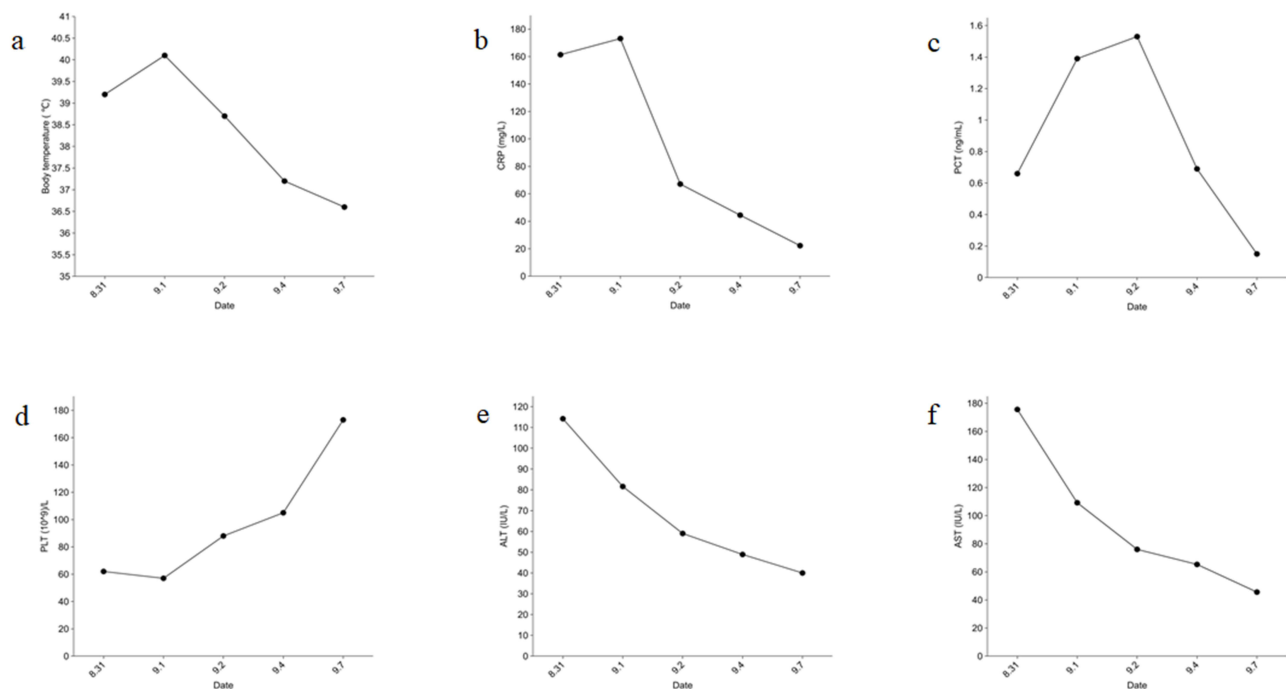
Laboratory analysis revealed a marked increase in C-reactive protein (CRP) (161.35 mg/L), procalcitonin (0.66 ng/mL), alanine transaminase (114.2 IU/L) and aspartate transaminase (175.6 IU/L); a marked decrease in eosinophils (0.00 x10<sup>9</sup>/L) and PLT (62 x10<sup>9</sup>/L); and abnormal WBC (4.90 x10<sup>9</sup>/L), NE (4.27 x10<sup>9</sup>/L), L (0.466 x10<sup>9</sup>/L), IL6 (154.03 pg/mL), IL10 (18.29 pg/mL), ALB (31.2 g/L), and BNP (270.35 pg/mL). A computed tomography (CT) scan of the chest revealed localized thickening and adhesion of the right pleura and a small amount of bilateral pleural effusion (Figure 2). The rest of the laboratory tests were negative, and image examination showed no abnormalities. Atypical pathogenic bacterial infection was suspected. Because of the lack of eschar, her blood was tested by mNGS, and the results of the mNGS on September 2 showed that *Rickettsia japonicum* (genus *Rickettsia* relative abundance 82.7%, sequence 36. species *Rickettsia japonicum*, confidence level 99%, sequence 3). No other disease-causing viruses or bacteria were found in the report. The patient was diagnosed with Japanese spotted fever and treated with doxycycline (first dose 0.2 g, 0.1 g bid po sequential treatment) and antishock treatments. The patient's general condition was good on September 7 (Figure 3 and Table 1). During the follow-up period, the patient did not complain of discomfort, and laboratory tests did not reveal any abnormalities.



**Figure 1** Petechial rash on the abdomen.



**Figure 2** CT revealed localized thickening and adhesion of the right pleura and a small amount of bilateral pleural effusion.



**Figure 3** Body temperature and laboratory indices during hospital stays. (a) The tendency of body temperature (°C) during hospital stays. (b) The tendency of high-sensitivity C-reactive protein value (mg/L) during hospital stays. (c) The tendency of procalcitonin value (ng/mL) during hospital stays. (d) The tendency of platelet value (10<sup>9</sup>/L) during hospital stays. (e) The tendency of alanine aminotransferase value (U/L) during hospital stays. (f) The tendency of aspartate aminotransferase value (U/L) during hospital stays.

## Discussion

JSF is a zoonotic infectious disease with *Rickettsia japonica* as the source of infection and the bite of arthropods (ticks, lice and mites) as the route of transmission, with ticks being the main source of transmission. It was found that *Rickettsia japonica* infection was detected in eight species of three genera of ticks (*Haemaphysalis*, *Dermacentor* and *Ixodes*), and that *H. flava* and *H. longicornis* were the important vector ticks of JSF. In China, the main vector of JSF is probably the *Haemaphysalis longicornis*, which is widely distributed in eastern China.<sup>2</sup> The onset of the disease is distinctly seasonal, occurring more frequently from early summer to fall in patients with a history of outdoor activities in jungles, wilderness, and farmland. The triad of high fever, petechial rash, and eschar is a typical clinical presentation of JSF, accompanied by progressive thrombocytopenia, elevated CRP, and elevated liver enzymes during the course of

**Table I** Body Temperature and Laboratory Indices During Hospital Stays

Date	Temperature Max, °C (36.0–37.0)	C-Reactive Protein, mg/L (0.0–3.0)	Procalcitonin, ng/mL (<0.05)	Platelet, 10 <sup>9</sup> /L (125.0–350.0)	Alanine Aminotransferase, IU/L (9.0–60.0)	Aspartate Aminotransferase, IU/L (15.0–45.0)
Aug. 31	39.2	161.35	0.66	62	114.2	175.6
Sept. 1	40.1	173.11	1.39	57	81.6	109.2
Sept. 2	38.7	67.11	1.53	88	59	76
Sept. 3	37.2	44.46	0.69	105	48.9	65.3
Sept. 7	36.6	22.24	0.15	173	40	45.6

the disease. Since the first case of JSF in China in 2013, scattered cases have been reported in Zhejiang, Sichuan, Hunan and Hubei provinces,<sup>7,10,11</sup> reflecting the widespread nature of the disease in China. The unclear history of arthropod exposure, incomplete presence of the typical triad and limitations of molecular diagnostic techniques in the laboratory have led to a relatively high rate of misdiagnosis, serious complications and risk of death. The absence of eschar was the main reason JSF was not suspected in the primary hospital in this case. Studies have shown that 60% of patients with JSF present with eschar, but 90.0% of patients with JSF present with fever, petechial rash, elevated CRP and eosinopenia, suggesting that fever, petechial rash, elevated CRP and eosinopenia are good markers of JSF when there is no evidence of eschar,<sup>8</sup> which is supported by clinical evidence in this case. The commonly used techniques of immunofluorescence, enzyme-linked immunosorbent assay and quantitative polymerase chain reaction for pathogenetic diagnosis are slightly less timely and less often positive for diagnosis, especially in patients without evidence of eschar. Rapid and accurate diagnosis via mNGS is invaluable for providing early etiologic therapy, reducing complications, and decreasing morbidity and mortality.<sup>12,13</sup> In nonspecific cases of JSF, mNGS can provide ideas for pathogenetic diagnostic diagnosis. Blood mNGS in this case facilitated the initiation of precision therapy and avoided serious complications to some extent.

*Rickettsia japonica* is a specialized intracellular gram-negative bacterium, and the judicious use of antibiotics is critical to the prognosis of JSF.<sup>2</sup> Its treatment has not yet been standardized.<sup>14</sup> Tetracyclines, especially doxycycline and minocycline, are the first-line drugs for the treatment of JSF. When JSF is suspected, empirical treatment with tetracyclines can be used to avoid rapid disease progression when contraindications are ruled out.<sup>15</sup> Some case reports have shown that the combination of omadacycline and omadacycline combined with moxifloxacin is advantageous in the treatment of severe rickettsial infections, fluoroquinolones in combination with tetracyclines have an advantageous regimen in reducing fever during the patient's clinical course,<sup>9,14,16</sup> and it is agreed that  $\beta$ -lactams and aminoglycosides cannot enter the cellular compartments and are ineffective against JSF. This is the main reason for the ineffectiveness of empirical anti-infective treatment of the present patient in the primary hospital, which should be emphasized by clinical practitioners.

## Conclusion

In geographic areas with tick-borne vectors, patients presenting with unexplained high fever and petechial rash should be considered for Japanese rickettsial infections. Early initiation of tetracycline-based anti-infective therapy, along with appropriate testing, is crucial for timely diagnosis and treatment of JSF, thereby reducing the rates of critical illness and fatalities.

## Acknowledgments

Many thanks for works by the staffs in the Department of Infectious Disease, The General Hospital of Western Theater Command.

## Consent for Publication

Written informed consent was provided by the patient for the publication of the case details and images. Details of the case can be published without institutional approval.

## Funding

This work was supported by the Natural Science Foundation of Sichuan Province (No. 2023NSFSC0742).

## Disclosure

The authors report no conflicts of interest in this work.

## References

1. Mahara F, Koga K, Sawada S, et al. The first report of the rickettsial infections of spotted fever group in Japan: three clinical cases. *Kansenshogaku Zasshi*. 1985;59(11):1165–1171. doi:10.11150/kansenshogakuzasshi1970.59.1165
2. Wang XLY, Shang M, et al. Rickettsia japonica and Japanese spotted fever: a review on the pathogen and disease. *Chin J Vector Biol Control*. 2024;35(01):128–131.
3. Lu Z, Han J, Wang Y, et al. Diagnosing and reintegrating traceability of infectious diseases via metagenomic next-generation sequencing: study of a severe case of Rickettsia japonica infection. *Infect Med*. 2024;3(1):100094. doi:10.1016/j.imj.2024.100094
4. Kinoshita H, Arima Y, Shigematsu M, et al. Descriptive epidemiology of rickettsial infections in Japan: scrub typhus and Japanese spotted fever, 2007–2016. *Inter J Infect Dis*. 2021;105:560–566. doi:10.1016/j.ijid.2021.02.069
5. National Institute of Infectious Diseases. Japanese spotted fever 1999–2019. *IASR*. 2021;41(08):133–135.
6. I Fukunaga. Trends in Japanese Spotted Fever (JSF) Outbreaks: situation in the Eastern Region of Kochi Prefecture in Japan, a High-incidence Area. *JMA J*. 2022;5(4):539–542. doi:10.31662/jmaj.2022-0131
7. Teng Z, Gong P, Wang W, et al. Clinical Forms of Japanese Spotted Fever from Case-Series Study, Zigui County, Hubei Province, China, 2021. *Emerg Infect Dis*. 2023;29(1):202–206. doi:10.3201/eid2901.220639
8. Noguchi M, Oshita S, Yamazoe N, Miyazaki M, Takemura YC. Important Clinical Features of Japanese Spotted Fever. *Am J Trop Med Hyg*. 2018;99(2):466–469. doi:10.4269/ajtmh.17-0576
9. Xu W-X, Huang S-M, Qu Q, Shen L, Qu J. Application of omadacycline in the treatment of severe Japanese spotted fever. *Travel Med Infectious Dis*. 2024;2024:58. doi:10.1016/j.tmaid.2024.102707
10. Zhou Y, Wang Q, Shen Y, et al. A Case of Critical Japanese Spotted Fever in Zhejiang, China. *Infect Drug Resist*. 2023;16:3425–3430. doi:10.2147/IDR.S408499
11. Yu YFD, Guan L, et al. Japanese spotted fever complicated with multiple organ failure: a case report. *Chin J Infect Chemother*. 2023;23(06):743–746.
12. Clinical Microbiology Group of Chinese Society of Laboratory Medicine CMGoCSolMaSoCM, Infection of China International Exchange and Promotion Association for Medical and Healthcare. Chinese expert consensus on metagenomics next-generation sequencing application on pathogen detection of infectious diseases. *Chin J Lab Med*. 2021;02(44):107–120.
13. Gu W, Deng X, Lee M, et al. Rapid pathogen detection by metagenomic next-generation sequencing of infected body fluids. *Nat Med*. 2021;27(1):115–124. doi:10.1038/s41591-020-1105-z
14. Itoh K, Kabata D, Shigemi H, et al. Evaluation of tetracycline and fluoroquinolone therapy against Japanese spotted fever: analysis based on individual data from case reports and case series. *Int J Antimicrob Agents*. 2023;62(2):106895. doi:10.1016/j.ijantimicag.2023.106895
15. Sato R, Yamada N, Kodani N, Makiishi T, Iwashita Y. Prompt diagnosis and appropriate treatment of Japanese spotted fever: a report of three cases. *Heliyon*. 2024;10(1):e23462. doi:10.1016/j.heliyon.2023.e23462
16. Quade BR, Ramírez-Hernández A, Blanton LS. In Vitro Susceptibility of Rickettsia Species to Eravacycline, Omadacycline, and Tigecycline. *Antimicrob Agents Chemother*. 2021;65(8):e0066521. doi:10.1128/AAC.00665-21

Infection and Drug Resistance

Dovepress

### Publish your work in this journal

Infection and Drug Resistance is an international, peer-reviewed open-access journal that focuses on the optimal treatment of infection (bacterial, fungal and viral) and the development and institution of preventive strategies to minimize the development and spread of resistance. The journal is specifically concerned with the epidemiology of antibiotic resistance and the mechanisms of resistance development and diffusion in both hospitals and the community. The manuscript management system is completely online and includes a very quick and fair peer-review system, which is all easy to use. Visit <http://www.dovepress.com/testimonials.php> to read real quotes from published authors.

Submit your manuscript here: <https://www.dovepress.com/infection-and-drug-resistance-journal>