

Original Article

Pathological analysis of batch safety testing of veterinary vaccines using small laboratory animals

Kasumi Sudo^{1†}, Mariko Ochiai^{1†}, Naoyuki Aihara^{1,2*}, Noriyuki Horiuchi^{1,3}, Atsushi Yamamoto¹, Sachiko Matsumoto¹, and Koji Oishi^{1,4}

¹National Veterinary Assay Laboratory, Ministry of Agriculture, Forestry and Fisheries, 1-15-1 Tokura, Kokubunji, Tokyo 185-8511, Japan

²Laboratory of Veterinary Pathology, Azabu University, 1-17-71 Fuchinobe, Chuo-ku, Sagamihara, Kanagawa 252-5201, Japan

³Research Center for Global Agromedicine, Obihiro University of Agriculture and Veterinary Medicine, Obihiro, Hokkaido 080-8555, Japan

⁴Present address: Japan Veterinary Products Association, Sato Bldg. 6F 4-6-10 Nihonbashi-Honcho, Chuo, Tokyo 103-0023, Japan

Abstract: Batch safety tests (BSTs) of veterinary vaccines are conducted using small laboratory animals to assure the safety of vaccines according to several criteria, including clinical signs and change in body weight. Although the latter is used as an evaluation index in BSTs, there have been no reports on the internal changes that affect body weight during the test period. Therefore, we analyzed BST via pathological examination of the tested animals. Here, BSTs were performed for 176 batches using mice and 126 batches using of guinea pigs. Most of the gross findings could be classified into four lesion types (nodules, adhesions, ascites, no apparent signs), with only one vaccine inducing lesions that could not be classified into any of these four types. Histopathological examination revealed that the reactions caused by BST were pyogenic and/or granulomatous inflammation. Nodular or adhesive lesions comprised more severe pyogenic granulomatous inflammation than ascites or cases with no apparent gross lesions. These nodular or adhesive lesions were more frequently induced by vaccines that contained an adjuvant than by vaccines that did not contain an adjuvant. The cases with “exceptional” gross findings histologically presented severe necrosis of the hematopoietic system. Additional testing showed that these “exceptional” lesions were induced when a specific type of light liquid paraffin was injected along with other vaccine additives. Our results show that body weight loss and/or lesions during BST were induced by proinflammatory properties of the tested vaccines and that BST is a sensitive method for detecting unexpected effects of vaccine components. (DOI: 10.1293/tox.2020-0078; J Toxicol Pathol 2021; 34: 137–146)

Key words: small laboratory animal batch safety test, pathological examination, veterinary vaccine toxicity

Introduction

Batch safety tests (BSTs) of veterinary vaccines using small laboratory and/or target animals can detect non-specific toxicity and reveal adverse effects of the finalized product formulations. Unlike pharmaceuticals that are synthesized chemically, biologicals carry an unpredictable risk because they are prepared with serum, live cells, and microorganisms, and unexpected substances and metabolites can be generated during production¹. This risk explains why BSTs are required for batch release in many countries, in-

cluding Japan. In BSTs using small laboratory animals, vaccine safety is assured when the tested animals do not show abnormal clinical signs or abnormal body weight changes within defined periods per the guidelines or laws of each country². In Japan, abnormal toxicity tests (ATTs) and toxicity limit tests (TLTs) are required as BSTs using small laboratory animals by the “minimum requirements for biological products” in Article 42, Clause 1 of the Law on Securing Quality, Efficacy, and Safety of Pharmaceuticals and Medical Devices^{3,4}. ATTs are applied to veterinary vaccines that do not contain virulent components, such as attenuated or inactivated vaccines; TLTs are applied to veterinary vaccines that contain some virulent components, such as liquid paraffin or lipopolysaccharide (LPS). ATTs and TLTs are briefly outlined in Table 1.

The introduction of vaccine quality assurance systems, such as Good Manufacturing Practice (GMP), Good Laboratory Practice (GLP), and seed lot system, into the manufacturing process has greatly increased the consistency of the batches produced, and stabilized the quality of veterinary vaccines¹. Recently, attitudes relating to the quality control

Received: 2 November 2020, Accepted: 2 February 2021

Published online in J-STAGE: 25 February 2021

*Corresponding author: N Aihara (e-mail: aihara@azabu-u.ac.jp)

†These authors contributed equally to this work.

©2021 The Japanese Society of Toxicologic Pathology

This is an open-access article distributed under the terms of the Creative Commons Attribution Non-Commercial No Derivatives

(by-nc-nd) License. (CC-BY-NC-ND 4.0: <https://creativecommons.org/licenses/by-nc-nd/4.0/>).



of veterinary vaccines have increased emphasis on controlling the manufacturing process compared with traditional batch control. The above-mentioned BSTs using small laboratory animals have been developed as general safety tests to detect non-specific toxicity and/or contain exogenous substances. However, a guideline describing the criteria to waive the BST in small laboratory animals for veterinary vaccines has been discussed, and BST is being considered to ensure consistency of the product safety profile⁵.

One assessment index in BSTs using small laboratory animals is the change in body weight of the tested animals. If animals lose a significant amount of body weight following injection of the tested vaccine, the vaccine is judged to have some safety problems. A previous study⁶ reported changes in body weight that are characteristic of each vaccine in BSTs using small laboratory animals, and proposed that the standardized changes can be used as references to evaluate the degree of vaccine toxicity or batch-to-batch differences in test vaccines. However, it is unclear what internal changes lead to the changes in body weight observed during BSTs. Understanding what abnormalities are detected by the BST will help to re-establish the consistency of the product safety profile. In this study, we pathologically examined small laboratory animals after BST and obtained fundamental data to help expand our understanding of the BST analysis on veterinary vaccines.

Materials and Methods

Animals

Female Hartley strain specific-pathogen free guinea pigs weighing approximately 350 g were obtained from Tokyo Laboratory Animal Science Co., Ltd (Tokyo, Japan) or Japan SLC, Inc. (Shizuoka, Japan). Female specific-pathogen free ddY mice (age: 5 weeks) were obtained from Japan SLC, Inc. In total, 1,760 mice and 276 guinea pigs were used in the ATTs and TLTs. For additional testing (see mentioned), 110 female specific-pathogen free ddY mice (age: 3 weeks) were used.

ATT and TLT

This study was performed at the National Veterinary Assay Laboratory (NVAL) in Japan from 2011 to 2012. The study vaccines included 176 vaccine batches (ATT: 117, TLT: 59) for mice and 126 vaccine batches (ATT: 118, TLT: 8) for guinea pigs (Table 2). In accordance with the general method for “minimum requirements for biological products”², the following parameters were set: number of animals (10 mice per vaccine batch, two or five guinea pigs per vaccine batch), administration route (intraperitoneal injection), dosage (0.5 ml per mouse, 5 ml per guinea pig), and observation period (ATT: 7 or 10 days, TLT: 7 days or the judgment day, based on the standard for each vaccine). If there were approved dosing methods, observation periods, and judgment days for a vaccine, those methods were used. All animals were weighed and observed for clinical signs during the test period. Briefly, in the ATT, body weight was measured at day 0 (before the test), days 1–4, and day 7 (end of the test) and day 10 if required. In the TLT, body weight was measured at day 0 (before the test), days 1–4, and day 7 or the judgment day. The maximum body weight loss compared to the body weight at day 0 was used for statistical analyses.

All procedures applied to the animals were approved by the Committee on the Ethics of Animal Experiments at NVAL (Permit Number: 22–031), and all applicable international, national, and institutional guidelines for animal care were followed.

Autopsy and histological observation

At the end of the ATT and TLT, mice and guinea pigs were humanely euthanized by cervical dislocation or carbon dioxide, respectively, and the gross appearance was recorded following dissection. If similar autopsy findings were recorded for animals in one group, three of the 10 mice were used for histological examination, while all guinea pigs were used for histological examination. The organs used for histological examinations included the heart, lung, liver, kidney, and spleen from mice; and the heart, lung, liver, kidney,

Table 1. Batch Safety Tests (BSTs) of Veterinary Immunological Products Using Small Laboratory Animals in Japan

	Animal	Method	Criterion
Abnormal toxicity test (ATT)	2 guinea pigs 10 mice	Guinea pig: 5 ml intraperitoneal injection, 7 days observation Mice: 0.5 ml intraperitoneal injection, 7–10-day observation	If there are no abnormal health signs during the observation period, the product passes the test.
Toxicity limit test (TLT)	5 guinea pigs 10 mice	Guinea pig: 5 ml intraperitoneal injection, 7 days observation Mice: 0.5 ml intraperitoneal injection, 7 days observation	If the animal survives without any abnormal signs during the observation and the body weight returns to the baseline level within a specified time, the product passes the test.

If there are approved methods that set the observation period and judgment day, these methods are used. These parameters were set in accordance with the general method for “minimum requirements for biological products” in Article 42, clause 1 of the Law on Securing Quality, Efficacy and Safety of Pharmaceuticals and Medical Devices.

spleen, and pancreas from guinea pigs. These tissues were embedded in paraffin and stained with hematoxylin and eosin. When abnormal macroscopic findings were found in other organs, they were also examined histologically.

Additional testing to evaluate the influence of different vaccine additives

As only one vaccine in the TLT resulted in abnormal pathological findings, additional testing was conducted to confirm the cause of the lesion. We focused on light liquid paraffin as the cause of the lesion, as it is the main adjuvant compound known to exhibit toxicity in rodents⁷. We prepared four mixtures and the vaccine that caused the initial lesion, and set six treatment groups (Table 3). Mixture-1 was similar to the adjuvant of the vaccine that induced the “exceptional” lesions mentioned above, and contained a light liquid paraffin of the same grade as that used in the vaccine (Hycol K-160, Kaneda Co., Tokyo, Japan), DL- α -tocopherol acetate (Kanto Chemical Co., Inc., Tokyo, Japan), surfactant polysorbate 80 (Kanto Chemical Co., Inc.), simethicone (KS66: Shin-Etsu Chemical Co., Ltd., Tokyo, Japan), and phosphate buffered salts. Mixture-2 contained the same combination of reagents as Mixture-1, with the exception of light liquid paraffin, which was from Kosakai Pharmaceutical Corporation (Chiba, Japan). Mixture-3 contained the same light liquid paraffin as Mixture-1, and water. Mixture-4 contained the same light liquid paraffin as Mix-

ture-2, and water.

Two-days after injection of the mixtures, the animals were euthanized and the blood, bone marrow, heart, lungs, liver, kidneys, spleen, and thymic gland were collected and observed for gross and histological changes.

Statistical analysis

Animals were divided into groups injected with vaccines with or without adjuvant. Then, we evaluated the relationship between adjuvant and four kinds of abdominal changes using the chi-square test. The relationship between maximum weight loss and four kinds of abdominal changes was evaluated by one-way ANOVA with a Tukey-Kramer post-hoc test using GraphPad Prism (GraphPad Software Inc., San Diego, CA, USA). Differences were considered significant at a *P* value <0.05.

Results

Autopsy findings of animals treated with test batch vaccine solutions

Most of the macroscopic intraperitoneal findings in mice and guinea pigs could be divided into four types of lesions, which are listed in Table 4. When multiple types of lesions were found in one treatment group, each type was classified and counted. Typical gross findings are presented in Fig. 1. Nodular lesions (Type 1) were mainly milk-white,

Table 2. Number of Vaccine Batches Tested in Mice and Guinea Pigs

		Mice			Guinea pigs		
		ATT	TLT	(n)	ATT	TLT	(n)
Adjuvant	+	42	59	101	43	8	51
	-	75	0	75	75	0	75
Total		117	59	176	118	8	126

ATT: abnormal toxicity test, TLT: toxicity limit test, (n): Number of animals

Table 3. Treatment Groups Used for Additional Testing of Injected Substances

Group	Injected substances	Dose	
A	Vaccine	0.5 ml	1.0 ml
B	Mixture-1 (same compound as the vaccine without pharmaceutical ingredients, and containing the same grade of light liquid paraffin, tocopherol acetate, polysorbate 80, simethicone, and phosphate buffered salts)	0.5 ml	1.0 ml
C	Mixture-2 (same compound as Mixture-1 but the light liquid paraffin is different)	0.5 ml	1.0 ml
D	Mixture-3 (emulsion of the same light liquid paraffin as Mixture-1 and water)	0.5 ml	1.0 ml
E	Mixture-4 (emulsion of the same light liquid paraffin as Mixture-2 and water)	0.5 ml	1.0 ml
F	Control (no injection)	No injection	

n = 10 animals in each group

Table 4. Classification of Observed Gross Findings

Type	Classification	Definition
Type 1	Nodules	Observed nodular lesions, histologically localized nodal suppurative inflammation
Type 2	Adhesions	Observed adhesions of organs
Type 3	Ascites	Observed significant ascitic fluid
Type 4	No significant lesions	Not relevant to the above types, but observed mild lesion such as liver discoloration and spleen swelling

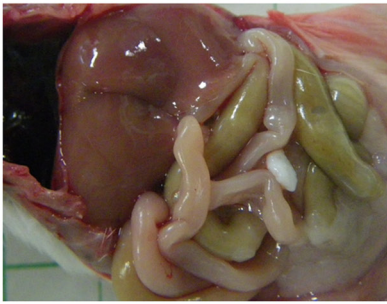
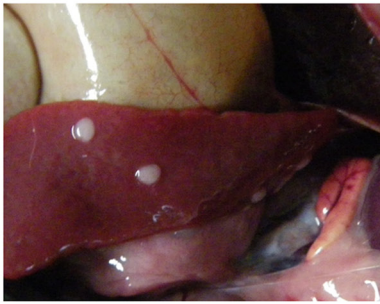

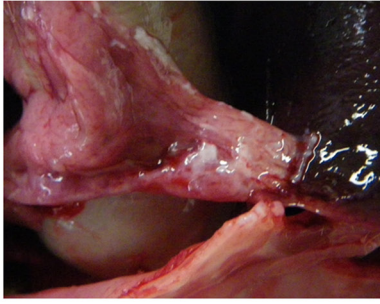


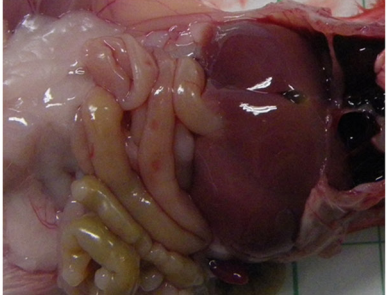
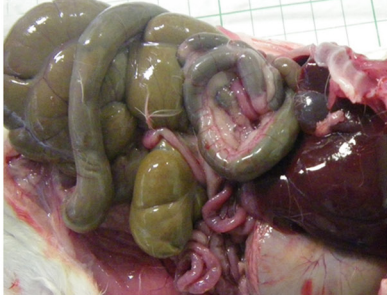
Type	Mice	Guinea pigs
1 Nodules		
2 Adhesions		
3 Ascites		
4 No significant lesions		

Fig. 1. Typical gross findings in mice and guinea pigs during post-treatment autopsy. (Type 1) nodules, (Type 2) adhesions, (Type 3) ascites, and (Type 4) no significant findings. Type 1 are milk-white and needle-tip-sized nodular lesions. Type 2 are adhesions observed on the contact surface of organs along with fibrin. Type 3 is colorless serous or milky viscous ascitic fluid. Type 4 is the absence of severe lesions or slight liver discoloration, or mild spleen swelling.

needle-tip sized, and were strongly attached to organ surfaces. Adhesions (Type 2) were particularly observed on the contact surface of organs, with fibrin present in adhesion areas. These adhesions frequently occurred between two or more organs (liver, stomach, pancreas, spleen, diaphragm, and intestines). Animals classified with ascites (Type 3) had colorless serous or milky viscous ascitic fluid. No signifi-

cant lesions (Type 4) were classified as the absence of severe lesions, slight liver discoloration, or mild spleen swelling. In mice treated with a vaccine, a lesion that could not be classified into the above four types (indicated as “exceptional” case or lesions) was characterized as broad spleen discoloration (Fig. 2A).

In mice who received different injections, Type 1 le-

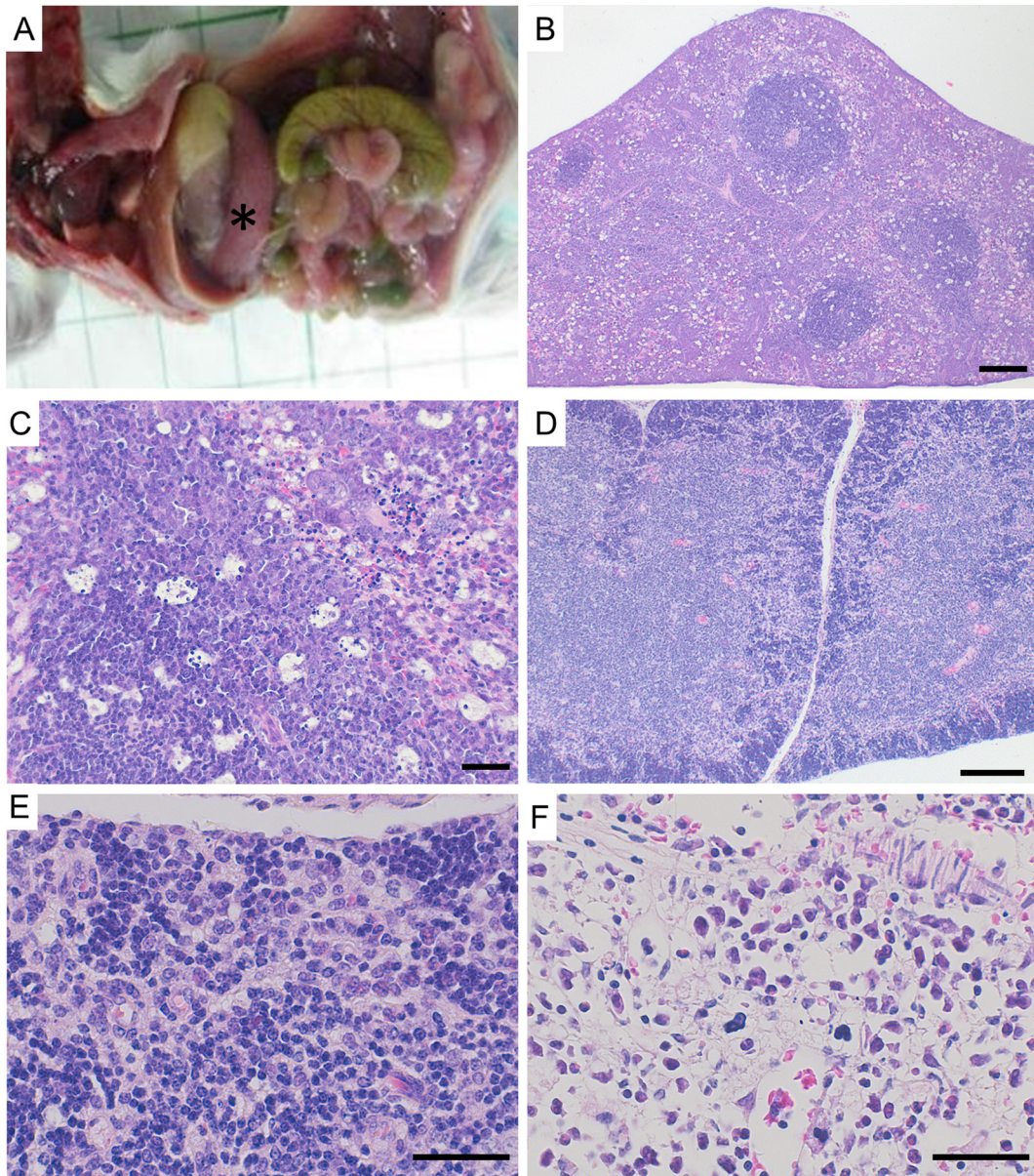


Fig. 2. Lesions observed in “exceptional” cases that could not be divided into the four typical types of lesions. (A) Severe splenic discoloration and atrophy (asterisk) at autopsy. (B to F) Histopathological findings. Lymphoid necrosis was observed in both red and white pulp, and vacuolated macrophages in red pulp. A starry sky-appearance with apoptosis was also observed in white pulp in the (B and C) spleen. Cortical atrophy was found in the (D and E) thymus. A decrease in cell density was observed in (F) bone marrow. HE, Bar = 100 μ m in B and D; and 20 μ m in C, E, and F.

sions were detected in 29.5% (52/176 tests), Type 2 lesions in 0.0% (0/176 tests), Type 3 lesions in 5.1% (9/176 tests), Type 1 and 2 lesions in 9.1% (16/176 tests), Type 1 and 3 lesions in 8.5% (15/176 tests), Type 1, 2, and 3 lesions in 2.3% (4/176 tests), and Type 4 lesions in 44.3% (78/176 tests). An exceptional lesion was detected in 1.1% of mice (2/176 tests) and Type 3 lesions were detected in one test. In guinea pigs, type 1, 2, 3, and 4 lesions were detected in 30.2% (38/126), 0.8% (1/126), 3.2% (4/126), and 46.0% (58/126) mice, respectively, and Type 1 and 2 lesions in 13.5% (17/126), Type 1 and 3 lesions in 5.6% (7/126), and Type 1, 2, and 3 lesions in 0.8% (1/126) mice; however, no “exceptional” le-

sions were observed (Table 5). There were multiple batches of one vaccine (42/185 tested batches); if they were the same vaccine, the intraperitoneal results tended to be the same because the intraperitoneal results were the same in 32/42 tested batches.

Histopathological findings of animals treated with test batch vaccine solutions

Histopathological findings in mice and guinea pigs administered peritoneal injections of test batch vaccine solutions are shown in Fig. 3. Type 1 lesions were localized to sites of pyogenic granulomatous inflammation, which were

Table 5. Observed BSTs Results in the Tested Mice and Guinea Pigs

	Mice (Number of tests)						Guinea pigs (Number of tests)					
	Adjuvant vaccine			Non-adjuvant vaccine			Adjuvant vaccine			Non-adjuvant vaccine		
	ATT (42)	TLT (59)	total (101)	ATT (75)	TLT (0)	total (75)	ATT (43)	TLT (8)	total (51)	ATT (75)	TLT (0)	total (75)
Type 1	34	53	87 ^a	0	0	0 ^b	40	8	48 ^a	15	0	15 ^b
Type 2	3	17	20 ^a	0	0	0 ^b	8	6	14 ^a	5	0	5 ^b
Type 3	10	13	23 ^a	6	0	6 ^b	6	0	6	6	0	6
Type 4	6	3	9 ^a	69	0	69 ^b	3	0	3 ^a	55	0	55 ^b
Exceptional	0	2	2	0	0	0	0	0	0	0	0	0
(Detailed breakdown)												
Type 1 only	23	29	52	0	0	0	27	2	29	9	0	9
Type 2 only	0	0	0	0	0	0	0	0	0	1	0	1
Type 3 only	2	1	3	6	0	6	0	0	0	4	0	4
Type 1 + 2	3	13	16	0	0	0	7	6	13	4	0	4
Type 1 + 3	8	7	15	0	0	0	5	0	5	2	0	2
Type 1 + 2 + 3	0	4	4	0	0	0	1	0	1	0	0	0
Type 4	6	3	9	69	0	69	3	0	3	55	0	55
Exceptional only	0	1	1	0	0	0	0	0	0	0	0	0
Exceptional + Type 3	0	1	1	0	0	0	0	0	0	0	0	0

The chi-square test was used (a statistically significant result at P value <0.05). There was a significant difference between different symbols (“a” and “b”) in each type of lesion observed in mice and guinea pigs. When multiple types of lesions were found in one treatment group, each type was classified and counted. ATT: abnormal toxicity test, TLT: toxicity limit test. The number of animals classified into four types is described. Some batches were re-tested.

mainly composed of eosinophilic homogenized substances accompanied by neutrophil and macrophage invasion (Fig. 3A and B). These lesions were surrounded by granulation tissue. In the liver, hepatocyte necrosis was observed adjacent to the area of inflammation. Type 2 lesions were observed as multiple organ adhesions attached by fibrin and pyogenic granulomatous inflammation (Fig. 3C and D). The animals with Type 3 lesions had mild neutrophil infiltration of organ serosa (Fig. 3F). In animals with Type 4, macroscopic lesions were not evident; slight liver discoloration and spleen swelling were observed. Microscopically, cloudy swelling of hepatocytes and reactive follicular hyperplasia of the spleen were observed. Microscopic micro-abscesses or small focal necrosis in the live and mild pyogenic granulomatous pancreatitis or lymphoid follicular hyperplasia of the lung were occasionally observed in all animals classified with Type 1–4 lesions. The degree of pyogenic and/or granulomatous inflammation was more severe in Type 1 and 2 lesions than in Type 3 and 4 lesions.

In “exceptional” lesions, lymphoid necrosis was observed in both red and white pulp, and in vacuolated macrophages in red pulp. There was a starry sky-appearance with apoptosis in the white pulp (Fig. 2B, C). Cortical atrophy was also found in the thymus (Fig. 2D and E), and a decrease in cell density was observed in the bone marrow of treated mice (Fig. 2F).

Statistical analysis of lesions from trials of vaccine batch treatments

Statistical analysis showed that Type 1, 2, and 3 lesions in mice, and Type 1 and 2 lesions in guinea pigs were more significantly induced by adjuvant vaccines than by non-ad-

juvant vaccines. Conversely, Type 4 lesions were observed more frequently with non-adjuvant vaccines than with adjuvant vaccines in both mice and guinea pigs (Table 5).

We also evaluated the relationship between the maximum weight loss recorded during the test and gross pathological findings. Mice with Type 1, 2, and 3 lesions had more significant body weight loss than those with Type 4 lesions. Mice with Type 2 lesions presented the most severe weight loss; this was significantly greater than in mice with Type 1 and 3 lesions. Although mice with “exceptional” lesions were only confirmed in two batches of one vaccine, they also presented a more significant loss in body weight than those with Type 4 lesions (Fig. 4A). In the guinea pig tests, animals with Type 1 and 2 lesions lost significantly more body weight than those with Type 4 lesions. Guinea pigs with Type 2 lesions presented the most severe weight loss, which was significantly greater than that of guinea pigs than Type 3 lesions (Fig. 4B).

Additional testing to evaluate the influence of different vaccine additives

Additional testing was conducted to evaluate the vaccine additive that was responsible for the uncharacterized lesions; mice were injected with test solutions A–F (see Table 3). One-milliliter of injected solution in groups A and B promoted significant spleen discoloration and atrophy (Fig. 5A), severe lymphoid necrosis in both red and white pulp, and vacuolated macrophages in the red pulp. A starry sky-appearance with apoptosis was also observed in the white pulp (Fig. 5B). Mild spleen discoloration, which presented as an accumulation of vacuolated macrophages in red pulp, was observed occasionally in group A and B

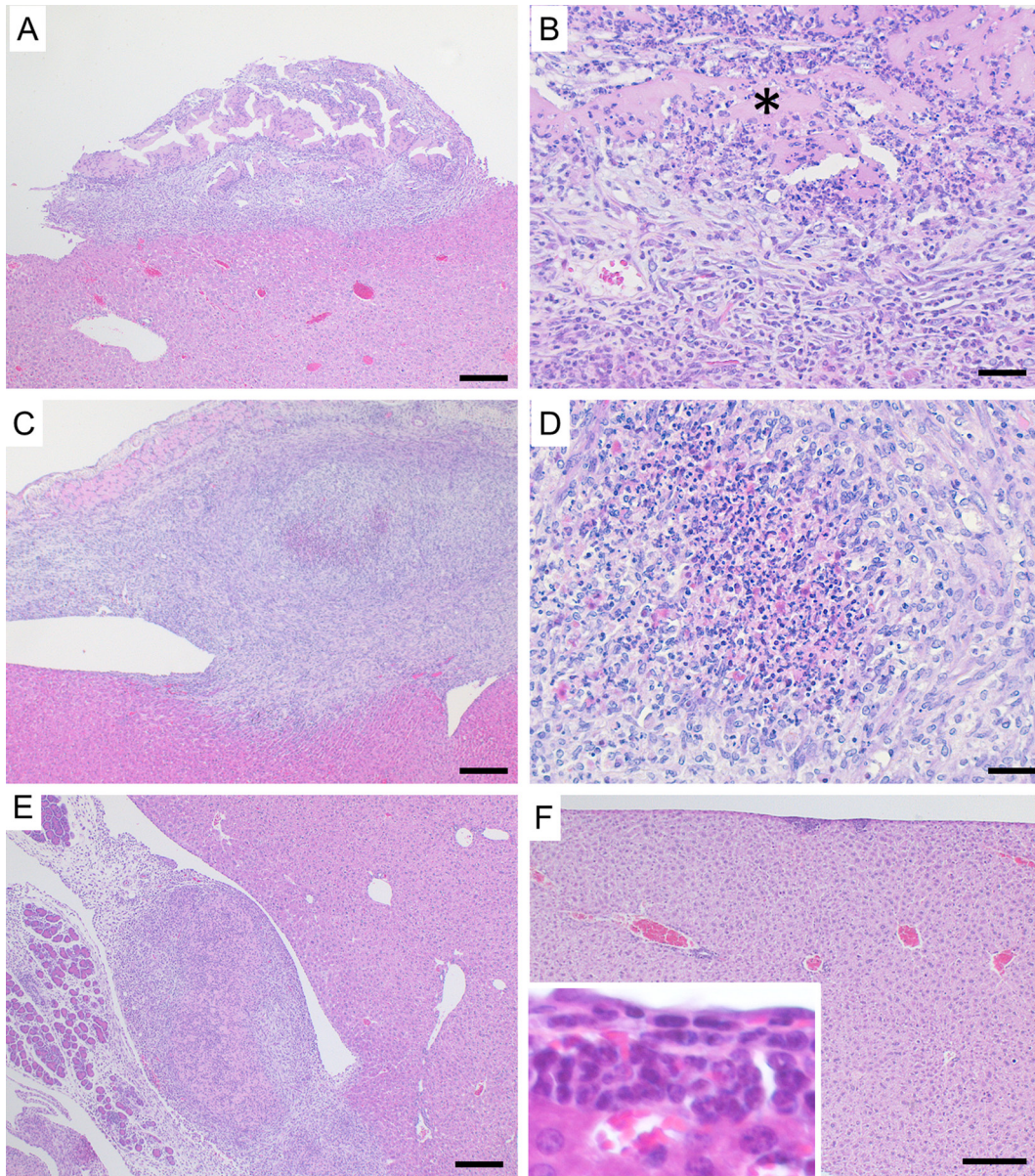


Fig. 3. Typical histopathologic findings in mice and guinea pigs during post-treatment autopsy. (A) Type 1 lesion observed in a mouse liver. A pyogenic granulomatous nodule was observed on the liver serosa. (B) Eosinophilic homogenized substance (asterisk) was surrounded by granulation tissue. (C and D) Type 1 lesion in a guinea pig liver. Pyogenic granulomatous inflammation composed of eosinophilic homogenized substances accompanied by neutrophil and macrophage invasion. (E) Type 2 lesions (adhesion) caused by pyogenic granulomatous tissues were observed between the liver and spleen in mice. (F) Mild neutrophil infiltration was observed in mice with Type 3 lesions. Inset shows neutrophil infiltration at high magnification. HE, Bar = 100 μ m in A, C, E, and F; and 20 μ m in B and D.

mice injected with 0.5 ml test solution, and group C mice injected with 0.5 and 1.0 ml test solution. However, these severe symptoms were not observed in groups A and B mice injected with 0.5 ml test solution or in group C, D, E, and F mice.

Discussion

In this study, we quantified the pathological findings of BSTs in mice and guinea pigs treated with batched vaccines, and identified the cause of body weight changes in

BST for the first time. The findings of our study showed that gross and histological lesions could be classified into four types, and these lesions were induced by an inflammatory response to a vaccine component. Histopathological evaluation showed that Type 1 and 2 lesions were associated with the most severe granulomatous and/or granulomatous and pyogenic inflammation, respectively, followed by Type 3 and 4 lesions. Additionally, severe inflammatory lesions (Type 1 and 2) were more significantly induced by vaccines that contained an adjuvant than by those that did not contain an adjuvant. The animals with severe inflammatory lesions

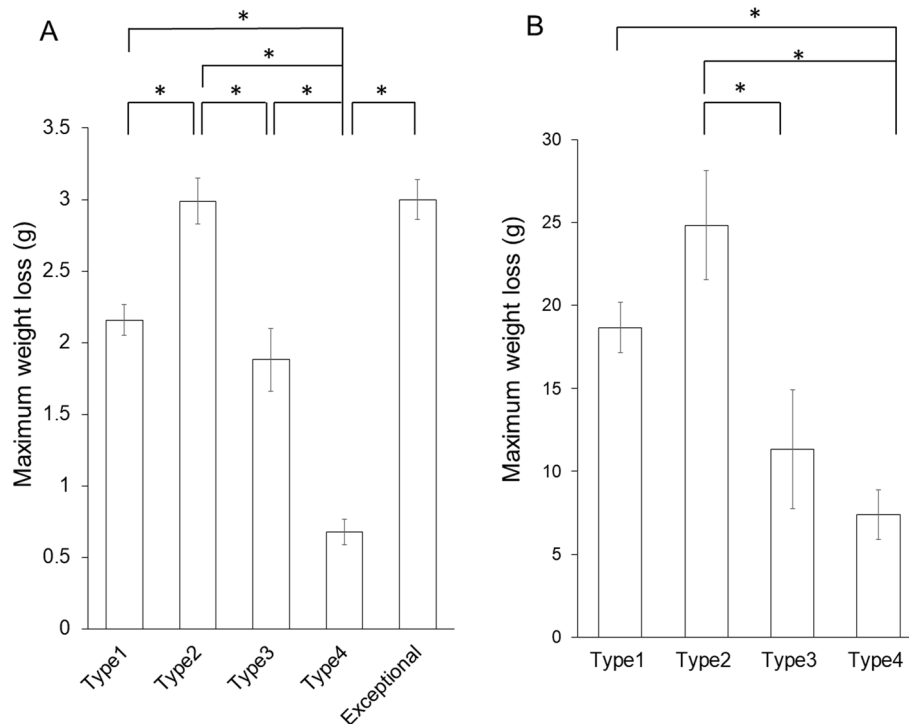


Fig. 4. The relationship between gross lesions and maximum body weight loss of tested mice and guinea pigs. (A) Results of the mice tests: (Type 1: $n = 90$, Type 2: $n = 23$, Type 3: $n = 29$, Type 4: $n = 80$, Exceptional: $n = 2$). (B) Results of the guinea pig tests: (Type 1: $n = 68$, Type 2: $n = 22$, Type 3: $n = 12$, Type 4: $n = 59$). Results are shown as the mean \pm standard error of the mean (SEM). Asterisk shows a significant difference at a P value < 0.05 .

(Types 1 and 2) lost significantly more body weight than those with mild inflammatory lesions (Type 4).

Vaccine adjuvants are used to enhance the immune response to vaccine antigens⁸. Our previous study⁹ showed that intraperitoneal injection of vaccines containing aluminum adjuvants potentially induced secondary bowel disorders in guinea pigs; however, this physical change was also caused by inflammation unrelated to vaccine toxicity. Therefore, an adjuvant potentiates inflammation and affects body weight loss during BST. Thus, BSTs mainly evaluate the proinflammatory properties of tested vaccines, but not vaccine toxicity, and the findings are expressed as temporal reductions in weight and/or mild clinical signs. Our experimental results also show that the vaccines examined as multiple batches tend to have the same effect on body weight, as well as gross and histopathological characteristics. These results suggest that each vaccine produces a specific response pattern in the BST.

Conversely, we found that one vaccine caused a lesion that could not be classified as any of the four abdominal lesion types. This lesion was characterized by severe splenic necrosis, which was not classified as inflammation. This lesion induced significant changes in body weight. To further investigate the “exceptional” lesion, we focused on the light liquid paraffin used as a vaccine solution additive, which is reported to exhibit toxicity in rodents⁷. Our additional testing showed that the injury of hematopoietic system led to

the lesion, and that this was not caused by the light liquid paraffin alone, but by mixing other components such as DL- α -tocopherol acetate and surfactants. In addition, an alternative liquid paraffin of the same grade did not induce such lesions. Emulsion adjuvants, including liquid paraffin, have been used empirically to enhance the immune effects of vaccines; however, their immune mechanism is not yet completely understood¹⁰. Some vaccines contain virulent components, such as liquid paraffin, with the expectation that these substances have adjuvant effects. Recently, effective methods for detecting the toxicity of vaccines have been improved^{11, 12}, but there are no alternative methods for BST in small laboratory animals that can detect unpredicted toxicity that is exhibited when other components are mixed into the vaccine solution. Therefore, BST can detect the toxicity of mixed solutions in rodents as well as changes in solution properties when a vaccine component is modified.

In conclusion, we showed that most changes in clinical signs and body weight loss observed in BSTs resulted from the proinflammatory properties of the tested vaccines; however, unpredictable effects of vaccine components were also detected with sensitivity. Although biologicals are stabilized through technical progression, the results of our study demonstrate that BSTs provide a quality check and can detect unexpected vaccine properties when their components are altered. When significant changes are made to the manufacturing process of a vaccine product, BST in small laboratory

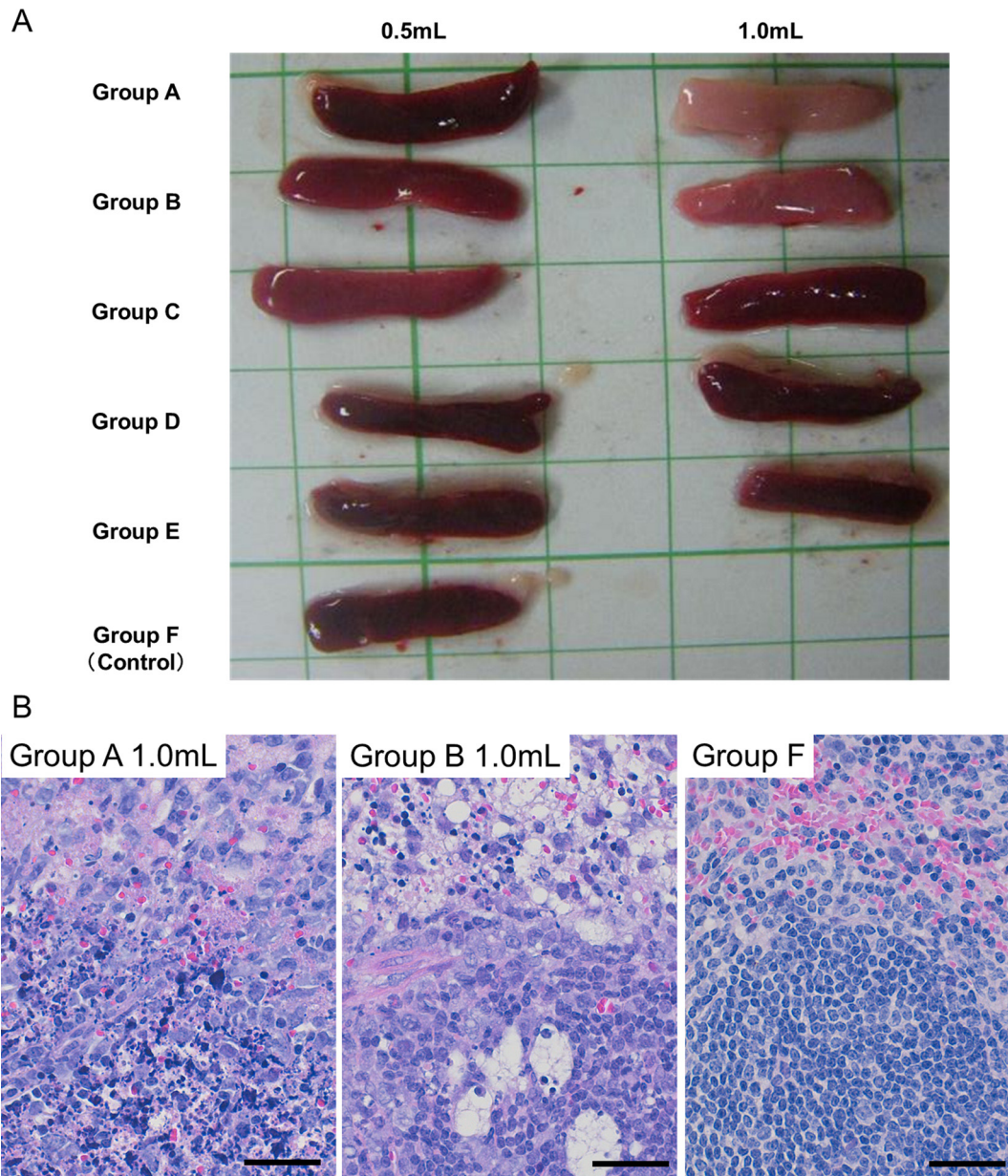


Fig. 5. Findings in the additional testing performed to evaluate the influence of vaccine additives. (A) Macroscopic comparison of the spleens from mice in each treatment group in the additional testing. Grid size = 1 cm. (B) Histopathological analysis reveals severe lymphoid necrosis in both red and white pulp, and vacuolated macrophages in red pulp from mice in treatment groups A and B injected with 1.0 ml of solution, but not from those in the control group F. In figure B, the upper site is the red pulp, and the lower site is the white pulp. HE, Bar = 20 μ m.

animals will be necessary to re-establish the consistency of the product safety profile.

Disclosure of Potential Conflicts of Interest: The authors declare no conflicts of interest.

Acknowledgments: We thank Ms. Mayumi Shibayama and Ms. Yoko Ishikawa for their excellent technical assistance. We also thank Editage (www.editage.jp) for English language editing.

References

1. Hendriksen C, Arciniega JL, Bruckner L, Chevalier M, Coppens E, Descamps J, Duchêne M, Dusek DM, Halder M, Kreeftenberg H, Maes A, Redhead K, Ravetkar SD, Spieser JM, and Swam H. The consistency approach for the quality control of vaccines. *Biologicals*. **36**: 73–77. 2008. [[Medline](#)] [[CrossRef](#)]
2. Garbe JHO, Ausborn S, Beggs C, Bopst M, Joos A, Kitashova AA, Kovbasenco O, Schiller CD, Schwinger M, Semenova N, Smirnova L, Stodart F, Visalli T, and Vromans L. Historical data analyses and scientific knowledge

- suggest complete removal of the abnormal toxicity test as a quality control test. *J Pharm Sci.* **103**: 3349–3355. 2014. [[Medline](#)] [[CrossRef](#)]
3. Anonymous. Minimum requirements for biological products. 2020, from Ministry of Agriculture, Forestry and Fisheries website: <https://www.maff.go.jp/nval/kijyun/pdf/ST06180.PDF>.
 4. Anonymous. Minimum requirements for biological products. 2020, from Ministry of Agriculture, Forestry and Fisheries website: <https://www.maff.go.jp/nval/kijyun/pdf/ST06190.PDF>.
 5. Viviani L, Halder M, Gruber M, Bruckner L, Cussler K, Sanyal G, Srinivas G, Goel S, Kaashoek M, Litthauer D, Lopes da Silva AL, Sakanyan E, Aprea P, Jin H, Vandeputte J, Seidle T, and Yakunin D. Global harmonization of vaccine testing requirements: Making elimination of the ATT and TABST a concrete global achievement. *Biologicals.* **63**: 101–105. 2020. [[Medline](#)] [[CrossRef](#)]
 6. Mizukami T, Masumi A, Momose H, Kuramitsu M, Takizawa K, Naito S, Maeyama J, Furuhashi K, Tsuruhara M, Hamaguchi I, and Yamaguchi K. An improved abnormal toxicity test by using reference vaccine-specific body weight curves and histopathological data for monitoring vaccine quality and safety in Japan. *Biologicals.* **37**: 8–17. 2009. [[Medline](#)] [[CrossRef](#)]
 7. Otunga GN, Maiyoh GK, Macharia BN, and Twei VC. Transformer mineral oil ingestion induces systemic sub-acute toxicity in Wistar rats. *Heliyon.* **5**: e02998. 2019. [[Medline](#)] [[CrossRef](#)]
 8. Garçon N, Hem S, and Friede M. Evolution of adjuvants across the centuries. In: *Vaccines*, 6th ed. SA Plotkin, WA Orenstein and PA Offit (eds). Elsevier, Amsterdam. 58–70. 2013.
 9. Aihara N, Ochiai M, Horiuchi N, Yamamoto A, Sudo K, Ishikawa Y, and Oishi K. Incidental induction of secondary bowel disorders in guinea pigs during a batch safety test of veterinary vaccines. *J Vet Med Sci.* **81**: 1129–1132. 2019. [[Medline](#)] [[CrossRef](#)]
 10. Fox CB, and Haensler J. An update on safety and immunogenicity of vaccines containing emulsion-based adjuvants. *Expert Rev Vaccines.* **12**: 747–758. 2013. [[Medline](#)] [[CrossRef](#)]
 11. Sasaki E, Momose H, Hiradate Y, Furuhashi K, Mizukami T, and Hamaguchi I. Development of a preclinical humanized mouse model to evaluate acute toxicity of an influenza vaccine. *Oncotarget.* **9**: 25751–25763. 2018. [[Medline](#)] [[CrossRef](#)]
 12. Hiradate Y, Sasaki E, Momose H, Asanuma H, Furuhashi K, Takai M, Aoshi T, Yamada H, Ishii KJ, Tanemura K, Mizukami T, and Hamaguchi I. Development of screening method for intranasal influenza vaccine and adjuvant safety in preclinical study. *Biologicals.* **55**: 43–52. 2018. [[Medline](#)] [[CrossRef](#)]