

This is an Open Access article licensed under the terms of the Creative Commons Attribution-NonCommercial 3.0 Unported license (CC BY-NC) (www.karger.com/OA-license), applicable to the online version of the article only. Distribution permitted for non-commercial purposes only.

Minimally Invasive Endourological Techniques may Provide a Novel Method for Relieving Urinary Obstruction due to Ureterosciatic Herniation

Tomonori Kato^{a, b} Akira Komiya^a Ryoichi Ikeda^b Takeshi Nakamura^b
Koichiro Akakura^b

^aDepartment of Urology, Graduate School of Medicine and Pharmaceutical Sciences for Research, University of Toyama, Toyama-shi, and ^bDepartment of Urology, Tokyo Kosei Nenkin Hospital, Tokyo, Japan

Key Words

Ureterosciatic hernia · Endourology · Retrograde pyelography

Abstract

Ureterosciatic herniation, the protrusion of the hernia sac through the sciatic foramen, is an extremely rare cause of ureteral obstruction. We describe a case revealed by severe left back pain in a 72-year-old female. She was referred to our hospital for urological assessment of left hydronephrosis observed by ultrasonography. Intravenous ureterography (IVU) showed findings compatible with a left sciatic ureter, a dilated ureter with a fixed kinking, which is known as the 'curlicue' sign. We decided to attempt recovery of the herniated ureter using a retrograde approach. Ureteral stent placement was performed to decompress the dilated upper urinary tract. The ureterosciatic hernia was relieved with the passage of a flexible guide wire and a double-pigtail stent. Three months after ureteral stenting, she refused continuing to have an indwelling stent and the stent was removed. Thereafter, IVU revealed recurrent ureterosciatic hernia; however, there was no hydroureter or hydronephrosis. The patient is currently being under observation for 6 years after stenting and continues to be without hydronephrosis or symptoms. Placement of an internal stent possibly provides the rigidity to the ureter, thereby reducing the hernia and urinary obstruction. In the previous reports, most symptomatic patients have been treated surgically, with conservative therapy reserved for asymptomatic patients. For the patient who is elderly or a poor surgical candidate, retro-

Tomonori Kato, MD, PhD
Department of Urology, Graduate School of Medicine and
Pharmaceutical Sciences for Research, University of Toyama
2630 Sugitani, Toyama-shi, Toyama 930-0194 (Japan)
E-Mail jpn3899kato@yahoo.co.jp

grade stenting may provide safe reduction and efficacious treatment. This endourological approach provides a minimally invasive means for the management of urinary obstruction caused by ureterosciatic herniation.

© 2014 S. Karger AG, Basel

Introduction

Ureterosciatic herniation is an extremely rare cause of ureteral obstruction. Sciatic herniation is the protrusion of the hernia sac through the sciatic foramen. Patients with symptomatic sciatic hernias commonly present with flank, abdominal, pelvic, lower back or thigh pain. Most asymptomatic patients have been treated conservatively, while surgery has been reserved for symptomatic patients. We describe a case revealed by left hydronephrosis with severe left back pain in a 72-year-old female. This case shows that minimally invasive endourological techniques may provide a novel method for relieving this cause of obstruction.

Case Presentation

A 72-year-old female accidentally struck her left forechest 2 months before she was referred to our hospital, and lower left rib fracture was observed on X-ray examination. Her past medical history included hypertension for 30 years and diabetes for 4 years. She was suffering from severe left-sided back pain, which was thought to be apart from the rib fracture site, and the pain was intermittent. The ultrasound sonography demonstrated left hydronephrosis and a simple renal cyst on the lower pole of the left kidney, and urinalysis showed microhematuria. Subsequently, she was referred for urological assessment of severe left flank pain. Routine blood tests were not remarkable except for a slightly elevated serum glucose level of 179 mg/dl.

Intravenous ureterography (IVU) showed findings compatible with a left sciatic ureter, a dilated ureter with a fixed kinking, which is known as ‘curlicue’ sign (fig. 1). The ureter distal to the kink was not well visualized.

The abdominal CT showed marked hydronephrosis and hydroureter on the level of the pelvic inlet and revealed the presence of a sciatic herniation of the ureter (fig. 2). The ureter was seen to course behind the left hip and through the greater sciatic foramen, anterior to the piriformis muscle. No evidence of inflammatory lesions, compressive tumor or herniation of another pelvic organ with the ureter was seen.

We decided to attempt recovery of the herniated ureter using a retrograde approach. Retrograde pyelography demonstrated hydronephrosis with ‘curlicue’ formation of the distal ureter (fig. 3a). Subsequently, the placement of ureteral stent was performed to decompress the dilated upper urinary tract. Interestingly, the ureterosciatic hernia was relieved with the passage of a flexible guide wire and a double-pigtail stent (fig. 3b–d). The patient noted that the back pain experienced before stent placement completely resolved.

Three months after stenting, we intended to exchange the stent. However, the patient refused continuing to have an indwelling stent and the stent was removed. Thereafter, she was followed by a periodic checkup using ultrasonography and IVU. IVU obtained 3 months after the removal of the ureteral stent revealed the recurrence of the ureterosciatic hernia; however, there was no evident recurrence of hydroureter, hydronephrosis or ureteral obstruction. Since then, abdominal sonography has not shown recurrence of hydronephrosis. The patient is asymptomatic and refuses further intervention but is currently followed

with observation. Six years after ureteral stenting, the patient continues to be without hydronephrosis, symptoms or the usage of the indwelling ureteral stent.

Discussion

Herniation of the ureter is relatively rare. Most ureteral herniations occur in the inguinal area but they have also been noted in femoral, sciatic, thoracic, and parailiac locations. Among them, uretersciatic herniation is extremely uncommon; only 31 cases have been reported since 1947 [1–15].

The clinical symptoms are nonspecific, consisting of ill-defined abdominal pain. Patients may have nonurologic complaints including vague abdominal pain or symptoms more typical of small-bowel obstruction [9]. When obstructive uropathy develops, patients with uretersciatic hernias may or may not experience symptoms of renal colic [3].

The diagnosis is difficult to establish by physical examination because uretersciatic hernias are deep to the gluteal muscles. However, these hernias may be detected as a palpable mass located underneath the gluteal muscles in a thin patient [4, 9].

Sciatic herniation is the protrusion of the sac through the sciatic foramen. The left ureter is affected more often than the right ureter. Bilateral herniation with acute renal failure is also reported [14]. Anatomically, most ureteral herniations such as ureteroinguinal and ureterofemoral hernias are paraperitoneal, since they are adherent to the posterior parietal peritoneum and hence associated with a herniating peritoneal sac [5]. In contrast, uretersciatic hernias are always extraperitoneal [8]. Structures such as small intestine, Meckel's diverticulum, omentum, colon, ovary, fallopian tube, bladder, and ureter may be found in sciatic hernia sacs [3–6].

In uretersciatic herniation, prolapse of the ureter occurs through the sciatic notch, which is divided by the sacrospinous ligament into the greater and lesser sciatic foramina [4]. The greater sciatic foramen is considered a potential space, as the piriformis muscle completely occupies the greater sciatic foramen. The greater sciatic foramen is bound by the ilium laterally, the sacrum and sacrotuberous ligament medially, and the sacrospinous ligament inferiorly. The greater sciatic foramen is further subdivided into the suprapiriformis and infrapiriformis compartments by the piriformis muscle [6].

Uretersciatic herniations usually occur through the suprapiriformis compartment of the greater sciatic foramen [5, 10]. Previous reports have suggested that atrophy of the piriformis muscle is the predisposing factor for the development of uretersciatic herniation, creating a potential space through which the ureter could migrate [7]. It has been speculated that the main predisposing factor could be piriformis muscle atrophy, related to hip joint disease, neuromuscular disorders or other locomotor disturbances of the lower extremities [4–7, 9]. Although most hernias occur through the greater sciatic foramen, several ones have been reported to herniate through the lesser sciatic foramen [2, 5, 8, 9]. These cases are usually undiagnosed clinically because the gluteus maximus muscle overlies the sciatic foramen.

Diagnosis has primarily been based on radiographic studies, such as IVU or CT. Sciatic ureter has a characteristic radiologic appearance in which a loop of ureter is displaced laterally, inferiorly, and posteriorly through the sciatic notch on IVU and retrograde urography. The diagnosis was confirmed by this image, known as the 'curlicue' sign, which is considered pathognomonic for uretersciatic herniation [2]. Uretersciatic hernia does not always induce ureteral obstruction. In our patient, recurrent sciatic ureter had not been associated with hydroureter or hydronephrosis.

CT may be helpful in diagnosis with the appearance of an ectopically positioned ureter posterior and lateral to the ischial spine [6], it can demonstrate an ureter with more anatomic information, and it may be useful in detecting the involvement of other structures [6, 12]. Moreover, CT with three-dimensional reconstruction might be useful for defining the exact location and extent of the herniation [12].

In previous reports, treatments for symptomatic patients included relief of the hernia by excision and reimplantation, ureteroureterostomy or stent placement and observation [2, 8].

In our patient, conservative endourological correction was performed. After the spontaneous removal of the ureteral stent, recurrent ureterosciatic hernia occurred. However, the patient continues to be without hydronephrosis and asymptomatic. Placement of an internal stent possibly provides the rigidity to the ureter, thereby recovering the hernia and urinary obstruction. The patient is currently being under strict observation. Observation should be used judiciously because the consequences of long-term obstruction can be devastating.

Indeed, ureterosciatic hernia causing intermittent ureteral obstruction and producing significant morbidity should be repaired. Furthermore, when the ureter shows signs of inflammation or trophic disturbances, ureterolysis, reimplantation, and hernioplasty should be carried out [1–4, 8, 10]. Surgical options include excision of the hernia with reimplantation of the remaining ureter, reduction of the ureter length, and transabdominal or transgluteal surgical reduction of the hernia plus fixation of the ureter [2, 4, 8]. Recently, laparoscopic and robotic repair surgery has also been reported [10, 15]. However, surgical repair should not be performed in asymptomatic patients [11].

For the patient who is elderly or a poor surgical candidate, retrograde stenting may provide safe reduction and an efficacious treatment. Sugimoto et al. [13] also reported a case successfully treated by ureteral stent placement. It is advisable to place a stent for few months and then remove it to see whether the obstruction recurs. This approach provides a minimally invasive means for the treatment of what can be a devastating problem.

References

- 1 Lindbom A: Unusual ureteral obstruction by herniation of ureter into sciatic foramen: report of a case. *Acta Radiol* 1947;28:225–226.
- 2 Beck WC, Baurys W, Brochu J, et al: Herniation of the ureter into the sciatic foramen ('curlicue ureter'). *JAMA* 1952;149:441–442.
- 3 Franken EA Jr, Smith EE: Sciatic hernia: report of three cases including two with bilateral ureteral involvement. *AJR Am J Roentgenol* 1969;107:791–795.
- 4 Lebowitz RL: Ureteral sciatic hernia. *Pediatr Radiol* 1973;1:178–182.
- 5 Pollack HM, Popky GL, Blumberg ML: Hernias of the ureter: an anatomic-roentgenographic study. *Radiology* 1975;117:275–281.
- 6 Spring DB, Vandeman F, Watson RA: Computed tomographic demonstration of ureterosciatic hernia. *AJR Am J Roentgenol* 1983;41:579–580.
- 7 Stockle M, Muller SC, Riedmiller H: Ureterosciatic hernia: a rare cause of pyonephrosis. *Eur Urol* 1989;16:463–465.
- 8 Rommel FM, Boline GB, Huffnagle HW: Ureterosciatic hernia: an anatomical radiographic correlation. *J Urol* 1993;150:1232–1234.
- 9 Epner SL, Lautin EM: Case report: intermittent sciatic herniation of the ureter. *Clin Radiol* 1994;49:832–833.
- 10 Gee J, Munson L, Smith JJ 3rd: Laparoscopic repair of ureterosciatic hernia. *Urology* 1999;54:730–733.
- 11 Weintraub JL, Pappas GM, Romano WJ, Kirsch MJ, Spencer W: Percutaneous reduction of ureterosciatic hernia. *AJR Am J Roentgenol* 2000;175:181–182.
- 12 Loffroy R, Bry J, Guiu B, Dubruille T, Michel F, Cercueil JP, Krause D: Ureterosciatic hernia: a rare cause of ureteral obstruction visualized by multislice helical computed tomography. *Urology* 2007;69:385.e1–e3.
- 13 Sugimoto M, Iwai H, Kobayashi T, Morokuma F, Kanou T, Tokuda N: Ureterosciatic hernia successfully treated by ureteral stent placement. *Int J Urol* 2011;18:716–717.

- 14 Whyburn JJ, Alizadeh A: Acute renal failure caused by bilateral ureteral herniation through the sciatic foramen. *Urology* 2013;81:e38–e39.
- 15 Singh I, Patel B, Hemal AK: Robotic repair of a rare case of symptomatic ‘Ureterosciatic Hernia’. *Indian J Urol* 2013;29:136–138.

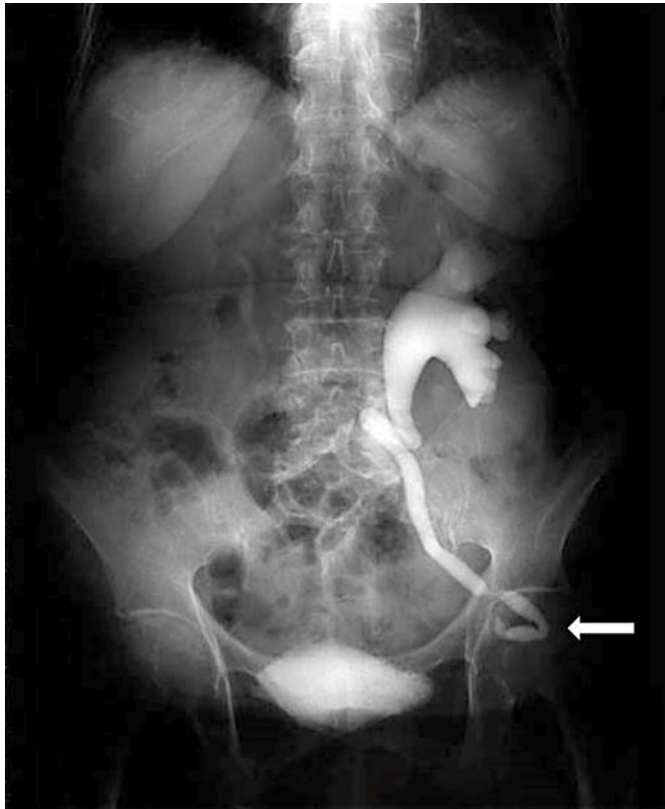


Fig. 1. IVU showed findings compatible with a sciatic ureter, a dilated left ureter with a fixed kinking. The diagnosis was confirmed by this image, known as the ‘curlicue’ sign, which is considered pathognomonic for ureterosciatic herniation.

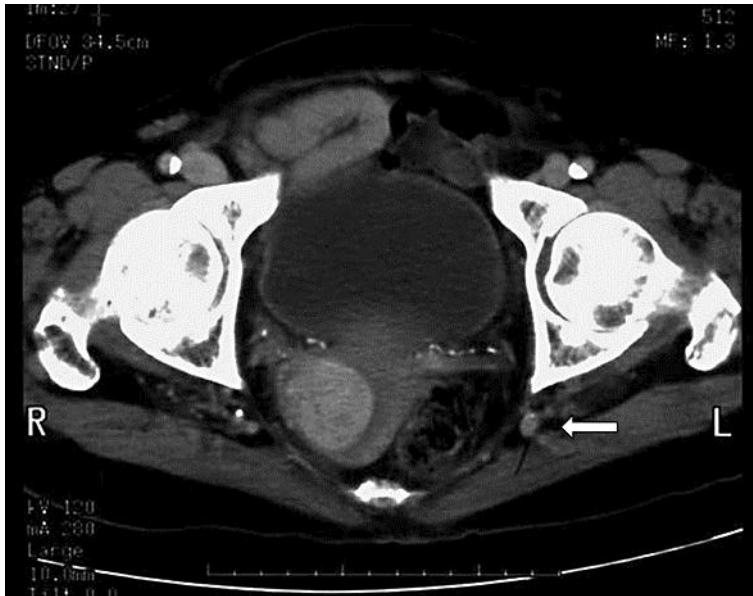


Fig. 2. Axial CT scan of the pelvis showing marked hydroureter on the level of the sciatic notch and the passage of the left ureter through the greater sciatic foramen posterior to the ischium, consistent with sciatic ureter.

Kato et al.: Minimally Invasive Endourological Techniques may Provide a Novel Method for Relieving Urinary Obstruction due to Ureterosciatic Herniation

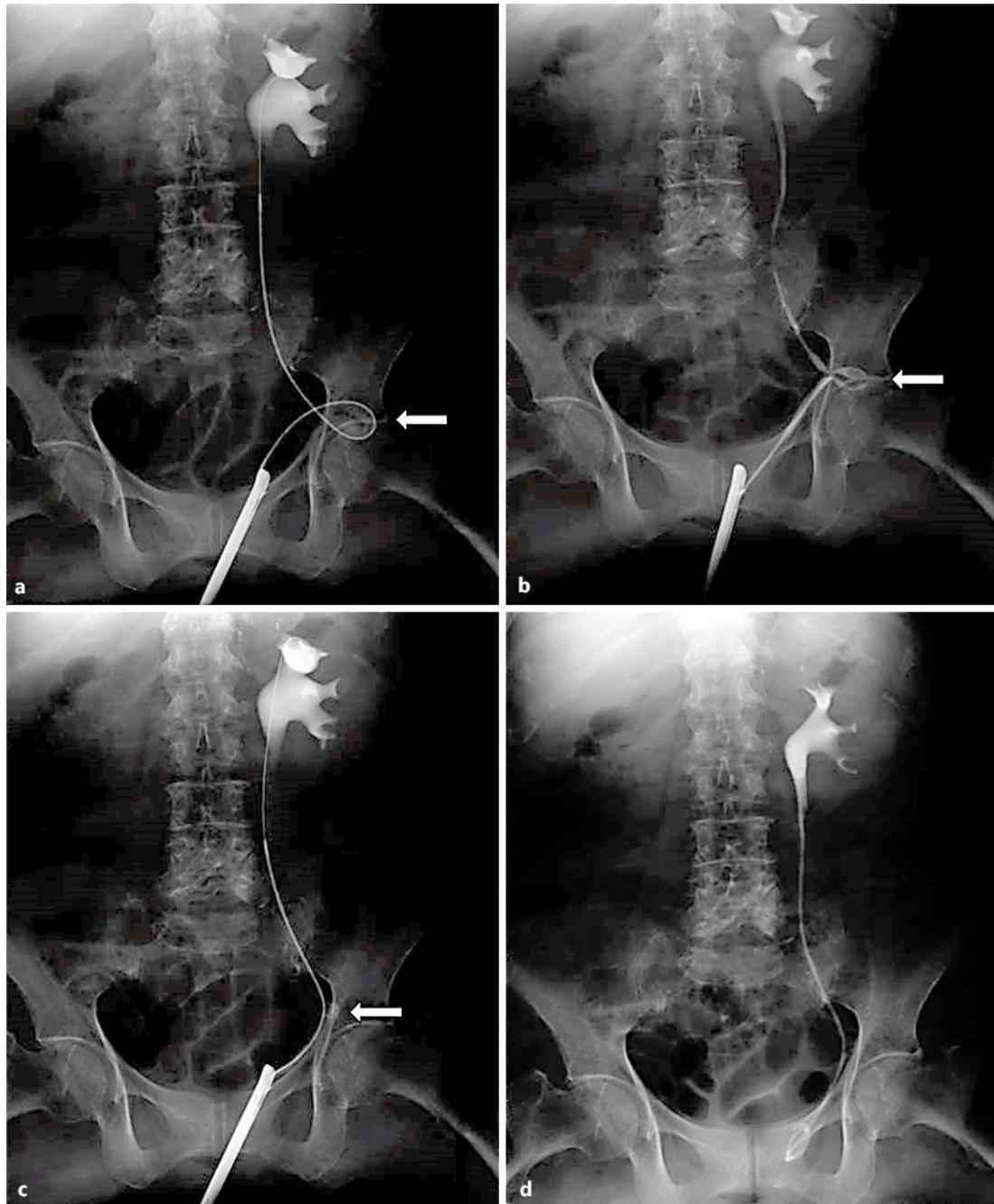


Fig. 3. **a** Retrograde pyelogram showing curlicue formation as the left ureter passes into the sciatic notch, demonstrating left ureterosciatic hernia. **b–d** The ureterosciatic hernia was relieved with the passage of a flexible guide wire and a double-pigtail ureteral stent.