

Impression Cytology in Eyes with Clinical and Confocal Scan Features of Acanthamoeba Keratitis

Mozhgan Rezaei Kanavi^{1,2}, MD; Bagher Hosseini², MD; Fatemeh Javadi³
Nasser Rakhshani^{2,4}, MD; Mohammad-Ali Javadi^{2,5}, MD

¹Ocular Tissue Engineering Research Center, Shahid Beheshti University of Medical Sciences, Tehran, Iran

²Central Eye Bank of Iran, Tehran, Iran

³Medical Student, Shahed University of Medical Sciences, Tehran, Iran

⁴Department of Pathology, Gastrointestinal and Liver Disease Research Center, Iran University of Medical Sciences, Tehran, Iran

⁵Ophthalmic Research Center, Shahid Beheshti University of Medical Sciences, Tehran, Iran

Purpose: To report impression cytology findings in specimens obtained from eyes with clinical and confocal microscopic features of Acanthamoeba keratitis (AK).

Methods: In this interventional case series, impression cytology was obtained from corneas of patients with clinical and confocal microscopic features indicative of AK. Specimens were stained with Periodic acid-Schiff/Papanicolaou (PAS/PAP) and examined for the presence of PAS-reactive Acanthamoeba cysts and/or hyperchromatic pear-shaped trophozoites. All specimens were then decolorized and re-stained with calcofluor white (CFW) for the presence of chemofluorescent cysts.

Results: Fifty-six eyes of 50 patients with mean age of 25.5±9.3 (range, 17 to 78) years were evaluated. Forty-one (82%) cases were female and 51 (91.1%) eyes had history of contact lens wear. PAS-reactive Acanthamoeba cysts and/or hyperchromatic pear-shaped trophozoites were identified in 53 eyes (94.6%), 2 of which demonstrated only trophozoite-like structures. CFW staining was able to reveal the presence of chemofluorescent cysts in all 51 specimens (91.1%) in which cysts had been demonstrated with PAS/PAP staining. Trophozoites were not detected with CFW due to background staining of the cellulose acetate strip used for impression cytology.

Conclusion: Corneal impression cytology, stained with PAS/PAP or with CFW, successfully detects Acanthamoeba and can be employed for early noninvasive diagnosis of AK.

Keywords: Impression Cytology; Confocal Scan; Acanthamoeba Keratitis

J Ophthalmic Vis Res 2013; 8 (3): 207-212.

Correspondence to: Mzhgan Rezaei Kanavi, MD. Associate Professor of Ophthalmology. Ocular Tissue Engineering Research Center, No 23, Pajdarfarad St., Boostan 9 St., Pasdaran Ave., Tehran 16666, Iran; Tel: +98 21 2258 5952, Fax: +98 21 2259 0607; e-mail: rezaeikanavi@gmail.com

Received: June 9, 2012

Accepted: November 27, 2012

INTRODUCTION

Acanthamoeba are ubiquitous free-living protozoans that can cause potentially serious keratitis in contact lens wearers,¹ and in others with a history of corneal trauma, contact with dirty water and exposure to leaf juice or bird

seed dust.^{2,3} The incidence of Acanthamoeba keratitis (AK) varies with geographical region and has been reported from 0.33^{4,5} to 1 in 10,000 soft contact lens wearers per year,⁶ however, recent studies have indicated an increasing trend in the incidence of AK worldwide.⁷⁻⁹ The clinical features of AK may lead to confusion with other

types of keratitis, such as herpes simplex, fungal or bacterial keratitis. Early suspicion and timely diagnosis of AK is necessary to prevent the devastating consequences of this infection and to obtain more favorable visual outcomes.^{1,10}

Invasive methods such as corneal scrapings or biopsy for microbiology, histopathology and polymerase chain reaction (PCR), and noninvasive techniques such as confocal microscopy and impression cytology have been employed for diagnosis of AK.^{1,11-13} Microbiologic cultures can be taken from 2 days to 2 weeks to yield positive results; true positive results range from 0% to 68%.⁸ Confocal microscopy is a rapid noninvasive diagnostic tool with high sensitivity and specificity^{11,14} which reveals hyper-reflective cyst-like structures and high-contrast irregular wedge-shaped features of *Acanthamoeba* within the cornea.¹⁵

Impression cytology is a simple and fairly rapid method that takes less than 2 hours for preparation and microscopic examination.¹⁶ Impression cytology stained with Periodic acid-Schiff/Papanicolaou (PAS/PAP) has been reported in small case series for diagnosis of AK in corneas with superficial involvement.^{12,17} Calcofluor white (CFW) is a chemofluorescent dye used for rapid diagnosis of amoebic cysts in corneal scrapings and paraffin-embedded corneal tissues.^{18,19}

To the best of our knowledge, CFW staining has not been used for detecting *Acanthamoeba* cysts on impression cytology specimens and there is no study on the results of impression cytology in eyes with both clinical and confocal microscopic features of AK. The current study was conducted to evaluate the results of impression cytology specimens stained with PAS/PAP and CFW in eyes with clinical and confocal microscopy features consistent with AK.

METHODS

This interventional case series was approved by the Ethics Committee at the Ophthalmic Research Center and informed consent was obtained from all subjects. Patients with both clinical and confocal microscopic features

indicative of AK were included for the purpose of this study. These included: 1) a high clinical suspicion such as history of contact lens wear, presence of keratoneuritis, ring infiltrates, geographic epitheliopathy, nummular infiltrates and an unusually painful keratitis; 2) Typical confocal scan (Confoscan 3.4, Nidek Co. Ltd., Gamagori, Japan) findings^{11,14} including high contrast round to oval-shaped structures with bi-layered, coffee-bean, or target-shaped appearance measuring 10-25 μm in diameter, within the corneal epithelium and/or stroma (Fig. 1A), and/or large irregular wedge-shaped, highly refractile structures (Fig. 1B).

Impression cytology was performed by an ophthalmologist/ophthalmic pathologist (MRK). After topical anesthesia with 0.5% tetracaine eye drops (Sina Darou Laboratories Company, Tehran, Iran), the site of corneal involvement was determined by slit lamp biomicroscopy, the eyelids were kept opened by an assistant and excess moisture was gently cleaned from the conjunctival surface with a cotton swab. Next, a 5×5mm precut cellulose acetate filter paper (47mm, pore size 0.45 μm , Schleicher & Schuell Microscience GMBH, Dassel, Germany) was applied to the affected area of the cornea and gentle pressure was applied for a few seconds. The filter paper was carefully peeled off the corneal surface and fixed in a cytology fixative containing glacial acetic acid, formaldehyde, distilled water and ethyl alcohol in 1:1:6:14 volume ratio.

After staining with PAS/PAP,¹⁶ these filter papers were cleared in xylene and mounted on glass slides using a DPX mountant. Simultaneously, one slide from a normal goblet

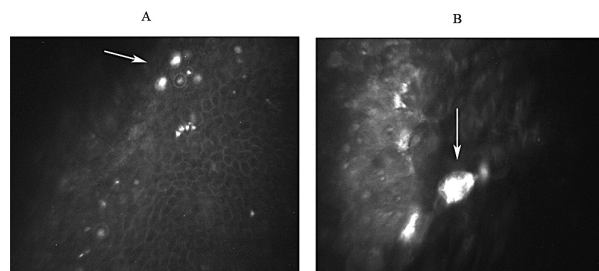


Figure 1. Confocal scan images ($\times 500$) of *Acanthamoeba* keratitis: A, Note the hyper-reflective cysts (arrow) with a bilayered appearance. B, High contrast irregular pear-shaped trophozoite (arrow) in the corneal epithelium.

cell-containing conjunctiva was stained as the positive control. The specimens were examined by another ophthalmic pathologist (BH) under bright field microscopy (Olympus BX43, Olympus Corporation, Tokyo, Japan) for the presence of PAS-reactive *Acanthamoeba* cysts, or hyper-chromatic irregular or pear-shaped trophozoites, the results were then confirmed by another pathologist (NR), who was masked to the study.

After recording the microscopic findings and taking photomicrographs, all impression cytology specimens which had been stained with PAS/PAP were decolorized and re-stained with CFW for the presence of chemofluorescent cysts or bright red-orange trophozoites¹⁹ using a fluorescent microscope (Olympus IX71/U-RFL-T/U-LH100HG, Olympus Corporation, Tokyo, Japan) equipped with ultraviolet light plus excitation and suppressing filters. This stage of the examination was performed by an ophthalmic pathologist (MRK) who was unaware of the results of the PAS/PAP-stained specimens. A tissue section of a cornea with characteristic amoebic cysts on histopathology was considered as a positive control for CFW staining.

Finally the frequency and percentage of *Acanthamoeba* cysts and trophozoites in impression cytology specimens stained with PAS/PAP and CFW were calculated.

RESULTS

Fifty-six eyes of 50 patients with mean age of 25.5 ± 9.3 (range, 17 to 78) years including 41 (82%) female subjects were enrolled. Six patients had bilateral corneal involvement. Fifty-one (91.1%) eyes had history of contact lens usage. Fifty-three eyes from 48 patients had superficial involvement with AK. Deep stromal involvement was observed in three eyes from 2 patients; one eye from one patient had a severe epithelial defect. All eyes were successfully sampled for impression cytology.

Fifty-three out of 56 eyes (94.6%) with clinical and confocal scan features of AK had positive impression cytology, based on demonstration of PAS-reactive *Acanthamoeba* cysts (Figures 2A

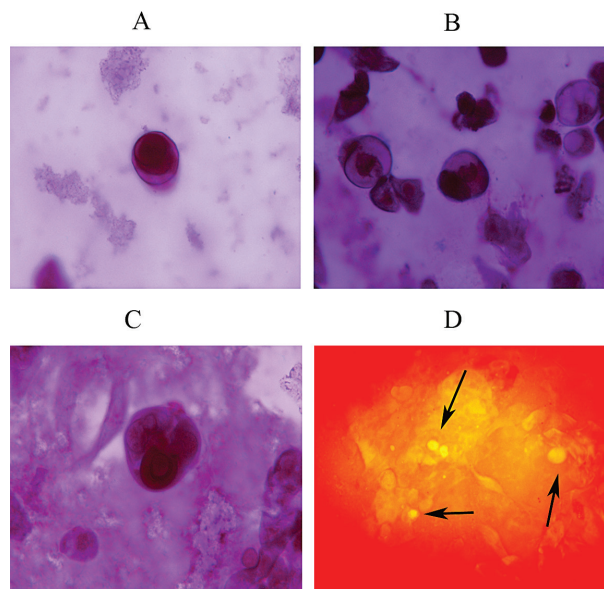


Figure 2. Impression cytology (Periodic acid-Schiff/Papanicolaou (PAS/PAP) stain, magnification $\times 1000$) from corneas with clinical and confocal scan findings indicative of *Acanthamoeba* keratitis: A, PAS-reactive oval-shaped *Acanthamoeba* cyst. B, Variable-sized PAS-reactive cysts. C, PAS-reactive and hyperchromatic wedge-shaped trophozoites larger than cysts D, Chemofluorescent amoebic cysts (arrows) shown with calcofluor white staining in a decolorized PAS/PAP-stained impression cytology specimen that had PAS-reactive *Acanthamoeba* cysts (magnification $\times 400$).

and 2B) and/or hyperchromatic irregular or pear-shaped trophozoites (Fig. 2C). Fifty-one out of 53 positive impression cytology specimens had *Acanthamoeba* cysts; such structures were not observed in the remaining 2 specimens which only showed hyper-chromatic irregular and pear-shaped trophozoites.

Re-staining of the impression cytology specimens with CFW, despite background staining of the cellulose acetate strips, confirmed the presence of chemofluorescent amoebic cysts (Fig. 2D) in all 51 specimens which had PAS-reactive *Acanthamoeba* cysts. In the two specimens which had only demonstrated trophozoites-like structures with PAS/PAP staining, CFW failed to reveal the trophozoites due to background staining of the cellulose acetate strip. Of those 3 cases (5.4%) in which impression cytology had not revealed *Acanthamoeba*, despite an adequate specimen, no cysts or trophozoites were observed in CFW.

Interestingly, impression cytology demon-

strated *Acanthamoeba* cysts and trophozoites in the 3 eyes with deep stromal involvement. In the case of the eye with marked epithelial defect, *Acanthamoeba* cysts and trophozoites were successfully found amongst the inflammatory cells and cell debris on impression cytology.

DISCUSSION

The current study demonstrated a high yield of *Acanthamoeba* (94.6%) by impression cytology whether stained with PAS/PAP or CFW in eyes with clinical and confocal scan features of AK, as compared to a 77% positive rate for PCR and 48% positive results for histopathology, in a confocal microscopic study of corneal epithelial biopsy specimens suspected of being positive for *Acanthamoeba*.¹³ Impression cytology may therefore be appropriate in centers where confocal microscopy and PCR techniques are unavailable and may substitute more invasive corneal biopsy techniques. Impression cytology can be easily implemented in all major ophthalmologic centers with a pathology department.

Corneal scraping is an invasive method to obtain biopsy specimens for histopathologic studies, microbiologic culture and PCR. Microbiologic cultures take some time to prove positive, with variable positive results. PCR has been introduced as an alternative to standard microbiologic tests for AK,¹³ it is relatively faster than histopathology and culture methods, but requires overnight incubation at -20°C and is not available in all laboratories. However, impression cytology in which the first layer or the 2 outermost layers of the corneal epithelium are removed²⁰ is a rapid and relatively noninvasive method for diagnosis of AK. The method is cost effective and eliminates the need for large epithelial scrapings which cause ocular pain.

Limitations of impression cytology include the demand for an expert pathologist or ophthalmic pathologist to conduct proper staining for cytopathologic diagnosis, and the possibility of insufficient sampling whilst obtaining the specimen due to keratitis-induced pain, photophobia and tearing. However, none of our impression cytology specimens were inadequate; keeping the eyelids open

during sampling and gentle clearing of excess moisture from the ocular surface are key points for obtaining a sufficient impression cytology specimen.

Swada et al¹² and Barros et al¹⁷ introduced an impression cytology technique for the diagnosis of AK with superficial corneal involvement early in the disease process. However, it has not been verified that *Acanthamoeba* actually depart from the ocular surface in favor of a less accessible stromal bed in an untreated eye.¹⁴ Our study demonstrated the presence of *Acanthamoeba* cysts and trophozoites within the corneal epithelium on impression cytology in three eyes with deep stromal involvement. We believe that despite the invasion of the organisms into deep stromal layers, clusters of cysts and trophozoites may still remain within the epithelium.

The purpose of CFW staining in our study was to confirm the results of a modified PAS/PAP staining in impression cytology specimens. To the best of our knowledge, CFW has not been employed for the diagnosis of amoebic cysts in impression cytology specimens. This staining method, by revealing chemofluorescent cysts in all impression cytology specimens that had previously shown PAS-reactive *Acanthamoeba* cysts, confirmed the results of PAS/PAP staining in our study. None of the specimens that were negative with modified PAS/PAP were positive with CFW.

Staining with CFW was not of any help in detecting *Acanthamoeba* trophozoites in impression cytology specimens and did not provide additional yield as compared to the modified PAS/PAP stain. Therefore, although CFW can be a simple, rapid and highly reliable method for diagnosis of *Acanthamoeba* cysts in impression cytology specimens, it seems logical to use the modified PAS/PAP in such cases which is as an easy and inexpensive staining method not requiring fluorescent microscopy. *Acanthamoeba* trophozoites were not detectable with CFW due to the presence of background staining of the filter paper interfering with their identification. CFW stains cellulose fibers of the cellulose acetate strips and results in background staining.^{18,21} In such cases, the use of Millicell-CM (hydrophilic polytetrafluoroethylene)

membranes (Millipore, Millipore Corporation, Bedford, USA) instead of cellulose acetate filter papers may be associated with less background staining. This observation requires further investigation.

In summary, impression cytology is a noninvasive method with a high positive yield which can be used alone or as an adjunct for early diagnosis of AK. To the best of our knowledge, there is no report on impression cytology in patients with both clinical and confocal microscopic findings of AK and this study demonstrated a high positive rate for impression cytology in such cases. We employed CFW for the first time to confirm the presence of Acanthamoeba cysts in impression cytology specimens; however it did not improve the results over the modified PAS/PAP staining method.

Acknowledgement

We thank Kefayat Roshanagh-Mohammadi for providing technical support contributing to this work.

Conflicts of Interest

None.

REFERENCES

- Abbott RL, Zegans M, Elander TR. Acanthamoeba keratitis. In: Tasman W. Foundations of Duane's clinical ophthalmology 2004; Volume 4, Chapter 18A, Lippincott Williams & Wilkins, on CD Rom.
- Sharma S, Garg P, Rao GN. Patient characteristics, diagnosis, and treatment of non-contact lens related Acanthamoeba keratitis. *Br J Ophthalmol* 2000;84:1103-1108.
- Syam P P, Narendran R, van der Hoek J. Persistent Acanthamoeba keratitis in a non-contact lens wearer following exposure to bird seed dust. *Br J Ophthalmol* 2005;89:388-389.
- Hammersmith KM. Diagnosis and management of Acanthamoeba keratitis. *Curr Opin Ophthalmol* 2006;17:327-331.
- Seal DV. Acanthamoeba keratitis update- incidence, molecular epidemiology and new drugs for treatment. *Eye* 2003;17:893-905.
- Schaumberg DA, Snow KK, Dana MR. The epidemic of Acanthamoeba keratitis: where do we stand? *Cornea* 1998;17:3-10.
- Tanhehco T, Colby K. The Clinical Experience of Acanthamoeba Keratitis at a Tertiary Care Eye Hospital. *Cornea* 2010;29:1005-1010.
- Patel DV, Rayner S, McGhee CN. Resurgence of Acanthamoeba keratitis in Auckland, New Zealand: a 7-year review of presentation and outcomes. *Clin Experiment Ophthalmol* 2010;38:15-20.
- Thebpatiphat N, Hammersmith KM, Rocha FN, Rapuano CJ, Ayres BD, Laibson PR, et al. Acanthamoeba keratitis: a parasite on the rise. *Cornea* 2007;26:701-706.
- Claerhout I, Goegebuer A, Van Den Broecke C, Kestelyn P. Delay in diagnosis and outcome of Acanthamoeba keratitis. *Graefes Arch Clin Exp Ophthalmol* 2004;42:648-653.
- Kanavi MR, Javadi M, Yazdani S, Mirdehghan S. Sensitivity and specificity of confocal scan in the diagnosis of infectious keratitis. *Cornea* 2007;26:782-786.
- Sawada Y, Yuan C, Huang AJ. Impression cytology in the diagnosis of Acanthamoeba keratitis with surface involvement. *Am J Ophthalmol* 2004;137:323-328.
- Mathers WD, Nelson SE, Lane JL, Wilson ME, Allen RC, Folberg R. Confirmation of confocal microscopy diagnosis of Acanthamoeba keratitis using polymerase chain reaction analysis. *Arch Ophthalmol* 2000;118:178-183.
- Tu EY, Joslin CE, Sugar J, Booton GC, Shoff ME, Fuerst PA. The relative value of confocal microscopy and superficial corneal scrapings in the diagnosis of Acanthamoeba keratitis. *Cornea* 2008;27:764-772.
- Parmer DN, Awwad ST, Petroll WM, Bowman RW, Mc Culley JP, Cavanagh HD. Tandem scanning confocal corneal microscopy in the diagnosis of suspected Acanthamoeba keratitis. *Ophthalmology* 2006;113:538-547.
- Tseng SC. Staging of conjunctival squamous metaplasia by impression cytology. *Ophthalmology* 1985;92:728-733.
- Barros Jde N, Mascaro VL, Lowen M, Martins MC, Foronda A. Diagnosis of Acanthamoeba corneal infection by impression cytology: case report. *Arg Bras Oftalmol* 2007;70:343-346.
- Wilhelmus KR, Osato MS, Font RL, Robinson NM, Jones DB. Rapid diagnosis of Acanthamoeba keratitis using calcofluor white. *Arch Ophthalmol* 1986;104:1309-1312.
- Silvany RE, Luckenbach MW, Moore MB. The rapid detection of Acanthamoeba in paraffin-embedded

- sections of corneal tissue with calcefluor white. *Arch Ophthalmol* 1987;105:1366-1367.
20. Puangsricharern V, Tseng SC. Cytologic evidence of corneal diseases with limbal stem cell deficiency. *Ophthalmology* 1995;102:1476-1485.
21. Sutphin JE, Robinson NM, Wilhelmus KR, Osato MS. Improved detection of oculomycosis using induces fluorescence with Cellufluor. *Ophthalmology* 1986;93:416-417.