

An operating room employee with a necrotic fingertip

Janna S. E. Ottenhoff,^{1,*} Geert P. Voorn,² Bart J. M. Vlamincx,² Philip G. Juten¹ and Gertjan H. J. Wagenvoort²

CASE SUMMARY

A 50-year-old, male, operating room employee presented with a swollen and painful left index finger and progressive lymphangitis on his left arm (patient A). Despite self-usage of antipyretics (paracetamol) and amoxicillin/clavulanate, prescribed by his general practitioner 1 day before presentation, he developed rigors.

The symptoms started 2 days after assisting an open repair of a ruptured abdominal aortic aneurysm in a 73-year-old male (patient B).

Vital parameters of patient A at first presentation were within the normal range: temperature 37.9 °C, blood pressure 121/78 mm Hg and pulse rate 90 bpm. The results for laboratory tests performed on admission were notable for a white blood cell (WBC) count of 18.4×10^9 cells l^{-1} (reference, $2.5\text{--}8.2 \times 10^9$ cells l^{-1}) with 90.9% neutrophils, and a CRP of 86 mg l^{-1} (reference, <10 mg l^{-1}). Physical examination revealed a swollen and necrotic fingertip of the left index finger (Fig. 1a). Flexion was limited, and palpation of the tendon at the mid phalanx was painful. Examination of the left arm revealed lymphangitis on the dorsoradial side of the under- and upper arm, reaching up to the left axilla (Fig. 1b). Intravenous treatment with benzylpenicillin and clindamycin was initiated. Exploration of the index finger by incision revealed transparent serous fluid but no pus. A sample was obtained for Gram staining and culture.

In patient B, Gram staining of the aortic thrombus revealed Gram-stain-positive cocci in chains, confirming the diagnosis of a mycotic aneurysm. Cultures obtained from blood and the mycotic thrombus were found to be positive (Fig. 1c).

DISCUSSION

Correct Answer: 3. Needlestick-injury-mediated transmission of *Streptococcus pyogenes*.

The symptoms of patient A started 2 days after a needlestick injury while assisting during an operation. The needle,

QUESTION

What was the underlying cause of infection and lymphangitis of patient A?

ANSWER OPTIONS

1. Erysipeloid infection following needlestick-injury-mediated transmission of *Erysipelotrix rhusiopathiae*.
2. Sporotrichosis (*Sporothrix schenckii* infection) following a rose prick injury while gardening.
3. Needlestick-injury-mediated transmission of *Streptococcus pyogenes*.
4. Transmission of *Staphylococcus aureus* owing to contamination in the operating room.

which hit his left index finger, had been used earlier for stitching the mycotic aneurysm of patient B.

Cultures obtained from blood and from the mycotic thrombus of the aneurysm in patient B revealed *Streptococcus pyogenes*, which was also isolated from the wound cultures of patient A. The group A streptococcal (GAS) strains of patients A and B were indistinguishable in antibiotic susceptibility pattern (penicillin-, erythromycin-, clindamycin- and trimethoprim-susceptible and doxycycline-resistant), emm-type (emm 8.3 – rarely found) and molecular genetic typing, using amplification fragment length polymorphism (AFLP) analysis. These findings suggest a rarely described case of needlestick-injury-mediated transmission of invasive group A streptococcal disease.

After intravenous treatment with benzylpenicillin and clindamycin, the physical signs and lab values of patient A progressively improved. The wound of his index finger, however, remained necrotic and was left for demarcation to heal per secundam. Patient A was discharged with amoxicillin prescribed orally for an additional week. Follow-up after 3 weeks revealed a dry, necrotic plaque without signs of

Received 11 November 2017; Accepted 9 January 2018

Author affiliations: ¹Department of Plastic Surgery, St. Antonius Hospital, P.O. Box 2500, 3430 EM Nieuwegein, The Netherlands; ²Department of Medical Microbiology and Immunology, St. Antonius Hospital, Nieuwegein, The Netherlands.

***Correspondence:** Janna S. E. Ottenhoff, jsottenhoff@gmail.com

Keywords: needlestick injury; Streptococcus group A; mycotic aneurysm; lymphangitis; bacterial infection; intravenous benzylpenicillin.

Abbreviation: GAS, group A streptococcal.

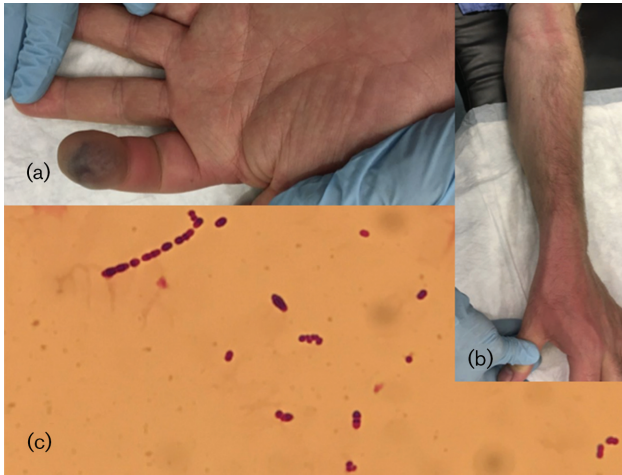


Fig. 1. (a) Patient A: swollen and necrotic left index fingertip; (b) Patient A: lymphangitis of the left arm; (c) Patient B: Gram-stain-positive cocci in chains.

infection. Patient B was successfully treated with a 6-week course of intravenous benzylpenicillin.

Transmission of GAS strains has caused death in many women owing to puerperal sepsis. High mortality rates after childbirth owing to puerperal sepsis decreased rapidly when Semmelweis instituted hand washing in his obstetric clinic in 1847 [1]. Nowadays, GAS still causes severe invasive infections, which can progress rapidly and requires aggressive therapy. A recent review of the literature shows fatality rates of 15 % in cases with invasive GAS infection [2].

Transmission of GAS strains to healthcare workers has been described following cardiopulmonary resuscitation and following necropsy [3, 4]. The transmission of GAS strains following needlestick injury is rare and only two previous cases have been published. The first case describes GAS-transmission that resulted in necrotizing fasciitis after inserting a central venous catheter in a septic patient [5].

The second documented case is similar to the case described here: a surgeon developed rigors and lymphangitis within 36 hours after injury by a medical instrument used to treat a patient with GAS infection [6]. These cases illustrate the potential risk of GAS transmission and serious infections associated with needlestick injuries in healthcare workers. The risks of HIV, B and hepatitis C transmission are well recognized, as opposed to the risk of GAS transmission. Healthcare workers should be aware of this risk after blood-contaminated injuries involving an index patient with GAS infection. Rapid recognition and aggressive treatment of invasive GAS infection is of great importance to prevent development of this severe disease.

Funding information

The authors received no specific grant from any funding agency.

Conflicts of interest

The authors declare that there are no conflicts of interest.

Ethical statement

Written informed consent for publication was obtained from the participant.

References

1. Anderson BL. Puerperal group A streptococcal infection: beyond Semmelweis. *Obstet Gynecol* 2014;123:874–882.
2. Meakle R, Saavedra-Campos M, Lamagni T, Usdin M, Coelho J *et al*. Household transmission of invasive group A *Streptococcus* infections in England: a population-based study, 2009, 2011 to 2013. *Euro Surveill* 2017;22. doi:10.2807/1560-7917.ES.2017.22.19.30532.
3. Valenzuela TD, Hooton TM, Kaplan EL, Schlievert P. Transmission of 'toxic strep' syndrome from an infected child to a firefighter during CPR. *Ann Emerg Med* 1991;20:90–92.
4. Hawkey PM, Pedler SJ, Southall PJ. *Streptococcus pyogenes*: a forgotten occupational hazard in the mortuary. *Br Med J* 1980;281:1058. Available from www.bmj.com/cgi/reprint/281/6247/1058.pdf %5Cnhttp://www.bmj.com/content/281/6247/1058.1.full.pdf.
5. Hagberg C, Radulescu A, Rex JH. Necrotizing fasciitis due to group A *Streptococcus* after an accidental needle-stick injury. *N Engl J Med* 1997;337:1699.
6. Corti G, Bartoloni A, von Hunolstein C, Scopetti F, Buonomini MI *et al*. Invasive *Streptococcus pyogenes* infection in a surgeon after an occupational exposure. *Clin Microbiol Infect* 2000;6:170–171.

Five reasons to publish your next article with a Microbiology Society journal

1. The Microbiology Society is a not-for-profit organization.
2. We offer fast and rigorous peer review – average time to first decision is 4–6 weeks.
3. Our journals have a global readership with subscriptions held in research institutions around the world.
4. 80% of our authors rate our submission process as 'excellent' or 'very good'.
5. Your article will be published on an interactive journal platform with advanced metrics.

Find out more and submit your article at microbiologyresearch.org.