

Small Dysplastic Congenital Melanocytic Nevi in Childhood as Possible Melanoma Imitators

Georgi Tchernev^{1,2*}, Anastasiya Atanasova Chokoeva³, Ivan Terziev⁴, Yavor Grigorov⁵, Torello Lotti⁶, Uwe Wollina⁷, José Carlos Cardoso⁸, Irina Yungareva¹, Ilija Lozev⁹, Georgi Konstantinov Maximov²

¹Medical Institute of Ministry of Interior (MVR), Department of Dermatology, Venereology and Dermatologic Surgery, Sofia, Bulgaria; ²"Onkoderma" - Polyclinic for Dermatology and Dermatologic Surgery, Sofia, Bulgaria; ³Medical University Plovdiv, Dermatology and Venereology, Vasil Aprilov 15A, Plovdiv 4000, Bulgaria; ⁴Universitetska mnogoprofilno bolnitsa za aktivno lechenie Tsaritsa Yoanna, Common and Clinical Pathology, Sofia, Bulgaria; ⁵University Hospital Lozenetz - Department of Orthopedics and Traumatology, Sofia, Bulgaria; ⁶University G. Marconi of Rome, Dermatology and Venereology, Rome, Italy; ⁷Städtisches Klinikum Dresden - Department of Dermatology and Allergology, Dresden, Sachsen, Germany; ⁸Dermatology Department, Coimbra Hospital and University Center, Praceta Mota Pinto, Coimbra, Portugal; ⁹Medical Institute of Ministry of Interior (MVR-Sofia), Department of Dermatology, Venereology and Dermatologic Surgery, Sofia, Bulgaria; *Correspondence: Georgi Tchernev, Department of Dermatology, Venereology and Dermatologic Surgery, Medical Institute of Ministry of Interior (MVR-Sofia), General Skobelev 79, 1606 Sofia, Bulgaria; georgi_tchernev@yahoo.de

Abstract

Citation: Tchernev G, Chokoeva AA, Terziev I, Grigorov Y, Lotti T, Wollina U, Cardoso JC, Yungareva I, Lozev I, Maximov GK. Small Dysplastic Congenital Melanocytic Nevi in Childhood as Possible Melanoma Imitators. Open Access Maced J Med Sci. 2018 Jan 25; 6(1):149-151. <https://doi.org/10.3889/oamjms.2018.018>

Keywords: Nevi; Small congenital nevi; Surgical approach; Melanoma imitators; Treatment; Melanoma; Histopathological evaluation

***Correspondence:** Georgi Tchernev. Department of Dermatology, Venereology and Dermatologic Surgery, Medical Institute of Ministry of Interior (MVR-Sofia), General Skobelev 79, 1606 Sofia, Bulgaria; Onkoderma - Polyclinic for Dermatology, Venereology and Dermatologic Surgery, General Skobelev 26, 1606, Sofia, Bulgaria. E-mail: georgi_tchernev@yahoo.de

Received: 06-Aug-2017; **Revised:** 27-Oct-2017; **Accepted:** 29-Oct-2017; **Online first:** 13-Jan-2018

Copyright: © 2018 Georgi Tchernev, Anastasiya Atanasova Chokoeva, Ivan Terziev, Yavor Grigorov, Torello Lotti, Uwe Wollina, José Carlos Cardoso, Irina Yungareva, Ilija Lozev, Georgi Konstantinov Maximov. This is an open-access article distributed under the terms of the Creative Commons Attribution-NonCommercial 4.0 International License (CC BY-NC 4.0)

Funding: This research did not receive any financial support

Competing Interests: The authors have declared that no competing interests exist

Small pigmented lesions in children can represent a significant diagnostic challenge. If the diagnostic features and therapeutic approach are relatively well established in large and giant nevi, there is still much controversy regarding small and intermediate-sized congenital pigmented lesions that can lead to significant diagnostic challenges, both clinically and dermoscopically, and consequently to difficulty in defining the optimal approach in such cases. Although dermoscopy can be useful in the diagnosis of pigmented lesions, the diversity of clinical and dermoscopic features of pigmented nevi in children usually hinder the differentiation between them and melanoma. Histological findings after resection often show surprising results that do not correspond either to the clinical nor the dermoscopic features. With the present case, we want to emphasise the variable natural behaviour of melanocytic lesions in children, which sometimes leads to unnecessary surgical excisions, which should be avoided in pediatric patients.

Introduction

Pigmented lesions in children can provide significant diagnostic challenges [1]. Melanocytic nevi can be present at birth, although in a minority of cases they may not be clinically apparent until one to two years of age, and acquired later in life [1]. Congenital melanocytic nevi (CMN) are classified based on size

and morphologic features [2]. Small CMN is less than 1.5cm in greatest diameter; intermediate CMN is between 1.5 - 10 cm in greatest diameter and large CMN are greater than 20 cm in greatest diameter, while the giant CMN corresponds to a CMN that is greater than 50 cm in diameter [1][2]. Although moles are frequently seen in the pediatric population, fortunately, the general incidence of malignant melanoma in children is low [2]. More than 50 melanocytic nevi, clinically atypical lesions, family

history of melanoma, excessive ultraviolet radiation exposure, fair skin and eyes, and immunosuppression are considered as risk factors for the occurrence of melanoma in childhood [1]. If the risk of melanoma arising in large and giant CMN is approximately 2 - 5% over a lifetime, a significant proportion of this risk is present in the first decade of life [2].

Therefore, it is recommended that large or giant CMN should be referred to an experienced dermatologist and a pediatric surgeon at birth for close follow - up and discussion of the risks and benefits of surgical intervention [2]. Also, if the diagnostic and therapeutic behaviour is well - known in large and giant nevi, small and intermediate congenital pigmented lesions could lead to significant diagnostic challenges, both clinically and dermoscopically [3]. Furthermore, although challenging, proper diagnosis of pigmented lesions in children is essential for the successful clinical outcome, prevention of unnecessary surgical excision and prognosis in general [3].

Case report

An eight-year-old male patient was admitted to the Dermatology department for evaluation of two pigmented lesions, present since birth. There were no comorbidities or medications. No family history of dermatologic diseases was reported by the patient's mother. Clinical examination revealed multiple pigmented lesions, disseminated all over the body. Two of them were larger than the remainder, clinically resembling dysplastic nevi or melanoma. An oval-shaped pigmented macule, with partial induration, measuring 1.5cm, irregularly bordered, with uneven colouration from light to dark brown and black was seen in rima ani (Fig.1 a, b). An oval-shaped dark brown - coloured pigmented macule, measuring 1 cm, was observed in the right scapular area of the back (Fig.1 a, b).

The dermoscopic findings and clinical appearance of both lesions were suspicious for malignant melanoma. An enlarged lymph node was detected on palpation in the right inguinal fold. Laboratory blood tests examination did not reveal any significant abnormalities. The enlarged lymph node was confirmed by ultrasonography, revealing a 7.4/3.3 mm in diameter lymph node in the right inguinal fold, with preserved structure. No additional enlarged lymph nodes were detected in the left inguinal or axillary folds. Abdominal ultrasonography did not reveal any pathological abnormalities. The lesions were surgically removed with elliptic surgical excision under general anaesthesia and safety margins of 0.8cm (Fig. 1 c, d).

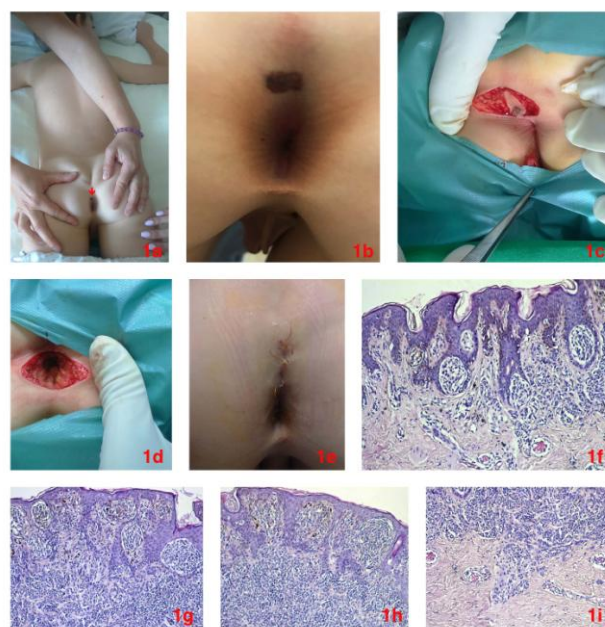

Figure 1: a, b - Clinical presentation of irregularly bordered pigmented lesion, location in rima ani in an 8 - year old male patient, clinically and dermoscopically suspicious for malignant melanoma; c, d – Intraoperative findings. Surgical excision of the lesion; f, g, h, i – Histological findings. Compound melanocytic lesion with the irregular architecture of the junctional component, with mild cytological pleomorphism, lentiginous hyperplasia and variably sized and shaped nests (1f to 1h). However, maturation of the intradermal component is adequate (1i)

Histological examination confirmed the diagnosis of melanocytic nevus in both lesions (Fig. e, f, g, h, i). Systemic antibiotic treatment was initiated in the postsurgical period, due to the enlarged lymph node, which normalised its size in two weeks.

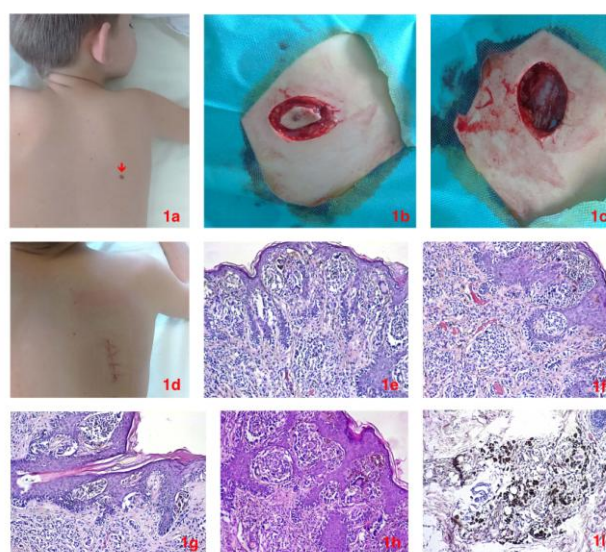


Figure 2: 1a - Clinical presentation of the second suspicious lesion, located on the back of the same patient; 1b, c, d – Intraoperative findings. Surgical excision of the lesion; 1e, f, g, h, i – Histological findings. Similar findings as in panel 1, with irregularity in the architecture of the junctional component, mild cytological pleomorphic and rare scattered suprabasal melanocytes (1e and 1g)

Discussion

Between 1% and 6% of infants are born with a congenital melanocytic nevus and between 2% and 6% of the population have a Congenital Naevus - Like Nevi (CNLN) [2].

It has been postulated that CMN could present in a wide diversity of patterns, forming the concept of so-called "nevus volatility" in childhood, being more likely to both develop new nevi and to have nevi that disappeared during follow - up [2][3]. On the other hand, the concept of "nevus volatility" in children is supported by the clinical and dermoscopic presentation of nevi in children, which is often confusing even for well - trained dermatologists [3]. CMN can first appear as macular lesions with irregular borders, strongly resembling superficial spreading malignant melanoma [3]. The irregular border of most of the nevi in children could be interpreted as a sign of melanocytic progression, which will clinically present as the growth of the nevus [1][2]. In contrast to the irregular border in adolescents, this pattern in children could simply mean that a given nevus is still growing [1][3]. They can be of one colour or multicoloured, from tan to dark brown to black, but most important, nevi in childhood may undergo some changes during the first few years of life [3]. Additional brown macules or papules can develop within the lesion, or the nevus could become infiltrated as a raised plaque [3]. Further confusion could be provided by the changing in nevus' colour - progressively darkening or lightening [4][5]. This often requires surgical excisions as a cautionary measure for these patients. The lack of well-qualified pathologists in the field of dermatopathology often leads to misdiagnosis of melanocytic nevi as melanoma, resulting in unnecessary second excisions, sentinel lymph node biopsies, etc. This stems from the fact that melanocytic lesions in children may exhibit certain features that look worrisome on the microscope to the unwary pathologist, for example, an architectural disorder of the junctional component, upward migration of melanocytes and variable cytological pleomorphism.

In addition to colour variation, congenital melanocytic nevi in children, especially the giant ones, are also more likely to be associated with satellite lesions and benign proliferative nodules within the lesion that can resemble melanoma [3]. All of these clinical diversities give rise to the diversity of dermoscopic patterns, which can also be confusing [4]. Furthermore, although considered as diagnostic tools, which improve the diagnosis in general, algorithms and checklists, such as Menzie's method, the seven-point checklist, pattern recognition, and the ABCD algorithm [2][3] are not so helpful when dealing

with the differential diagnosis between melanocytic nevi and melanoma in children.

Most CMN is characterised by globular or reticular dermoscopic pattern, while overlap of the globular and reticular patterns was seen in less than 2% of nevi [5]. Zalaudek I et al. (2006) have shown that globular pattern and uniform pigmentation predominated in children, while the reticular or homogeneous patterns and central hyperpigmentation was predominantly seen in the group of individuals aged 16 - 30 years [6]. Despite the age, a site-dependent variation of dermoscopic patterns of small and medium congenital melanocytic nevi has also been reported [5].

Although dermoscopy can be useful in the diagnosis of pigmented lesions, the diversity of clinical and dermoscopic features of pigmented nevi in children usually make the distinction between them and melanoma difficult. With the present case, we want to emphasise the variable natural behaviour of melanocytic lesions in children, which sometimes leads to unneeded surgical excisions, which should be avoided in pediatric patients.

References

1. Senthilkumar M, Thappa DM. Melanocytic nevi in children: A clinical study. *Indian J Dermatol*. 2006; 51:26-9. <https://doi.org/10.4103/0019-5154.25184>
2. Rogers T, Marino M, Raciti P, Jain M, Busam KJ, Marchetti MA, Marghoob AA. Biologically distinct subsets of nevi G *Ital Dermatol Venereol*. 2016; 151(4): 365–384. PMID:27119653 PMCID:PMC5445663
3. Scope A, Dusza SW, Marghoob AA, Satagopan JM, Tavoloni G, Braga J, Psaty EL, Weinstock MA, Oliveria AS, Bishop M, Geller AC, Halpern AH. Clinical and dermoscopic stability and volatility of melanocytic nevi in a population-based cohort of children in Framingham school system. *J Invest Dermatol*. 2011; 131(8):1615–1621. <https://doi.org/10.1038/ijd.2011.107> PMID:21562569 PMCID:PMC3136658
4. Scope A, Marghoob AA, Dusza SW, Satagopan JM, Agero AL, Benvenuto-Andrade C, Lieb JA, Weinstock MA, Oliveria SA, Geller AC, Halpern AC. Dermoscopic patterns of naevi in fifth-grade children of the Framingham school system. *Br J Dermatol*. 2008; 158(5):1041-9. <https://doi.org/10.1111/j.1365-2133.2008.08510.x> PMID:18363751
5. Seidenari S, Pellacani G, Martella A, Giusti F, Argenziano G, Buccini P, Carli P, Catricalà C, De Giorgi V, Ferrari A, Ingordo V, Manganoni AM, Peris K, Piccolo D, Pizzichetta M. Instrument-, age- and site-dependent variations of dermoscopic patterns of congenital melanocytic naevi: a multicentre study. *Br J Dermatol*. 2006; 155(1):56-61. <https://doi.org/10.1111/j.1365-2133.2006.07182.x> PMID:16792752
6. Zalaudek I, Grinschgl S, Argenziano G, Marghoob AA, Blum A, Richtig E, Wolf IH, Fink-Puches R, Kerl H, Soyer HP, Hofmann-Wellenhof R. Age-related prevalence of dermoscopy patterns in acquired melanocytic naevi. *Br J Dermatol*. 2006; 154(2):299-304. <https://doi.org/10.1111/j.1365-2133.2005.06973.x> PMID:16433800