



Single Center Experience of the Balloon-Stent Technique for the Treatment of Unruptured Distal Internal Carotid Artery Aneurysms: Sharing a Simple and Reliable Tip to Use Scepter-Atlas Combination

원위내경동맥에 위치한 비파열성 동맥류의 치료에 있어
풍선-스텐트 테크닉에 대한 단일기관의 경험:
Scepter-Atlas 조합을 사용하기 위한 간단하지만
확실한 방법

Yu-jung Park, MD¹ , Jieun Roh, MD^{1*} , Seung Kug Baik, MD¹ ,
Jeong A Yeom, MD¹ , Chul-Hoo Kang, MD² ,
Hee Seok Jeong, MD¹ , Sang Won Lee, MD³

Departments of ¹Radiology and ³Neurosurgery, Pusan National University Yangsan Hospital,
Pusan National University School of Medicine, Yangsan, Korea

²Department of Neurology, Jeju National University Hospital, Jeju National University
School of Medicine, Jeju, Korea

Purpose The balloon-stent technique (BST) has certain strengths as an assisted technique for the treatment of complex aneurysms. After Atlas release, the BST can be executed without an exchange maneuver of the balloon to the stent-delivery catheter. The purpose of this article is to share our experience with the BST using the Scepter-Atlas combination.

Materials and Methods Device inspection led us to a simple method to avoid failure in loading Atlas to the Scepter. From March 2018 to December 2019, 57 unruptured distal internal carotid artery (dICA) aneurysms were treated with coil embolization; among which, 25 aneurysms in 23 patients were treated with BST. Clinical and angiographic data were retrospectively collected and reviewed.

Received June 10, 2020
Revised September 29, 2020
Accepted October 28, 2020

***Corresponding author**

Jieun Roh, MD
Department of Radiology,
Pusan National University
Yangsan Hospital,
Pusan National University
School of Medicine,
20 Geumo-ro, Mulgeum-eup,
Yangsan 50612, Korea.

Tel 82-55-360-1849
Fax 82-55-360-1848
E-mail jieunrohmd@gmail.com

This is an Open Access article distributed under the terms of the Creative Commons Attribution Non-Commercial License (<https://creativecommons.org/licenses/by-nc/4.0>) which permits unrestricted non-commercial use, distribution, and reproduction in any medium, provided the original work is properly cited.

ORCID iDs

Yu-jung Park
<https://orcid.org/0000-0002-0420-3927>
Jieun Roh
<https://orcid.org/0000-0002-6876-3990>
Seung Kug Baik
<https://orcid.org/0000-0001-5408-747X>
Jeong A Yeom
<https://orcid.org/0000-0002-0328-7989>
Chul-Hoo Kang
<https://orcid.org/0000-0002-4176-0941>
Hee Seok Jeong
<https://orcid.org/0000-0002-8459-1260>
Sang Won Lee
<https://orcid.org/0000-0002-3199-7072>

Results The technical success rate of the Scepter-Atlas combination increased from 50% to 100% after careful inspection. BST angiographic results were comparable to the stent-assisted coil (SAC) group treated during the immediately post-embolization same period (modified Raymond-Roy classification [MRRRC] 1 & 2 84% in BST, 96.3% in SAC) and during short-term follow-up (MRRC 1 & 2 95.8% in BST, 88.4% in SAC). A small number of patients showed periprocedural complications, but none had clinical consequences.

Conclusion BST using the Scepter-Atlas combination can provide an effective and safe method for the treatment of dICA aneurysms. Scepters can be used as delivery catheters for Atlas.

Index terms Intracranial Aneurysm; Stent; Endovascular Procedure

INTRODUCTION

Even though it seems that stent-assisted coil embolization (SAC) has been adopted as the main endovascular treatment (EVT) for intracranial wide-neck aneurysms, the balloon remodeling technique (BRT) still has advantages in the stabilization of microcatheters by preventing premature kickback and subsequent undercoiling. BRT followed by stent deployment, so-called balloon-stent technique (BST) may maximize advantage of EVT and achieve better initial and long term radiographic results compared to SAC alone (1, 2). During BRT, unconstrained adjustment and easier repositioning of microcatheter during coil embolization may enhance coil packing whereas conversion from jailing to stent-through technique requires high risk manipulation of microwire and catheter crossing just-deployed metal struts. With BST, by deploying a stent at the last part of the coil packing, very important strengths of SAC can be adopted too: bailout strategy for coil protrusion to the parent artery, potential flow diverting effect, and scaffolding endothelial growth fostering aneurysm healing. Traditionally, BST necessitates manipulation of devices when exchanging a balloon catheter with a stent-delivery catheter. But with introduction of low-profile stents (such as Neuroform Atlas, LVIS Jr., LEO Baby, and ACCLINO Flex), now it is possible to utilize BST without need for catheter exchange, which means in turn, without risk of compromising coil mass shaped as intended or risk of dragging out coils to the parent artery during back-and-forth movement of catheters.

There have been some literatures advocating BST (1-4). Some recent case reports demonstrated the feasibility of BST using a low-profile visualized intraluminal stent (LVIS Jr, Microvention, Tustin, CA, USA) with double lumen balloons in the treatment of middle cerebral artery (MCA) aneurysms (5, 6). A study of Martínez-Galdámez et al. (3) specifically addresses “combined remodeling technique” using various types of low-profile stents available in the market, delivered through double lumen balloons. The article suggests that BST with low-profile stents and double lumen balloons can be safe and effective way to treat intracranial aneurysms, without extra manipulation of catheter exchange.

The Neuroform Atlas™ (Stryker Neurovascular, Fremont, CA, USA) is a relatively new, open-cell stent with characteristics of high conformability for the treatment of aneurysms. Early users have reported its safety and efficacy (7-9). Its biggest advantage over its former versions in the Neuroform family is that it is designed to be delivered through 0.0165- or 0.017-inch micro-

catheters. The inner diameter of compliant double-lumen balloon catheters, Scepter C or XC (Microvention), is also 0.0165 inch. However, the Scepter-Atlas combination is not recommended by both manufacturers, due to possibility of failure to load the stent into the balloon. Probably, that is why Scepter-Atlas combination has not been explored in the literature yet.

At our institution, a high proportion of distal internal carotid artery (dICA) aneurysms have been treated with the BST. We have learned that with a little caution attended while handling the devices, Atlas stent works perfectly well with Scepter balloon catheter. The purpose of this article is to share our technical experience over the Scepter-Atlas combination in treatment of unruptured distal ICA aneurysm, along with immediate and short-term angiographic results of this specific type of BST.

MATERIALS AND METHODS

PATIENTS

From March 2018 to December 2019, a total of 142 intracranial aneurysms were treated with EVT by our neurointervention team in the authors' institution. Among them, we retrospectively sorted out unruptured, dICA aneurysms under 15 mm in size (dICA aneurysms over 15 mm in size were treated with flow diverters). Fifty-seven unruptured dICA aneurysms of 55 patients were identified, 43 female and 12 male patients with mean age of 62 for female patients (range 43–79) and 59 for male patients (range 34–79). Locations of those dICA aneurysms includes 31 paraclinoid ICA, 10 ICA dorsal wall, 9 posterior communicating artery (PCom), 3 anterior choroidal artery (ACho), 2 ophthalmic artery, and 2 cavernous ICA aneurysms. The mean size of the treated aneurysms was 4.7 mm, ranging from 2 mm to 12 mm, and most of them were wide neck aneurysms (45 of 57, 78.9%). For BST group, average size of aneurysms was 4.2 mm (range 2–8 mm), and 88% was wide-neck aneurysm. Patient demographics of all unruptured dICA aneurysms are summarized in the Table 1.

Table 1. Summary of All Unruptured dICA Aneurysms that Underwent Coil Embolization

	Total dICA	Simple	SAC	BST
Total No. of aneurysm (cases)	57 (55)	5	27	25 (23)
Mean age (range)	61.5 (34–82)	66.6 (53–82)	60.1 (34–72)	61.8 (38–79)
Female (%)	43/57 (75.4)	4/5 (80.0)	21/27 (77.8)	18/23 (78.3)
Location				
Paraclinoid	31	3	18	10
Cavernous	2	0	1	1
Ophthalmic	2	0	0	2
PCom	9	1	5	3
ACho	3	1	2	0
Dorsal wall	10	0	1	9
Mean size (range, mm)	4.7 (2–12)	4.5 (3–7)	5.2 (3–12)	4.2 (2–8)
Wide neck (%)	45/57 (78.9)	1/5 (20.0)	22/27 (81.5)	22/25 (88.0)

ACho = anterior choroidal artery, BST = balloon-stent technique, dICA = distal internal carotid artery, PCom = posterior communicating artery, SAC = stent-assisted coil

Decision for mode of EVT in our neurointervention team is made through case-by-case approach, largely based on opinion of an experienced interventional neuroradiologist (more than 20 years of experience), not only considering neck of the aneurysm, but parent vessel environment (atherosclerotic change, angulation of carotid siphon and its distal segment), patient factors (age and co-morbidity), and aneurysm morphology (location, projection, shape, and etc.). One of the most important indication for BST in our team is presumed microcatheter position and its stability based on diagnostic angiography findings. If stable catheter position seems achievable with commercially available pre-shaped microcatheters, simple coiling or SAC is considered as primary method. But unfavorable projections (dorsal wall aneurysms) or curvature of the ICA is present, primary BRT is planned at the beginning of the procedure. At times, catheter stability could not be accurately predicted but it only turned out to be unstable after advance of microcatheters to the aneurysm, then whether to utilize BRT first or proceed straight to stenting was decided at the moment.

Accordingly, 25 aneurysms (in 23 patients) were treated with BST. Other mode of EVT for dICA aneurysms were SAC (27 aneurysms), and simple coil embolization (5 aneurysms). There was no BRT case within same period. High proportion of assisted techniques used in our patient pool (52/57, 91.2%) can be partially explained by high proportion of wide neck aneurysms. Locations of 25 aneurysms managed with BST were as follows: 10 paraclinoid ICA, 9 dorsal wall (supraclinoid ICA with superior or lateral projection), 3 Pcom, 2 ophthalmic artery, and one cavernous ICA.

COIL EMBOLIZATION PROCEDURE

All procedures included in this study were done under local anesthesia, with or without conscious sedation using remifentanyl (0.05–0.2 mcg/kg/min IV). Main operator of those procedures had been either one of the two interventional neuroradiologists working in our team, with three years and more than 20 years of experience, respectively. Senior operator conducted the procedure himself or supervised the junior operator all the time. Systemic heparinization was done with initial bolus IV of 50 U/kg and maintenance dose of 10 U/kg every hour of the procedure, with target active clotting time of 200–300 sec.

Patients were managed during the peri-procedure period as our institution's routine practice, and pre-medicated with oral dual-antiplatelet regimen (100 mg of aspirin and 75 mg of clopidogrel daily) for a week prior to EVT. For patients ended up with stenting, oral antiplatelet medications (100 mg aspirin qd and 75 mg clopidogrel qd) were continued for at least 6 months after embolization, but preferably for 12 months to prevent delayed thromboembolic event. Anti-platelet agent resistance test was performed at the day of the procedure (Verify Now™, Instrumentation Laboratory, Bedford, MA, USA). If the patient were resistant to clopidogrel, it would be replaced with other anti-platelet agent, such as cilostazol. Aspirin was sustained even in resistant patients.

When frank thrombosis noted during embolization or on the final angiography, intra-arterial (IA) tirofiban infusion was done (ranging 0.25–1.25 mg), followed by intravenous (IV) infusion of the drug for the next 24 hours, according to our institution's protocol (0.1 µg/kg/min IV infusion for 24 hours) (10, 11). Some patients received IV infusion of tirofiban even without evidence of frank thrombus formation, when subtle halo was seen along the exposed

portion of coil mass (at the neck of the aneurysm) or stent strut, when flow velocity of incorporated vessel (i.e. Pcom or ophthalmic artery) was compromised, or when the treated aneurysm was incorporated with highly eloquent vessel such as ACho or ophthalmic artery.

DEVICES

For cases of BST, either Scepter C or XC balloon catheters were used for both balloon remodeling and stent-delivery. Twenty-three Neuroform Atlas stents (not counting failed-to-deliver stents), all of them in size of 4.5×21 mm, were used to cover neck of 25 aneurysms (in two patients with two aneurysms nearby, the procedures were started as BRT for both aneurysms and single stent simultaneously covered both at the end). For 27 cases of SAC, 2 Neuroform EZ stents were used and one Atlas with size of 3×15 mm was used in ACho aneurysm in which case the stent was deployed in the ACho to cover neck of aneurysm. In the other 24 SAC cases, Atlas stents in size of 4.5×21 mm were inserted.

During the early experience of Scepter-Atlas combination after release of Neuroform Atlas, our team faced some technical difficulties which is failure to load the stent into the balloon catheter and subsequent deformity of the stent. Photography of the devices used were taken, especially of the Scepter balloon catheters and introducer sheath of the Atlas stent from the failed cases. In the cases we failed to introduce Atlas stents through Scepter, additional microcatheter (Excelsior SL-10, Stryker) was advanced to dICA and stent was deployed with that catheter.

CLINICAL AND ANGIOGRAPHIC DATA

We retrospectively collected imaging and clinical data of patients not only including BST group but all dICA aneurysms treated during the same period. Immediate angiographic results were assessed by one interventional neuroradiologist, according to modified Raymond-Roy classification (MRRC) (12) on the final angiography at the procedure day. For the most of the patients included for analysis, 6-months follow-up angiography were available for analysis of angiographic result (50/55 patients, 90.9%). Of 5 patients without 6-months follow-up study, two patients had 12-months follow-up angiography so those were regarded as short-term result together with those with 6-months imaging. Among the other three patients, two patients were lost for follow-up, and one had only one-year MR angiography (MRA) which was negative for recanalization evidence. But MRA findings were not considered as proper follow-up study on this analysis. Only 4 patients had 2-year follow-up angiography, for those cases had been treated quite recently, so 2-year results were not taken into analysis.

Periprocedural complications and any morbidity or mortality results during the follow-up period were collected, based on the patients' medical records on our institution's electronic medical record system. Our Institutional Review Board approved this retrospective study and waived the requirement of informed consents (IRB No. 05-2021-060). Patient demographics, angiographic results and complication events are going to be displayed in descriptive manner in this article. Comparison between BST group and SAC group was done with Fisher's exact test, using SPSS (IBM SPSS Statistics for Windows, version 26.0. IBM Corp.; Armonk, NY, USA).

RESULTS

SCEPTER-ATLAS COMBINATION

For the first 3 months of our early experience after release of Neuroform Atlas stent, we embolized 6 aneurysms with BST, but failed to put Atlas into Scepter in 50% of cases (3/6). In successful cases, only minor bump was felt when the stent was passing the transition zone from the introducer sheath and the balloon catheter hub, and once the stent was loaded within the balloon, deployment was uneventful and identical to deploying it with compatible microcatheters (Excelsior SL-10, Stryker Neurovascular). But in unsuccessful cases, stents could not be introduced to balloon catheters at all, stents were wrecked in the hub of the balloon when pushed into the balloons. Failure to put Atlas to Scepter did not result in adverse event, except for damaging the device itself, so the balloons were exchanged to SL-10 microcatheters (or retrieved and new microcatheter was advanced) and rest of the procedure went on as usual.

After the initial experience, to address this problem, we carefully inspected the devices used in the failed and successful cases. At first, we reviewed balloon catheters, however, we could not find any structural differences between the failed and successful ones. Balloons used in failed cases did not seem defective, and failure happened in both C and XC balloons.

The authors also looked at the introducer sheaths of failed-to-deliver stents, to figure out whether any mechanical change had occurred, and compared them with the ones used in successful cases. We discovered that there was a dent at the tip of the sheath that might have compromised its inner lumen. The Neuroform Atlas stent is designed to be delivered through 0.0165-inch microcatheters, preferably with the Excelsior SL-10 made by the same manufacturer. Therefore, the morphology of the introducer sheath of the stent delivery system is (probably) optimized to fit into the SL-10 catheter's hub (Fig. 1A).

We tried to apply an intact introducer sheath left out from other procedures to the failed Scepter XC catheter; close-up images were taken when the sheath was in contact with the hub (Fig. 1B) and forced into the hub (Fig. 1C). There is a gap between the tip of the sheath and the starting point of the balloon catheter lumen. Obviously, there is a discrepancy between the diameter at the hub of the Scepter XC catheter and that of the introducer sheath of the Atlas stent. The gap cannot be overcome even under forceful push (to make it fully engaged to the hub), but it only makes the sheath deformed, with dents at the tip (Fig. 2), similar to the dent we observed from failed cases.

On the other hand, if the sheath is not pushed hard enough to create a dent, although there may be a small gap between the catheter and the tip of the sheath, an Atlas stent shall pass the transition zone unbroken. This is probably why the authors noted a slight bump when passing the stent into the Scepter balloon catheter.

After this realization, we have been paying extra attention while loading the stent into the Scepter XC balloon catheter, not pushing the sheath but rather keeping it in contact with the wall of the hub. Since then, 19 aneurysms in 17 patients (with 17 stents, for single stent covered two aneurysms in two patients) have been managed with BST using Scepter-Atlas combination without any problem, regardless of C or XC type. In total, overall technical success rate to deliver Atlas stent through Scepter balloon was 87.0% (20/23). Technical success rate

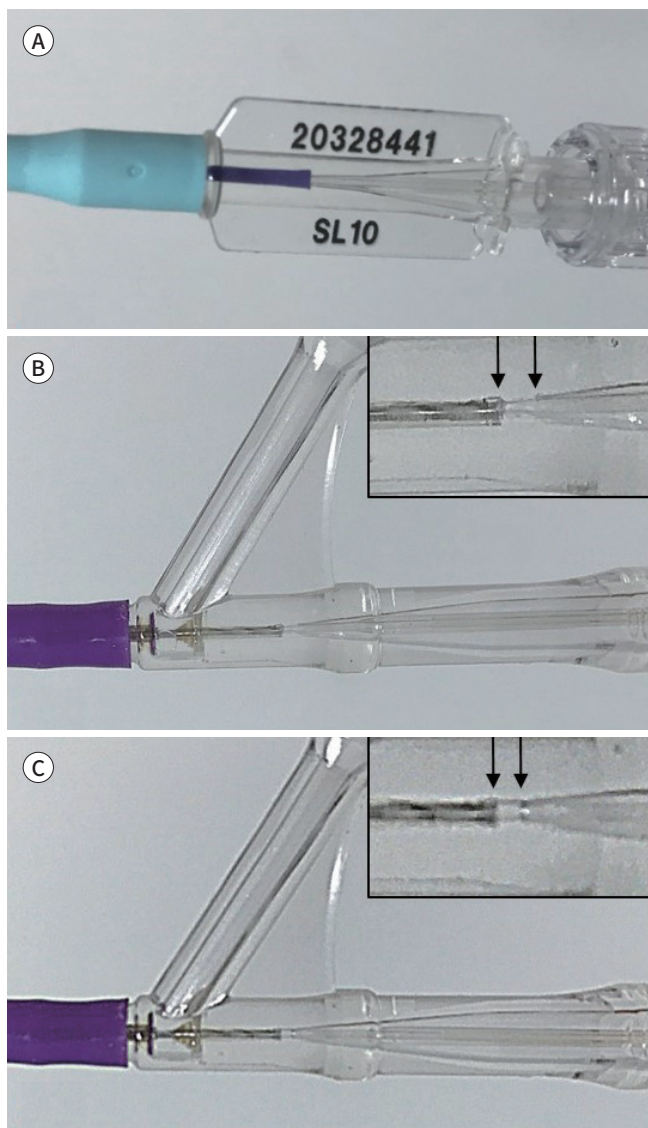


Fig. 1. Photographs of devices demonstrating relationship between microcatheter hub and introducer sheath.

A. Introducer sheath of the Neuroform Atlas stent is engaged into the Excelsior SL-10 microcatheter hub to demonstrate how well it fits in profile compared to Scepter balloon catheters.

B. The same introducer sheath is engaged in the Scepter XC balloon catheter (the very same one that failed during the procedure), and due to disagreement between those and the device structure, a gap occurred between the starting point of the catheter lumen and the tip of the sheath.

C. When the sheath is pushed hard enough to be fully engaged, the tip may become dented, but still, the gap cannot be reduced.

before the petit discovery was only 50%, but it went up to 100% after we figured out how to handle the devices. Ideal position of sheath within the hub we suggest is demonstrated in the Fig. 3.

ANGIOGRAPHIC RESULTS OF BST

At the final angiography taken immediately after BST, 84% (21/25) showed complete (18/25, 72%) or near complete (3/25, 12%) occlusion. During the same period, 91.2% (52/57) of all dICA aneurysms showed complete or near complete obliteration of sac (MRRC 1 & 2) after EVT, and 96% of aneurysms treated with SAC showed same result (26/27). Angiographic results of all unruptured distal ICA aneurysms underwent EVT are summarized in Table 2.

BST group showed slightly higher MRRC 1 & 2 percentage of 95.8% (23/24) on 6–12 months follow-up compared to SAC group (88.4% showed MRRC 1 & 2), but the difference was not statistically significant ($p = 0.870$). Total percentage of complete or near-complete occlusion was

Fig. 2. Photographs of introducer sheath of Neuroform Atlas stent.

The tip of the introducer sheath of the Neuroform Atlas stent is crushed after being forced into the hub of the Scepter XC balloon catheter (left), compared to the normally-delivered introducer sheath (right).

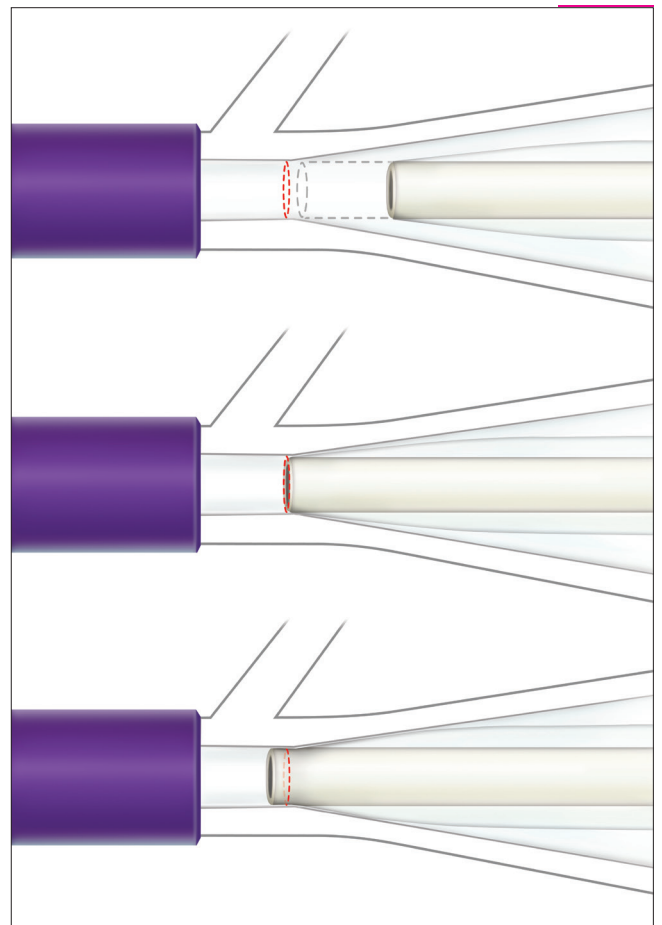



Fig. 3. Schematic illustration of the recommended position for an introducer sheath tip.

Introducer sheath of the Atlas is not yet touching the wall of the Scepter hub. There is a discrepancy between the diameter of the first portion of the catheter lumen and that of the sheath tip (upper). Ideal position of the introducer sheath in the hub (middle). A forceful push of the sheath results in deformation of the introducer sheath tip and subsequent failure to load the stent into the Scepter (lower).

Table 2. Angiographic Results of Unruptured Distal Internal Carotid Artery Aneurysms

	Immediate Post-Embolization	Short-Term Follow-Up (6 m or 12 m DSA)
Total	n = 57	n = 54
MRRC 1	48/57 (84.2)	48/54 (88.9)
MRRC 2	4/57 (7.0)	2/54 (3.7)
MRRC 3a	3/57 (5.3)	0
MRRC 3b	2/57 (3.5)	2/54 (3.7)
Simple coil	n = 5	n = 4
MRRC 1	5/5 (100)	3/4 (75)
MRRC 2	0	1/4 (25)
MRRC 3a	0	0
MRRC 3b	0	0
SAC	n = 27	n = 26
MRRC 1	25/27 (92.6)	22/26 (84.6)
MRRC 2	1/27 (3.7)	1/26 (3.8)
MRRC 3a	0	0
MRRC 3b	1/27 (3.7)	3*/26 (11.5)
BST	n = 25	n = 24
MRRC 1	18/25 (72)	23/24 (95.8)
MRRC 2	3/25 (12)	0
MRRC 3a	3/25 (12)	0
MRRC 3b	1/25 (4)	1 [†] /24 (4.2)

Data are presented as number (%).

*Including two major recanalization and regrowth of the aneurysms.

† Including one major recanalization and regrowth of the aneurysm.

BST = balloon-stent technique, DSA = digital subtraction angiography, m = months, MRRC = modified Raymond-Roy classification, SAC = stent-assisted coil

92.6% for all coiled dICA aneurysms (50/54).

Four lesions that showed residual filling to the aneurysm sac at immediate post-BST (MRRC 3a or b from BST group) spontaneously occluded to MRRC 1 at 6-months follow-up. Three aneurysms with residual neck (MRRC 2) after BST turned into one complete occlusion, one major recanalization and regrowth at first follow-up, and the other one had been lost for follow-up. For the SAC group, immediate near complete occlusion rate was higher than BST, but on short-term follow-up, the rate dropped to 88.4%, with two cases of major recanalization which seemed to require additional treatment.

PERIPROCEDURAL COMPLICATION

In two patients of BST (2/23, 8.7%), IA tirofiban infusion was necessary to resolve frank thrombosis at the parent vessel during the embolization procedure. Those thrombosis were non-obstructive thrombi, and none of those patients experienced focal neurologic symptom or sign. In one patient from BST group, there was no definite thrombosis on angiography but the patient started to complain left upper extremity weakness at the last stage of coil filling, so IA tirofiban was given (0.75 mg) followed by IV infusion for the next 24 hours. The patient's symptom improved by the end of the procedure and immediate post-procedure diffusion

weighted imaging did not show any positive lesion, motor power completely returned to normal at the next day. Those three periprocedural events makes complication rate of (13%), but none of them resulted in clinical consequences.

IV tirofiban was given in many cases for various reasons (16/23, 69.6%), for the first day of the post-procedure (0.1 µg/kg/min IV infusion for 24 hours). Reasons for IV tirofiban infusion were as follows: 1) continued after IA loading dose in frank thrombosis cases (2 cases), 2) continued after IA loading in a patient with left upper extremity weakness without evidence of thrombosis or arterial occlusion (1 case), 3) suspicious halo around stent strut or at the margin of coil mass seen on final angiography (not obvious thrombosis) (1 case), 4) suspicious decrease in flow velocity demonstrated as slowed ophthalmic artery flow or reversal of Pcom flow (2 cases), and 5) highly susceptible environment for thrombosis, i.e. protrusion of coil to the parent artery, large area of coil mass exposed to parent vessel, or highly eloquent incorporating vessel such as ACho (8 cases).

In the patients treated other methods (SAC and simple coil, 32 aneurysms in 32 patients), we experienced four events of intra-procedural complications (12.5%): clinically silent small thrombus formation on angiography in 2 cases (kept stable and symptom-free with IA and IV tirofiban infusion), one M2 occlusion necessitated thrombectomy (discharged without any permanent neurologic deficit), and one coil stretching resulted in additional stent insertion to secure the stretched coil segment with no clinical consequences. None of the patients treated in the same period (total 57 cases of unruptured dICA aneurysms) had thromboembolic event during the follow-up period.

To summarize, among the all 55 patients treated for unruptured dICA aneurysms, there were 4 clinically silent thrombosis (2 BST, 1 SAC, 1 simple coil), one major vessel occlusion without clinical consequence (SAC group), and one transient focal neurology without evidence of arterial occlusion (BST group). There was no technical complication seemed specifically associated with Scepter-Atlas combination.

DISCUSSION

Regardless of mode of procedure, primary and ultimate goal of EVT for intracranial aneurysm is its complete obliteration. Various techniques have been proposed and being practiced, and BRT is known for its paramount advantage in terms of catheter stability. Under temporary inflation and deflation of a balloon, microcatheters barely located at the neck of an aneurysm can transfer coils into the sac even in anatomically most-challenging cases. Also, unconstrained catheter manipulation within the sac is possible, and fewer difficulties noted repositioning catheters (2) which may prevent significant undercoiling. On the contrary, primary stenting may have potential drawbacks, once a jailed microcatheter pushed or kicked out of the sac during coil filling, catheter moving to re-access the sac can be risky at times, either one moves catheters in between arterial wall and stent, or within the lumen of just-now-deployed stent.

BST is often preferred by our team for certain cases, wide-necked aneurysms, unfavorable parent artery curvature, or out-of-plane orientation of sac projection to parent artery course. One of the best candidates for BST is ICA dorsal wall aneurysm (superior or lateral projection

aneurysms located in supraclinoid segment). Percentage of dorsal wall aneurysm in our BST group (9/25, 36%) was much higher than SAC group (1/27, 3.7%), though the difference was not statistically significant ($p = 0.360$) probably owing to small number of cases. One case out of 9 dorsal wall aneurysms embolized with BST resulted in major recanalization and regrowth, but 7 of the other 8 lesions regressed with complete occlusion at the first follow-up (6-months). Fig. 4 illustrates a successful BST case, about 8 mm sized dorsal wall aneurysm with large neck (> 4 mm), complex shaped, and unfavorable projection.

Before Neuroform Atlas was available, we adopted Neuroform EZ stents for BST in many cases of dICA aneurysms, and there was an inconvenient step of exchanging double lumen balloons to stent-delivery catheter (XT-27, Stryker Neurovascular). Scepter-Atlas combination means exchange-free BST. This implies more than merely cutting one step down, because numerous potential problems may occur during the exchange maneuver. There are risks associated with moving of the microcatheter, including degradation or even migration of the coil mass. Therefore, exploring balloon catheters for stent deployment can strengthen the efficacy of the BST with negligible cost.

Not many, but a few articles about BST advocates use of a balloon prior to stent deployment. Spiotta et al. (2) published their single center data retrospectively reviewing 260 intracranial aneurysm patients underwent SAC between 2003 and 2010. In 94 (36.2%) patients 'balloon-stent' technique was facilitated, with immediate complete occlusion of 63% and 79% at follow-up (16 ± 12 months). BST was most likely to be chosen in cases of side-wall aneurysms arising from curved vessels, especially for ophthalmic artery aneurysms, among which 48% (39/80) were treated with BST. This preference toward BST in cases of side-wall aneurysms in unfavorable curvature is also noted in our treatment group.

Gentric et al. (1) reported subgroup data from Safety and Efficacy of Neuroform for Treatment of intracranial Aneurysms (SENAT) registry, including 97 unruptured aneurysm patients treated by stenting combined with or without balloon (51 BRT+ group, 46 BRT- group). In their results, primary BRT group prior to stenting had significantly better angiographic outcome at 12–18 months follow-up ($p = 0.03$), with similar peri-procedural morbidity and mortality.

Another retrospective study by Velasco González et al. (4) demonstrated low rates of recanalization for wide neck aneurysms treated with stenting after BRT, in 87 aneurysms of 80 patients treated between 2009–2012. This relatively old patient pool had long-term follow-up results. Complete (60.9%) or near-complete (32.2%) occlusion were achieved at initial stage, and relatively long-term follow-up (34.68 ± 25.26 months) angiography revealed stability and further thrombosis in 92.4%.

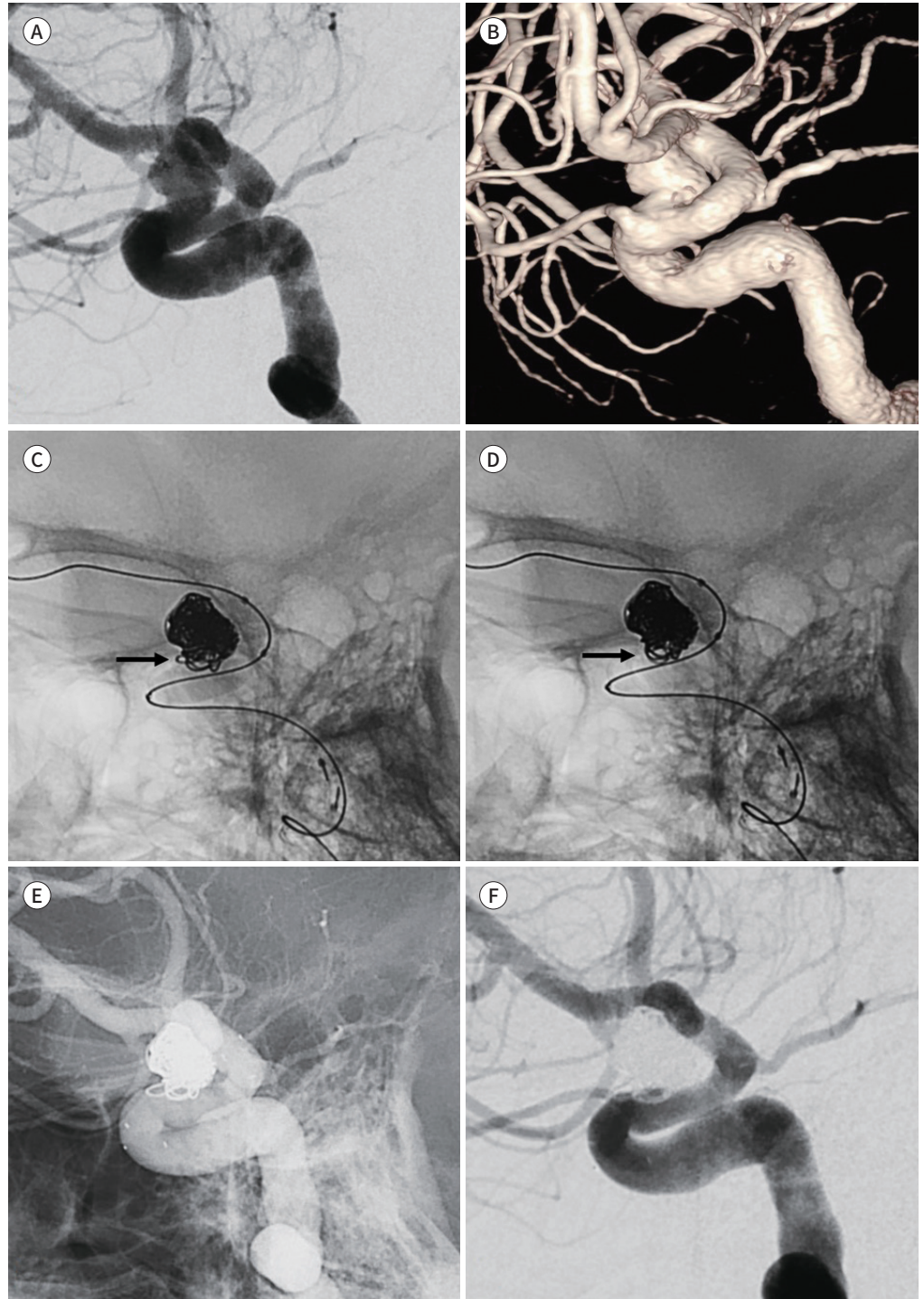
Nowadays, various low-profile stents have become available (eg. Neuroform Atlas, LVIS Jr., LEO Baby, and ACCLINO Flex). Two brief reports presented MCA aneurysms successfully treated using combination of LVIS Jr. and double-lumen balloons, without technical complications (5, 6). Those two reports commonly emphasized the fact that this type of device combination can be useful reducing number of procedure steps and subsequently diminishing potential complications.

The first original article regarding specific use of low-profile stents and double lumen balloon catheters was reported by Martinez-Galdamez et al. (3). In this retrospective multicenter

Fig. 4. An example case of BST. A 57-year-old female patient with an ICA dorsal wall aneurysm, up to 8 mm in its largest dimension, with a wide neck that measured more than 4 mm in diameter.

A-F. The pre-embolization DSA image (**A**) and volume rendering image from rotational angiography (**B**) are shown. Most of the coils were filled under BRT, and the neck portion of coil mass becomes herniated down to the parent vessel (**D**, arrow), compared to its morphology under balloon inflation (**C**, arrow). The final angiography native fill image after stent was deployed through the balloon catheter (**E**). Six-month follow-up DSA (**F**) demonstrates the sac has remained completely occluded.

BST = balloon-stent technique, DSA = digital subtraction angiography, ICA = internal carotid artery



study, 86 aneurysms of 84 consecutive patients (9 ruptured, 62 unruptured, and 15 recanalized aneurysm) from 8 centers from 2015 to 2017 were analyzed. Scepter C or XC and Eclipse 2L double-lumen balloons were used with either LVIS Jr. ($n = 63$), LEO baby ($n = 15$), ACCINO Flex ($n = 14$), or Neuroform Atlas ($n = 1$). Immediate angiographic results were 77.9% of complete and 19.7% of near-complete occlusion, and for those had follow-up at average of 7-months (71/84), complete and near complete occlusion rate was 90.1%. They said there were 2 minor clinical events (2.4%) and one major event (1.2%), and 11.6% of intraprocedural technical complication rate.

Our results of BST seems comparable to those reports (1, 3, 4) in that anatomical results of 95.8% (23/24) near complete occlusion on 6–12 months follow-up, and acceptable spectrum of periprocedural complications. It seems that there is tendency of better angiographic results of BST compared to BRT or SAC, though further accumulation of scientific evidence is needed. It sounds logical that BST shows better outcome than BRT in the long term because it takes advantage of stenting, scaffolding endothelialization over aneurysm neck and subsequently promoting aneurysm healing process. Also, there seems to be certain cases of challenging anatomy which cannot be overcome by simply deploying stent covering the neck, especially in those with unfavorable projections and locations.

Novelty of our report lies in that this is the first article focusing on BST using Scepter and Atlas combination in unruptured dICA aneurysms. The reason why we chose Atlas stents for dICA lesions is its open-cell characteristics and conformability. In principle, better wall apposition of open-cell stent to the parent artery of aneurysms may reinforce scaffolding effect of neointima formation, while minimizing risk of thromboembolic complication, and consequently, maximizing long-term efficacy of stenting. However, providing scientific evidence of which stents works better in BST is beyond the scope of this study.

A valuable finding of our study is that BST using Scepter-Atlas combination may be technically feasible and safe, and angiographic results of BST group for unruptured dICA in our single center pool were comparable to those of SAC, even when BST was applied to more complicated anatomies. Only a small number of patients had intraprocedural complications that did not result in clinical problem.

Another key finding from our experience is successful delivery of the Atlas stent through the Scepter catheter is possible, even though there is a discrepancy in profiles between hub of Scepter and sheath of Atlas. If the operators pay careful attention loading the stent into the catheter following our tips, stents can be introduced into the catheter unharmed. Once the Atlas stent is settled within the catheter, stent deployment is not different from deploying it with any other catheters.

Based on our experience, here are our recommendations for those who are planning to use Scepter as Atlas delivery catheter. First, do not push the introducer sheath into the hub of the Scepter catheter, but only have it in contact with the wall of the hub (Fig. 3). Second, carefully watch the hub under operating light, and hold the introducer sheath steady while advancing the stent into the Scepter. A second operator (who pushes the wire) may feel a minor bump when the stent passes the gap between the tip of the introducer sheath and the first part of catheter lumen.

There are several limitations in our study. Not only small number of patients enrolled

made it difficult to show statistical significance of superiority or non-inferiority of BST compared to SAC, lack of comparison with BRT (due to there was no case of BRT in the pool) also makes it hard to clarify advantage of stenting in BST. Furthermore, it is a single center experience and choice over treatment method was selected on case-by-case basis, directly comparing results of different methods may not play as scientific evidence proving superiority (or non-inferiority) in efficacy and safety of BST. Average size of aneurysms included in this study is small (4.2 mm), and that may partly contribute to good results. Therefore, cautions must be taken when interpreting the results of our BST group, for they are only confined to small, unruptured aneurysms located in dICA. As far as we know, despite our experience, Scepter-Atlas combination is still not recommended by both manufacturers. And lastly, our experience is limited to a single size (4.5×21 mm) of Atlas carried through Scepter balloons and to dICA aneurysm cases.

In conclusion, BST using Scepter-Atlas combination can be an effective and safe method in treatment of unruptured dICA aneurysms, with comparable immediate and short-term angiographic results to SAC and acceptable peri-procedural complication. Scepters can be used as delivery catheters for Atlas when the operators carefully engage the introducer sheath of the stent system into the balloon catheter hub. Acknowledging that the Scepter-Atlas combination is actually possible can be a valuable asset to neurointerventionists, for it helps us to cut down one step of exchange during procedures, thereby maximizing advantages of BST.

Author Contributions

Conceptualization, B.S.K., R.J.; data curation, P.Y., K.C.; formal analysis, P.Y., R.J.; funding acquisition, R.J.; investigation, P.Y., J.H.S., K.C.; methodology, B.S.K., L.S.W.; project administration, B.S.K., Y.J.A.; resources, L.S.W., R.J.; supervision, B.S.K.; visualization, Y.J.A., J.H.S.; writing—original draft, P.Y., R.J.; and writing—review & editing, Y.J.A., R.J.

Conflicts of Interest

The authors have no potential conflicts of interest to disclose.

Funding

This study was supported by a 2018 research grant from Pusan National University Yangsan Hospital.

Acknowledgments

Authors of this article would like to express special thanks to Mijin Jung from MJED Biomedial illustration & Design Company, for creating the illustrations used in figure 3.

REFERENCES

1. Gentric JC, Biondi A, Pötin M, Mounayer C, Lobotesis K, Bonafé A, et al. Balloon remodeling may improve angiographic results of stent-assisted coiling of unruptured intracranial aneurysms. *Neurosurgery* 2015;76:441-445
2. Spiotta AM, Wheeler AM, Smithason S, Hui F, Moskowitz S. Comparison of techniques for stent assisted coil embolization of aneurysms. *J Neurointerv Surg* 2012;4:339-344
3. Martínez-Galdámez M, Orlov K, Kadziolka K, Puthuran M, Kalousek V, Pabón B, et al. Safety and efficacy of intracranial aneurysm embolization using the “combined remodeling technique”: low-profile stents delivered through double lumen balloons: a multicenter experience. *Neuroradiology* 2019;61:1067-1072
4. Velasco González A, Stracke P, Nordmeyer H, Heddier M, Saleme S, Sauerland C, et al. Low rates of recanalization for wide-necked aneurysms treated with stenting after balloon-assisted coiling: combination of techniques delivers stable and improved results during follow-up. *Neuroradiology* 2018;60:1223-1230

5. Spiotta AM, Miranpuri A, Chaudry MI, Turner RD 4th, Turk AS. Combined balloon stent technique with the Scepter C balloon and low-profile visualized intraluminal stent for the treatment of intracranial aneurysms. *J Neurointerv Surg* 2013;5 Suppl 3:iii79-iii82
6. Kadziolka K, Tomas C, Robin G, Pierot L. Combined use of a double-lumen remodeling balloon and a low-profile stent in the treatment of intracranial aneurysms ('remostent' technique): a technical note. *J Neuro-radiol* 2013;40:50-53
7. Cay F, Peker A, Arat A. Stent-assisted coiling of cerebral aneurysms with the Neuroform Atlas stent. *Interv Neuroradiol* 2018;24:263-269
8. Ulfert C, Pham M, Sonnberger M, Amaya F, Trenkler J, Bendszus M, et al. The Neuroform Atlas stent to assist coil embolization of intracranial aneurysms: a multicentre experience. *J Neurointerv Surg* 2018;10: 1192-1196
9. Ten Brinck MFM, De Vries J, Bartels RHMA, Grotenhuis JA, Boogaarts HD. NeuroForm Atlas stent-assisted coiling: preliminary results. *Neurosurgery* 2019;84:179-189
10. Yoon CH, Lee HW, Kim YS, Lee SW, Yeom JA, Roh J, et al. Preliminary study of tirofiban infusion in coil embolization of ruptured intracranial aneurysms. *Neurosurgery* 2018;82:76-84
11. Baik SK, Oh SJ, Park KP, Lee JH. Intra-arterial tirofiban infusion for partial recanalization with stagnant flow in hyperacute cerebral ischemic stroke. *Interv Neuroradiol* 2011;17:442-451
12. Mascitelli JR, Moyle H, Oermann EK, Polykarpou MF, Patel AA, Doshi AH, et al. An update to the Raymond-Roy Occlusion Classification of intracranial aneurysms treated with coil embolization. *J Neurointerv Surg* 2015;7:496-502

원위내경동맥에 위치한 비파열성 동맥류의 치료에 있어 풍선-스텐트 테크닉에 대한 단일기관의 경험: Scepter-Atlas 조합을 사용하기 위한 간단하지만 확실한 방법

박유정¹ · 노지은^{1*} · 백승국¹ · 염정아¹ · 강철후² · 정희석¹ · 이상원³

목적 풍선-스텐트 테크닉(balloon-stent technique; 이하 BST)은 복잡한 동맥류를 치료하는 보조술로서 그 고유한 장점을 가지고 있다. 저자들의 기관에서 Atlas의 출시 이래 Scepter-Atlas 조합의 BST를 치료에 적용해 온 경험을 공유하고자 한다.

대상과 방법 초기에 Atlas를 Scepter 카테터에 진입시키지 못하는 기술적 실패를 겪은 뒤 이를 해결하기 위해 문제가 되었던 기구들을 면밀히 관찰하였다. 2018년 3월부터 2019년 12월까지 총 57개의 비파열성 원위내경동맥 동맥류에 대해 코일 색전술을 시행하였고, 이중 25개(23명)의 증례는 BST로 치료하였다. 포함된 증례들의 영상 및 임상 정보는 후향적으로 수집하고 분석하였다.

결과 이 논문에서 소개하는 간단한 팁을 알게 된 이후 Scepter-Atlas 조합의 기술적 성공률은 50%에서 100%로 상승하였다. BST로 치료한 환자군에서 시술 직후에 84%, 추적검사에서 95.8%가 완전하거나 거의 완전한 폐색을 보였고 stent-assisted coil 그룹에서는 각각 96.3%, 88.4%가 시술 직후와 추적검사에서 같은 결과를 보였다. 소수의 환자에서 합병증을 보였지만 임상적으로 문제가 된 증례는 없었다.

결론 Scepter-Atlas 조합을 이용한 BST는 원위내경동맥에 위치한 비파열성 동맥류를 치료하는 데 효과적이고 안전한 방법이 될 수 있다. Scepter는 Atlas를 매개하는 카테터로 충분히 사용될 수 있다.

부산대학교 의과대학 양산부산대학교병원 ¹영상의학과, ³신경외과,
²제주대학교 의과대학 제주대학교병원 신경과