

Case Report

Acute mitral valve regurgitation causing severe alveolar hemorrhage

Ayaka Sakamoto,¹ Yuki Enomoto,¹ Hiroaki Watabe, Yasuaki Koyama, Yukei Matsumoto, Nobutake Shimojo, Aiki Marushima, Satoru Kawano, and Yoshiaki Inoue

Department of Emergency and Critical Care Medicine, University of Tsukuba Hospital, Tsukuba, Japan

Background: Acute mitral regurgitation could occur without common symptoms like hemodynamic instability, but with dyspnea, hemoptysis, and right-sided infiltration on radiography. We report a case of severe alveolar hemorrhage caused by acute mitral regurgitation, which occurred in the absence of shock.

Case Presentation: A 40-year-old man presented with dyspnea with bloody phlegm and hypoxia, despite being hemodynamically stable. Chest radiography revealed right-sided infiltration, and bronchoscopy showed fresh bloody phlegm in his tracheae. No specific findings were detected with any tests. After treatment with several medications and support with extracorporeal membrane oxygenation, his condition improved, although the etiology of the disease remained unknown. Transthoracic and transesophageal echocardiogram revealed severe mitral valve regurgitation with ruptured mitral chordae tendineae. These suggested that the sudden onset of mitral valve regurgitation had caused severe alveolar hemorrhage.

Conclusion: Severe alveolar hemorrhage, especially with right-sided infiltration on chest radiography, should be considered a symptom of acute mitral regurgitation.

Key words: Extracorporeal membrane oxygenation, hemoptysis, hemorrhage, mitral valve insufficiency, radiography

INTRODUCTION

ACUTE MITRAL VALVE regurgitation (AMR) usually presents with dyspnea, hemodynamic instability, and symptoms of shock.¹ However, cases wherein alveolar hemorrhage is the first symptom of AMR with no cardiogenic shock are rarely reported.²⁻⁶ We report a case of severe alveolar hemorrhage caused by AMR, which occurred in the absence of shock.

CASE REPORT

A 40-year-old man developed sudden-onset dyspnea with bloody sputum. He visited a local hospital a few hours after the onset of symptoms. On examination, he showed orthopnea and hypoxia with SpO₂ of 88% in room air, but was hemodynamically stable with a blood pressure

of 149/86 mmHg. Computed tomography showed the diffuse ground-glass shadow, especially in the right upper lobe. He had no history of any major illness.

On the day of presentation, he was admitted to the intensive care unit and intubated, and mechanical ventilation was induced. Bronchoscopy revealed fresh bloody sputum in his trachea. Because of the unknown etiology of the illness, empirical antibiotics and steroid pulse therapy were given from day 1 with the suspicion of an autoimmune disease or a severe infectious disease. However, his respiratory condition rapidly deteriorated and chest radiography showed a worsening right-sided infiltration (Fig. 1). The PaO₂/FiO₂ ratio decreased to approximately 60. Therefore, the doctor at the local hospital requested assistance from our hospital for induction of veno-venous extracorporeal membrane oxygenation (VV-ECMO) on the day 4 of the patient's admission. When our ECMO team induced VV-ECMO, fresh blood flowed into the tracheal tube, and thus, had to be suctioned continuously. Eventually, chest radiography could not visualize his bronchus because of blood build-up in the lung. On the same day, we transferred the patient to our university hospital while continuing VV-ECMO.

Laboratory findings revealed negative results for autoantibodies, typical bacterial antigens, and viruses, but not for α -streptococcus. Although there were positive results for α -

Corresponding: Yuki Enomoto, MD, Department of Emergency and Critical Care Medicine, University of Tsukuba Hospital, 2-1-1 Amakubo, Tsukuba, Ibaraki 305-8576, Japan. E-mail: enomoto-y@md.tsukuba.ac.jp.

Received 16 Jan, 2020; accepted 4 Mar, 2020

Funding Information

No funding information provided.

streptococcus from pharynx-wiping and bronchial lavage, the result of the bronchial lavage specimen culture was negative, so we did not consider α -streptococcus as the causative bacteria. Moreover, there was no significant elevation of anti-streptolysin O and no arthritis was noted.

Although the cause of the disease had not been ascertained, his respiratory condition gradually improved under VV-ECMO support, with continuous removal of clots by a bronchoscope. On day 15, the patient was successfully weaned off VV-ECMO support. On day 18, alveolar hemorrhage worsened and a second steroid pulse therapy was induced. On day 45, he could be weaned off mechanical ventilation support.

Since his admission to our hospital, systolic murmur had been detected in his chest, and transthoracic echocardiogram revealed mild mitral valve regurgitation (MR) with normal heart function. After being weaned off mechanical ventilation, repeated transthoracic echocardiogram and additional transesophageal echocardiogram showed severe MR with ruptured mitral chordae tendineae (Fig. 2). These findings suggested that the sudden onset of MR might be the cause of the severe alveolar hemorrhage.

Cardiac catheterization on day 49 revealed grade 3 MR according to the Sellers' classification; the pulmonary capillary wedge pressure was 17 mmHg and the cardiac index was 3.11 L/min/m². To reduce the risk of infection, surgery was planned after the natural closure of the tracheostomy. The patient underwent mitral valve annuloplasty and tricuspid annuloplasty on day 151 and achieved full recovery. He

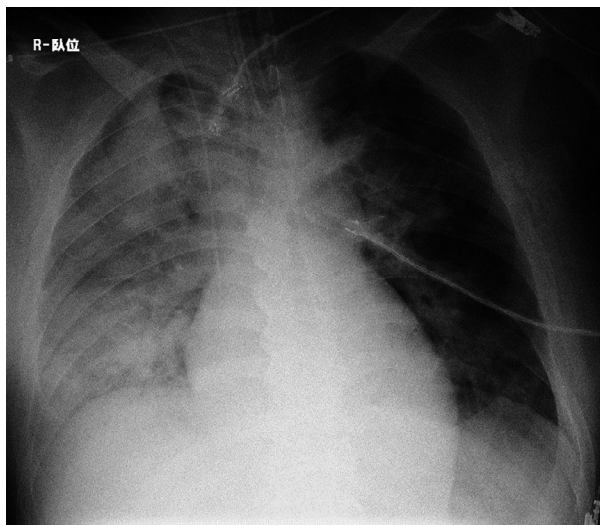


Fig. 1. Chest radiograph of a 40-year-old man with acute mitral valve regurgitation on day 2 of hospitalization. Right-sided infiltration worsened compared to day 1.

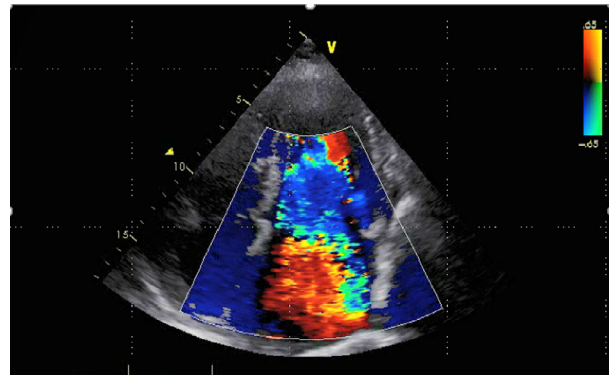


Fig. 2. Transesophageal echocardiogram of a 40-year-old man. Severe mitral valve regurgitation with ruptured mitral chordae tendineae was observed.

was discharged from our hospital on day 168 and has returned to his normal activities.

DISCUSSION

THE PATIENT PRESENTED with unusual symptoms of AMR. Severe alveolar hemorrhage accompanied by massive hemoptysis and acute respiratory failure appeared as the initial symptoms, without signs of cardiogenic shock, which is a common finding in AMR.

Acute mitral valve regurgitation is known to result from chordal rupture, papillary muscle rupture, endocarditis, rheumatic fever with carditis, and other conditions.¹ In AMR cases, the left atrium cannot be adapted to the sudden increase in regurgitant volumes. However, with chronic regurgitation, the left atrial size increases to accommodate for the increased intra-atrial pressure. Acute mitral valve regurgitation is a rare condition and usually presents with acute-onset dyspnea, hemodynamic instability, and symptoms of shock. However, a subset of patients with AMR may solely present with new-onset dyspnea.¹ There are seven reports of alveolar hemorrhage with AMR,²⁻⁸ and among the eight cases, including our case, six showed right-sided infiltration on chest radiography, and in no case was cardiogenic shock a clinical symptom (Table 1). However, massive hemoptysis caused by severe alveolar hemorrhage due to AMR is rarely reported.

Diffuse alveolar hemorrhage (DAH) could be due to various causes, such as localized lung damage (inhalation injuries, diffuse alveolar damage) or systemic disorders (vasculitis, connective tissue disease). Unilateral DAH is rare and is occasionally accompanied by heart failure, clotting disorder, and pneumonia. In a previous report, right-sided DAH was frequently caused by pulmonary congestion resulting from heart failure.⁹

Table 1. Cases of alveolar hemorrhage with acute mitral valve (MV) regurgitation

	Age, years	Sex	Initial symptoms			Laterality of infiltration on chest radiography	Surgical operation	Outcome
			Hemoptysis	Fever [†]	Cardiogenic shock			
Scully, 1995 ⁸	81	F	–	–	–	Left	MV replacement	Recovered
Spence, 2000 ²	49	F	–	+	NA	Right	MV replacement	NA
Kim, 2007 ⁴	38	M	+	–	–	Right	MV repair	Recovered
McNinch, 2007 ⁶	60	M	+	+	–	Right	MV repair and annuloplasty	Recovered
Marak, 2013 ⁷	57	M	+	–	–	Right	MV repair	Recovered
Yeung, 2013 ⁷	50	M	+	+	–	Bilateral	MV repair	NA
Chae, 2015 ⁵	48	M	+	–	–	Right	MV repair	Recovered
Our case	39	M	+	+	–	Right	MV annuloplasty, tricuspid annuloplasty	Recovered

+, present; –, not present; F, female; M, male; NA, not available.

[†]Fever+, ≥37.5°C.

Right-sided pulmonary edema is known to occur with AMR.¹¹ The etiology is related to the reverse flow of MR towards the right pulmonary veins.¹⁰ Unilateral pulmonary edema tends to be misdiagnosed as pneumonia,¹¹ and a misdiagnosis of unilateral alveolar hemorrhage with AMR could also occur.

However, severe alveolar hemorrhage, especially with right-sided infiltration detected on chest radiography, should be considered a symptom of AMR.

ACKNOWLEDGEMENTS

WE WOULD LIKE to thank Editage for language editing.

DISCLOSURE

Approval of the research protocol: N/A.

Informed consent: Informed consent was obtained from the patient.

Registry and the registration no. of the study/trial: N/A.

Animal studies: N/A.

Conflict of interest: None.

REFERENCES

- 1 Stout KK, Verrier ED. Acute valvular regurgitation. *Circulation* 2009; 119: 3232–41.
- 2 Spence TH, Connors JC. Diffuse alveolar hemorrhage syndrome due to “silent” mitral valve regurgitation. *South Med. J.* 2000; 93: 65–7.
- 3 Yeung AW, Lau AC, Shum H *et al.* Diffuse alveolar hemorrhage and intravascular hemolysis due to acute mitral valve regurgitation. *Crit. Care Shock* 2013; 16: 3–7.
- 4 Kim U, Hong G-R, Kim D-H *et al.* Diffuse alveolar hemorrhage due to acute mitral regurgitation. *J. Cardiovasc. Ultrasound* 2007; 15: 16–8.
- 5 Chae WY, Park SJ, Song CW, Lee BH, Kim SH, Lee JH. Massive hemoptysis due to acute mitral regurgitation with sporadic primary mitral valve prolapse. *Korean J. Crit. Care Med.* 2015; 30: 202–6.
- 6 McNinch RW, McNamara MJ. An unusual cause of right upper- and mid-zone infiltrates on chest x-ray. *Crit. Care Resusc.* 2007; 9: 256–8.
- 7 Marak CP, Joy PS, Gupta P, Bukovskaya Y, Guddati AK. Diffuse alveolar hemorrhage due to acute mitral valve regurgitation. *Case Rep. Pulmonol.* 2013; 2013: 179587.
- 8 Scully RE, Mark EJ, McNeely WF, McNeely BU (eds). Case records of the Massachusetts General Hospital. Weekly clinicopathological exercises. Case 17–1995. An 81-year-old woman with mitral regurgitation and a left-upper-lobe pulmonary infiltrate. *N. Engl. J. Med.* 1995; 332: 1566–72.
- 9 Tamai K, Tomii K, Nakagawa A, Otsuka K, Nagata K. Diffuse alveolar hemorrhage with predominantly right-sided infiltration resulting from cardiac comorbidities. *Intern. Med.* 2015; 54: 319–24.
- 10 Lesieur O, Lorillard R, Ha Thi H, Dudeffant P, Ledain L. Unilateral pulmonary oedema complicating mitral regurgitation: diagnosis and demonstration by transoesophageal echocardiography. *Intensive Care Med.* 2000; 26: 466–70.
- 11 Ogunbayo GO, Thambaiyah S, Ojo AO, Obaji A. ‘Atypical pneumonia’: acute mitral regurgitation presenting with unilateral infiltrate. *Am. J. Med.* 2015; 128: e5–6.