

# Spontaneous Regeneration of the Mandible after Hemimandibulectomy: Report of a Case

A. Khodayari<sup>1</sup>, A. Khojasteh<sup>2✉</sup>, MT. Kiani<sup>3</sup>, A. Nayebi<sup>4</sup>, L. Mehrdad<sup>5</sup>, M. Vahdatinia<sup>6</sup>

<sup>1</sup>DMD, MS. Associate Professor; Oral and Maxillofacial Surgery, Program Director, Department of Oral and Maxillofacial Surgery, ShahidBeheshti University of Medical Sciences

<sup>2</sup>DMD, MS. Assistant Professor; Oral and Maxillofacial Surgery, Department of Oral and Maxillofacial Surgery, Head of the Division of Basic Sciences, Dental Research Center, ShahidBeheshti University of Medical Sciences

<sup>3</sup>DMD. Chief Resident; Oral and Maxillofacial Surgery, Department of Oral and Maxillofacial Surgery, ShahidBeheshti University of Medical Sciences

<sup>4</sup>DMD. Senior Resident; Oral and Maxillofacial Surgery, Department of Oral and Maxillofacial Surgery, ShahidBeheshti University of Medical Sciences

<sup>5</sup>DMD. Faculty Member, Department of Oral and Maxillofacial Pathology, Tehran University of Medical Sciences

<sup>6</sup>MD, Resident; General Medical Pathology, Babol University of Medical Sciences

## Abstract:

Mandibular defects may result from many conditions such as trauma, inflammatory diseases and tumors. There are rare cases reported in the literature that have demonstrated spontaneous bone regeneration after resection of the mandible. Several factors such as age, preservation of the periosteum and genetics seem to influence spontaneous bone regeneration capacity in individuals. Evaluation of these factors may lead to a better understanding of the mechanism of spontaneous bone regeneration and also help to create new methods for bone reconstruction. The purpose of this article was to describe the spontaneous regeneration of the hemi-mandible with a well shaped condyle and coronoid after resecting a mandibular pathologic lesion in a young man.

**Key Words:** Bone Formation; Spontaneous; Mandibular Resection

*Journal of Dentistry, Tehran University of Medical Sciences, Tehran, Iran (2011; Vol.8, No.3)*

✉ Corresponding author:  
A. Khojasteh, Assistant Professor, Department of Oral and Maxillofacial Surgery, Head of the division of Basic Sciences, Dental Research Center, ShahidBeheshti University of Medical Sciences, Tehran, Iran  
arashkhojasteh@yahoo.com

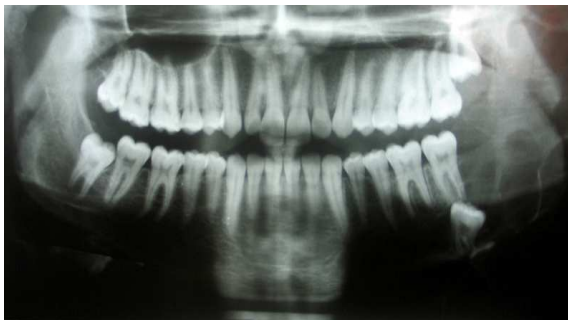Received: 25 April 2011

Accepted: 21 July 2011

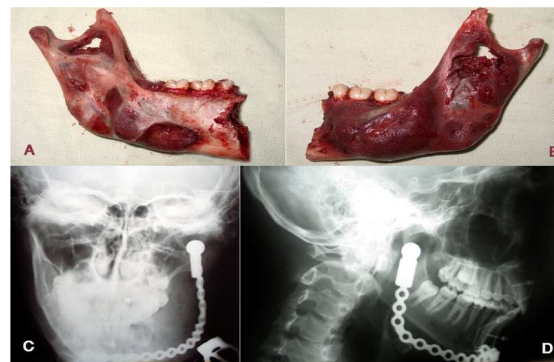
## INTRODUCTION

Reconstruction of the mandible is to restore the shape and function of the face, the continuity of the mandible and the muscular attachment [1]. Principles of reconstruction have evolved dramatically over the recent years with the aim of improving the patient's quality of life [2].

Investigators have reported various approaches for reconstruction of the mandible and so far, autogenous bone grafting is considered as the golden standard [1]. While microvascular flaps have been successfully used to correct defects with significant soft tissue deficiencies [1,2]. Several authors have studied the use of free bone grafts harvested mostly from the iliac for



**Fig 1.** Multilocular extension of the lesion in the left hemimandible, involving the ramus condyle unit.



**Fig 2.** A, B: Intra operative view of lingual (A) and buccal (B) aspects of the resected hemimandible; C,D: Post-operative radiographic evaluation of the reconstruction plate, frontal (A) and lateral (B) views.

delayed or immediate reconstruction of the mandible [3].

Spontaneous regeneration of the mandible on the other hand, has been rarely stated in previous studies [4-7].

Our review of literature showed only one report of spontaneous regeneration of the whole mandible [8]. The mechanism of spontaneous regeneration is not thoroughly understood.

Various factors however, have been suggested to influence this event [7-9].

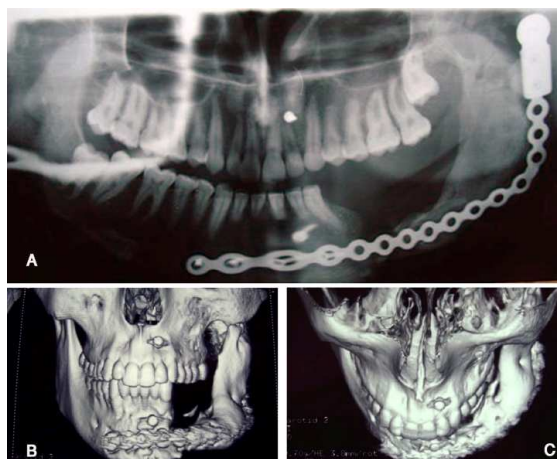
The present study presents a rare case of spontaneous regeneration of the hemimandible with a well-shaped condyle and coronoid in a 19-year-old patient following hemimandibulectomy for the treatment of an extensive odontogenic keratocyst. The observation was supported by histological evidence.

### CASE REPORT

A 19-year-old male subject with a one year history of painless swelling in the posterior region of the left mandible was referred to the Department of Oral and Maxillofacial Surgery, Shahid Beheshti University of Medical Sciences on April 18, 2007.

Clinical examination showed mild facial asymmetry with expansion of the left mandible.

A tangible lymph node in the left submandibular region was also found. Intraoral examination revealed a minimal expansion of the body and ramus of the mandible extending from the left second premolar to the anterior border of the ramus. Lingual expansion was more pronounced. The swelling had caused an eggshell cracking sensation on palpation. The overlying mucosa was normal, whereas the first and second molar teeth were moderately mobile. Radiographic examination demonstrated an extensive multilocular radiolucency extending from the left second premolar to the left subcondylar region (Fig 1). In computed tomography views, perforations of the lingual side of the mandible were noted and yellow liquid was also aspirated from the lesion. Intra-oral incisional biopsy confirmed the diagnosis of odontogenic keratocyst. Due to the wide extension of the lesion, intra-oral hemimandibulectomy was selected as the treatment of choice for the patient. Sulcular incision extending from the left first premolar to the ascending ramus parallel to the external oblique ridge was made and periosteum was gently elevated from both buccal and lingual sides. Muscular attachments were released from the posterior ramus to the condylar region.



**Fig 3.** One year postoperative evaluation of the patient revealed evidence of bone formation in the resected area of the hemimandible from the ramus condyle unit to the anterior mandible; C,D: Three dimensional computed tomographic evaluation of the spontaneously reconstructed hemimandible

Lingual cortex perforations—previously detected in CT views—were obvious intraoperatively. The first premolar was extracted and osteotomy was made through the extraction socket. The left hemimandible was then disarticulated from the glenoid fossa (Fig 2 A, B). A well shaped reconstruction plate that simulated the curvature of the mandible was used to preserve the surgical bed and improve the facial contour (Fig 2C, D).

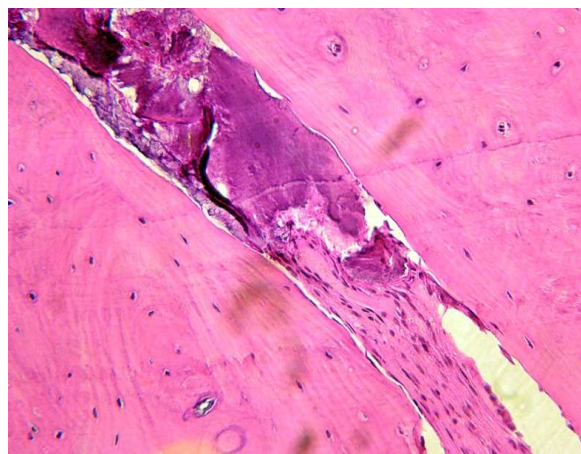
Three layer tension free closure of the wound was obtained after rigid fixation of the reconstruction plate.

Postoperative recovery was uneventful and the patient was discharged 5 days after the surgery.

One year radiographic follow-up of the patient revealed spontaneous healing of the mandible with a well shaped condyle and coronoid process (Fig 3A).

CT scan views also confirmed the evidence of denovo mandibular regeneration (Fig 3B, C).

During removal of the reconstruction plate, an incisional biopsy was performed from the newly regenerated bone.



**Fig 4.** Histological evaluation of the newly regenerated bone revealed dense trabecular formation with osteocytes and mixed fibro-marrow area.

The obtained specimen was embedded for 24 hours in 10% formalin for fixation and underwent a 7-day treatment with 10% formic acid for decalcification. Subsequently, the specimen was cut into 40-micron-thick sections. Sections were stained with hematoxylin and eosin which appeared to be consolidated, well-shaped trabecular bone. The bone marrow space was also filled with dense fibrous connective tissue (Fig 4).

## DISCUSSION

Bone tissue is believed to have the capacity to regenerate spontaneously following injury [1]. However, literature reports rare cases of this event following resection of a part or the whole of the mandible [4-9].

Although the exact mechanism that induces spontaneous bone regeneration is not fully understood, several factors including the patient's age [6,8,9], preservation of the periosteum [5,6,7,9], infection [3,4,7], post operation immobilization [4,5,8] and genetic behavior [8] have been suggested to influence this process.

Infection is believed to be a stimulating factor for periosteal bone regeneration. Adekeye et al reported a spontaneous regeneration of the mandible affected by an infected ameloblastoma seven months after resection [4].

They believed that infection activated osteoblasts originating from the intact periosteum. Complete regeneration of a mandible was also reported in a case with a history of an infected lesion 3 years prior to a complete mandibulectomy [8].

However, in the case described in this study, there were no signs of infection either preoperatively or during the healing period.

Age is believed to be an important influential factor on the process of spontaneous bone regeneration. Based on our review of literature, most patients with a report of this event in their records were younger than 15 years old [4,6-8], with the exception of two 27-year-old male subjects and a 32-year-old woman [5,9].

It is suggested that the cellular activities that influence bone regeneration are higher in younger patients [1,7,9].

In the case presented in this study too, age may have played an important role. Nineteen years of age; however, seems to be a median age compared with the reported cases of spontaneous mandibular regeneration. The role of periosteum as an important structure in bone healing and bone grafting is well recognized [8-10] and therefore, preservation of periosteum might have a central role in bone regeneration procedures.

It is also reported that periosteum has an important function in spontaneous bone regeneration [4-6,9-11].

Ruggerio and Donoff reported a case of mandibular spontaneous regeneration after irradiation, concluding that even an irradiated periosteum has some osteogenic potential although to a lesser degree than non-irradiated tissue [9].

While most of the reported cases with spontaneous regeneration of the mandible had gone

through resection of the mandible by an extra-oral incision approach, our surgical method was the same as Oganlewe et al, who used an intraoral approach for total mandibulectomy [8].

Authors believed that an intraoral incision in this case might preserve the periosteum better than extra oral approaches.

A newly designed titanium reconstruction plate was used in this study.

This structure is believed to be well tolerated by the human tissue and seems to act as a favorable guide for bone regeneration. Reviewed literature for this case report revealed no histological analysis of the spontaneously regenerated mandible. In this case, authors had the chance to harvest newly formed bone during removal of the plate. The following microscopic examination demonstrated a dense network of trabecular bone with fibrous connective tissue in bone marrow spaces, supporting the presence of a reactive phenomenon. It seems that a delicate surgical removal of a pathologic lesion with preservation of periosteum in young patients alongside the use of an appropriate space maintainer device may lead to spontaneous bone regeneration.

## CONCLUSION

The present case report describes spontaneous regeneration of a hemi-mandible with well shaped condyle and coronoid after resecting a pathologic lesion of the mandible in a young man. This observation might demonstrate that while most in vitro tissue engineering methods or *in situ* regeneration approaches fail to reconstruct a functional bone, human body itself, has a unique capacity in bone regeneration and tissue engineering researchers can count on the regenerative potential of the body more than before.

## ACKNOWLEDGMENTS

The authors wish to thank DrMashhadiabbas for her kind histological interpretation.

**REFERENCES**

- 1-Arrington ED, Smith WJ, Chambers HG, Bucknell AL, Davino NA. Complications of iliac crest bone graft harvesting. *ClinOrthopRelat Res* 1996 Aug;329:300-9.
- 2-Goh BT, Lee S, Tideman H, Stoelting PJ. Mandibular reconstruction in adults: a review. *J Oral MaxillofacSurg* 2008;37:597-605.
- 3-Hinds EC. Bone grafts, indications and timing. *J Oral SurgAnesthHosp Dent Serv* 1962 Jul;20:298-301.
- 4-Adekeye EO. Rapid bone regeneration subsequent to subtotal mandibulectomy: Report of an unusual case. *Oral Surg Oral Med Oral Pathol* 1977 Oct;44(4):521-6.
- 5-Elbeshir EI. Spontaneous regeneration of mandibular bone following hemimandibulectomy. *Br J Oral MaxillofacSurg* 1990 Apr;28(2):128-30.
- 6-Nagase M, Ueda K, Suzuki I, Nakajima T.. Spontaneous regeneration of condyle following hemimandibulectomy by disarticulation. *J Oral MaxillofacSurg* 1985 Mar;43(3):218-20.
- 7-Nwoku AL. Unusually rapid bone regeneration following mandibular resection. *J MaxillofacSurg* 1980 Nov;8(4):309-15.
- 8-Ogunlewe MO, Akinwande JA, Ladeinde AL, Adeyemo WL. Spontaneous regeneration of whole mandible after total mandibulectomy in a sickle cell patient. *J Oral MaxillofacSurg* 2006 Jun;64(6):981-4.
- 9-Ruggiero SL, Donoff RB. Bone regeneration after mandibular resection. *J Oral MaxillofacSurg* 1992 Jun;49(6):647-52.
- 10-Lemperle SM, Calhoun CJ, Curran RW, Holmes RE. Bony healing of large cranial and mandibular defects protected from soft-tissue interposition: a comparative study of spontaneous bone regeneration, osteoconduction, and cancellousautografting in dogs. *PlastReconstrSurg* 1998 Mar;660-72.
- 11-Smith JO, Aarvold A, Tayton ER, Dunlop DG, Oreffo RO. Skeletal tissue regeneration - current approaches, challenges and novel reconstructive strategies for an aging population. *Tissue Eng Part B Rev* 2011 May 27.