

Role of Fluorescence Imaging Device in Screening of Oral Cancer: A Cross-Sectional Study in Chhattisgarh Population

Shilpa Jain, Kamlesh Jain¹, Priyamvada Singh Bais², Swapnil V. Shinkar¹, Fatema Saify³

Departments of Oral Medicine and Radiology, Government Dental College, Raipur, ¹Department of Community Medicine, Pt. J. N. M. Medical College, Raipur, ²Pediatric Biology Center, Translational Health Science and Technology Institute (THSTI) Faridabad, Haryana, ³Department of Oral Pathology, Government Dental College, Raipur, Chhattisgarh, India

Abstract

Background: Oral squamous cell carcinoma is a major health issue worldwide. Screening and early diagnosis are the key elements for the better prognosis of potentially malignant oral disorders. **Objectives:** This study establishes the effectiveness of fluorescence imaging device in the early detection and precise examination of the normal-appearing oral mucosa of tobacco chewer patients in white light and fluorescence light. **Materials and Methods:** The study consists of a total of 150 patients equally categorized into frequent tobacco chewers with normal mucosa, precancerous lesion, and cancerous lesion. Out of which 10 cases were excluded due to technical errors and consent-related issues. The correlation between examined oral mucosa under white light and fluorescence light was evaluated through a 2 × 3 contingency table Chi-square test. **Results:** Out of 140 participants with a positive cancer diagnosis, there are 43 and 53 patients were sensitive to white light and fluorescence light, respectively. The estimated values for sensitivity and specificity were 0.83 (95% confidence interval: 0.736–0.906) for biopsy report diagnosis. **Conclusions:** Although autofluorescence device plays a critical role in the diagnosis of precancerous oral mucosal lesions in the early stages, the histopathological evaluation remains the gold standard diagnostic approach for this life-threatening disease. Due to the high sensitivity of autofluorescence examination, it has a vital role in determining high-risk oral lesions (precancerous) and oral cancer in mass screening programs for the cancer-prone population.

Keywords: Fluorescence imaging device, leukoplakia, oral squamous cell carcinoma, oral submucous fibrosis

INTRODUCTION

Oral cancer is the second most leading cause of death globally. It contributes to the high number of fatalities and is a major health problem worldwide, causing 127,000 deaths each year.^[1] In India, approximately 20/100,000 population annually are suffering from squamous cell carcinoma of the oral cavity and oropharynx.^[2] Oral premalignant lesion (OPL) and early oral squamous cell carcinoma (OSCC) have manifested mostly in the form of leukoplakia (white patch) and occasionally as erythroplakia (red patch) and further dysplastic changes which lead to carcinoma.^[3]

Few chair side investigations are available which include Lugol's iodine test, Toluidine blue staining, Vizilite, Brush biopsy, and Fluorescence device visualization technology. If suspected it can be confirmed by biopsy. A biopsy is an invasive procedure, which lowers its acceptability among the patients and so there is need for a noninvasive procedure.^[4] Since the

acceptability of the staining procedures is also quite low, the other screening methods are required.

For many years, screening for oral cancer is limited with the use of incandescence light illumination to visually inspect the oral cavity and perform manual palpation by the dentist. It is assumed that recently adjunctive screening technologies such as fluorescence device visualization that uses autofluorescence mechanism may allow the clinician to detect epithelial dysplasia and OSCC at an early stage.^[5] Autofluorescence is a

Address for correspondence: Dr. Shilpa Jain, Departments of Oral Medicine and Radiology, Government Dental College, Raipur, Chhattisgarh-492001, India. E-mail: drshilpakjain2@gmail.com

This is an open access journal, and articles are distributed under the terms of the Creative Commons Attribution-NonCommercial-ShareAlike 4.0 License, which allows others to remix, tweak, and build upon the work non-commercially, as long as appropriate credit is given and the new creations are licensed under the identical terms.

For reprints contact: WKHLRPMedknow_reprints@wolterskluwer.com

How to cite this article: Jain S, Jain K, Bais PS, Shinkar SV, Saify F. Role of fluorescence imaging device in screening of oral cancer: A cross-sectional study in chhattisgarh population. Indian J Community Med 2021;46:622-5.

Received: 30-11-20, **Accepted:** 22-08-21, **Published:** 08-12-21

Access this article online

Quick Response Code:



Website:
www.ijcm.org.in

DOI:
10.4103/ijcm.IJCM_987_20

phenomenon where endogenous fluorophores are excited with the extrinsic light source and these endogenous fluorophores are certain types of amino acids, structural proteins, and metabolic products. The most significant fluorophores within the oral mucosa are nicotinamide adenine dinucleotide and flavin adenine dinucleotide present within the epithelium and cross-links collagen in the stroma. The photons are absorbed by fluorophores through exogenous light sources leading to the emission of lower-energy photons which is presented clinically in the form of fluorescence. Each fluorophore is associated with the release of specific wavelengths of excitation and emission photons. The particular wavelength and intensity of light are emitted by the device which illuminates the oral mucosa and excites natural fluorophore in the tissue. The absorption and scattering properties of tissue are altered by the mucosal abnormalities.^[6]

The tissue emits fluorescence which is visualized through a filter by a human observer. For the direct visualization of fluorescence of oral cavity tissue, a nonmagnifying hand-held device was introduced by Lane, which is approved by the Food and Drug Administration for clinical use and is commercially available. A metal halide lamp is utilized by the system with an emission peak at 405 nm and 436 nm which helps in the activation of auto-fluorescence images which can be viewed by the eye through the instrument. However, in cases of malignant progression, there is a characteristic loss of fluorescence.^[7]

Hence, the main aim and objective of this study is to establish the effectiveness of fluorescence imaging device in early detection and precise examination of the normal-appearing oral mucosa of tobacco chewer patients in white and fluorescence light. For that purpose, the present study is conducted to assess the evidence and utility of fluorescence screening devices for early diagnosis of OPL. According to claudia carreras, the oral screening techniques that contribute to the diagnosis of oral cancer are given in Table 1.

MATERIALS AND METHODS

A prospective, observational, descriptive, and cross-sectional study was conducted from July 2016 to June 2017 after obtaining ethical clearance. Written informed consent was taken from all participants who were included in the study. A total sample size of $N = 150$ patients were selected by the purposive sampling technique. All the participants were screened into three categories namely N_1 group which contains the subjects with depicted normal mucosa but are frequent tobacco chewers ($N_1 = 50$), N_2 group which contains the subjects demonstrated precancerous lesion ($N_2 = 50$), and finally, N_3 group which contains the subjects with cancerous lesion ($N_3 = 50$), by taking a detailed case history. The details of the inclusion and exclusion criteria are as follows:

Inclusion criteria

Patients who gave their consent, patients who showed a

positive history of tobacco chewing without any visible mucosal changes, patients showing oral premalignant and malignant lesions.

Exclusion criteria

Patients with any hereditary disorder, patients who had blood dyscrasias and any other systemic problems.

Criteria for clinical diagnosis

The criteria used for the clinical diagnosis of premalignant lesions such as leukoplakia and oral submucous fibrosis (OSMF) is as follows:

For leukoplakia

- History of tobacco chewing
- Nonscrapable white patch raised above the surface
- Combined red and white lesions.

For oral submucous fibrosis

- Areca-nut chewing history
- A complaint of burning sensation of oral mucosa on consuming spicy foods
- Blanching of the oral mucosa
- Presence of fibrous bands in the cheek mucosa
- Reduced mouth opening.

Further, the details of the armamentarium used for the study are as follows

- Dental chair with an additional illumination facility
- Pair of sterile gloves
- Disposable mouth masks and head caps
- Disposable punches, blade, and local anaesthesia with the syringe for biopsy [Figure 1]
- Fluorescence imaging device.

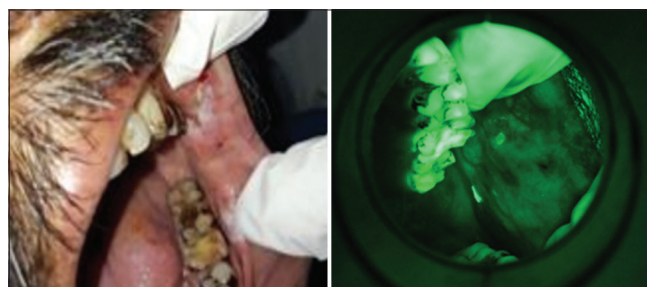


Figure 1: Leukoplakia appears white in white light and dark green in fluorescent light

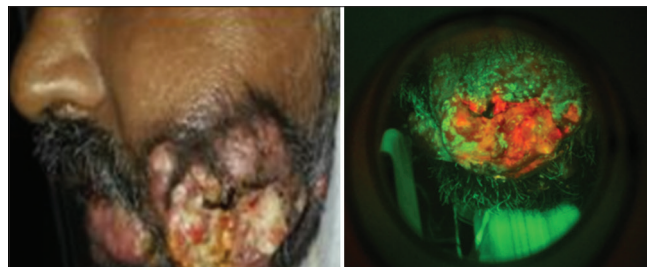


Figure 2: Malignancy of buccal mucosa appears yellow and red in white light and in fluorescent light it is appearing yellowish red

The specifications of the velscope Vx system are as follows

- a. Optical: Nominal output power (400–460 nm)-1W
 - i. Illumination spot diameter (@10 cm working distance)-1.5" (4 cm)
 - ii. Minimum working distance - 3 inches (8 cm).
- b. Hand-piece dimension: 22 cm × 6 cm × 9 cm
- c. Charging cradle dimensions: 6 cm × 10 cm × 18 cm
- d. Input voltage: 100–240V.

For the clinical examination, patients were seated on a dental chair. Then, the oral cavity was examined and palpitate thoroughly under a white light illumination. Further, at the same seating, similar examination and palpitation of oral cavity was revised under a fluorescence light illumination. Note that for examination under fluorescence light illumination, we strictly kept the distance of light source and the oral cavity equals to three inches throughout the study. During the examinations, the photographs of inspected sight under both fluorescence light and white light were taken with the same camera which was attached to the instrument. Both the photographs under white and the fluorescence light were compared. Premalignant lesions encountered during the study were leukoplakia, erythroplakia, and oral sub-mucous fibrosis. Areas with premalignant lesions under fluorescence light showed a dark green hue [Figure 1], and red hue in malignant lesions [Figure 2], which can be distinguished from bright green color of normal mucosa. Punch biopsy was done and sent for histopathology.

RESULTS

All 150 study subjects who were either frequent tobacco chewers or presented suspicious OPLs and cancerous lesion underwent a conventional examination with white-light and auto-fluorescence with a visualization device (Velscope). Ten cases were excluded due to technical errors and consent related issues. Out of 140 samples (121 were males and 19 were females) only thirteen (13) patients had history of cancer, however, one hundred and seven (127) patients had no history of cancer. It can be seen from Figure 2 that out of 140 patients, fifty seven (57 i.e., 40.7%) patients were found to be normal whereas forty (40 i.e., 28.6%) were diagnosed as premalignancy which included leukoplakia, erythroplakia, and OSMF; and lastly forty three (43 i.e., 30.7%) were diagnosed with malignancy on white light examination. With fluorescent light examination, fifty six (56 i.e. 40.0%) patients were found to be normal and eighty four (84 i.e., 60.0%) patients were diagnosed with positive [Figure 2]. Which are further segregated as, 31 i.e., 22.1% were diagnosed as premalignancy which included leukoplakia, erythroplakia, and OSMF, and 53 i.e., 37.85% patients were diagnosed with malignancy.

Punch biopsies were taken from all the patients who were positive for premalignancy and malignancy on white light and fluorescent light examination. On histopathological examination, it was revealed that eighty one (81 i.e., 57.9%) patients were positive. Out of these 81 patients, 29 i.e., 20.7%

were premalignant lesions which included 15 as leukoplakia, 10 as OSMF, and five (5) as dysplastic lesions, while 52 i.e., 37.2% patients were diagnosed with squamous cell carcinoma [Figure 2].

Association between white light and fluorescent light was evaluated through 2 × 3 contingency table Chi-square Test. Among the precancerous subjects, there were forty (40) subjects found sensitive to white light, whereas thirty one (31) study subjects were sensitive to the fluorescence light. In case of subjects with positive cancer diagnosis, forty three (43) patients were sensitive to white light, on the other hand, fifty three (53) patients were sensitive with fluorescence light [Table 2 and Figure 2]. For the white light, the sensitivity was 0.80 (95% confidence interval [CI]: 0.699–0.883) and specificity was 0.69 (95% CI: 0.561–0.801) while for the Velscope the sensitivity was of 0.97 (95% CI: 0.914–0.997) and a specificity of 0.91 (95% CI: 0.813–0.972) [Table 2]. Hence, it can be concluded that the performance of white light diagnosis is less as compared to the use of Velscope, although there was no significant difference in the proportions (Chi-square = 2.19, $P = 0.334$) when the comparison was done between them [Table 1].

DISCUSSION

Screening for a disease has been defined as: “The application of a test or tests to people who are apparently free from the disease in question in order to sort out those who probably have the disease from those who probably do not.”^[5] The confirmation of suspected tissue samples needs to be done by the histopathological examination.

The screening device should have the ability for the accurate detection of the occult cases of OSCC and OPL. Velscope is a handheld device used for direct visualization of tissue fluorescence. In Velscope, normal healthy tissue appears as bright apple green while the suspected lesions appear darker in color due to loss of fluorescence [Figure 2]. In the study conducted by Marzuoki *et al.*,^[8] The device was able to detect four dysplastic lesions that were not detected by clinical examination alone. The performance of any diagnostic test is determined by its sensitivity and specificity values. In the current literature higher sensitivities were observed in several studies ranging from 92% to 100%.^[8,9] Thus the present study, was designed to evaluate the role of a fluorescence imaging device in the early detection of cancer and to compare the fluorescence imaging finding of OPL and carcinoma patients with histopathological findings. However, in the present study, pathological lesions were diagnosed in 9.3% of patients who were having cancer history at the time of their oncological follow-up.

According to the pilot study findings of Bhatia *et al.*,^[10] it was concluded that the oral mucosal abnormalities which are not visible under a white light examination can be detected with the use of Velscope. In our study, we also noticed that some premalignant lesion was seen in fluorescence light which was missed by white light.

Table 1: Association of fluorescent light and white light in the study subjects

Parameter	Normal	Precancerous	Cancerous
White light	57 (40.7)	40 (28.6)	43 (30.7)
Fluorescent light	56 (40.0)	31 (22.1)	53 (37.9)

Table 2: Diagnostic test for white and fluorescent light examination for biopsy

Statistics	Fluorescent light		White light	
	Value (%)	95% CI	Value (%)	95% CI
Sensitivity	97.5	91.3-99.7	80.2	69.9-88.2
Specificity	91.5	81.3-97.2	69.5	56.1-80.8
Positive predictive value	94.0	87.2-97.3	78.3	70.7-84.3
Negative predictive value	96.4	87.3-99.1	71.9	61.6-80.4
Accuracy	95.0	90.0-98.0	75.7	67.8-82.6

In this study we have used biopsy as a gold standard approach. CI: Confidence interval

In a study by Farah *et al.* in 2012,^[11] 112 patients were examined by Velscope and it showed a 30% of sensitivity and 63% of specificity, with the accuracy of recognizing dysplasia was 55%. Based on the sensitivity and specificity, the present study showed that Velscope aided diagnosis does not appear to be more accurate in cancer diagnosis than white light in clinical exploration. However, fluorescence light shows more effectiveness in early premalignant lesion detections. The lesions which are invisible to the naked eye in the clinical examination has shown a promising result with the use of standard methods.^[11]

In the study conducted by Rana *et al.*,^[12] 289 patients with OPLs were randomly divided into two groups, and patients were examined with the auto-fluorescence visualization device (Velscope) in addition to the white light examination. The results showed that the Velscope has higher sensitivity but lower specificity. Thus, they concluded that the Velscope can be used as a new diagnostic device for the early detection of oral cancer diseases.^[12] In our study, specificity and sensitivity were found to be 91% and 97%, respectively.

In a recent study by Burian *et al.* in 2017,^[13] the analysis of photographs of 90 patients suffering from malignant oral soft-tissue lesions was done. A red color showed a significant difference in pathologic and physiologic tissues in 85.6% of the case and for the green and blue color, their measurements showed significantly higher values in the healthy tissue. The shade of red color has also shown a significantly higher value. Hence, they suggested that shortly, the Velscope could help to a greater extent in the identification of the margins of tumor resections as compared to the visual observation.^[13] Our study also showed a red and yellow color in the malignant lesion. In brief, our study proved that this instrument could be an adjuvant in clinical diagnosis if we have adequate resources.

CONCLUSIONS

The fluorescence device is a simple, noninvasive screening test of the oral mucosa. Since autofluorescence examination has high sensitivity, it might be helpful in the detection of high-risk oral lesions. Hence, it could be recommended for mass screening programs of oral cancer for the cancer-prone population. Moreover, It will guide the experienced clinicians in performing the biopsy within the altered mucosa for the final diagnosis of oral precancerous malignant lesions. Although this device has various advantages, it cannot be a replacement for the gold standard of histopathological examination. At present, this device can help in convincing the patients for further clinical investigation and management to reduce the impact of the psychological, physical, and financial burden of cancer. Probably in this manner, “optical biopsy” might turn into a clinical reality.

Financial support and sponsorship

Nil.

Conflicts of interest

There are no conflicts of interest.

REFERENCES

1. American Cancer Society: Cancer Facts and Figures 2005. Available from: <https://www.cancer.org>. [Last accessed on 2021 Mar 29].
2. Sankaranarayanan R, Ramadas K, Thomas G, Muwonge R, Thara S, Mathew B, *et al.* Effect of screening on oral cancer mortality in Kerala, India: A cluster-randomised controlled trial. *Lancet* 2005;365:1927-33.
3. Gillenwater A, Jacob R, Ganeshappa R, Kemp B, El-Naggar AK, Palmer JL, *et al.* Noninvasive diagnosis of oral neoplasia based on fluorescence spectroscopy and native tissue autofluorescence. *Arch Otolaryngol Head Neck Surg* 1998;124:1251-8.
4. Scully C, Bagan JV, Hopper C, Epstein JB. Oral cancer: Current and future diagnostic techniques. *Am J Dent* 2008;21:199-209.
5. Lingen MW, Kalmar JR, Karrison T, Speight PM. Critical evaluation of diagnostic aids for the detection of oral cancer. *Oral Oncol* 2008;44:10-22.
6. Lane PM, Gilhuly T, Whitehead P, Zeng H, Poh CF, Ng S, *et al.* Simple device for the direct visualization of oral-cavity tissue fluorescence. *J Biomed Opt* 2006;11:024006.
7. Carreras-Torras C, Gay-Escoda C. Techniques for early diagnosis of oral squamous cell carcinoma: Systematic review. *Med Oral Patol Oral Cir Bucal* 2015;20:e305-15.
8. Marzuoki HZ, TuongVi Vu T, Ywakim R, *et al.* Use of fluorescence light in detecting malignant and potentially malignant lesions in the oral cavity: A prospective, single blind study. *J Otolaryngol Head Neck Surg* 2012;41:164-8.
9. Awan KH, Patil S. Efficacy of Autofluorescence Imaging as an Adjunctive Technique for Examination and Detection of Oral Potentially Malignant Disorders: A Systematic Review. *J Contemp Dent Pract* 2015;16:744-9.
10. Bhatia N, Lalla Y, Vu AN, Farah CS. Advances in optical adjunctive AIDS for visualisation and detection of oral malignant and potentially malignant lesions. *Int J Dent* 2013;2013:194029.
11. Farah CS, McIntosh L, Georgiou A, McCullough MJ. Efficacy of tissue autofluorescence imaging (VELScope) in the visualization of oral mucosal lesions. *Head Neck* 2012;34:856-62.
12. Rana M, Zapf A, Kuehle M, Gellrich NC, Eckardt AM. Clinical evaluation of an autofluorescence diagnostic device for oral cancer detection: A prospective randomized diagnostic study. *Eur J Cancer Prev* 2012;21:460-6.
13. Burian E, Schulz C, Probst F, Palla B, Tröltzsch M, Maglitta F, *et al.* Fluorescence based characterization of early oral squamous cell carcinoma using the Visually Enhanced Light Scope technique. *J Craniomaxillofac Surg* 2017;45:1526-30.