

# Eyelid Thread-lifting Treatment for Periocular Infantile Hemangioma in an Extremely Premature Low-birth-weight Infant

Ayana Kurachi, MD  
 Mine Ozaki, MD, PhD  
 Aki Ihara, MD, PhD  
 Hitomi Eto, MD, PhD  
 Akihiko Takushima, MD, PhD

**Summary:** Periocular infantile hemangioma (IH) sometimes hinders proper eye opening and limits the visual field. Even short-term deprivation of hemilateral vision may cause amblyopia in infants during the visually sensitive period and, thus, necessitates prompt treatment. Propranolol is a commonly known remedy for IH, though it may not act sufficiently to rapidly resolve a vision-threatening critical condition in an infant. Low birth weight is a significant risk factor for IH incidence. Despite the high incidence, evidence-based treatment for IH in preterm infants has not been established. This report describes periocular IH of an extremely premature low-birth-weight infant (body weight: 526 g) whose lesion showed no reduction after oral administration of propranolol for 2 weeks but was successfully treated by topical steroid injection and eyelid thread-lifting management, with no eventual visual impairment. (*Plast Reconstr Surg Glob Open* 2019;7:e2373; doi: 10.1097/GOX.0000000000002373; Published online 19 August 2019.)

**H**emilateral visual deprivation in infants during the visually sensitive period can lead to life-long vision impairment, called “stimulus-deprivation amblyopia (SDA)”. Periocular infantile hemangioma (IH) sometimes causes SDA. Therefore, effective and rapid treatment is necessary for vision-threatening IH.<sup>1-3</sup>

Currently, administration of propranolol is a common treatment for cases of IH, which are life threatening, function threatening, or severely ulcerated hemangioma. A randomized controlled trial showed that 88% of IH patients receiving propranolol regimen showed improvement,<sup>4</sup> although a few cases not responding to propranolol have been known. There have been no large-scale studies or controlled clinical trials regarding IH treatment of premature infants, with appropriate treatment protocols yet to be established.<sup>5</sup> We report a case of periocular IH occurring in a premature infant, which did not show notable improvement after propranolol administration for 2 weeks but was successfully treated by eyelid thread-lifting

management combined with topical steroid injection, without subsequent onset of SDA.

## CASE REPORT

A preterm male infant born at 25 weeks and 6 days of gestational age with the body weight of only 526 g presented with IH in the right upper eyelid. The lesion was flat immediately after birth; however, the lesion gradually swelled to an extent that the infant became unable to open his right eyelid at 60 days after birth (corrected age: -1 mo). The patient was referred to our department at 70 days after birth (Fig. 1).

Oral propranolol administration (in syrup form) was initiated at 0.5 mg/kg/d, from 71 days after birth at 1,356 g of body weight. Although the dosage was gradually increased to 3.0 mg/kg/d in 2 weeks, the lesion showed no noticeable reduction. As an alternative treatment, topical steroid (triamcinolone) injections of 8 mg (at a rate of 5 mg/kg) were given to the eyelid twice at 84 and 98 days of age. Regression of the lesion was seen after the first injection, and the lesion became soft enough to be foldable after the second injection. However, his right eyelid could still not be opened sufficiently. Therefore, we performed thread-lifting management for the right upper eyelid at 110 days of age (body weight: 1,858 g) under general anesthesia (Fig. 2). Immediately after thread lifting, spontaneous opening of the eyelid was achieved. Full eyelid closure was not possible for a week after thread

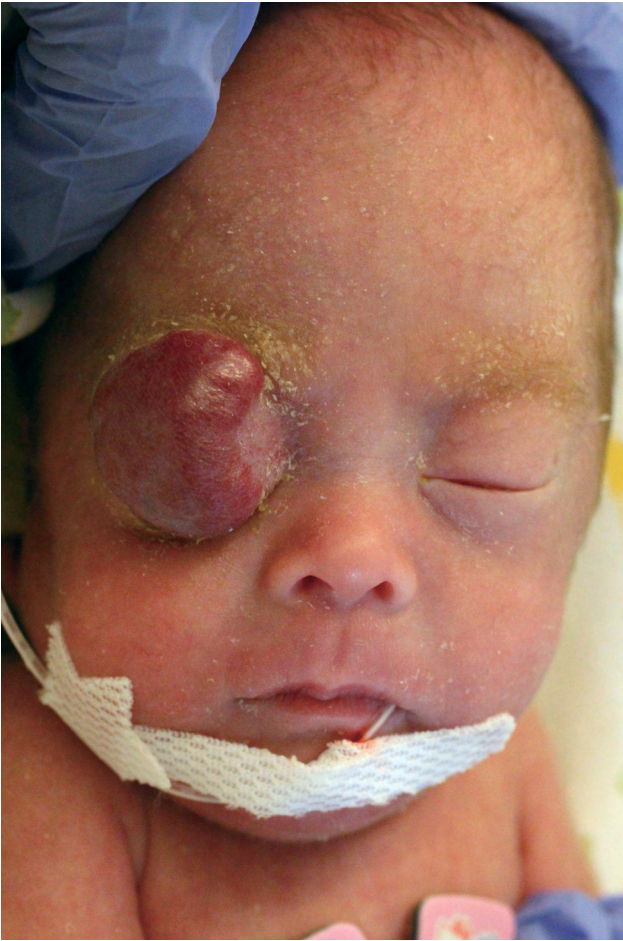*From the Department of Plastic, Reconstructive and Aesthetic Surgery, Kyorin University School of Medicine, Mitaka, Tokyo, Japan.*

*Received for publication March 10, 2019; accepted June 17, 2019.*

*Copyright © 2019 The Authors. Published by Wolters Kluwer Health, Inc. on behalf of The American Society of Plastic Surgeons. This is an open-access article distributed under the terms of the Creative Commons Attribution-Non Commercial-No Derivatives License 4.0 (CCBY-NC-ND), where it is permissible to download and share the work provided it is properly cited. The work cannot be changed in any way or used commercially without permission from the journal.*

DOI: 10.1097/GOX.0000000000002373

**Disclosure:** *The authors have no financial interest to declare in relation to the content of this article.*

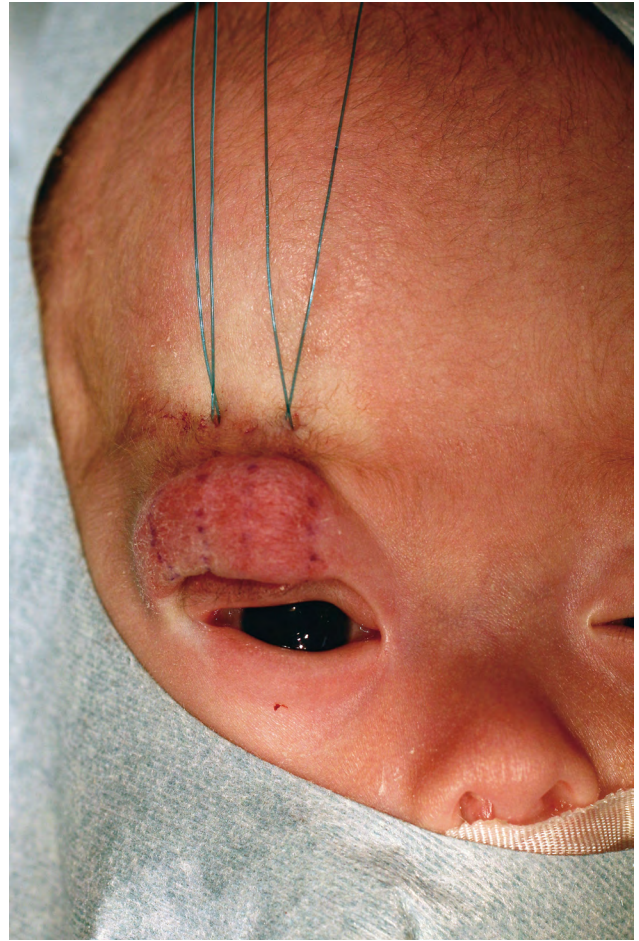

**Fig. 1.** Frontal view on the first consultation at 70 d of age (corrected age -1 mo).

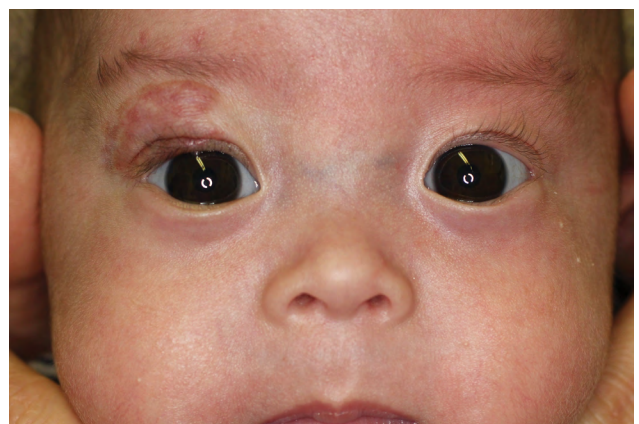lifting; thus, ofloxacin (0.3%) ophthalmic ointment was used to protect the cornea during that time. At 39 days after thread lifting, the infant was discharged from hospital without any complications. Administration of oral propranolol was prophylactically continued, which was gradually reduced until stopped at 1.5 years after discharge from hospital. Five-year follow-up with ophthalmic examinations has shown no regrowth of the lesion or visual impairment (Fig. 3).

#### Surgical Procedure

A 3-0 absorbable monofilament suture of which both ends were equipped with straight needles (Maxon, Covidien; Medtronic PLC, Dublin, Ireland) was used for lifting the upper eyelid. Sutures were placed subcutaneously to form rectangular shapes between the drooped eyelid and eyebrow. First, the needle was inserted at the side of the eyelid margin, then pulled out from the upper margin of the eyebrow. Second, another needle was inserted at the same hole in the eyelid margin, passed through transversely, pulled out from another site of the eyelid margin, then passed through upward in parallel with the first suture, and passed through transversely along the upper margin of eyebrow. Finally, the ends of

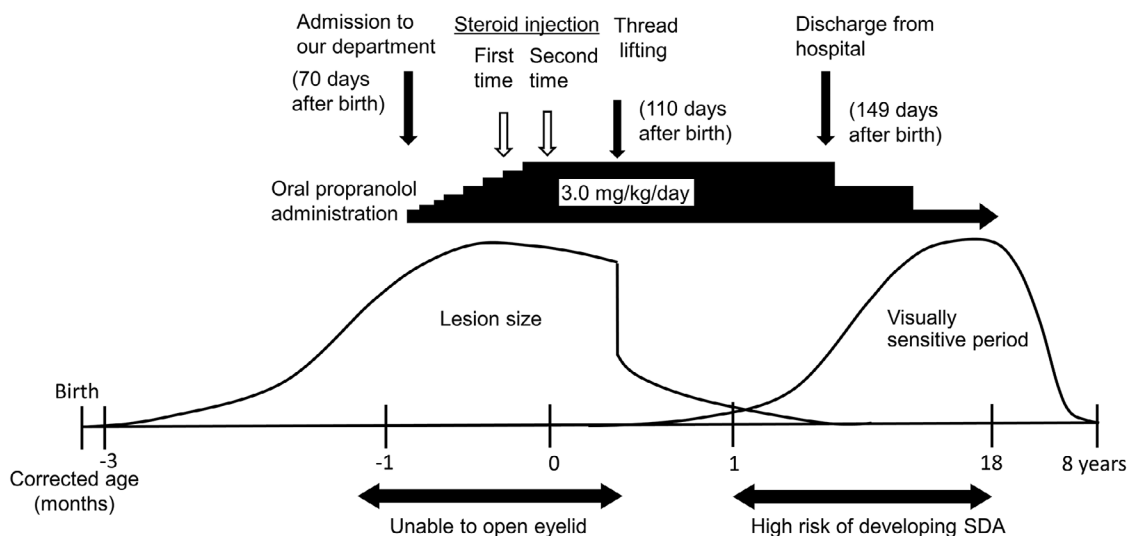


**Fig. 2.** Intraoperative image of thread lifting. Two sutures were placed subcutaneously to form rectangular shapes between the eyelid and eyebrow. Threads were tightened to ensure the optimal position.



**Fig. 3.** Two months (59 d) postoperative views showing regression of IH.

the suture were tightened to ensure the optimal position of the drooping eyelid and knotted. In this case, 2 sutures were used as the eyelid of the infant was too small to apply a greater number of sutures (Fig. 2).



**Fig. 4.** Summary of our treatment course and sensitive period for deprivation amblyopia. Lesion size did not notably change after onset of oral propranolol administration. After injection of steroid (triamcinolone), the lesion appeared to enter an involuting phase. Following thread lifting, the size of IH significantly regressed. No sign of stimulus deprivation amblyopia was noted in this case.

## DISCUSSION

SDA develops due to a deprivation of vision during the visually sensitive period. Visual sensitivity tends to be low for 4–6 weeks after birth and then increases with a peak around 18 months of age. Because hemilateral deprivation of vision even for a week during the sensitive period can cause SDA,<sup>1,2</sup> closed eyelids need to be spontaneously opened as soon as possible.<sup>3</sup> In our IH case, the patient suffered complete hemilateral visual deprivation at 2 months after birth, and his visual deprivation lasted for over 1.5 months. However, he did not develop SDA. We focused on his state of prematurity at birth and assessed his clinical course based on a corrected age. We started treatment from the corrected age of –1 month, and the affected eyelid could be opened at a corrected age of 13 days (Fig. 4). Therefore, we can infer that our patient avoided SDA, because eyelid opening became possible during the corrected age of 0 months. This finding suggests that a corrected age is an important index when determining treatment timing and regimen of periocular IH.

Low birth weight is the risk factor for the occurrence of IH. Drolet et al<sup>6</sup> stated that the risk of IH increased by 40% for every 500g decrease in birth weight. Despite a high incidence and high risk of complications, there have been few reports about the treatment for premature infants, such as our case.<sup>5,7</sup> Thus, individualized assessment for management of a regimen is required.

Thread lifting was an effective treatment option for periocular IH for our case, which required immediate eyelid opening. Numerous case reports have shown propranolol to be highly effective as a first-line treatment for alarming IH cases.<sup>8</sup> Meanwhile, there are a few reports of treatment failure with propranolol for IH. Phillips et al<sup>9</sup> suggested that focal facial lesions are sometimes refractory to propranolol, and He et al<sup>10</sup> stated that a certain genotype with cytochrome P450 metabolizes propranolol

rapidly, resulting in a poor response to propranolol. In our case, while propranolol may have prevented regrowth of IH after regression, it initially was ineffective in resolving the critical vision-threatening condition. Topical steroid injection and the thread-lifting management provided immediate eyelid-opening relief. The physical stimulation of the applied threads may have also been instrumental in rapid regression of IH. Other beneficial aspects of thread lifting were the short operative time (29 min) and minimal (1 mL) intraoperative hemorrhage. In our case, though mild drooping of the eyelid persisted for 3 weeks after thread lifting, the condition was deemed acceptable, because the limited visual deprivation did not ultimately result in SDA.<sup>1</sup> Our thread eyelid lifting technique is a relatively easy, safe, and effective treatment for vision-threatening hemangioma in an infant.

## CONCLUSIONS

In case of preterm infants, a corrected age can be an index to determine and initiate treatment regimen for periocular IH to prevent SDA. Thread lifting is an effective treatment, which can be performed within a short operative time and with minimal amount of bleeding. Our findings may be useful in choosing treatment options to achieve a favorable outcome for premature infants at risk of visual impairment from periocular IH.

Ayana Kurachi, MD

Division of Plastic, Reconstructive and Aesthetic Surgery  
Kyorin University Hospital  
6-20-2 Shinkawa, Mitaka-shi, Tokyo 181-8611, Japan  
E-mail: a-kajitani@ks.kyorin-u.ac.jp

## REFERENCES

1. Awaya S, Miyake S. Form vision deprivation amblyopia: further observations. *Graefes Arch Clin Exp Ophthalmol.* 1988;226: 132–136.

2. Elston JS, Timms C. Clinical evidence for the onset of the sensitive period in infancy. *Br J Ophthalmol*. 1992;76:327–328.
3. Haik BG, Jakobiec FA, Ellsworth RM, et al. Capillary hemangioma of the lids and orbit: an analysis of the clinical features and therapeutic results in 101 cases. *Ophthalmology*. 1979;86:760–792.
4. Léauté-Labrèze C, Hoeger P, Mazereeuw-Hautier J, et al. A randomized, controlled trial of oral propranolol in infantile hemangioma. *N Engl J Med*. 2015;372:735–746.
5. Goelz R, Poets CF. Incidence and treatment of infantile hemangioma in preterm infants. *Arch Dis Child Fetal Neonatal Ed*. 2015;100:F85–F91.
6. Drolet BA, Swanson EA, Frieden IJ; Hemangioma Investigator Group. Infantile hemangiomas: an emerging health issue linked to an increased rate of low birth weight infants. *J Pediatr*. 2008;153:712–5, 715.e1.
7. Kado M, Shimizu A, Matsumura T, et al. Successful treatment of infantile hemangiomas with propranolol in low-birth-weight infants. *J Craniofac Surg*. 2017;28:789–793.
8. Holmes WJ, Mishra A, Gorst C, et al. Propranolol as first-line treatment for rapidly proliferating infantile haemangiomas. *J Plast Reconstr Aesthet Surg*. 2011;64:445–451.
9. Phillips RJ, Lokmic Z, Crock CM, et al. Infantile haemangiomas that failed treatment with propranolol: clinical and histopathological features. *J Paediatr Child Health*. 2014;50:619–625.
10. He A, Khanna R, Kwatra SG. Cytochrome P450 isoform genotyping in poor propranolol responders for hemangioma treatment. *Pediatr Int*. 2017;59:120.