

# Sialodochitis fibrinosa (kussmaul disease) report of 3 cases and literature review

Bryan Josue Flores Robles, MD<sup>a,\*</sup>, Beatriz Brea Álvarez, MD-PhD<sup>b</sup>, Abel Alejandro Sanabria Sanchinel, MD<sup>c</sup>, Robert Francis Andrus, MD<sup>d</sup>, María Espinosa Malpartida, MD<sup>a</sup>, Consuelo Ramos Giráldez, MD<sup>a</sup>, Ana Lerma Verdejo, MD<sup>e</sup>, Carolina Merino Argumanez, MD<sup>a</sup>, Jose Antonio Pérez Pimiento, MD<sup>f</sup>, Camen Bellas Menéndez, MD-PhD<sup>g</sup>, Luis Fernando Villa Alcázar, MD<sup>a</sup>, José Luis Andréu Sánchez, MD-PhD<sup>a</sup>, Mercedes Jiménez Palop, MD<sup>a</sup>, Hildegarda Godoy Tundidor, MD<sup>a</sup>, José Campos Esteban, MD<sup>a</sup>, Jesús Sanz Sanz, MD<sup>a</sup>, Carmen Barbadiillo Mateos, MD<sup>a</sup>, Carlos María Isasi Zaragoza, MD<sup>a</sup>, Juan Bartolomé Mulero Mendoza, MD-PhD<sup>a</sup>

## Abstract

**Background:** Sialodochitis fibrinosa is a rare disease which is characterized by recurring episodes of pain and swelling of the salivary glands due to the formation of mucofibrinous plugs. Analytic studies ascertain elevated levels of eosinophils and immunoglobulin E (IgE). Imaging studies such as magnetic resonance imaging (MRI) and sialography reveal dilation of the main salivary duct (duct ectasia). Treatment is initially supportive, consisting of compressive massages, and use of antihistamines and/or corticosteroids.

**Material and methods:** In the following, 3 cases of sialodochitis fibrinosa are presented which were diagnosed in a third level hospital during the period of 2008 and 2016, as well as a literature review of all cases reported to our knowledge.

**Results:** Of the 41 cases found, including the 3 of this article, 66% were women with an average age of 45 years old. However, 75% of reported cases were of Japanese heritage. Involvement of the parotid glands was more frequent than the submandibular glands. In more than half of all cases treatment with compressive massages, antihistamines and/or corticosteroids was effective.

**Conclusion:** Clinicians should consider sialodochitis fibrinosa as a diagnostic possibility when presented with cases of recurring parotid and submandibular gland tumescence.

**Abbreviations:** ACE = angiotensin-converting enzyme, ACPA = anticitrullinated protein antibody, ANA = antinuclear antibody, ANCA = antinutrophil cytoplasmic antibody, CBC = complete blood count, CRP = C-reactive protein, ESR = erythrocyte sedimentation rate, HBV = hepatitis B virus, HCV = hepatitis C virus, HIV = human immunodeficiency virus, IgE = immunoglobulin E, MRI = magnetic resonance imaging, RF = rheumatoid factor.

**Keywords:** allergic parotitis, Fibrinous sialodochitis, Kussmaul disease, sialodochitis fibrinosa

## 1. Introduction

Sialodochitis fibrinosa was first described in 1879 by Kussmaul<sup>[1]</sup> as pain and diffuse swelling of the parotid and/

or submandibular glands caused by the obstruction of the salivary ducts by mucofibrinous plugs. Diagnosis is difficult and may be confused with other clinical entities such as Sjögren syndrome or infectious sialadenitis.<sup>[2]</sup> Although diagnostic criteria has not been defined, the typical findings of described cases are: (a) recurring episodes of parotid/submandibular gland swelling, (b) discharge of mucofibrinous plugs with a high content of eosinophils, (c) elevated levels of IgE and/or eosinophils in blood, (d) presence of concomitant allergic processes such as asthma or allergic rhinitis, (e) irregular dilation of the main salivary ducts as seen by imaging studies (sialography or MRI), (f) glandular biopsy showing lymphocytic infiltrates and abundant eosinophils within the interstium surrounding the salivary ducts.<sup>[3,4]</sup> The etiology of this disease remains unknown although the most accepted hypothesis is that it is an allergic process.<sup>[4-6]</sup> Treatment varies according to the severity of the disease, nevertheless initial supportive treatment with massages and hydration is recommended in conjuncture with the use of antihistamines and/or corticosteroids. In refractory cases, corticosteroid infiltration and dilation of the parotid duct has been done.<sup>[3]</sup> The following presents 3 cases of sialodochitis fibrinosa seen in a third-level hospital with a description of their clinical presentation, diagnostic workup, and management.

Editor: Priscila Lie Tobouti.

Authorship: Dr. Flores Robles and Dr. Mulero Mendoza had access to all study data and assumed responsibility for data integrity and accuracy of data analysis. Study supervision: Dr. Mulero Mendoza.

The authors have no funding and conflicts of interest to disclose.

<sup>a</sup> Rheumatology Division, <sup>b</sup> Radiodiagnostic Division, Puerta de Hierro Hospital, Madrid, <sup>c</sup> Neurology Division, Lozano Blesa Hospital, Zaragoza, Spain,

<sup>d</sup> Independence Polyclinic, Belize, <sup>e</sup> Haematology Division, <sup>f</sup> Allergology Division,

<sup>g</sup> Anatomical Pathology Division, Puerta de Hierro Hospital, Madrid, Spain.

\* Correspondence: Bryan Josué Flores Robles, Rheumatology Division, Puerta de Hierro Hospital Majadahonda, Madrid, Spain. (e-mail: aldolasa@hotmail.com).

Copyright © 2016 the Author(s). Published by Wolters Kluwer Health, Inc. All rights reserved.

This is an open access article distributed under the Creative Commons Attribution License 4.0 (CCBY), which permits unrestricted use, distribution, and reproduction in any medium, provided the original work is properly cited.

Medicine (2016) 95:42(e5132)

Received: 4 August 2016 / Received in final form: 15 September 2016 /

Accepted: 21 September 2016

<http://dx.doi.org/10.1097/MD.0000000000005132>

## 2. Method

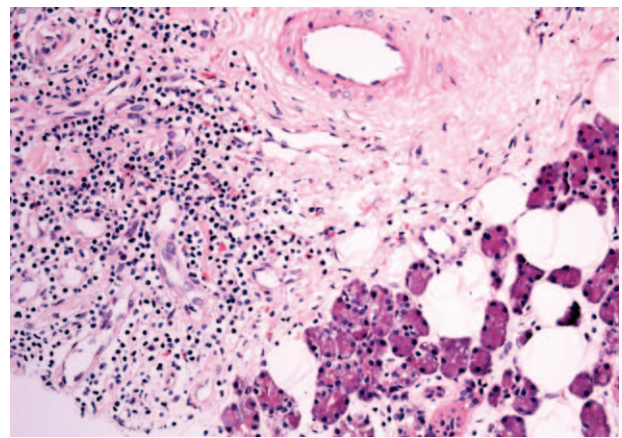
Three patients with sialodochitis fibrinosa consulting in a third-level hospital were evaluated during the period of 2008 to 2016, of whom their sociodemographic characteristics, clinical presentations, study imaging findings, and cytological findings were described. Subsequently, a thorough literature review was done, finding 28 articles reporting a total of 41 cases including the 3 from this report. The search timeframe included articles from April 1879, the time of Kussmaul's initial description, until June 2016. Searching was done using the terms sialodochitis fibrinosa, fibrinous sialodochitis, Kussmaul disease, and allergic parotitis, within platforms such as Pubmed, Embase, Medline, Scopus, as well as nonindexed journals found in the hospital's virtual library and internet browser (mainly Japanese journals). Furthermore, the bibliography of each article was reviewed to capture more reported cases. In this review, all articles were taken into account regardless of the language in which they were written. The study was approved by the hospital ethics committee investigation (CEIC).

## 3. Case reports

### 3.1. Case 1

A 41-year-old Spaniard woman consulted because of recurring bilateral parotid swelling and pain during the past 4 years which were triggered by food consumption. Episodes initially occurred every 3 to 4 days and progressed until they occurred daily during the last weeks before consultation. After meals she would massage her parotid glands, relieving the pain and swelling as mucous secretions would be expressed into her buccal cavity. The only past medical history finding mentioned was allergic rhinitis. She was a nonsmoker with no history of alcohol consumption. She had no family history of allergies. She had no history of fever, weight loss, or other constitutional symptoms. Physical exam revealed bilateral parotid swelling with pain on palpation and associated erythema. Intraoral examination showed extruded mucous plugs and secretion from the Stensen ducts upon compressing the glandular region. A sterile cotton swab was used to obtain a sample of the secretion for slide analysis.

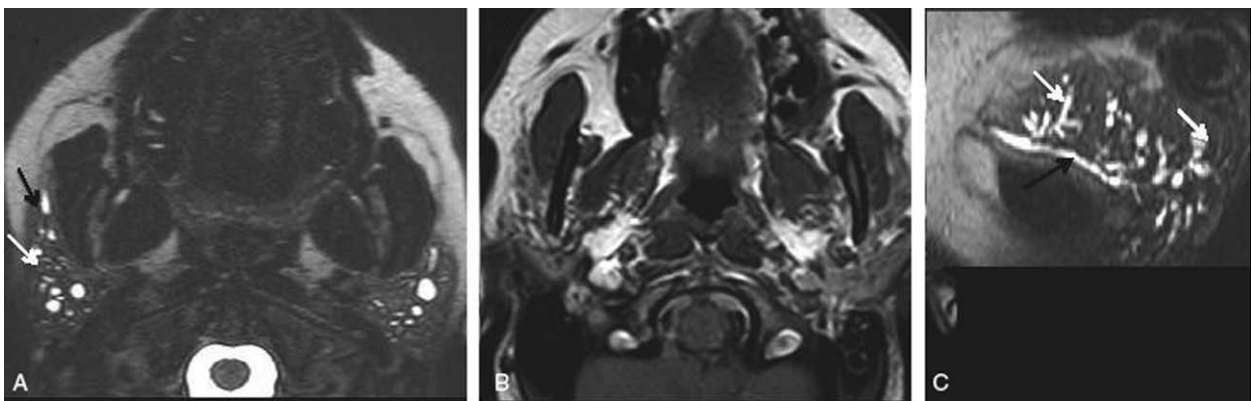
Laboratory results showed a complete blood count (CBC) with a leukocyte count of 4970  $\mu\text{L}$ , and eosinophil count of 570  $\mu\text{L}$ , IgE levels of 93.5 KU/L (reference range 4.2–592), and C-reactive



**Figure 2.** Interstitial filtrate of mature lymphocytes T and B and abundant eosinophils surrounding the salivary ducts.

protein (CRP), erythrocyte sedimentation rate (ESR), rheumatoid factor (RF), anticitrullinated protein antibody (ACPA), angiotensin-converting enzyme (ACE), proteinogram and IgG4 with normal levels. Antinuclear antibodies (ANAs), antineutrophil cytoplasmic antibodies (ANCA) were negative, serology for hepatitis B virus (HBV), hepatitis C virus (HCV), human immunodeficiency virus (HIV) were negative, Mantoux test was negative, and food allergy studies were negative. Chest and neck x-rays, neck tomography, salivary gland scintigraphy, 18F-FDG PET/CT were normal. An MRI of the parotid glands reported multiple cystic dilations of the intraglandular ducts and dilation of the main drainage duct (Fig. 1). The glandular secretion was stained demonstrating numerous eosinophils. Glandular biopsy revealed an interstitial infiltrate of mature lymphocytes T and B (CD3+ and CD20+) and abundant eosinophils surrounding the salivary ducts (Fig. 2). The patient was diagnosed with sialodochitis fibrinosa.

Treatment was started with prednisone 10 mg/day and loratadine 10 mg/day. Accordingly, the patient showed good clinical response after the first week and then was found to be asymptomatic after 5 months. Six months after the diagnosis, the patient continued treatment with loratadine 10 mg/day and prednisone 2.5 mg/q.a.d.



**Figure 1.** (A) MRI fat saturated T2-weighted axial plane. (B) MRI T1-weighted axial plane. (C) Oblique sagittal reconstruction. The parotid glands are slightly reduced in size and present multiple cystic dilations in the intraglandular ducts (white arrows) and mild dilation of main ducts (black arrows). MRI = magnetic resonance imaging.

### 3.2. Case 2

A 46-year-old Peruvian woman consulted because of recurring episodes of swelling and pain in both parotid regions during the past 5 years which were triggered by the consumption of various foods, although the patient did not specify the food types. Episodes were associated with the expulsion of mucous secretions as the patient would massage her parotid glands postprandially. She had a significant medical history of asthma and chronic rhinoconjunctivitis. She was a nonsmoker and had no history of alcohol consumption. She had no family history of allergies. Physical exam revealed bilateral parotid swelling which was more pronounced on the right side. Intraoral examination revealed extruded mucous secretion upon compressing the right parotid region.

Laboratory results showed a CBC with a leukocyte count of  $8290 \mu\text{L}$  and eosinophil count of  $820 \mu\text{L}$ , and IgE level of 200 KU/L, and CRP, levels of PCR, ESR, RF, ACPA, ACE, proteinograma, and IgG4 with normal levels. ANAs and ANCAs were negative, serology for HVB, HVC, and VIH were negative, and the Mantoux test was negative. Among imaging studies, a chest x-ray was normal, whereas an MRI of the salivary glands demonstrated dilation of both main drainage parotid ducts (Fig. 3). Food allergy studies were negative. A stain of the salivary gland secretion presented abundant mixed-type inflammatory cellularity with a high proportion of eosinophils (20%) in a proteinaceous background. Parotid gland biopsy was refused by the patient. The patient controlled her symptoms with irregular use of antihistamines.

### 3.3. Case 3

A 28-years-old Spaniard woman consulted because of a 20-year history of recurring left-side parotid swelling. Episodes were not related with food consumption, yet the episodes were turning more frequent. Past medical history only included seasonal rhinitis. Physical exam presented left parotid swelling with expulsion of mucous material from the Stensen duct upon compressing the left glandular region, whereas the right-side parotid region presented no relevant physical exam findings. Laboratory results showed a CBC with a leukocyte count of  $8590 \mu\text{L}$  and eosinophil count of  $600 \mu\text{L}$ . The rest of laboratory results were normal. An MRI of the parotid glands showed both Stenson ducts to be dilated. A stain of the salivary gland secretion

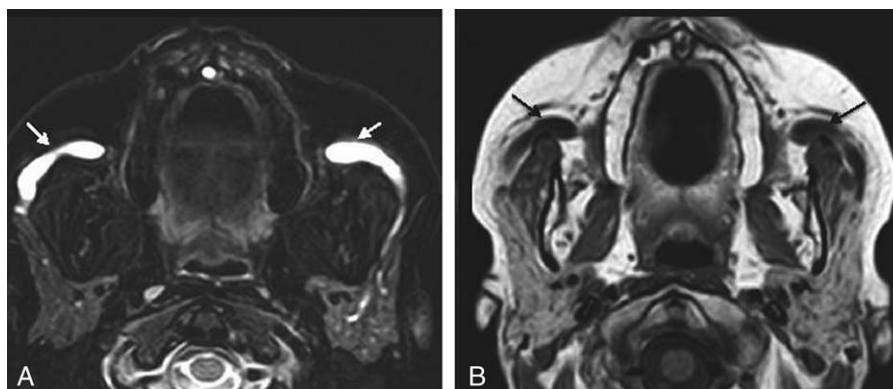
presented abundant eosinophils. The patient remained asymptomatic with periodic compressive massages.

## 4. Discussion

The swelling of the salivary glands is a relatively common symptom which can be caused by several different processes whether inflammatory or noninflammatory.<sup>[4]</sup> Among the differential diagnosis of parotid swelling, it is important to rule out secondary and systemic causes, one of them being sialodochitis fibrinosa (also known as Kussmaul disease). Sialodochitis fibrinosa was first described in 1879, as salivary gland swelling, affecting mainly the parotid glands, habitually bilateral and recurring, with the expulsion of mucous secretion from the salivary ducts upon compressing the affected glandular regions, in patients with a past medical history of allergic processes and elevated eosinophils and IgE. Stained samples of the mucous material demonstrate abundant eosinophils. Imaging studies, such as MRI and sialography, demonstrate dilated salivary ducts and ectasia. Salivary gland biopsy shows lymphocytic infiltrates with abundant eosinophils in the periductal interstitium. Currently there are no established criteria for diagnosis being an extremely rare disease. Diagnosis is difficult and done by exclusion, requiring a high index of suspicion for its confirmation. The differential diagnosis of this disease includes Sjögren syndrome, sarcoidosis, lymphoma, IgG4-related disease, bacterial and viral infectious sialadenitis, sialolithiasis, among others.

Although the exactitude of the epidemiological and demographical characteristics is unknown, in this study it was found (Table 1) that 66% of the 41 reported cases were women with an average age of 45-years old, and the parotid glands was predominantly more affected than the submandibular glands (26 cases affecting the parotid glands and 15 cases affecting the submandibular glands). Almost 75% of the patients from reviewed cases were of Japanese heritage.

Although the etiology of sialodochitis fibrinosa remains unknown, it is suggested that it is caused by an allergic process related to the consumption of certain foods, namely tuna fish, wheat, lettuce, and legumes such as lima beans.<sup>[5,6]</sup> In this study, it was noted that 23 case reports specifically referenced the presence of food-related exacerbations; 4 case reports established that the symptoms were not food related; and 14 case reports made no mention of food-related symptoms. It is, therefore,



**Figure 3.** (A) MRI fat saturated T2-weighted axial plane. (B) MRI T1-weighted axial plane. The parotid glands have a conserved signal and size. There is no evidence of intaparotid solid or cystic lesions. There is significant dilation of the main drainage ducts (arrows). MRI = magnetic resonance imaging.

**Table 1****Case reports of sialodochitis fibrinosa (Kussmaul disease).**

Author and country	Year	Age, y	Sex	Localization	Treatment	Related to food
Kussmaul <sup>[1]</sup> (Germany)	1879	32	F	Bilateral parotid	Massage	Unknown
Waldbott et al <sup>[5]</sup> (USA)	1947	47	M	Bilateral parotid	Diet	Yes
		44	F	Bilateral parotid	Desensibilization	Yes
		55	M	Bilateral parotid	Unknown	Yes
Ammar-Khodja <sup>[7]</sup> (France)	1971	39	F	Bilateral parotid	Lidocaine infiltration	Yes
Okuda et al <sup>[8]</sup> (Japan)	1975	44	M	Right parotid	Surgical	Yes
		33	M	Left submandibular	Surgical	Unknown
		35	F	Left parotid	Surgical	Yes
Miyazaki and Kumagami <sup>[9]</sup> (Japan)	1981	40	M	Bilateral submandibular	Corticosteroids and antihistamines	Yes
Murakami <sup>[10]</sup> (Japan)	1982	39	F	Bilateral parotid	Corticosteroids injection and antihistamines	Yes
Yoshida et al <sup>[11]</sup> (Japan)	1994	66	M	Bilateral submandibular	Surgical	Yes
Ogawa et al <sup>[12]</sup> (Japan)	1995	52	F	Left submandibular	Massage	Unknown
		54	F	Bilateral submandibular	Corticosteroids injection and antihistamines	Unknown
Kiuchi <sup>[13]</sup> (Japan)	1996	47	M	Left submandibular	Antihistamines	Unknown
Goto <sup>[14]</sup> (Japan)	1996	47	M	Bilateral submandibular	Corticosteroids	Yes
Yoshioka et al <sup>[15]</sup> (Japan)	1997	39	F	Bilateral parotid	Surgical	No
Tanimoto et al <sup>[16]</sup> (Japan)	1997	29	M	Bilateral submandibular	Antihistamines	Unknown
Motosugy et al <sup>[17]</sup> (Japan)	1998	37	M	Bilateral submandibular	Antihistamines	Unknown
		39	M	Left submandibular	Surgical	Unknown
Yoshihara <sup>[18]</sup> (Japan)	2002	23	F	Bilateral submandibular	Massage	Unknown
Kinoshita and Sadanaga <sup>[19]</sup> (Japan)	2003	25	F	Bilateral parotid	Antihistamines	Yes
Tsutsumi et al <sup>[20]</sup> (Japan)	2003	52	F	Bilateral parotid	Antihistamines	Yes
Yamamoto <sup>[21]</sup> (Japan)	2004	40	F	Bilateral parotid	Bromhexina	Yes
Nemoto et al <sup>[22]</sup> (Japan)	2006	58	F	Bilateral submandibular	Surgical	Unknown
Chikamatsu et al <sup>[4]</sup> (United Kingdom)	2006	60	F	Bilateral parotid	Massage	Unknown
		58	F	Bilateral parotid	Massage	No
Otsuka et al <sup>[23]</sup> (Japan)	2006	61	F	Bilateral parotid	Antihistamines	Yes
		66	F	Bilateral submandibular	Antihistamines	Yes
Shimada et al <sup>[24]</sup> (Japan)	2006	50	F	Left parotid	Surgical	Yes
Pollak et al <sup>[25]</sup> (USA)	2009	34	F	Bilateral parotid	Surgical	Unknown
Miyagi <sup>[26]</sup> (Japan)	2009	15	M	Bilateral parotid	Corticosteroids	Unknown
Frati et al <sup>[27]</sup> (Japan)	2011	8	M	Bilateral parotid	Corticosteroids	No
Tsuchiya et al <sup>[28]</sup> (Japan)	2012	69	F	Bilateral parotid	Antihistamines	Yes
		49	F	Bilateral parotid	Antihistamines	Yes
		48	F	Left parotid	Antihistamines	Yes
Ray et al <sup>[2]</sup> (USA)	2015	56	F	Right parotid and submandibular	Surgical	Yes
Hayashi et al <sup>[3]</sup> (Japan)	2016	80	M	Bilateral parotid	Surgical	Yes
Sakaguchi et al <sup>[29]</sup> (Japan)	2016	62	F	Bilateral submandibular.	Antihistamines	Unknown
Flores-Robles et al (Spain)	2016	41	F	Bilateral parotid	Antihistamines and corticosteroids	Yes
		46	F	Bilateral parotid	Antihistamines	Yes
		28	F	Bilateral parotid	Massage	No

F = female, M = male.

deduced that food allergies should be sought out in a majority of patients. Of the 23 case reports affirming food-related symptoms, the majority did not specify the food type.

The treatment of this disease depends on the severity of the symptoms. Generally, compressive massages of the salivary glands, abundant hydration, and the administration of antihistamines with or without corticosteroids should be considered as the initial management. In reviewing 41 cases, it was noted that more than half of the patients improved with only massaging and antihistamines. In 11 cases, an invasive procedure was required such as instrumental dilation of the parotid ducts and/or partial gland resection.<sup>[3]</sup>

Of the 3 case reports presented in this article, it was observed that 2 patients presented symptoms that were triggered by food consumption, although the specific food types were not determined. The patient mentioned in the first case presented good treatment response and achieved complete remission of her

symptoms by taking low-dose corticosteroids together with an antihistamine.

Together with the series described by Okuda (1975)<sup>[8]</sup> and Tsuchiya (2012),<sup>[28]</sup> this is the largest series of sialodochitis fibrinosa described thus far; also, this is the first literature review to date written in English which delimits demographic characteristics, clinical presentations, and therapeutic management of this disease. Due to the limited number of sialodochitis fibrinosa cases reported, incomplete information regarding food-related symptoms, and incomplete recall of the specific food types, it is challenging at the present to provide meaningful conclusions on the association of this disease and food allergies. Nevertheless, this also indicates that further research is warranted.

In conclusion, patients undergoing diagnostic workup for episodes of recurring parotid or submandibular swelling, where systemic and infectious causes have been ruled out, sialodochitis fibrinosa should be considered as a potential cause. Sialodochitis

fibrinosa is a disease which may be easily treated by conservative means, therefore improving the patients' quality of life.

## References

- [1] Kussmaul I. Recurrent salivary gland tumor due to chronic fibrotic inflammation of the Stensen's ducts (Anfallsweise auftretende Speichelgeschwulst in Folge von chronischer eitrig-fibrinöser Entzündung des Stenonschen Ganges). *Berlin Klin Wschr* 1879;15:209–11. Article in German.
- [2] Ray A, Burgin SJ, Spector ME. A rare case of Kussmaul disease (sialodochitis fibrinosa). *J Case Rep Med* 2015;4:1–3.
- [3] Hayashi K, Onda T, Ohata H, et al. Case of suspected sialodochitis fibrinosa. *Bull Tokyo Dent Coll* 2016;57:91–6.
- [4] Chikamatsu K, Shino M, Fukuda Y, et al. Recurring bilateral parotid gland swelling: two cases of sialodochitis fibrinosa. *J Laryngol Otol* 2006;120:330–3.
- [5] Waldbott GL, Shea JJ. Allergic parotitis. *J Allergy* 1947;18:51–4.
- [6] Harkness P. Submandibular salivary disease: a proposed allergic aetiology. *J Laryngol Otol* 1995;109:66–7.
- [7] Ammar-Khodja A. Sialodochitis fibrinosa of Kussmaul (Sialodochite fibrineuse de Kussmaul). *Rev Laryng* 1971;92:11–2. Article in French.
- [8] Okuda M, Ogami Y, Unno T. Sialodochitis fibrinosa (Kussmaul). *Otology Fukuoka* 1975;21:635–9. Article in Japanese.
- [9] Miyazaki M, Kumagami H. Sialodochitis fibrinosa with report of case. *Otology Fukuoka* 1981;6:821–4. Article in Japanese.
- [10] Murakami S. Sialodochitis fibrinosa of the parotid gland. *Otolaryngology* 1975;54:919–24. Article in Japanese.
- [11] Yoshida M, Samejima Y, Mayusama K, et al. Sialodochitis fibrinosa of the submandibular gland. A case report. *Stomato-pharyngology* 1994;6:97–102. Article in Japanese.
- [12] Ogawa T, Kazusada Y, Lida S, et al. Two cases of sialodochitis fibrinosa (Kussmaul's disease). *Jap J Oral Maxillofac Surg* 1995;6:549–51. Article in Japanese.
- [13] Kiuchi N. Sialodochitis fibrinosa a case report. *Otolaryngol Head Neck Surg (Tokyo)* 1996;68:1082–5. Article in Japanese.
- [14] Goto H. An example of a fibrinous salivary duct inflammation. *Stomato-pharyngology* 1996;9:106. Article in Japanese.
- [15] Yoshioka Y, Makino K, Sakoda K, et al. Sialodochitis fibrinosa of parotid glands. *Stomato-pharyngology* 1997;9:409–16. Article in Japanese.
- [16] Tanimoto K, Ishii K, Suei Y, et al. Sialodochitis fibrinosa (Kussmaul) in the submandibular gland—report of case. *Shika Hoshasen Dental Radiol* 1997;37:151–5. Article in Japanese.
- [17] Motosugy H, Itoh H, Tachibana M, et al. two cases of sialodochitis fibrinosa. *Stomato-pharyngology* 1998;10:345–9. Article in Japanese.
- [18] Yoshihara T. Bilateral enlargement of the submandibular glands—clinical and pathological appearance. *Practica oto-Rhino-Lryngologica* 2002;95:555–61. Article in Japanese.
- [19] Kinoshita S, Sadanaga Y. A case of sialodochitis fibrinosa. *Clin Otolaryngol* 2003;96:245–7. Article in Japanese.
- [20] Tsutsumi Y, Sugiyama Y, Ishibashi S, et al. *Jap J Oral Maxillofac Surg* 2033;49:623–6. Article in Japanese.
- [21] Yamamoto T. A case of sialodochitis fibrinosa accompanied by meal-induced, recurrent swelling of parotid glands and Urticaria. *Jap J Dermatol* 2004;11:187–92. Article in Japanese.
- [22] Nemoto T, Matsui Y, Ohno K, et al. A case of sialodochitis fibrinosa (Kussmaul's disease) bilaterally affecting the submandibular glands.). *Jap J Oral Maxillofac Surg* 2006;52:81–4. Article in Japanese.
- [23] Otsuka S, Tsunoda K, Takamori K, et al. Two cases of sialodochitis fibrinosa including cases accompanying with Sjögren's Syndrome. *J Jap Soc Oral Mucous Membr* 2006;2:59–66. Article in Japanese.
- [24] Shimada T, Okano H, Hisa Y. A case of severe dilatation of the parotid duct due to fibrinous sialodochitis. *Acta Otolaryngol* 2006;126:1112–4.
- [25] Pollak N, Templer JW, Esebua M, et al. Episodic painful parotid swelling caused by sialodochitis with eosinophilic inflammation: a new entity. *Otolaryngol Neck Surg* 2009;140:132–3.
- [26] Miyagi N. A case of sialodochitis fibrinosa affecting the parotid gland accompanied by SLE. *Jap J Oral Diagn/Oral Med* 2009;22:96–9. Article in Japanese.
- [27] Frati F, Boccardo R, Scurati S, et al. Idiopathic eosinophilic parotitis in an eight-year-old boy: a case report. *J Med Case Rep* 2011;5:385–6.
- [28] Tsuchiya A, Aizawa N, Sato K. Three cases of sialodochitis fibrinosa. *Practica Otorhinolaryngol* 2012;25:173–7. Article in Japanese.
- [29] Sakaguchi O, Fuji S, Tsurushima H, et al. A case of sialodochitis fibrinosa affecting bilateral submandibular glands. *J Jap Stomatol Soc* 2016;65:44–50. Article in Japanese.