



Received: 2015.12.12
Accepted: 2016.02.23
Published: 2016.10.01

Authors' Contribution:

- A** Study Design
- B** Data Collection
- C** Statistical Analysis
- D** Data Interpretation
- E** Manuscript Preparation
- F** Literature Search
- G** Funds Collection

Ultrasonography of Extravaginal Testicular Torsion in Neonates

Przemysław Bombiński^{1ABCDEF}, Stanisław Warchol^{2BCDEF}, Michał Brzewski^{1ACDE},
Zofia Majkowska^{1BCD}, Teresa Dudek-Warchol^{2GD}, Maria Żerańska^{2GD},
Małgorzata Panek^{2GD}, Magdalena Drop^{1GD}

¹ Department of Pediatric Radiology, Medical University of Warsaw, Warsaw, Poland

² Department of Pediatric Surgery and Urology, Medical University of Warsaw, Warsaw, Poland

Author's address: Przemysław Bombiński, Department of Pediatric Radiology, Medical University of Warsaw, Warsaw, Poland, e-mail: przebom@op.pl

Preliminary compilation of the material was used for the ECR presentation: Extravaginal testicular torsion in neonates – review of clinical symptoms with ultrasound and intraoperative photo documentation. ECR 2014. DOI: 10.1594/ecr2014/C-1013

Summary

Background:

Extravaginal testicular torsion (ETT), also called prenatal or perinatal, occurs prenatally and is present at birth or appears within the first month of life. It has different etiology than intravaginal torsion, which appears later in life. Testicular torsion must be taken into consideration in differential diagnosis of acute scrotum and should be confirmed or ruled out at first diagnostic step. Ultrasonography is a basic imaging modality, however diagnostic pitfalls are still possible. There is still wide discussion concerning management of ETT, which varies from immediate orchiectomy to conservative treatment resulting in testicle atrophy.

Material/Methods:

In this article we present ultrasonographic spectrum of ETT in neonates, which were diagnosed and treated in our hospital during the last 8 years (2008–2015), in correlation with clinical and intraoperative findings.

Results:

Thirteen neonates with ETT were enrolled in the study – 11 patients with a single testicle affected and 2 patients with bilateral testicular torsion. Most common signs on clinical examination were: hardened and enlarged testicle and discoloration of the scrotum. Most common ultrasonographic signs were: abnormal size or echostructure of the affected testicle and absence of the blood flow in Doppler ultrasonography. In 3 patients ultrasound elastography was performed, which appeared very useful in testicle structure assessment.

Conclusions:

Testicular torsion may concern boys even in the perinatal period. Ultrasonographic picture of acute scrotum in young boys may be confused. Coexistence of the abnormal size or echostructure of the torsed testicle with absence of the blood flow in Doppler ultrasonography appear as very specific but late ultrasonographic signs. Ultrasound elastography may be a very useful tool for visualisation of a very common clinical sign – hardening of the necrotic testicle.

MeSH Keywords:

Child • General Surgery • Pediatrics • Radiology

PDF file:

<http://www.polradiol.com/abstract/index/idArt/897066>

Background

Extravaginal testicular torsion (ETT), also referred to as prenatal or perinatal, is a rare cause of acute scrotum in early childhood. The torsion occurs during pregnancy

(antenatal torsion) or within one month after birth (post-natal torsion) [1]. Apart from clinical examination, Doppler ultrasonography constitutes the ground for diagnostics. The current paper presents our own experience with

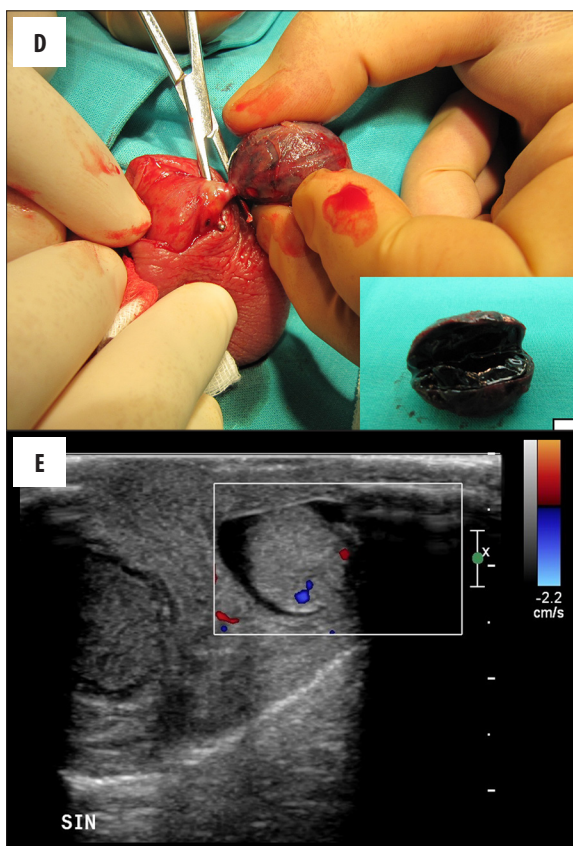
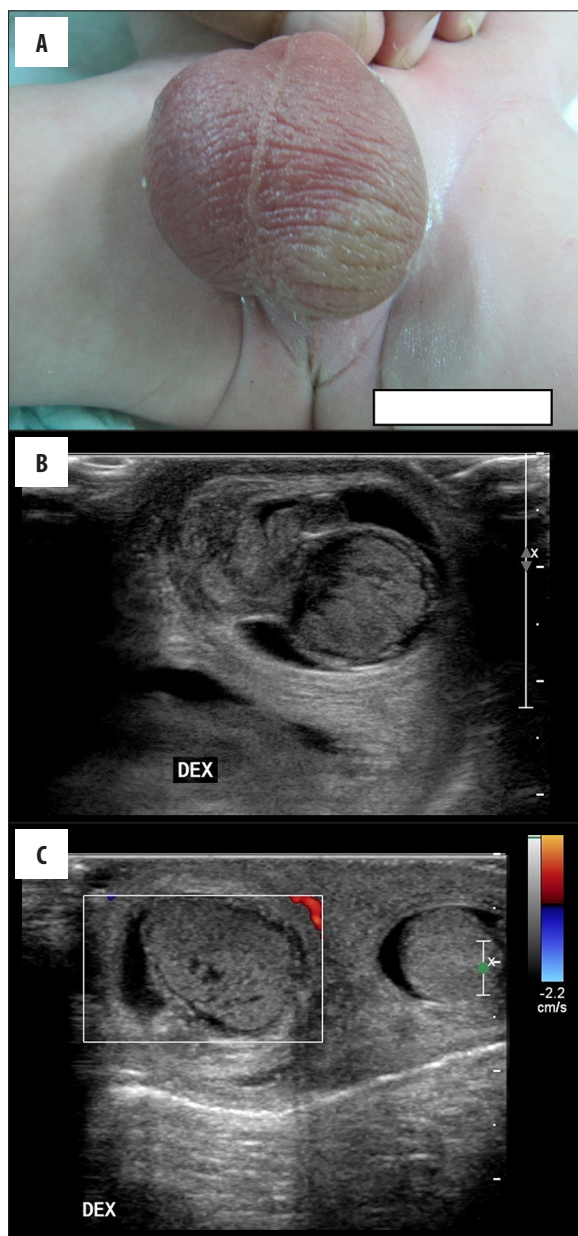


Figure 1. Newborn in the 1-st day of life with swelling and redness of the right hemi-scrotum (A). Ultrasonography revealed enlarged and heterogenous right testicle (B), without blood flow in Doppler ultrasonography (C). Intraoperative findings confirmed right testicle necrosis (D). For comparison – normal left testicle in the same patient, with blood flow visualized in several vessels (E).

diagnosing extravaginal testicular torsion with the use of ultrasonography.

Material and Methods

Thirteen boys were treated between 2008 and 2015 in our hospital due to extravaginal testicular torsion. In 10 of them, clinical symptoms were observed immediately after birth, and in 3 cases the symptoms occurred within the first month of life. The most frequently observed clinical symptoms in the first group included: increase in the consistency of the testicle (testicle that is „hard” in palpation) and livid colour of the scrotum (Figure 1A). The symptoms of acute scrotum, i.e. swelling, redness and pain of the scrotum on palpation, prevailed in the second group. In total, 15 cases of testicular torsion were analysed. In 7 patients, the affected testicle was the right one, in 4 cases – the left one. Bilateral torsion was observed in 2 patients. Preliminary diagnosis was made

on the basis of the clinical examination performed by the paediatric surgeon. Ultrasonography was performed in all cases and it showed: reduction in blood flow or absence of blood flow in Doppler examination (10 testicles), inhomogeneous echogenicity of the testicle with hypoechoic necrotic areas (7 testicles) (Figure 1B), enlargement of the scrotum (7 testicles), thickening of testicular tunicae (7 cases), hydrocele of the testicle (6 cases). In 4 cases, the testicles were small with mixed echogenicity areas (hypo- and hyperechogenic), which suggested atrophic transformation. In 4 cases ultrasonography revealed physiological echostructure of the testicle – in 2 cases of prenatal torsion and 2 cases of postnatal torsion (in 3 cases in this group there was no unequivocal ultrasonographic statement whether the blood flow was present in the testicles, in the fourth case the testicular flow was increased over the course of acute torsion).

All boys underwent emergency surgery immediately after the diagnosis was established. Surgical protocol included: orchiectomy of the testicle affected by the torsion with fixation of the other testicle (5 cases) (Figure 1D), orchiectomy without the fixation of the other testicle (7 cases) and the removal of both necrotically altered testicles (1 case). In one patient with bilateral torsion, the testicle with features of haemorrhagic necrosis was removed, and the other,

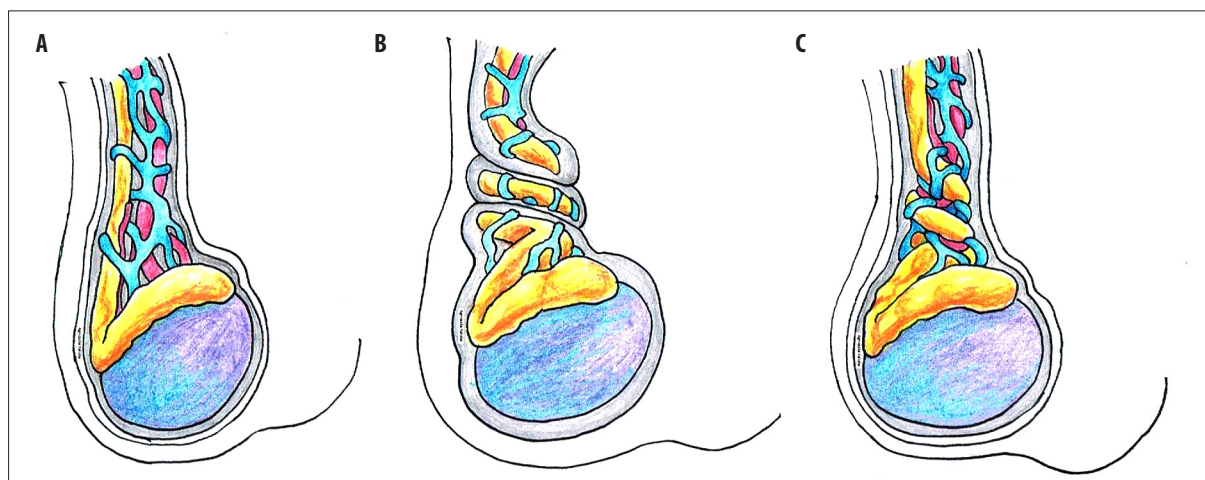


Figure 2. Testicular torsion anatomical background: (A) normal structures of the scrotum, (B) extravaginal testicular torsion (with tunica vaginalis involvement), (C) intravaginal testicular torsion (within tunica vaginalis). Prepared by Dr. Agnieszka Kalicka.

atrophied one, was left and fixated due to the possibility of preserving endocrine function.

Discussion

Extravaginal testicular torsion occurs rarely, its incidence is estimated at 6: 100.000 [2-4]. Its aetiology has not been clarified yet, it has been suggested that there is a relationship between the increased mobility of the testicular tunica vaginalis in relation to the wall of the scrotum [5-6], related to the lack of fixation that occurs a few weeks after birth. This mechanism is different from the intravaginal torsion that develops at later stages of life – the testicle undergoes torsion inside the fixated tunica vaginalis (Figure 2).

In most cases, the torsion develops prenatally (antenatal torsion), and the testicle undergoes irreversible necrosis [6]. Increased consistency („hardness”) of the testicle is the dominating symptom in the clinical examination performed after birth [7]. Different clinical course is observed in cases in which the torsion develops postnatally (postnatal torsion). This condition requires urgent diagnostics and surgical treatment, but general symptoms such as pain or irritability of the child are not characteristic and may delay the delivery of the correct diagnosis. Attention should be paid to local symptoms such as swelling, redness or pain on palpation of the scrotum.

Testicular torsion, testicular tumour, orchitis and epididymitis, inguinal hernia with or without the incarceration of intestinal loops, testicular hydrocele, and testicular haematoma should be included in differential diagnostics of pathological lesions of the scrotum in neonates [5,8].

Acute torsion requires urgent surgical intervention. Ischemia of the testicle leads to the development of irreversible alterations within a short period of time. Spermatogenesis is lost within 4-6 hours, and 12 hours after torsion Leydig cells that are responsible for testosterone production undergo destruction [9,10].

However, there is no established management protocol in case the torsion and irreversible necrotic alterations have

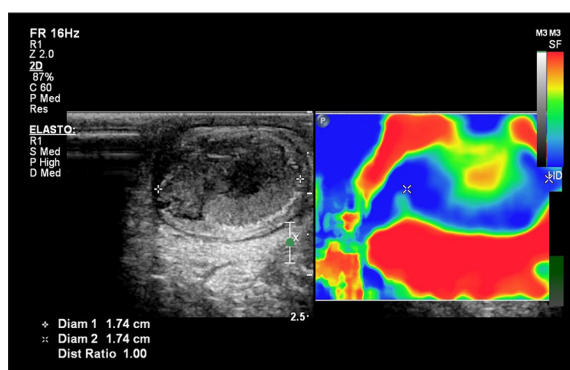


Figure 3. A One-day-old newborn with suspected prenatal testicular torsion. Ultrasonography revealed enlarged and heterogenous right testicle. Elastography revealed abnormal structure of the right testicle – stiffer peripheral part with soft-tissue central part (hard tissues are displayed in blue, soft tissues – in red).

already developed earlier in prenatal period. Depending on the centre, the management varies and includes immediate removal of the necrotic testicle or conservative treatment with keeping of the gonad [3,9,11-15]. Some authors suggest that the altered testicle should be left in place as trace endocrine function may be preserved, even if vascular flow is not observed in diagnostic imaging. The argument for testicle removal is the possibility of a generalised infection of the neonate, as well as possible production of antibodies that may destroy the other, healthy testicle [16]. Amputation of the necrotic testicle is the standard procedure at our centre.

Colour Doppler ultrasonography is frequently considered conclusive in the diagnostic process [4,8] (Figure 1C). It should be underlined, however, that even in healthy boys the evaluation of blood flow in testes may be difficult [17]. The absence of blood flow in Doppler examination was unequivocally determined in our material only in those cases in which morphological changes of the testicle were observed (distinct change in echostructure or size of the testicle). In other cases, the assessment of blood flow was not reliable, as in the neonatal period testicular blood

flow, even in healthy boys, is weakly visible (it also applies to older boys in the first years of life). The value of the Doppler examination also depends on the class of the ultrasonography device – more credible outcomes are achieved if high-class equipment is used (Figure 1E). It seems that unequivocal diagnosis of testicular torsion in young boys can be made if such symptoms as the change in echostructure or size of the testicle, and reduction in blood flow or even no blood flow are observed (even though these are late symptoms and in ambiguous cases they should not delay surgical intervention!).

Increased hardness in clinical examination is the most frequently observed clinical symptom of a necrotic testicle after torsion. The examination that includes elastographic assessment may be used for a more precise evaluation of the structure of the testicle (Figure 3). Such an examination, performed in our material in three patients,

confirmed the changes in consistency and structure of the gonad. The evaluation of the usefulness of this method and determination of diagnostic criteria requires further research based on a larger number of cases.

Conclusions

Testicular torsion can occur in boys in the perinatal period. The basic aim of diagnostic imaging in cases of scrotal pathology is the exclusion of testicular torsion. However, in many cases the picture can be equivocal. The diagnosis of testicular torsion with the use of ultrasonography can be made if symptoms such as changes in echostructure or size of the testicle are observed concurrently with reduction or lack of the blood flow. Elastography may be useful in order to visualise the most frequent clinical symptom – increased hardness of the necrotic testicle. Management protocol for these patients is still a topic for debate.

References:

1. Brandt MT, Sheldon CA, Wacksman J, Matthews P: Prenatal testicular torsion: Principles of management. *J Urol*, 1992; 147: 670–72
2. Nandi B, Murphy FL: Neonatal testicular torsion: A systematic literature review. *Pediatr Surg Int*, 2011; 27: 1037–40
3. Djahangirian O, Ouimet A, Saint-Vil D: Timing and surgical management of neonatal testicular torsions. *J Pediatr Surg*, 2010; 45: 1012–15
4. Kowal A, Wieprzowski L, Sawicka E: Bilateral neonatal testicular torsion – case report. *Pediatrics Polska*, 2013; 88(3): 290–93
5. Callewaert PRH, Van Kerrebroeck P: New insights into perinatal testicular torsion. *Eur J Pediatr*, 2010; 169: 705–12
6. Kaye JD, Levitt SB, Friedman SC et al: Neonatal torsion: A 14-year experience and proposed algorithm for management. *J Urol*, 2008; 179(6): 2377–83
7. Baptist EC, Amin PV: Perinatal testicular torsion and the hard testicle. *J Perinatol*, 1996; 16: 67–68
8. Van der Sluijs JW, Den Hollander JC et al: Prenatal testicular torsion: Diagnosis and natural course, an ultrasonographic study. *Eur Radiol*, 2004; 14: 250–55
9. Arena F, Nicotina PA, Romeo C et al: Prenatal testicular torsion: Ultrasonographic features, management and histopathological findings. *Int J Urol*, 2006; 13: 135–41
10. Bagci S, Bachour H, Woelfle JF et al: Bilateral perinatal testicular torsion in an infant: A rare neonatal emergency. *Pediatr Int*, 2010; 52(4): e227–28
11. Ahmed SJ, Kaplan GW, DeCambre ME: Perinatal testicular torsion: preoperative radiological findings and the argument for urgent surgical exploration. *J Pediatr Surg*, 2008; 43: 1563–65
12. Yerkes EB, Robertson FM, Gitlin J et al: Management of perinatal torsion: Today, tomorrow or never? *J Urol*, 2005; 174: 1579–83
13. Stone KT, Kass EJ, Cacciarelli AA et al: Pediatric urology: Management of suspected antenatal torsion, what is the best strategy? *J Urol*, 1995; 153: 782–84
14. Broderick KM, Martin BG, Herndon CD et al: The current state of surgical practice for neonatal torsion: A survey of pediatric urologists. *J Pediatr Urol*, 2013; 9(5): 542–45
15. Guerra LA, Wiesenthal J, Pike J, Leonard MP: Management of neonatal testicular torsion: which way to turn? *Can Urol Assoc J*, 2008; 2(4): 376–79
16. Rybkiewicz M: Long term and late results of treatment in patients with a history of testicular torsion. *Ann Acad Med Stetin*, 2001; 47: 61–75
17. Brzewski M: Odrębność ultrasonografii dopplerowskiej u dzieci. In: Małek G. Ultrasonografia dopplerowska. Zastosowania kliniczne. Tom 2. Str. 144. Wyd. Medipage, 2003 [in Polish]