

## CASE REPORT

# Leptomeningeal carcinomatosis in non-small-cell lung cancer: initial response to erlotinib followed by relapse despite continuing radiological resolution of disease

Alvin J. X. Lee<sup>1,\*</sup>, Rachel Benamore<sup>2</sup>, Monika Hofer<sup>3</sup> and Meenali Chitnis<sup>1</sup>

<sup>1</sup>Department of Oncology, Oxford University Hospitals NHS Foundation Trust, Churchill Hospital, Old Road, Oxford OX3 7LE, UK, <sup>2</sup>Department of Radiology, Oxford University Hospitals NHS Foundation Trust, Churchill Hospital, Old Road, Oxford OX3 7LE, UK, and <sup>3</sup>Department of Neuropathology, Oxford University Hospitals NHS Foundation Trust, John Radcliffe Hospital, Headley Way, Oxford OX3 9DU, UK

\*Correspondence address. Department of Oncology, Oxford University Hospitals NHS Foundation Trust, Churchill Hospital, Old Road, Oxford OX3 7LE, UK. Tel: 03003047777; E-mail: A.J.LEE@UCL.AC.UK

## Abstract

A 60-year-old male was diagnosed with T3, N3, M1b epidermal growth factor receptor (EGFR) mutant lung adenocarcinoma. Five months later he developed significant headaches, weakness and numbness of the left leg, and unsteadiness of gait. Magnetic resonance imaging (MRI) brain demonstrated subtle gyral enhancement indicative of early leptomeningeal infiltration. He was commenced on second-line erlotinib which improved his lower limb symptoms. Three months later he developed increased urinary frequency and redeveloped leg symptoms. MRI brain showed improvement in the gyral enhancement. Four weeks later, the patient developed new onset confusion and decrease in mobility. Examination of the cerebrospinal fluid (CSF) demonstrated leptomeningeal carcinomatosis. This case demonstrates radiological and clinical response of leptomeningeal disease to erlotinib in EGFR mutant lung cancer with subsequent clinical relapse despite continued radiological resolution of leptomeningeal disease. This suggests that CSF examination should be considered when monitoring leptomeningeal disease response following treatment as the disease can be undetectable on repeat radiological imaging.

## INTRODUCTION

Leptomeningeal carcinomatosis is the infiltration of the leptomeninges by malignant cells. Without treatment the median survival is 4–6 weeks and death occurs from progressive neurological dysfunction [1]. Approximately 9% of epidermal growth factor receptor (EGFR) mutant non-small cell lung cancer (NSCLC) patients proceed to develop leptomeningeal carcinomatosis [2].

Previous case reports have demonstrated that erlotinib, an EGFR tyrosine kinase inhibitor (TKI), can induce clinical and

radiological response in EGFR mutant NSCLC patients with leptomeningeal carcinomatosis [2, 3].

## CASE REPORT

A 60-year-old male with no significant medical history was diagnosed with T3, N3, M1b lung adenocarcinoma in May 2015. He initially presented to his General Practitioner with an unresolving cough. Investigations revealed the primary lung tumour and lytic bone metastases, with loss in height of L4. Histology from

Received: May 24, 2016. Revised: June 28, 2016. Accepted: July 7, 2016

© The Author 2016. Published by Oxford University Press.

This is an Open Access article distributed under the terms of the Creative Commons Attribution Non-Commercial License (<http://creativecommons.org/licenses/by-nc/4.0/>), which permits non-commercial re-use, distribution, and reproduction in any medium, provided the original work is properly cited. For commercial re-use, please contact [journals.permissions@oup.com](mailto:journals.permissions@oup.com)

bronchoscopy confirmed a lung adenocarcinoma with an EGFR exon 19 deletion mutation. He received palliative radiotherapy to L3-L5 vertebrae, and four cycles of Cisplatin/Pemetrexed chemotherapy.

In October 2015, he developed significant headaches, weakness and numbness of the left leg, and unsteadiness of gait. Magnetic resonance imaging (MRI) brain demonstrated multiple skull metastases and subtle gyral enhancement indicative of early leptomeningeal infiltration (Fig. 1a). MRI spine demonstrated multifocal marrow deposits with new vertebral collapse in T6 but no evidence of significant cord compression. He received radiotherapy to base of skull and T5–T7 vertebra. In view of his EGFR mutation status, he was commenced on second-line treatment with erlotinib at standard oral dosing. His leg weakness and unsteadiness improved.

In January 2016 he developed increased urinary frequency with a feeling of incomplete emptying of the bladder. His prostate was not enlarged, prostate specific antigen (PSA) was not raised and urine cultures were negative. A bladder ultrasound demonstrated a large residual with no evidence of outflow obstruction. During this period the patient redeveloped leg weakness and unsteadiness of gait. MRI spine demonstrated resolution of the soft tissue at T6 level, and MRI brain showed an improvement in the gyral enhancement (Fig. 1b). A computed tomography thorax/abdomen/pelvis performed at the same time demonstrated minor interval disease response.

Four weeks later, the patient was admitted to hospital as an emergency with new onset confusion and a decrease in mobility. He was found to be in urinary retention and a catheter was inserted. Left lower limb weakness was demonstrated. Hip flexors and knee extensors were 4/5 on the Medical Research Council (MRC) power scale, ankle dorsiflexion 1/5 and great toe extension 3/5. Abbreviated Mental Test Score fluctuated between 7/10 and 10/10 on consecutive days. MRI spine showed

no evidence of cord compression, and MRI brain did not demonstrate evidence of radiological progression (Fig. 1c). Lumbar puncture and examination of the cerebrospinal fluid (CSF), however, revealed atypical epithelioid cells likely to represent malignant cells, consistent with intrathecal dissemination of the known metastatic lung adenocarcinoma (Fig. 2). The patient died 2 weeks later.

## DISCUSSION

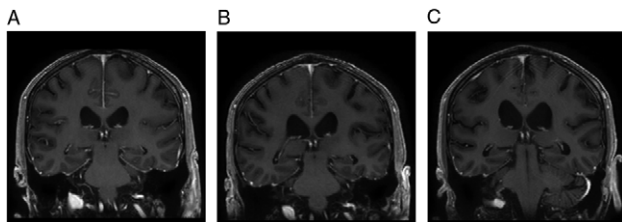
Erlotinib is an EGFR TKI that has been demonstrated to cross the blood brain barrier (BBB) and accumulates in the CSF at concentrations greater than its IC50 when taken at standard oral doses [4, 5]. This drug is able to permeate across the BBB due to its low molecular weight and the disruption of the integrity of the BBB during the metastatic process [6].

The use of erlotinib has previously been shown to induce clinical and radiological response in EGFR NSCLC patients with leptomeningeal carcinomatosis [2, 3] with an increase in overall survival and performance status following treatment [7]. EGFR TKI treatment naïve EGFR mutant leptomeningeal disease responds to treatment with an EGFR TKI and continued radiological response is associated with prolonged survival. However, the median time to progression or symptom deterioration in patients with leptomeningeal disease receiving EGFR TKIs remains short, at 2.2 months [2]. Ascertaining the cause of death in patients with leptomeningeal disease can be difficult as they often have concomitant refractory progressive systemic disease [8].

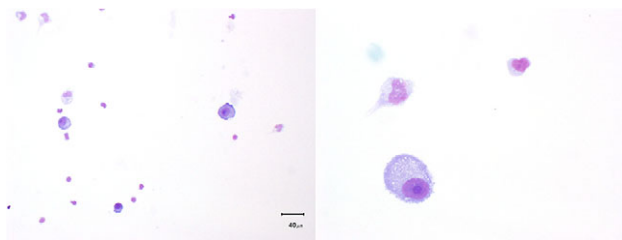
MRI brain imaging has a sensitivity of approximately 70% for the detection of leptomeningeal disease [9] and CSF examination is the gold standard for diagnosing leptomeningeal carcinomatosis [10]. However, when it comes to assessing leptomeningeal disease response following treatment, methods for assessment of outcome and response criteria have not been standardised. Assessment methods that have been looked at include MRI imaging which may not be sufficiently sensitive and lacks a consensus criteria for assessing response, CSF examination which is invasive and may require repeat sampling, and clinical examination, which can be variable and subjective [8].

Here we demonstrate a case of an EGFR mutant lung adenocarcinoma patient with leptomeningeal carcinomatosis who initially responded symptomatically and radiologically to second-line erlotinib. Despite demonstrating sustained radiological response to erlotinib with regards to his systemic and leptomeningeal disease, he subsequently relapsed with symptoms suggestive of leptomeningeal carcinomatosis. Recurrence of leptomeningeal disease was proven on CSF examination. Although it was unfortunate that his leptomeningeal disease had recurred, the confirmation of the diagnosis provided the patient and his family the opportunity to plan for end of life care and related issues, especially as his radiological imaging gave the impression that he was still responding to treatment. His duration of survival following erlotinib treatment was comparable to that in previous reports [2].

Previous studies have focused on radiological response to EGFR TKIs as their outcome measure. However, our report suggests that response monitoring of leptomeningeal disease following erlotinib treatment cannot be reliably measured by radiological criteria alone. Clinical history and examination, and CSF cytology needs to be evaluated especially as there is a lack of consensus regarding assessment methods and



**Figure 1:** Coronal T1W post gadolinium MRI brain images. (a) Prior to erlotinib treatment demonstrating leptomeningeal enhancement, most notable in the parafalcine region and overlying the temporal lobes. (b) After 12 weeks of erlotinib treatment. There is a decrease in leptomeningeal enhancement. (c) After 16 weeks of erlotinib treatment. There is no progression in leptomeningeal enhancement



**Figure 2:** Photographs of CSF cytopspins stained with MGG (May Grunwald Giemsa) stain. The low power image on the left shows scattered tumour cells against a background of mononuclear cells. The high power image on the right shows a tumour cell in more detail. Note the large prominent nucleolus, the generally large size of the cell, the deep blue cytoplasm and well-defined cytoplasmic border

outcome criteria for monitoring leptomeningeal disease response. CSF examination should be considered in all patients with EGFR mutant lung cancer when monitoring leptomeningeal disease response following treatment as the disease can be undetectable on repeat radiological imaging. Accurate diagnosis and response monitoring helps to inform prognosis and this information can be highly valued by patients and their next of kin.

### CONFLICT OF INTEREST STATEMENT

None declared.

### FUNDING

The authors received no specific grant from any funding agency in the public, commercial or not-for-profit sectors.

### ETHICAL APPROVAL

None required.

### CONSENT

Permission granted by the patient and wife.

### GUARANTOR

Alvin J. X. Lee.

### REFERENCES

- Grossman SA, Krabak MJ. Leptomeningeal carcinomatosis. *Cancer Treat Rev* 1999;25:103–19.
- Kuiper JL, Hendriks LE, van der Wekken AJ, de Langen AJ, Bahce I, Thunnissen E, et al. Treatment and survival of patients with EGFR-mutated non-small cell lung cancer and leptomeningeal metastasis: a retrospective cohort analysis. *Lung Cancer* 2015;89:255–61.
- Wagner M, Besse B, Balleyguier C, Soria J-C. Leptomeningeal and medullary response to second-line erlotinib in lung adenocarcinoma. *J Thorac Oncol* 2008;3:677–9.
- Deng Y, Feng W, Wu J, Chen Z, Tang Y, Zhang HUA, et al. The concentration of erlotinib in the cerebrospinal fluid of patients with brain metastasis from non-small-cell lung cancer. *Mol Clin Oncol* 2014;2:116–20.
- Masuda T, Hattori N, Hamada A, Iwamoto H, Ohshimo S, Kanehara M, et al. Erlotinib efficacy and cerebrospinal fluid concentration in patients with lung adenocarcinoma developing leptomeningeal metastases during gefitinib therapy. *Cancer Chemother Pharmacol* 2011;67:1465–9.
- Zhang J, Yu J, Sun X, Meng X. Epidermal growth factor receptor tyrosine kinase inhibitors in the treatment of central nerve system metastases from non-small cell lung cancer. *Cancer Lett* 2014;351:6–12.
- Umamura S, Tsubouchi K, Yoshioka H, Hotta K, Takigawa N, Fujiwara K, et al. Clinical outcome in patients with leptomeningeal metastasis from non-small cell lung cancer: Okayama lung cancer study group. *Lung Cancer* 2012;77:134–9.
- Chamberlain M, Soffiotti R, Raizer J, Rudà R, Brandsma D, Boogerd W, et al. Leptomeningeal metastasis: a response assessment in neuro-oncology critical review of endpoints and response criteria of published randomized clinical trials. *Neuro Oncol* 2014;16:1176–85.
- Sze G, Soletsky S, Bronen R, Krol G. MR imaging of the cranial meninges with emphasis on contrast enhancement and meningeal carcinomatosis. *AJNR Am J Neuroradiol* 1989;10:965–75.
- Taillibert S, Laigle-Donadey F, Chodkiewicz C, Sanson M, Hoang-Xuan K, Delattre JY. Leptomeningeal metastases from solid malignancy: a review. *J Neurooncol* 2005;75:85–99.