



# Surgical treatment of secondary hyperparathyroidism combined with Sagliker syndrome caused by chronic renal failure: a case report

Yi Pang, Xiangchao Meng

Department of General Surgery, Tianjin Third Central Hospital, Tianjin Institute of Hepatobiliary Disease, Tianjin Key Laboratory of Artificial Cell, Tianjin, China

Correspondence to: Xiangchao Meng. Department of General Surgery, Tianjin Third Central Hospital, Tianjin Institute of Hepatobiliary Disease, Tianjin Key Laboratory of Artificial Cell, Tianjin 300170, China. Email: mxc5168@sina.com.

**Background:** Sagliker syndrome is caused by severe secondary hyperparathyroidism in hemodialysis patients with chronic renal failure. It is mainly manifested by disturbances of calcium and phosphorus metabolism and bone changes, which eventually lead to abnormal changes in facial appearance and morphology, seriously affecting the quality of life of patients. With the improvement of management mode and technology for hemodialysis in chronic renal failure, the incidence of severe secondary hyperparathyroidism related to hemodialysis is relatively reduced. Therefore, Sagliker syndrome is more rare. How to early identify and choose the appropriate treatment for Sagliker syndrome is particularly important.

**Case Description:** A 34-year-old female patient with uremia, who underwent regular hemodialysis at the Blood Purification Center of Tianjin Third Central Hospital, developed Sagliker syndrome. The general data, clinical symptoms, height changes, biochemical indicators (serum calcium, phosphorus, alkaline phosphatase, parathyroid hormone, hemoglobin, and hematocrit), and parathyroid emission computerized tomography (ECT) were collected and analyzed. The patient had a history of hemodialysis with chronic renal failure for 6 years, and presented with bone pain for 2 years. Laboratory tests showed parathyroid hormone was 2,269 pg/mL and ECT showed 3 parathyroid hyperplasia. Finally, total parathyroidectomy and forearm transplantation were performed. The level of parathyroid hormone was significantly lower than that before the operation. On the first postoperative day, the level of parathyroid hormone decreased to 28.3 pg/mL. Four months later, the bone pain symptoms of the patient were significantly improved compared with those before the operation.

**Conclusions:** Sagliker syndrome is a special syndrome in maintenance hemodialysis patients with refractory secondary hyperparathyroidism. Early monitoring and standardized treatment of secondary hyperparathyroidism may prevent the occurrence of Sagliker syndrome. Early identification and diagnosis of Sagliker syndrome and the choice of appropriate treatment will have an important impact for the prognosis.

**Keywords:** Hemodialysis; Sagliker syndrome; secondary hyperparathyroidism; total parathyroidectomy plus autotransplantation; case report

Submitted Aug 02, 2022. Accepted for publication Sep 06, 2022.

doi: 10.21037/gs-22-479

View this article at: <https://dx.doi.org/10.21037/gs-22-479>

## Introduction

In 2004, Sagliker *et al.* reported that in patients with chronic renal failure undergoing hemodialysis, hyperparathyroidism could lead to calcium and phosphorus metabolism disorders

in the patient's body, and a series of changes occurred under the periosteum, resulting in a group of syndromes dominated by abnormal facial morphological changes, which was named Sagliker syndrome (1). The main facial



**Figure 1** Facial features before surgery.

manifestations include the maxilla increasing forward and downward as a whole, and the front of the mandible increasing vertically. Eventually, the entire face of the patient shows a significant increase in height compared with before onset, and the face changes like a “hippo” (2). Due to the maxillofacial deformity, oral structural changes, and spongy and brittle craniofacial bones in Sagliker syndrome patients, they are prone to injury.

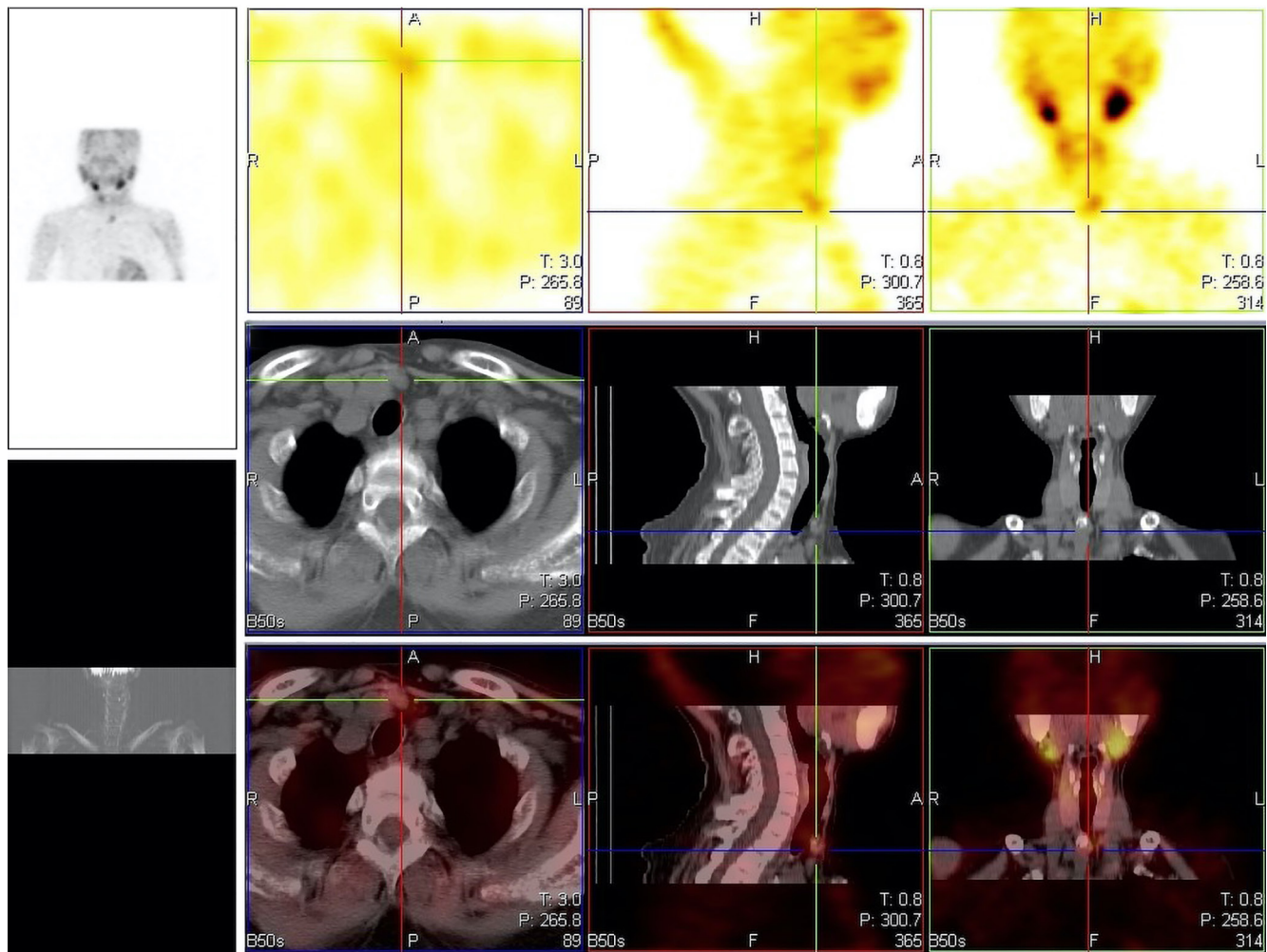
At present, it is believed that the main reason for the development of Sagliker syndrome is secondary hyperparathyroidism (SHPT). In recent years, progress has been made in the treatment of SHPT in maintenance hemodialysis patients, and the serious complications of this disease have improved. Furthermore, many patients undergo surgical intervention before the appearance of Sagliker syndrome. With the improvement of management mode and technology for hemodialysis in chronic renal failure, the incidence of severe SHPT related to hemodialysis is relatively reduced. Therefore, Sagliker syndrome is more rare. How to early identify and choose the appropriate treatment for Sagliker syndrome is particularly important. Here, we report a case who was recently diagnosed with Sagliker syndrome in our hospital and finally underwent surgery. We present the following case in accordance with the CARE reporting checklist (available at <https://gs.amegroups.com/article/view/10.21037/gS-22-479/rc>).

### Case presentation

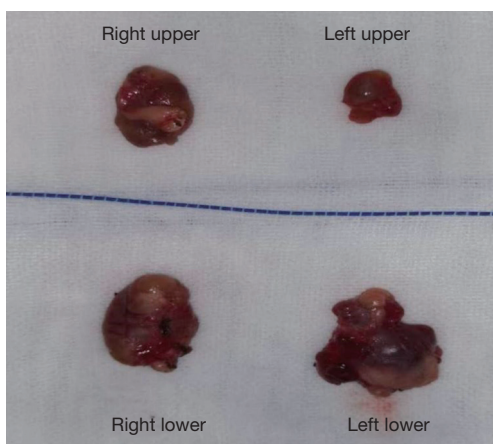
The patient, who was a 34-year-old female [58 kg, body mass index (BMI) 23.8 kg/m<sup>2</sup>], was admitted to hospital for 19 months due to bone pain with elevated parathyroid hormone. She had a previous history of hypertension for

7 years, up to 190/100 mmHg. The patient started regular hemodialysis 6 years ago due to chronic renal failure (uremia stage) and developed bone pain 2 years ago. It was found that parathyroid hormone was elevated 19 months ago, up to 3,600 pg/mL, and no treatment was taken. One year ago, the face began to deform, and the jaw of the patient was prominently protruded, the cheeks were bulging, the nose was retracted, and the lips could not be closed (*Figure 1*). The teeth were loose, the craniofacial bone was spongy, and the thoracic bones were deformed. Clubbed fingers and bone tenderness all over the body were obvious. Her self-reported height decreased by about 10 cm in the past 2 years. Laboratory tests on admission showed parathyroid hormone 2,269 pg/mL, serum calcium 2.32 mmol/L, serum phosphorus 1.58 mmol/L, serum potassium 4.28 mmol/L, alkaline phosphatase 2,247 IU/L, red blood cell count  $2.58 \times 10^{12}$ /L, hemoglobin 68 g/L, and hematocrit 0.22. Parathyroid ultrasonography showed echoes on the deep dorsal surface of the lower right lobe, the dorsal side of the middle left lobe, and the lower pole of the left lobe, which were considered parathyroid tissue. Parathyroid emission computerized tomography (ECT) suggested concentrated areas of tracer distribution below the lower pole of the bilobed thyroid and above the upper pole of the right lobe, which were considered to be hyperfunctioning parathyroid tissues (3 pieces) (*Figure 2*). Echocardiography showed calcification of the mitral valve anterior leaflet root and posterior leaflet annulus, left atrial enlargement, left ventricular hypertrophy, and decreased diastolic function. Head computed tomography (CT) showed increased density shadows in the craniofacial bone, subcutaneous soft tissue, and anterior wall of the maxillary sinus. Bone mineral density examination showed osteoporosis in the lumbar spine and bilateral hip joints.

After admission, the patient was diagnosed with Sagliker syndrome, SHPT, and chronic renal failure. Due to the ineffectiveness of vitamin D pulse therapy, after multi-disciplinary treatment, it was decided that the patient would undergo parathyroidectomy plus forearm autografting under general anesthesia. The whole process was performed under neurological monitoring to avoid injury to the recurrent laryngeal nerve and superior laryngeal nerve. The operation went smoothly. Four parathyroid glands were completely removed (*Figure 3*) and an autograft was performed on the right forearm. On the first day after the operation, re-examination of laboratory indicators showed that the level of parathyroid hormone was 28.3 pg/mL,



**Figure 2** Manifestations of hyperparathyroidism on ECT. ECT, emission computerized tomography.

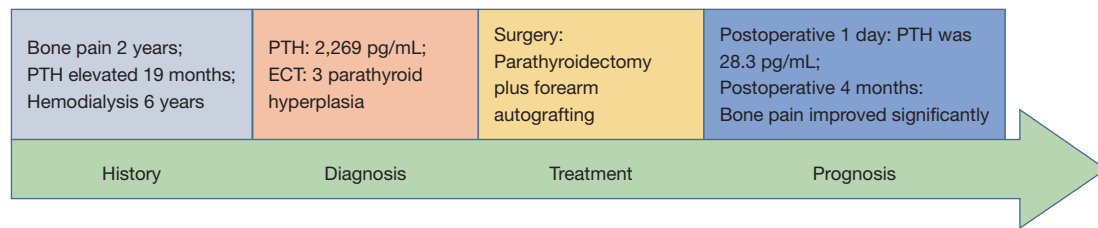


**Figure 3** Four hyperplastic parathyroid glands removed during surgery.

which was significantly lower than that before the operation. Four months after the operation, parathyroid hormone and alkaline phosphatase returned to the normal range (*Table 1*). The bone pain symptoms of the patient were significantly improved compared with those before the operation, though examinations reflecting bone changes have not yet been carried out. Diagnosis and treatment timeline of the patient is shown in *Figure 4*. All procedures performed in this study were in accordance with the ethical standards of the institutional and/or national research committee(s) and with the Helsinki Declaration (as revised in 2013). Written informed consent was obtained from the patient for publication of this case report and accompanying images. A copy of the written consent is available for review by the editorial office of this journal.

**Table 1** Comparison of the main laboratory indicators before and after surgery

Follow-up time	Alkaline phosphatase	Parathyroid hormone	Calcium	Phosphorus	Albumin
Preoperative	2,247 IU/L	2,269 pg/mL	2.32 mmol/L	1.58 mmol/L	35.3 g/L
Postoperative 1 day	1,675 IU/L	28.3 pg/mL	1.72 mmol/L	1.72 mmol/L	32.0 g/L
Postoperative 4 months	391 IU/L	19.9 pg/mL	2.50 mmol/L	0.50 mmol/L	39.0 g/L

**Figure 4** Diagnosis and treatment timeline of the patient. PTH, parathyroid hormone; ECT, emission computerized tomography.

## Discussion

Saglikler syndrome is usually accompanied by a variety of clinical manifestations, including bone and joint pain, bone deformity, numbness and weakness of limbs, and skin itching, which seriously affects the quality of life of patients (1). The risk of cardiovascular events, renal osteodystrophy, pathological fractures, and death are significantly increased in patients. About 50% of chronic kidney disease (CKD) patients die of cardiovascular and cerebrovascular complications caused by excessive bone resorption and ectopic calcification of blood vessels (3,4).

Some international multicenter studies reported that patients with Saglikler syndrome have missense mutations in exons 1, 4, and 10 of the *GNAS1* gene, but patients with CKD often have disorders of calcium and phosphorus metabolism, resulting in parathyroid hyperplasia and secondary parathyroid gland hyperfunction (5-7). The etiology of secondary hyperparathyroidism is complex. There are not only genetic factors, but also many other stimulating factors, such as low calcium, high phosphorus, and insufficient calcitriol (8). For patients with Saglikler syndrome, there is currently no effective treatment. Zhang *et al.* reported that after total parathyroidectomy in 10 patients with Saglikler syndrome, serum parathyroid hormone was significantly decreased, the development of skeletal deformities ceased, and the malnutrition status was improved (9).

SHPT can lead to abnormal functions of various organs, such as ectopic calcification of blood vessels and tissues

and pathological fractures, which increase the disability rate and the incidence of cardiovascular events (10). In severe cases, surgery is required. Treatment for Saglikler syndrome includes lowering serum phosphorus (including a low-phosphorus diet, use of phosphorus binders, and adequate dialysis), rational use of vitamin D and calcium, and parathyroid surgery (11). At present, the main surgical methods for secondary hyperparathyroidism include subtotal parathyroidectomy (SPTX), total parathyroidectomy (TPTX), and total parathyroidectomy plus autotransplantation (TPTX + AT). SPTX, which removes 3 hemi-glands, has the advantages of mild postoperative hypoparathyroidism and low incidence of hypocalcemia, but the residual parathyroid after continuous stimulation may re-proliferate and cause hyperplasia. Surgical treatment is required, and the difficulty of re-operation on the neck increases. The recurrent laryngeal nerve or superior laryngeal nerve is more likely to be injured, causing hoarseness, coughing when drinking water (12,13). TPTX removes all parathyroid glands without autotransplantation, and has a low recurrence rate. Relevant literature has reported that the recurrence rate after TPTX is lower than that of SPTX or TPTX + AT, but the incidence of postoperative hypoparathyroidism is higher (14). After surgical treatment of SHPT patients, due to factors such as increased bone resorption, hypocalcemia often occurs. A previous study found that there are significant differences in the occurrence of postoperative hypocalcemia, and most patients showed transient hypocalcemia, which improved after intravenous or oral calcium supplementation (15).



SHPT in patients with Sagliker syndrome is mostly caused by hyperparathyroidism. Parathyroidectomy prevents the progression of Sagliker syndrome, but does not reverse the skeletal deformity (16,17). As the survival time of hemodialysis patients is increasing, there will be more and more Sagliker syndrome patients. As the faces of patients become abnormal, they may experience greater mental and psychological pressure, which should arouse the attention of doctors. The diagnosis of this case was relatively late, and the best opportunity for surgery was missed. Early monitoring and standardized treatment of secondary hyperparathyroidism may prevent the occurrence of Sagliker syndrome. Early identification and diagnosis of Sagliker syndrome and the choice of appropriate treatment will have an important impact for the prognosis.

### Acknowledgments

*Funding:* None.

### Footnote

*Reporting Checklist:* The authors have completed the CARE reporting checklist. Available at <https://gs.amegroups.com/article/view/10.21037/gc-22-479/rc>

*Conflicts of Interest:* Both authors have completed the ICMJE uniform disclosure form (available at <https://gs.amegroups.com/article/view/10.21037/gc-22-479/coif>). Both authors have completed the ICMJE uniform disclosure form.

*Ethical Statement:* The authors are accountable for all aspects of the work in ensuring that questions related to the accuracy or integrity of any part of the work are appropriately investigated and resolved. All procedures performed in this study were in accordance with the ethical standards of the institutional and/or national research committee(s) and with the Helsinki Declaration (as revised in 2013). Written informed consent was obtained from the patient for publication of this case report and accompanying images. A copy of the written consent is available for review by the editorial office of this journal.

*Open Access Statement:* This is an Open Access article distributed in accordance with the Creative Commons Attribution-NonCommercial-NoDerivs 4.0 International License (CC BY-NC-ND 4.0), which permits the non-commercial replication and distribution of the article with

the strict proviso that no changes or edits are made and the original work is properly cited (including links to both the formal publication through the relevant DOI and the license). See: <https://creativecommons.org/licenses/by-nc-nd/4.0/>.

### References

1. Sagliker Y, Balal M, Sagliker Ozkaynak P, et al. Sagliker syndrome: uglifying human face appearance in late and severe secondary hyperparathyroidism in chronic renal failure. *Semin Nephrol* 2004;24:449-55.
2. Sagliker Y, Acharya V, Ling Z, et al. International Study on Sagliker Syndrome and Uglifying Human Face Appearance in Severe and Late Secondary Hyperparathyroidism in Chronic Kidney Disease Patients. *Journal of Renal Nutrition* 2008;18:114-7.
3. Li X, Zhuang D, Zhou P. Comparative analysis of surgical treatment and sinacasai internal medicine treatment for triple hyperparathyroidism. *International Journal of Surgery* 2018;45:845-9.
4. Xu Y, Evans M, Soro M, et al. Secondary hyperparathyroidism and adverse health outcomes in adults with chronic kidney disease. *Clin Kidney J* 2021;14:2213-20.
5. Yildiz I, Sagliker Y, Demirhan O, et al. International evaluation of unrecognizably uglifying human faces in late and severe secondary hyperparathyroidism in chronic kidney disease. Sagliker syndrome. A unique catastrophic entity, cytogenetic studies for chromosomal abnormalities, calcium-sensing receptor gene and GNAS1 mutations. Striking and promising missense mutations on the GNAS1 gene exons 1, 4, 10, 4. *J Ren Nutr* 2012;22:157-61.
6. Wang TY, George J, Zheng MH. Metabolic (dysfunction) associated fatty liver disease: more evidence and a bright future. *Hepatobiliary Surg Nutr* 2021;10:849-52.
7. Hu PF, Zeng X, Zou ZY, et al. The presence of NAFLD in nonobese subjects increased the risk of metabolic abnormalities than obese subjects without NAFLD: a population-based cross-sectional study. *Hepatobiliary Surg Nutr* 2021;10:811-24.
8. Mi JP, He P, Shi K, et al. Cephalometric craniofacial features of patients with Sagliker syndrome: a primary analysis of our experience. *Ann Transl Med* 2021;9:963.
9. Zhang L, Yao L, Hua Z. Total parathyroidectomy in treatment of Sagliker syndrome in 10 cases of hemodialysing patients with secondary hyperparathyroidism. *Zhonghua Nei Ke Za Zhi* 2011;50:562-7.

10. Uzel A, Uzel I, Sagliker Y, et al. Cephalometric evaluation of patients with Sagliker syndrome: uglifying human face appearance in severe and late secondary hyperparathyroidism in chronic renal failure patients. *J Ren Nutr* 2006;16:229-32.
11. Cozzolino M, Bernard L, Csomor PA. Active vitamin D increases the risk of hypercalcaemia in non-dialysis chronic kidney disease patients with secondary hyperparathyroidism: a systematic review and meta-analysis. *Clin Kidney J* 2021;14:2437-43.
12. Wang D, Li L, Zhang C, et al. A new anesthesia scheme for parathyroidectomy under neuromonitoring: a retrospective cohort study. *Gland Surg* 2021;10:1576-86.
13. Saito Y, Ikeda Y, Katoh H, et al. Is total endoscopic parathyroidectomy an acceptable treatment for patients with primary hyperparathyroidism due to a presumed solitary adenoma?—comparison of minimally invasive total endoscopic parathyroidectomy and open minimally invasive parathyroidectomy. *Gland Surg* 2021;10:83-9.
14. Shih ML, Duh QY, Hsieh CB, et al. Total parathyroidectomy without autotransplantation for secondary hyperparathyroidism. *World J Surg* 2009;33:248-54.
15. Schlosser K, Veit JA, Witte S, et al. Comparison of total parathyroidectomy without autotransplantation and without thymectomy versus total parathyroidectomy with autotransplantation and with thymectomy for secondary hyperparathyroidism: TOPAR PILOT-Trial. *Trials* 2007;8:22.
16. Giray S, Sagliker Y, Yildiz I, et al. Neurologic manifestations in Sagliker syndrome: uglifying human face appearance in severe and late secondary hyperparathyroidism in chronic renal failure patients. *J Ren Nutr* 2006;16:233-6.
17. Pontes FSC, Lopes MA, de Souza LL, et al. Oral and maxillofacial manifestations of chronic kidney disease-mineral and bone disorder: a multicenter retrospective study. *Oral Surg Oral Med Oral Pathol Oral Radiol* 2018;125:31-43.

(English Language Editor: C. Betlazar-Maseh)

**Cite this article as:** Pang Y, Meng X. Surgical treatment of secondary hyperparathyroidism combined with Sagliker syndrome caused by chronic renal failure: a case report. *Gland Surg* 2022;11(9):1568-1573. doi: 10.21037/gS-22-479