

Treatment of Autoimmune Disease with Extracorporeal Photochemotherapy: Progressive Systemic Sclerosis

ALAIN H. ROOK, M.D., BRUCE FREUNDLICH, M.D.,
GEORGE T. NAHASS, M.D., RITA WASHKO, M.D.,
BARBARA MACELIS, R.N., MICHELE SKOLNICKI, R.N.,
PATRICIA BROMLEY, R.N., WILLIAM K. WITMER, B.S.,
AND BRIAN V. JEGASOTHY, M.D.

General Clinical Research Center, University of Pennsylvania, and Departments of Dermatology and Rheumatology, Hospital of the University of Pennsylvania, Philadelphia, Pennsylvania

Received July 20, 1989

In this report, we describe the use of extracorporeal photochemotherapy in the treatment of two patients with rapidly advancing progressive systemic sclerosis. Both patients experienced improvement in the cutaneous as well as the systemic manifestations of their disease while undergoing therapy. The potential therapeutic mechanisms are discussed.

The ability to ameliorate or prevent autoimmune disease by the *in vivo* administration of lethally damaged syngeneic pathogenic T-cell clones is well established in animal models [1]. In this regard, recent observations by Khavari and colleagues [2] have demonstrated that one of the most effective means of prophylaxis against the development of murine experimental allergic encephalitis has been to inoculate animals with myelin basic protein-specific T-cell clones that have initially been photoinactivated with 8-methoxypsoralen (8-MOP) and ultraviolet A radiation. With the introduction of extracorporeal photochemotherapy into the clinic for the treatment of cutaneous T-cell lymphoma (CTCL) [3], this basic therapeutic strategy, which undertakes the extracorporeal photoinactivation of peripheral blood leukocytes using 8-MOP and ultraviolet A, followed by their reinfusion, is now available for the treatment of human autoimmune diseases. In light of this fact, it is noteworthy that a number of patients, who exhibited concomitant manifestations of both CTCL and autoimmune disease and were treated with extracorporeal photochemotherapy at our center, experienced marked improvement in their autoimmune phenomenon during the treatment. These clinical observations resulted in the genesis of several pilot studies to assess the efficacy of extracorporeal photochemotherapy in the treatment of aggressive autoimmune disease. One protocol has included the treatment of corticosteroid and immunosuppressive drug-resistant pemphigus vulgaris in an effort to determine if extracorporeal photochemotherapy could produce clinical improvement, which was not previously possible with potent immune-suppressing medications. (Refer to the article by Rook and colleagues which follows this.) A second pilot study was initiated to

Abbreviations: CTCL: cutaneous T-cell lymphoma 8-MOP: 8-methoxypsoralen

This work was partially supported by grant M01 RR00040-29 from the National Institutes of Health.

Address reprint requests to: Alain H. Rook, M.D., Dept. of Dermatology, Hospital of the University of Pennsylvania, 3400 Spruce Street, Philadelphia, PA 19104

Copyright © 1989 by The Yale Journal of Biology and Medicine, Inc.
All rights of reproduction in any form reserved.

examine the effects of extracorporeal photochemotherapy on the evolution of progressive systemic sclerosis. In this report, we describe the beneficial effect of extracorporeal photochemotherapy on the cutaneous as well as the systemic manifestations of scleroderma in the two patients participating in this initial study. These results have formed the basis for the initiation of a larger multi-center clinical trial.

TREATMENT PROCEDURE

The treatment of the patients was accomplished using the UVAR photopheresis system (Therakos, West Chester, PA) in a manner similar to that which has been previously described for cutaneous T-cell lymphoma [3]. Briefly, two hours following the ingestion of 0.6 mg of 8-MOP per kilogram of body weight, patients underwent a discontinuous leukapheresis procedure with subsequent exposure of removed leukocytes to ultraviolet A radiation. During the procedure, approximately 240 ml of leukocyte-enriched blood was mixed with 300 ml of the patients' plasma, and 200 ml of sterile normal saline. The final buffy coat preparation contained an estimated 25–50 percent of the total peripheral blood leukocyte compartment and had a hematocrit ranging from 2.5 to 8 percent. The buffy coat then passed as a 1 mm film through a sterile cassette, permitting a 270-minute exposure to ultraviolet A, yielding an average exposure per lymphocyte of 2 J/cm². Following exposure of the cells to ultraviolet A, the buffy coat was returned to the patient. During the initial phases of therapy, the patients received the treatment on each of two successive days at four-week intervals. If, after three treatments, improvement was not observed, therapy was increased to two treatments on successive days at two-week intervals.

PATIENT SELECTION AND EVALUATION

The two patients selected for treatment had the diagnosis of progressive systemic sclerosis made by a combination of clinical and histological criteria, which included the evaluation of a skin biopsy. Both patients were chosen for this pilot study as a result of their unusually rapid progression of skin thickening to involve a majority of their cutaneous surface area. Clinical evaluations of skin thickening before and during therapy were performed independently by at least two examining physicians.

CASE HISTORY

Patient 1

This patient was a 60-year-old male who was in excellent health until April 1986, when he developed Raynaud's phenomenon and arthralgias. In September 1986, he noted the development of skin swelling and tightness on his upper extremities and trunk and a diagnosis of progressive systemic sclerosis was made. Nifedipine 10 mg three times daily was started. By November 1986, the skin tightening had progressed rapidly to involve all areas except the distal lower extremities. Finger mobility was markedly decreased; 250 mg D-penicillamine daily was added. In March 1987, the patient was referred for potential treatment with extracorporeal photochemotherapy. At that time, marked skin tightening and sclerosis of hands, forearms, abdomen, chest, and legs was observed (Fig. 1A, dated March 25, 1987). Decreased finger mobility and grip were evident at this time. All fingertips exhibited necrotic ulcerations. Pulmonary function testing revealed a carbon monoxide diffusing capacity which was 68 percent of the expected normal. An upper gastrointestinal series demonstrated esophageal

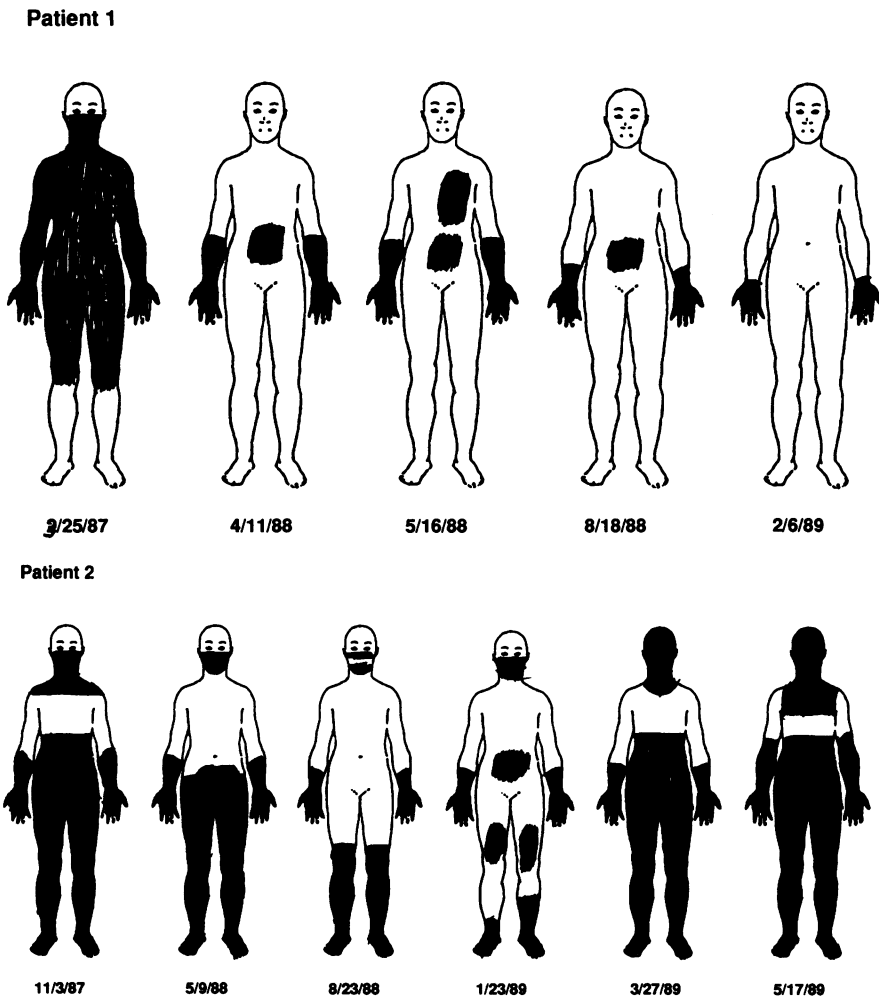


FIG. 1. A. Progress of skin thickening in patient 1 during treatment with extracorporeal photochemotherapy. Areas in black indicate skin thickening on physical examination. B. The course of skin thickening in patient 2 during extracorporeal photochemotherapy treatment.

hypomotility. A urine analysis revealed 3+ protein, and a 24-hour urine collection contained 1,300 mg of protein. Red cell fragments were present on the peripheral blood smear, indicative of microangiopathic hemolytic anemia. Blood urea nitrogen and serum creatinine were normal. On March 27, 1987, the patient was started on extracorporeal photochemotherapy. After one month, the patient felt symptomatically improved. At the third cycle, red cell fragments were no longer detectable on the peripheral blood smear, and repeat urinalysis revealed the absence of urinary protein. The D-penicillamine was discontinued in August 1987. By the ninth cycle of therapy (December 1987), the Raynaud's phenomenon was no longer present and all digital ulcers had healed, permitting discontinuation of nifedipine. By April 11, 1988, aside from a minor degree of skin thickening on the forearms, hands, and mid-abdomen, the skin examination had returned to normal. At this time, repeat pulmonary function

testing revealed a carbon monoxide-diffusing capacity that had improved to 96 percent of the expected normal value. A 24-hour urine collection demonstrated less than 300 mg of protein. The patient elected to decrease the frequency of treatments from every four weeks to every six weeks. On May 16, 1988, he was noted to have new skin thickening on a large area of the left anterior chest (Fig. 1A). Treatments were reinstated on an every-four-week basis. Except for mild sclerodactylia, all skin thickening has resolved, and, at present (June 1989), there are no other demonstrable subjective or objective clinical criteria consistent with the original diagnosis of progressive systemic sclerosis.

Patient 2

This patient was a 42-year-old female who was well until late 1985 when she noted the onset of Raynaud's phenomenon. In early 1987, skin thickening on the hands and distal legs was first noted. D-penicillamine 250 mg daily was begun. Cutaneous thickening progressed rapidly to involve arms, face, trunk, and legs (Fig. 1B). D-penicillamine was increased to 750 mg daily by July 1987. At this time, the patient noted decreased salivation, dry eyes, marked weakness of her arms and legs, decreased sweating, hair loss, and loss of weight. The patient was started on extracorporeal photochemotherapy on November 30, 1987. A creatine phosphokinase obtained at that time was 570 (upper limit of normal, 150). By January 1988, numerous flaccid vesicles erupted on the extremities, and prednisone 40 mg daily was added and the D-penicillamine was discontinued. The vesiculation responded promptly, and the prednisone was tapered and discontinued over a 16-week period. At the fourth cycle of therapy (March 10, 1988), no improvement in the skin thickening was noted, and the treatment frequency was increased to every two weeks for two cycles and then to every three weeks. By May 9, 1988 (Fig. 1B), significant skin softening was observed on the upper chest and mid-abdomen. Continuous improvement occurred during the next several months. A repeat creatine phosphokinase in July of 1988 was less than 20 units, which correlated with improved strength. The patient indicated that her hypohidrosis and xerostomia had improved and that she felt an overall improvement in her sense of well-being. During the winter of 1988, she indicated that her Raynaud's phenomenon had improved. During early 1989, the skin on her abdomen and upper arms slowly recommenced to thicken. In March 1989, despite encouragement to return to an every-two-week course of therapy, she elected to discontinue extracorporeal photochemotherapy. Since March of 1989, her general condition as well as her skin thickening has continued to deteriorate.

DISCUSSION

The results of this pilot study demonstrated the improved clinical course of two patients with progressive systemic sclerosis while undergoing extracorporeal photochemotherapy (Table 1). One of the patients is currently experiencing a sustained complete remission while remaining on an every-four-week regimen. The clinical improvement in our patients was not restricted to the cutaneous manifestations of their disease, as patient 1 had complete normalization of his pulmonary and renal abnormalities and disappearance of the microangiopathic hemolysis as well as the Raynaud's phenomenon. Patient 2, although concomitantly on a short course of low-dose prednisone, as well as D-penicillamine, experienced improvement in her myopathy, her Sjogren's-like symptoms, and her Raynaud's phenomenon. It is noteworthy that our

TABLE 1
Clinical Manifestations of Progressive Systemic Sclerosis Before and During
Treatment with Extracorporeal Photochemotherapy

Patient	Clinical Signs	
	Before Treatment	During Treatment
1	Skin thickening	Resolved
	Proteinurea	Resolved
	Microangiopathic hemolysis	Resolved
	Raynaud's phenomenon	Resolved
	Decreased D _L CO	Normalized
2	Skin thickening	Improved
	Myositis	Resolved
	Xerostomia	Resolved
	Raynaud's phenomenon	Improved
	Hypohydrosis	Resolved

beneficial results were obtained with virtually no side effects attributable to extracorporeal photochemotherapy. Throughout the course of treatment, the only adverse event related to therapy was a single occurrence of mild hypotension in patient 2. Moreover, we failed to document clinical evidence of immune suppression. Most important, during the past five years at our institution, we have not observed any long-lasting harmful effects of extracorporeal photochemotherapy in any of our treatment populations.

The beneficial effects of extracorporeal photochemotherapy on the course of our two patients with progressive systemic sclerosis complement our clinical observations regarding the effects of this treatment on other autoimmune diseases. We have previously described the marked improvement of patients with immunosuppressive drug-resistant pemphigus vulgaris (see the article by Rook et al. in this issue). Currently three of four patients with pemphigus vulgaris have experienced long-lasting remissions induced by extracorporeal photochemotherapy and are currently off therapy. We have also observed improvement in all aspects of disease expression in a patient with collagen vascular disease overlap syndrome with features of systemic lupus erythematosus, Sjogren's syndrome, and polymyositis. Finally, a patient with an IgG-associated autoimmune hemolytic anemia, which occurred concomitantly with CTCL, experienced a significant steroid-sparing effect when extracorporeal photochemotherapy was initiated for the treatment of the lymphoma. Thus, it appears that extracorporeal photochemotherapy may provide promise for the future treatment of autoimmune diseases.

At present, the use of extracorporeal photochemotherapy is in its infancy as a therapeutic tool for autoimmune disease. Therefore, the optimal regimens for each treatment-responsive disease will be determined as experience with current and future clinical trials broadens. In this regard, our observations with pemphigus vulgaris and progressive systemic sclerosis indicate that treatment cycles administered on an every-two-week basis may be superior to monthly treatments for individuals with rapidly progressive disease. Similarly, while therapeutic responses may be obtained in many cases with monthly treatments, more frequent regimens need to be considered for those who fail to respond at this frequency of treatment.

Another issue that is relevant to the maximization of the benefit of extracorporeal photochemotherapy relates to the concomitant use of other pharmacological agents that may have activity against the "targeted" autoimmune disease. As an example, although patient 2, with progressive systemic sclerosis, improved clinically while on twice-monthly extracorporeal photochemotherapy, her D-penicillamine administration overlapped with this therapy, and she was also started on a modest dose of prednisone just preceding her improvement. Thus, in her case, D-penicillamine and prednisone used together with extracorporeal photochemotherapy may have played a prominent role in her partial recovery. Aside from prednisone and D-penicillamine, other agents which directly inhibit collagen synthesis [4], such as gamma interferon, may ultimately be demonstrated to enhance the benefit of extracorporeal photochemotherapy in the treatment of progressive systemic sclerosis.

The precise therapeutic mechanisms underlying the effect of extracorporeal photochemotherapy on autoimmune disease have not been clearly delineated. Data derived from clinical observations as well as animal models support several potential modes of action. Khavari et al. [2] and Perez and colleagues [5], employing murine models of experimental allergic encephalitis and cutaneous allograft rejection, respectively, have each developed evidence that a clonotypic immune response occurs when specific pathogenic T cells are first treated *in vitro* with 8-MOP and ultraviolet A radiation, and then reinfused into syngeneic animals. One of the characteristics of this immune response is the generation of a clone-specific suppressor T-cell response [2,5], which inhibits the proliferation of the pathogenic T cell. Similarly, patients with autoimmune disease who have experienced clinical improvement while receiving extracorporeal photochemotherapy sustain an increase in the number of peripheral blood lymphocytes which phenotypically express features of suppressor T cells [Rook AH, et al: unpublished results]. Evidence from studies of CTCL patients further supports the importance of the suppressor-cytotoxic population of T cells in the clinical response to extracorporeal photochemotherapy. In this respect, we have demonstrated a striking relationship between the absolute numbers of circulating CD8+ T cells and the ultimate ability to develop substantial disease regression while receiving extracorporeal photochemotherapy [Rook AH, Nahass GT: unpublished results]. Thus, in the case of progressive systemic sclerosis, which is characterized by an increase in the numbers of activated helper T cells at sites of heightened collagen production [6,7] a CD8+ suppressor T-cell response may be generated which "dampens" the activity of the "autoreactive" helper T lymphocytes.

Extracorporeal photochemotherapy has been established as an effective form of treatment for CTCL. In addition, the initial success of extracorporeal photochemotherapy in the treatment of a small number of individuals with pemphigus vulgaris and progressive systemic sclerosis has led to the development of carefully planned clinical trials for a variety of autoimmune diseases. These studies will permit a further analysis of the potential promise of this novel form of immunotherapy.

ACKNOWLEDGEMENT

The authors are grateful for the editorial expertise of Laura Bretone.

REFERENCES

1. Cohen IR: Regulation of autoimmune disease: Physiological and therapeutic. *Immunol Rev* 94:5, 1986
2. Khavari PA, Edelson RL, Lider O, Gasparro FP, Weiner HL, Cohen IR: Specific vaccination against photoinactivated cloned T cells. *Clinical Research* 36:662, 1988

3. Edelson R, Berger C, Gasparro F, Jegasothy B, Heald P, Wintroub B, Vonderheid E, Knobler R, Wolff K, Plewig G, McKiernan G, Christiansen I, Oster M, Honigsmann H, Wilford H, Kokoschka E, Rehle T, Perez M, Stingl G, LaRoche L: Treatment of cutaneous T cell lymphoma by extracorporeal photochemotherapy: Preliminary results. *N Engl J Med* 316:297-303, 1987
4. Rosenbloom J, Feldman G, Freundlich B, Jimenez SA: Inhibition of excessive scleroderma fibroblast collagen production by recombinant gamma-interferon. *Arthritis Rheum* 29:851-856, 1986
5. Perez M, Edelson R, LaRoche L, Berger C: Inhibition of antiskin allograft immunity by infusions with syngeneic photoinactivated effector lymphocytes. *J Invest Dermatol* 92:669-676, 1989
6. Roumm AD, Whiteside TL, Medsger TA Jr, Rodnan GP: Lymphocytes in the skin of patients with progressive systemic sclerosis. *Arthritis Rheum* 27:645-653, 1984
7. Freundlich B, Jimenez SA: Phenotype of peripheral blood lymphocytes in patients with progressive systemic sclerosis: Activated T lymphocytes and the effect of penicillamine therapy. *Clin Exp Immunol* 9:375-384, 1987