

Severe Cytomegalovirus Gastritis During Natalizumab-Mediated Immunosuppression

Stephen P. Persaud, MD, PhD¹, Adil Hassan², Anjum Hassan, MD³, and Tariq Hassan, MD⁴

¹Department of Pathology and Immunology, Division of Laboratory and Genomic Medicine, Washington University School of Medicine, St. Louis, MO

²Combined BA/MD Program, University of Missouri-Kansas City School of Medicine, Kansas City, MO

³Department of Pathology and Immunology, Division of Anatomic and Molecular Pathology, Washington University School of Medicine, St. Louis, MO

⁴Endoscopy and Colonoscopy Center, Hazelwood, MO

ABSTRACT

We report a 35-year-old female receiving natalizumab as monotherapy for multiple sclerosis who subsequently developed severe cytomegalovirus gastritis. As cytomegalovirus gastritis has not been previously described during natalizumab treatment, we discuss the biological plausibility of this potential association and avenues for further study.

INTRODUCTION

Gastrointestinal (GI) infection by cytomegalovirus (CMV) primarily afflicts patients who are immunosuppressed, occurring in association with transplantation, malignancy, human immunodeficiency virus (HIV) infection, and chronic steroid usage.^{1,2} T cell-mediated immunity is essential in restraining CMV replication and reactivation; thus, abnormalities of lymphocyte number, function, or tissue distribution may impact patient susceptibility to infection.³ Treatment with natalizumab, which binds α 4-integrins, promotes such an immunocompromised state by blocking adhesion interactions required for lymphocyte trafficking, thus perturbing normal immunosurveillance. While numerous studies have discussed natalizumab-associated infections of the central nervous system, fewer studies have addressed infectious sequelae at other anatomic sites.

CASE REPORT

A 35-year-old woman presented in September 2015 with two weeks of nausea, vomiting, and epigastric pain, with no fevers, chills, or GI bleeding. Her past medical history was notable for multiple sclerosis (MS) diagnosed in 2012, no prior history of GI disease, and no history of recurrent or opportunistic infections that would suggest immunodeficiency. Her medications included ergocalciferol, dosed at 50,000 units per week since October 2013, and natalizumab, dosed at 300 mg every 4 weeks since February 2015; she denied use of alcohol and nonsteroidal anti-inflammatory drugs. The patient's only prior MS therapy was a 6-month trial of dimethyl fumarate started December 2013, with no prior treatment with steroids.

On physical examination, the patient was in no apparent distress and exhibited normal vital signs. Abdominal exam showed a non-tender, non-distended abdomen with normal bowel sounds and no palpable masses. Complete blood count showed a white blood cell count of 4,900/ μ L (absolute neutrophil and lymphocyte counts were 1,700/ μ L and 2,710/ μ L, respectively), hemoglobin 10.5 g/dL, and platelet count 168,000/ μ L. Basic chemistry, hepatic function, lipase, and coagulation testing were normal. The patient was HIV-negative, and periodic John

ACG Case Rep J 2017;4:e43. doi:10.14309/crj.2017.43. Published online: March 15, 2017.

Correspondence: Stephen P. Persaud, Department of Pathology and Immunology, Washington University School of Medicine, 660 S Euclid Ave, Box 8118, St. Louis, MO 63110 (persaud@wustl.edu).



Copyright: © 2017 Persaud et al. This work is licensed under a Creative Commons Attribution-NonCommercial-NoDerivatives 4.0 International License. To view a copy of this license, visit <http://creativecommons.org/licenses/by-nc-nd/4.0>.

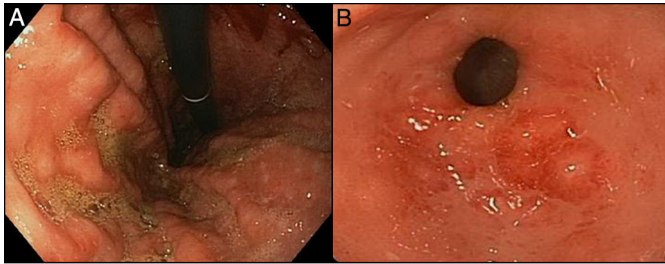


Figure 1. Upper GI endoscopy demonstrating severe inflammation of the (A) body and (B) antrum of the stomach, with significant erythema, erosions, and friability of the involved mucosa.

Cunningham (JC) virus serology testing since starting natalizumab was negative. Immunoglobulin and cortisol levels, as well as counts of CD4⁺ and CD8⁺ T lymphocytes, were not assessed. Barium upper GI fluoroscopy demonstrated no esophageal dilatation or stricture, hiatal hernia, reflux, or ulceration of the esophagus or duodenum. Helical computed tomography scans of abdomen and pelvis with intravenous contrast were unremarkable.

Upper GI endoscopy revealed severe inflammation of the entire examined stomach, with mucosal erosions and erythema and without ulceration or mass lesions (Figure 1). Cold forceps biopsies of the gastric antral mucosa were obtained for histopathologic analysis. Microscopic examination of hematoxylin and eosin-stained tissue showed a chronic inflammatory infiltrate and nuclear enlargement of the glandular epithelial cells consistent with reactive changes (Figure 2). Occasional epithelial cell nuclei showed prominent nucleoli and possible intranuclear inclusions. Immunostaining for CMV was positive, while it was negative for herpes simplex virus

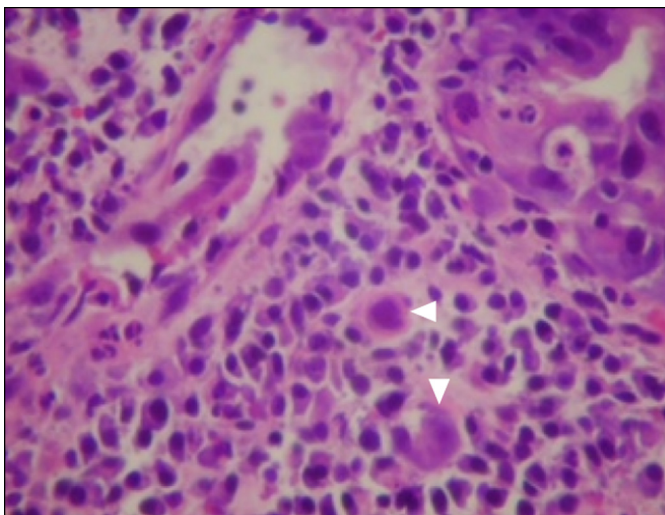


Figure 2. Hematoxylin and eosin staining of gastric antrum tissue demonstrating severe chronic mucosal inflammation and occasional enlarged cells with prominent intracellular inclusions (arrowheads).

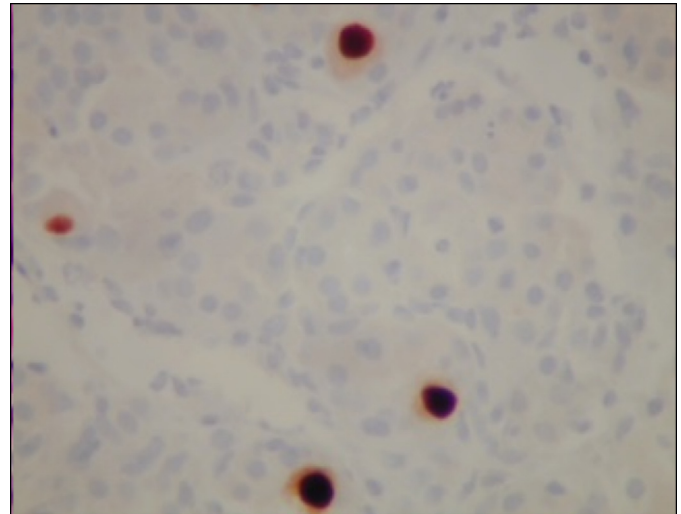


Figure 3. Immunohistochemical staining for CMV shows strong nuclear reactivity among the enlarged cells.

and *Helicobacter pylori* (Figure 3). Rapid urease testing of the biopsy tissue was negative. On the basis of these findings, a final diagnosis of severe chronic active CMV gastritis was rendered.

The patient completed a 3-week course of valganciclovir, dosed at 900 mg twice per day. She reported complete resolution of her symptoms on follow-up with her infectious disease physician 1 week after finishing treatment. Due to her clinical improvement, the patient declined repeat endoscopy. Natalizumab was continued as her MS symptoms were well-controlled; she has continued follow-up with her neurologist approximately every 3 months and has denied recurrence of her GI symptoms.

DISCUSSION

CMV has a broad cellular tropism and can cause disease in nearly any organ; within the GI tract, the colon and stomach are the most commonly affected sites.^{1,4} Definitive diagnosis of CMV gastritis relies on endoscopy and biopsy. Grossly, mucosal erosion and ulceration may be observed, with hemorrhage, obstruction, or perforation seen in more severe cases. Unusual tissue morphologies of CMV gastritis, with polypoid or pseudotumoral appearance on endoscopy, have been described.^{5,6} Microscopically, infected cells may show cytomegaly and intracellular viral inclusions with a surrounding clear zone ("owl's eye" inclusions).^{2,7}

CMV gastritis is a rare condition, with approximately 110 cases described in the literature. Presenting symptoms are generally nonspecific, including nausea, vomiting, and epigastric pain, although several unique presentations have been described, including protein-losing gastropathy with generalized edema, postural epigastric pain, chronic dysmotility, and

gastrocolic fistula formation.⁸⁻¹¹ The majority of reported patients were immunocompromised, although several cases in immunocompetent patients have been described.^{8,12} CMV gastritis is typically self-limited and can be managed supportively in healthy patients, but antiviral treatment was frequently initiated in the reported cases if patients were immunosuppressed or had severe or persistent disease.² Complete recovery was often achieved with resolution of the pathologic endoscopic findings, though notably adult cases of protein-losing gastropathy showed poorer prognosis than their pediatric counterparts.⁸

Natalizumab has primarily been associated with progressive multifocal leukoencephalopathy secondary to JC virus reactivation.¹³ Consequently, clinical and laboratory assessment of patient immune status, including total leukocyte and T-lymphocyte counts, history of opportunistic infection and prior immunosuppressive therapy, and periodic JC virus serologic screening have been recommended for patients taking this medication.^{14,15} Other atypical infections, including herpes simplex and varicella zoster virus encephalitis and meningitis, as well as CMV colitis, have also been described.^{16,17} Notably, CMV colitis has also been reported with the use of vedolizumab, an $\alpha 4\beta 7$ -integrin specific antibody used to treat inflammatory bowel disease.¹⁸

We hypothesize that CMV gastritis and colitis in patients taking natalizumab or vedolizumab share a common pathogenesis, whereby lymphocyte $\alpha 4$ -integrin blockade disrupts normal mucosal immunosurveillance. Consistently, the cell adhesion molecule MAdCAM-1, which binds $\alpha 4\beta 7$ -integrins, is expressed by gut endothelial cells, particularly during inflammation.¹⁹ Human studies and mouse models of *H. pylori* gastritis have demonstrated dense lymphocytic infiltration of MAdCAM-1-positive tissue foci, implicating this receptor in recruiting circulating lymphocytes into the gastric mucosa.^{19,20} More studies, however, are necessary to solidify the connection between CMV gastritis and natalizumab; given the rarity of this condition, accrual of greater numbers of natalizumab-treated patients will likely be necessary. Detailed immunologic workup will be particularly helpful in excluding other causes of immunodeficiency. Finally, animal models of viral GI infection in the setting of integrin blockade may provide important proof-of-principle and pathophysiologic insights to how natalizumab impacts susceptibility to CMV GI infection.

DISCLOSURES

Author contributions: SP Persaud wrote the manuscript and is the article guarantor. T. Hassan provided the images. All authors edited the manuscript and approved the final version.

Financial disclosure: None to report.

Informed consent was obtained for this case report.

Received September 24, 2016; Accepted January 17, 2017

REFERENCES

- Hokama A, Taira K, Yamamoto Y, et al. Cytomegalovirus gastritis. *World J Gastrointest Endosc.* 2010;2:379-80.
- Goodgame RW. Gastrointestinal cytomegalovirus disease. *Ann Intern Med.* 1993;119:924-35.
- Gandhi MK, Khanna R. Human cytomegalovirus: Clinical aspects, immune regulation, and emerging treatments. *Lancet Infect Dis.* 2004;4:725-38.
- Scrivano L, Sinzger C, Nitschko H, Koszinowski UH, Adler B. HCMV spread and cell tropism are determined by distinct virus populations. *PLoS Pathog.* 2011;7:e1001256.
- Laguna F, Garcia-Samaniego J, Alonso MJ, Alvarez I, Gonzalez-Lahoz JM. Pseudotumoral appearance of cytomegalovirus esophagitis and gastritis in AIDS patients. *Am J Gastroenterol.* 1993;88:1108-11.
- Tsujii Y, Nishida T, Takehara T. Polypoid change in cytomegalovirus gastritis following treatment. *Dig Endosc.* 2013;25(3):342.
- Sepulveda AR, Patil M. Practical approach to the pathologic diagnosis of gastritis. *Arch Pathol Lab Med.* 2008;132:1586-93.
- Setakhr V, Muller G, Hoang P, Lambert AS, Geubel A. Cytomegalovirus-associated protein losing gastropathy in an immunocompetent adult: A case report. *Acta Gastroenterol Belg.* 2007;70:296-9.
- Moustafellos P, Hadjianastasiou V, Gray D. Postural epigastric pain as a sign of CMV gastritis: A case report. *Transplant Proc.* 2006;38:1357-8.
- Nowak TV, Goddard M, Batteiger B, Cummings OW. Evolution of acute cytomegalovirus gastritis to chronic gastrointestinal dysmotility in a non-immunocompromised adult. *Gastroenterology.* 1999;116:953-8.
- Aqel NM, Tanner P, Drury A, Francis ND, Henry K. Cytomegalovirus gastritis with perforation and gastrocolic fistula formation. *Histopathology.* 1991;18:165-8.
- Crespo P, Dias N, Marques N, Saraiva da Cunha J. Gastritis as a manifestation of primary CMV infection in an immunocompetent host. *BMJ Case Rep* 2015. 2015;2015:pil:bcr2014206991.
- Warnke C, Olsson T, Hartung HP. PML: The dark side of immunotherapy in multiple sclerosis. *Trends Pharmacol Sci.* 2015;36:799-801.
- Gold R, Jawad A, Miller DH, et al. Expert opinion: Guidelines for the use of natalizumab in multiple sclerosis patients previously treated with immunomodulating therapies. *J Neuroimmunol.* 2007;187:156-8.
- Fernandez O. Best practice in the use of natalizumab in multiple sclerosis. *Ther Adv Neurol Disord.* 2013;6:69-79.
- Center for Drug Evaluation and Research (CDER). *Tysabri (Natalizumab) biologic license application 125104/15: In: Proceedings of the Peripheral and Central Nervous System Drugs Advisory Committee; March 7-8, 2006; Gaithersburg, Maryland.* <http://www.fda.gov/ohrms/dockets/ac/06/slides/2006-4208S1-Slide-Index.htm>. Accessed January 9, 2017.
- Fine AJ, Sorbello A, Kortepeter C, Scarazzini L. Central nervous system herpes simplex and varicella zoster virus infections in natalizumab-treated patients. *Clin Infect Dis.* 2013;57:849-52.
- Vivio EE, Kanuri N, Gilbertsen JJ, et al. Vedolizumab effectiveness and safety over the first year of use in an IBD clinical practice. *J Crohns Colitis.* 2016;10:402-9.
- Hatanaka K, Hokari R, Matsuzaki K, et al. Increased expression of mucosal addressin cell adhesion molecule-1 (MAdCAM-1) and lymphocyte recruitment in murine gastritis induced by *Helicobacter pylori*. *Clin Exp Immunol.* 2002;130:183-9.
- Ohara H, Isomoto H, Wen CY, et al. Expression of mucosal addressin cell adhesion molecule 1 on vascular endothelium of gastric mucosa in patients with nodular gastritis. *World J Gastroenterol.* 2003;9:2701-5.