

Received: 2018.12.17
Accepted: 2019.03.18
Published: 2019.05.30

e-ISSN 1941-5923
© Am J Case Rep, 2019; 20: 764-769
DOI: 10.12659/AJCR.914668

A Case of Rheumatoid Arthritis and Paget Disease of Bone

Authors' Contribution:
Study Design A
Data Collection B
Statistical Analysis C
Data Interpretation D
Manuscript Preparation E
Literature Search F
Funds Collection G

ABCDEF 1,2 **Carolina Borz-Baba**
EF 2 **Yamini Sachan**
AF 1,2 **Benjamin Sapers**
BD 3 **Liviu Georgescu**

1 Yale School of Medicine, New Haven, CT, U.S.A.
2 Department of Internal Medicine, Saint Mary's Hospital, Waterbury, CT, U.S.A.
3 Department of Rheumatology, North Shore University Hospital, Manhasset, NY, U.S.A.

Corresponding Author: Carolina Borz-Baba, e-mail: carolina.borzbaba@stmh.org
Conflict of interest: None declared

Patient: Male, 74
Final Diagnosis: Rheumatoid arthritis (RA)
Symptoms: Joint pain • joint swelling
Medication: —
Clinical Procedure: —
Specialty: Rheumatology





Objective: Rare co-existence of disease or pathology
Background: Paget disease is a primary bone disease with adjacent joint involvement that commonly presents with degenerative arthritis. Rheumatoid arthritis (RA) is mainly an articular disease with symmetric synovitis of the peripheral joints and usually does not involve the lumbar spine. The coexistence of Rheumatoid Arthritis and Paget disease of bone is infrequently reported in the literature.

Case Report: A 74-year-old African-American man was referred for the investigation of symmetrical polyarthritis, left upper arm joint deformity, and low back pain. X-ray imaging of the hands demonstrated bilateral erosions and deformities of the carpal bones, and the left arm showed mixed lytic and sclerotic bone lesions. Laboratory tests showed high levels of rheumatoid factor and alkaline phosphatase. Analysis of the synovial fluid from the left knee was consistent with inflammatory joint disease.

Conclusions: The purpose of this article is to present the diagnostic challenges associated with the rare coexistence of Rheumatoid Arthritis and Paget disease of bone in the same patient. The correct diagnosis of both diseases has important consequences in preventing treatment delay.

MeSH Keywords: Arthritis, Rheumatoid • Diagnosis • Osteitis Deformans

Full-text PDF: <https://www.amjcaserep.com/abstract/index/idArt/914668>

 2689  —  3  29



Background

Paget disease of bone is the second most common disease associated with bone remodeling, after osteoporosis. The prevalence of Paget disease of bone varies from 0.00028% in Japan to 5.4% in the UK [1]. Genetic factors are involved in this condition and familial Paget disease of bone is inherited in an autosomal dominant pattern [2]. The proposed environmental etiological factors for Paget disease include viral infection, particularly measles, animal contact, and pesticides, but evidence for a single cause is limited [3].

Rheumatoid arthritis is the most common type of autoimmune arthritis. Epidemiological data in patients with rheumatoid arthritis support that complex interactions between genetic, hormonal, and environmental factors are involved. Shared epitopes on HLA-DRB1, but also non-HLA genes confer particular susceptibility for the development of rheumatoid arthritis. Infectious causes have been suggested that include Epstein-Barr virus (EBV), cytomegalovirus (CMV), *Escherichia coli* and *Proteus sp.* infection, but heat shock proteins have been linked with the etiology of rheumatoid arthritis [4].

To our knowledge, the association between Paget disease of bone and rheumatoid arthritis was first described in 1971 [5], but rheumatoid arthritis remains a rare association with Paget disease and with other chronic osteoarticular diseases that include osteoarthritis, ankylosis spondylitis, gouty arthritis, pseudogout, and rheumatoid arthritis [6,7]. A case is presented of the co-existence of Paget disease with rheumatoid arthritis that demonstrates the importance of imaging and laboratory findings in identifying the diagnoses.

Case Report

A 74-year-old African-American man, who was a retired nurse, was referred by his primary care physician for an outpatient rheumatology evaluation. The patient complained of pain and swelling of both wrists and hands, which was worse on movement and in the morning and lasted for a few hours. These symptoms had been present for approximately 20 years with recent episodes of worsening bilateral groin pain and left upper arm and elbow pain. The patient reported morning stiffness in both wrists and hands but not in the large joints. For the previous few weeks, he had noticed pain and swelling of his left knee. He also had chronic low back pain, aggravated at night and for an unknown duration. He denied a history of Raynaud's phenomenon, rash, dry eyes, or dry mouth. He had no respiratory complaints or chest pain. The patient also denied headache, numbness, weakness, visual or hearing loss, urinary symptoms, or intestinal symptoms. He had not traveled outside of the New York area, had no previous febrile illness,

diarrhea, or exposure to tick bites. The patients drank alcohol only occasionally and did not smoke. He had not been sexually active for the past year and did not have a history of sexually transmitted diseases, including gonorrhea, chlamydia, or human immunodeficiency virus (HIV). His past medical history was significant for hypertension for which he had been taking enalapril 10 mg daily. The patient denied a previous diagnosis of a rheumatic disorder. He had previously been advised to take over the counter anti-inflammatory medications and analgesics for his joint symptoms.

On examination, his vital signs were stable. He had bilateral wrist deformity and decreased range of motion, more for the left wrist than the right, and deformity of the proximal interphalangeal (PIP) joints. The bilateral carpometacarpal, proximal intercarpal and radiocarpal joints were diffusely swollen and tender to palpation, but there was no erythema. These findings were suggestive of synovitis in the wrists and hands, but no effusions were present in the distal joints of the hands. There was firm bony enlargement of the left elbow, which was slightly tender but without erythema. The left knee was swollen with medial and lateral joint line tenderness and decreased range of motion. An effusion was noted in the suprapatellar region. The lower lumbosacral spine and sacroiliac region were also tender to palpation, and there was bilateral limited internal and external rotation of the hips.

Laboratory tests included hemoglobin (Hb) of 11.2 g/dl (normal range, 12.5–16.0 g/dl) with normal iron levels, and an unremarkable comprehensive metabolic screen. Rheumatoid factor was 995 U/ml (normal, <40 U/mL), the erythrocyte sedimentation rate (ESR) was 95 mm/h (normal range, 0–15 mm/h), cyclic citrullinated peptide antibody (anti-CCP) >250 U (normal, <20 U), and alkaline phosphatase (ALP) 1,264 U/L (normal range, 36–92 U/L). The C-reactive protein (CRP) was not measured as the ESR was significantly elevated. Analysis of the left knee synovial fluid aspirate was consistent with inflammatory arthritis with yellow fluid with a total nucleated cell count (TNCC) of 3,550 cells/mm³ (72% neutrophils), no red blood cells (RBCs) or crystals, and negative growth on bacterial culture.

Radiographic findings of the wrists and hands were typical for rheumatoid arthritis, and showed symmetrical joint space narrowing and irregularities at the radiocarpal and intercarpal joints, with carpal bone erosions and periarticular osteopenia around the joints of the hands. Flexion of the PIP joints and hyperextension of the distal interphalangeal (DIP) joints were both identified on X-ray imaging (Figure 1). There was an area of osteolysis in the right distal radius that was associated with disruption of the cortical bone, which was thought to be due to rheumatoid arthritis, as simple bone cysts usually involve only trabecular bone. There were marked

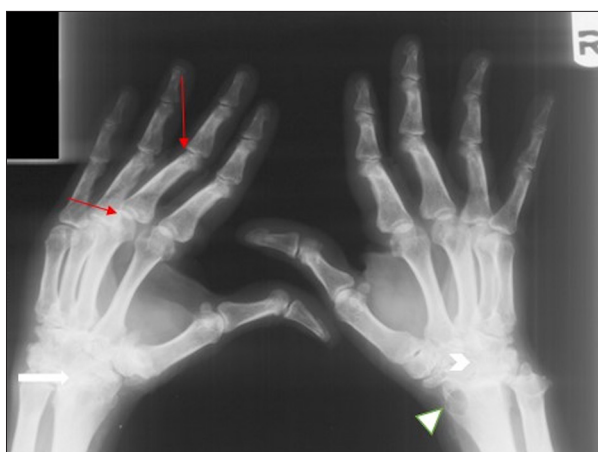

Figure 1. X-radiograph of both hands in a 74-year-old man with Paget disease and rheumatoid arthritis. X-radiograph of both hands shows decreased and irregular joint spaces at the radiocarpal (arrow) and intercarpal joints (arrowhead). Hyperextension of the distal interphalangeal (DIP) joints with flexion of the proximal interphalangeal (PIP) joints (red arrows). Distal radial erosion is present (triangular indicator).

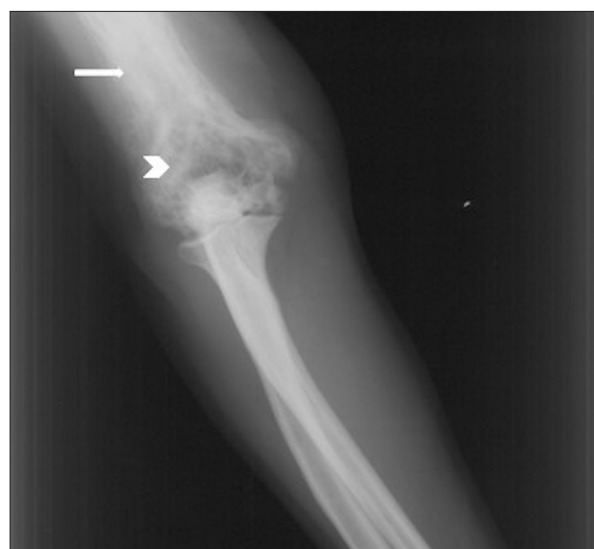

Figure 2. X-radiograph of the elbow joint in a 74-year-old man with Paget disease and rheumatoid arthritis. X-radiograph of the elbow joint shows cortical thickening of the distal diaphysis (arrow). Marked lytic bone lesions of the left elbow and distal humerus are present (arrowhead).

lytic bone lesions of the left elbow and distal humerus, and cortical thickening of the distal diaphysis (Figure 2). These changes, and the findings of sclerosis of the vertebral bodies with a 'picture frame' appearance, were seen on conventional X-ray imaging of the L3–L5 lumbar vertebrae (Figure 3), and are commonly seen in Paget disease of bone. Additional methods used to diagnose Paget disease of bone, including a bone scan and bone biopsy were not considered necessary in the presence of typical biochemical and radiographic findings of Paget disease of bone.

The combined clinical, laboratory, and radiographic findings were consistent with the co-existence of Paget disease of bone and rheumatoid arthritis. Therefore, treatment commenced with a combination of the bisphosphonate, alendronate sodium (30 mg p.o. daily), prednisone, and methotrexate were initiated in our patient. According to the evaluation of disease activity in rheumatoid arthritis in the guidelines endorsed by the American College of Rheumatology (ACR), the patient achieved clinical improvement as demonstrated by reduced pain and swelling of the joints and increased overall mobility, the absence of joint effusions, and reduced fatigue at the follow-up visits. The ALP level decreased from 1,264 U/L to 265 U/L at two months following the start of treatment, to 124 U/L by the seventh month of treatment, and 67 U/L at the tenth month of treatment. Rheumatoid factor decreased to 562 U/ml, the ESR decreased to 67 mm/h after two months of treatment but remained persistently elevated. The patient refused treatment with tumor necrosis factor (TNF) inhibitors, but continued on methotrexate and preferred to have oral

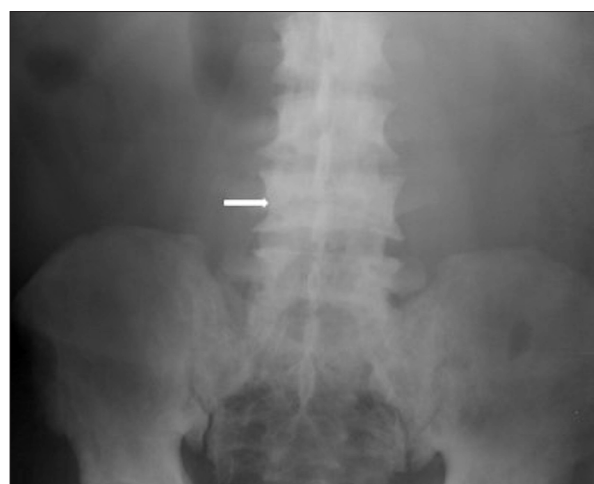

Figure 3. X-radiograph of the lumbar spine in a 74-year-old man with Paget disease and rheumatoid arthritis. X-radiograph of the lumbar spine shows sclerosis of the vertebral bodies with a 'picture frame' appearance (arrow). Diffuse mild sclerosis is present in the pelvic bones.

treatment with prednisone combined with intra-articular glucocorticoid injections for any episodes of increased symptoms. He continued to be followed-up in the rheumatology clinic until the age of 80 years, and his clinical condition remained controlled on the above treatment regimen.

Discussion

Bone lesions in Paget disease develop in three phases. Early changes are predominantly lytic and characterized by excessive osteoclast-mediated bone resorption. The second phase of Paget disease of bone is a mixed osteolytic and osteoblastic process with formation of new bone matrix. The final phase, in which bone formation becomes dominant, is represented by a new bone but with a distorted bone architecture. Abnormal bone expansion occurs in multiple areas throughout the skeleton, commonly in the pelvis, vertebral bodies, skull, femur, and tibia [2]. Bone involvement in Paget disease can be asymptomatic. However, local periosteal involvement and increased intramedullary pressure [8] manifest clinically in 50% of cases as bone pain, that is described as lancinating in nature [9,10]. Bone pain in Paget disease is constant and tends to worsen at night and on weight-bearing [11]. Occasionally, pain in Paget disease of bone is due to cortical microfractures and is self-limiting. The biomechanics of limb deformity leads to secondary gait problems and pressure on joints. Bone lesions adjacent to a joint commonly cause degenerative joint changes that can present clinically as osteoarthritis. The prevalence of osteoarthritis in Paget disease of bone is 91% and is mostly localized in the spine (37%), hip (30%), and knee (11%) [7].

The etiology of pain in rheumatoid arthritis is multifactorial. Cytokine-mediated destruction of joint cartilage, due to synovial hyperplasia, leads directly to biomechanical dysfunction of the joint. Subchondral bone erosions are usually present within the first two years of the disease [12]. An increase in central pain also appears early in the course of the disease and the mechanism contributing to central sensitization is driven by local inflammation and circulating cytokines [13]. Pain on movement of the affected joints improves during the day and is typically preceded by persistent morning stiffness. According to the 2010 American College of Rheumatology (ACR) and European League Against Rheumatism (EULAR) criteria, the duration of this pattern of symptoms is more specific for rheumatoid arthritis when it exceeds six weeks in duration [14]. Rheumatoid arthritis affects the small joints of the hands and feet, including the proximal interphalangeal (PIP) joints, the wrist, and the metatarsophalangeal (MTP) joints, and larger joints of the lower extremity, including the knees and hips, and is frequently associated with joint deformity. Inflammatory changes typically spare the axial skeleton, except the upper cervical spine. The presence of low back pain and tenderness to palpation of the lower lumbosacral spine or sacroiliac region in patients with rheumatoid arthritis requires the exclusion of other potential causes of low back pain, including vertebral fractures, osteoarthritis, ankylosing spondylitis, axial gout, osteomyelitis, bone tumors, or Paget disease.

Differentiation between these diseases is facilitated by imaging and laboratory testing, including synovial fluid aspiration and analysis, when feasible. In rheumatoid arthritis, the radiographic findings depend on the stage of the disease. Fusiform periarticular soft tissue swelling and osteopenia are observed in the initial phases of rheumatoid arthritis [15]. These changes are followed by early widening of the small joints due to the presence of an effusion. In time, cartilage destruction occurs, and the joint space becomes narrow. Associated bone erosions and joint subluxations occur before the final stages of marked fusion and ankylosis [15].

The typical findings in Paget disease of bone are often shown in X-radiographs of the pelvis and include radiolucent and radiodense lesions of the ilium, with a thickened and sclerotic iliopectinal line (Brim sign). The same radiographic changes can be found along the shaft of the long bones [16]. Thickening and softening of the subchondral bone at the ileopectineal lines can allow axial migration of the pelvis, as in rheumatoid arthritis [17]. The radiological features of Paget disease of bone involving the spine include vertebral enlargement with marginal sclerosis with typical 'picture frame pattern' that represents the destruction of the normal bone architecture with increased density of the neural arch, also known as 'ivory vertebrae' [18].

The most useful biochemical marker of activity of Paget disease of bone is the increase in the total alkaline phosphatase (ALP) level, although a normal ALP does not exclude the disorder [19]. Assessment of ALP isoenzymes can be helpful when the tissue of origin of the elevated plasma level of ALP is unclear. The serological markers of rheumatoid arthritis are rheumatoid factor and cyclic citrullinated peptide antibody (anti-CCP). An increased erythrocyte sedimentation rate (ESR) and/or C-reactive protein (CRP) level are included in the 2010 American College of Rheumatology/European League Against Rheumatism (ACR/EULAR) diagnostic criteria for rheumatoid arthritis [14].

Synovial fluid analysis remains a very sensitive and relatively inexpensive method to distinguish between the different causes of acute arthritis. Synovial fluid appearance and testing, particularly the total cell count and differential, Gram's stain and culture, and polarized light microscopy can reliably determine the cause of joint inflammation. The diagnosis of a non-infectious, non crystal-induced arthropathy, as in the patient described in this report, is suggested by the presence of a typical inflammatory gross fluid analysis [20], a white blood cell count of at least 2000 cells/mm³, a negative Gram's stain and culture, and the absence of crystals.

In Paget disease of bone, bisphosphonates are the first-line treatment. Bisphosphonates have an inhibitory effect on osteoclasts, limiting and reversing bone destruction associated

with reduced bone remodeling [21]. Serum measurement of ALP levels is used as a surrogate marker of bone turnover and to evaluate both disease activity and response to therapy [22]. Denosumab, an alternative therapy, prevents bone resorption in Paget disease of bone by inhibiting receptor activator of nuclear factor kappa-B ligand (RANKL), as patients treated with denosumab achieve normalization of biochemical indices but the response may not be sustained [23]. However, denosumab remains an option for patients who are intolerant to bisphosphonate treatment.

The treatment of rheumatoid arthritis includes synthetic and biologic disease-modifying antirheumatic drugs (DMARDs), which should be initiated early in the course of the disease. Currently, disease remission is considered a realistic goal for a significant number of patients with rheumatoid arthritis. Both psychometric testing and biochemical markers are recommended by the ACR to assess disease activity and response to treatment [24]. To measure the activity of rheumatoid arthritis, both ESR and CRP are also endorsed by the ACR [24]. However, in a literature review of 182 studies, ESR was noted to be more sensitive to change in the activity of rheumatoid arthritis than CRP, mainly after 12 weeks and 24 weeks of treatment [25].

To the best of our knowledge, there have been few case reports [5,26] and studies [6,7] that have previously reported the co-existence of rheumatoid arthritis and Paget disease of bone. Archibald reported a case of a 42-year-old man with Paget disease of bone localized at the femur who developed typical signs and symptoms of rheumatoid arthritis in both hand and wrist at the age of 44 years [5]. Arcritidis et al. reported a case of rheumatoid factor-negative 72-year-old woman with acute-on-chronic rheumatoid arthritis of both wrists and with Paget disease of the thoracic vertebra, right innominate bone, and femur [26]. Rath et al. recently described a 65-year-old woman with Paget disease of bone localized at the humerus and femur who had been treated for approximately two years before developing symptoms and signs of rheumatoid arthritis [27]. In a study on musculoskeletal manifestations of Paget disease of bone, Altman reviewed 290 patients with Paget disease of bone [7]. Rheumatoid arthritis was identified in three patients (prevalence of 1%) in whom no active synovitis or

deformities were noted and rheumatoid factor was absent in two patients [7]. Franck et al. published a study of 55 patients with Paget disease of bone [6]. Classic rheumatoid arthritis was found in only one female patient (prevalence of 1.8%) in whom symmetrical polyarthritis was described in the hands, wrist, and knees with Paget disease of bone being limited to the right hemi-pelvis [6]. The small number of case reports are heterogeneous and are unlikely to help to identify a clinical or biochemical pattern for the association.

It has recently been proposed that Paget disease of bone is an osteoimmunological disorder with a cytokine profile similar to other osteoimmunological diseases, including rheumatoid arthritis [28]. If such a common pathological mechanism can underlie these two distinct clinical entities, then it would follow that some patients may be predisposed to develop both conditions. This theory is supported by the use of monoclonal antibodies that inhibit receptor activator of nuclear factor kappa-B ligand (RANKL) in both Paget disease of bone and rheumatoid arthritis [29]. This momentum in research on osteoimmunology represents significant progress towards an improved understanding of the association between bone disorders and the immune system.

Conclusions

A comprehensive differential diagnosis should be considered when evaluating patient with rheumatoid arthritis or Paget disease of bone since these diseases could overlap. Recent studies have begun to identify common cytokine pathways underlying both of these diseases and suggest that, in some patients, both Paget disease and rheumatoid arthritis may co-exist by more than chance alone. Making the correct and timely diagnosis of both diseases and administration of the most appropriate treatment will result in the prevention of further bone destruction and result in reduced pain and improved quality of life for the patient.

Conflict of interest

None.

References:

- Corral-Gudino L, Borao-Cengotita-Bengoa M, Del Pino-Montes J, Ralston S: Epidemiology of Paget's disease of bone: A systematic review and meta-analysis of secular changes. *Bone*, 2013; 55(2): 347–52
- Singer F, Bone HG, Hosking DJ et al: Paget's disease of bone: an Endocrine Society Clinical Practice Guideline. *J Clin Endocrinol Metab*, 2014; 99: 4408–22
- Shaker JL: Paget's disease of bone: A review of epidemiology, pathophysiology and management. *Ther Adv Musculoskelet Dis*, 2009; 1(2): 107–25
- McInnes I, Schett G: The pathogenesis of rheumatoid arthritis. *N Engl J Med*, 2011; 23: 2205–19
- Archibald CG: Observation on Paget's disease of bone: Case report. *N Z Med J*, 1972; 75(479): 205–8
- Franck WA, Bress NM, Singer FR et al: Rheumatic manifestations of Paget's disease of bone. *Am J Med*, 1974; 56: 592–603
- Altman RD: Musculoskeletal manifestations of Paget's disease of bone. *Arthritis Rheum*, 1980; 23(10): 1121–27
- Whyte M: Paget's disease of bone. *N Engl J Med*, 2006; 6: 593–600
- Winfield J: The rheumatology of Paget's disease. *Clin Rheum Dis*, 1966; 12(3): 707–28

10. Tan A, Ralston SH: Clinical presentation of Paget's disease evaluation of a contemporary cohort and systematic review. *Calcif Tissue Int*, 2014; 95: 385–92
11. Tuck SP, Fordham JN: The current management of Paget's disease. *Prescriber*, 2001; 12: 97–102
12. van der Heijde DM: Joint erosions and patients with early rheumatoid arthritis. *Br J Rheumatol*, 1995; 34: 74–78
13. McWilliams DF, Walsh DA: Pain mechanism in rheumatoid arthritis. *Clin Exp Rheumatol*, 2017; 35: S94–101
14. Aletaha D, Neogi T, Silman AJ et al: 2010 Rheumatoid arthritis classification criteria: an American College of Rheumatology/European League Against Rheumatism collaborative initiative. *Arthritis Rheum*, 2010; 62(9): 2569–81
15. Jacobson J, Girish G, Jiang Y, Sabb B: Radiographic evaluation of arthritis: Degenerative joint disease and variation. *Radiology*, 2008; 248: 737–47
16. Favus M, Vokes T: Paget's disease and other dysplasias of bone. *Harrison's Principles of Internal Medicine*, 16th ed. McGraw-Hill, 2005; 2280
17. Altman RD: Arthritis in Paget's disease of bone. *J Bone Miner Res*, 1999; 14: 85S–87S
18. Theodorou DJ, Theodorou SJ, Kakitsubata Y et al: Imaging of Paget's disease of bone and its musculoskeletal complications: Review. *Am J Roentgenol*, 2011; 196(6 Suppl.): S64–75
19. Walsh JP: Paget's disease of bone. *Med J Aust*, 2004; 5: 262–65
20. Abdullah S, Young-Min SA, Hudson SJ, Kelly CA et al: Gross synovial fluid analysis in the differential diagnosis of joint effusion. *J Clin Pathol*, 2007; 60(10): 1144–47
21. Reid IR, Nicholson GC, Weinstein RS et al: Biochemical and radiologic improvement in Paget's disease of bone treated with alendronate: A randomized, placebo-controlled trial. *Am J Med*, 1996; 101: 341–48
22. Reid IR, Miller P, Lyles K et al: Comparison of a single infusion of zoledronic acid with risedronate for Paget's disease. *N Engl J Med*, 2005; 353: 898–908
23. Reid IR, Sharma S, Kalluru R: Treatment of Paget disease of bone with denosumab: case report and literature review. *Calcif Tissue Int*, 2016; 99: 322–25
24. Anderson J, Caplan L, Yazdany J et al: Rheumatoid arthritis disease activity measures: American College of Rheumatology. Recommendations for Use in Clinical Practice. *Arthritis Care Res*, 2012; 64(5): 640–47
25. Ward MM: Relative sensitivity to change of the erythrocyte sedimentation rate and serum C-reactive protein concentration in rheumatoid arthritis. *J Rheumatol*, 2004; 31: 884–95
26. Arcitidis NC, Kaftantzis CN, Katsiotis PA: Coexistence of Paget's Disease of bone and rheumatoid arthritis. *Clin Exp Rheumatol*, 1983; 1(2): 161–63
27. Rath PD, Pandey SC, Bhasin S: Paget's disease with rheumatoid arthritis: By chance not providence. *Rheumatol Adv Pract*, 2018; 2(S1)
28. Numan M, Amiable N, Brown J: Paget's disease of bone: An osteoimmunological disorder? *Drug Des Devel Ther*, 2015; 9: 4695–707
29. Chiu YG, Ritchlin CT: Denosumab: Targeting the RANKL pathway to treat rheumatoid arthritis. *Expert Opin Biol Ther*, 2017; 17(1): 119–28