

TOXOPLASMIC ENCEPHALOMYELITIS

IV. EXPERIMENTAL TRANSMISSION OF THE INFECTION TO ANIMALS FROM A HUMAN INFANT*

BY ABNER WOLF, M.D., DAVID COWEN, M.D., AND BERYL H. PAIGE, M.D.

(From the Neuropathology Department of the College of Physicians and Surgeons, Columbia University, the Neuropathology Department of the Neurological Institute, and the Department of Pathology of the Babies Hospital, New York)

PLATES 12 TO 16

(Received for publication, October 31, 1939)

A new case of granulomatous encephalomyelitis due to a protozoon has afforded an opportunity for transmission of the infection to animals and identification of the causative microorganism as a *Toxoplasma*. The clinical history of the infant and the pathologic findings at autopsy are presented in detail in a recent paper (1).

A white female infant (C. D., Babies Hospital) delivered at full term by Caesarean section, became ill at 3 days of age, and developed convulsive seizures, disturbances in respiration, and symptoms of involvement of the spinal cord with subarachnoid "block" in the cervical region. Terminally, irregular reddish brown areas were observed ophthalmoscopically in each macular region. The infant died at the age of 31 days. Autopsy revealed a widespread encephalomyelitis characterized by multiple focal areas of inflammation and necrosis, and disseminated miliary granulomas. There was localized leptomeningitis in relation to the superficial parenchymal areas of inflammation. Cyst formation occurred in some of the degenerative lesions, while others, especially those in the cerebral cortex, were calcified. The inflammation and degeneration in the spinal cord resulted in marked swelling of the lower cervical segments, sufficient to account for the subarachnoid "block" observed during life. The right eye contained a localized zone of chorioretinitis. Parasites morphologically identical with those found in four previously recorded cases of this disease (2, 3) were present, often in great numbers, in the leptomeningeal and parenchymal exudates, in the granulomas, and in the lesions of the choroid and retina.

It is the purpose of this paper to record the transmission of the human infection to animals and to describe the characteristics of the experimental disease thus produced. A brief report of these investigations has been made in a preliminary note (4).

* Investigation carried out under a grant from the Friedsam Foundation.

Material and Methods

The infective material consisted of fresh tissue taken at autopsy from the infant referred to above 5 hours after death. A small block of cerebral cortex and subcortical white matter from the softened and discolored upper portion of the pre- and postcentral gyri, and a small piece of the swollen cervical portion of the spinal cord, amounting together to about 2 cc. of tissue, were ground in a sterile mortar without the use of an abrasive. Approximately 25 cc. of sterile physiological saline solution were added, and a cloudy emulsion containing some coarse particles prepared. That fraction of the emulsion which could be drawn up into a syringe through a 27 gauge hypodermic needle without preliminary filtration or centrifugation was used for the injection of experimental animals. One group of animals was inoculated directly with freshly prepared emulsion while a second group was inoculated with emulsion which had been preserved overnight (about 11 hours) in the ice box (temperature approximately 7°C.). Preservation of material in this fashion produced no essential difference in the results and, therefore, all the animals in this first passage will be considered as a single group. All injections were by the intracerebral route and in rabbits and rats were preceded by induction of a light ether anesthesia, incision of the scalp, and puncture of the calvarium. In injecting infant mice, the scalp was merely wiped with 70 per cent alcohol and the needle inserted directly into the cerebral hemisphere through scalp and skull without preliminary etherization.

Initial Passage

Four adult rabbits, twenty-six infant white mice (four litters) ranging in age from 2 to 7 days, six 6 weeks old white rats (one litter), and three 2½ months old white rats were injected with the human material.

Each of the rabbits received 0.2 cc. of the emulsion. Three of these died, one in 9 days and two in 13 days, and each showed a meningoencephalitis of varying intensity and focal inflammatory lesions in some of the other organs. The histopathology of these lesions and those in the subsequent passage animals will be described fully in a later section. Parasites, to be described below, were found in the lesions in two, and passage to a group of rabbits and adult and infant mice was successfully carried out by intracerebral inoculation of emulsified brain from each of the three. Successful transmission of the infection was judged by illness or death of the injected animal, by the presence of lesions containing parasites in the central nervous system, and by further successful serial passage. The fourth rabbit remained well for 5 months and was then sacrificed. No lesions or parasites were found in any of the organs. Passage was not attempted from this animal.

The twenty-six infant mice were inoculated intracerebrally with 0.02 to 0.03 cc. of the original emulsion. Of these, eighteen were cannibalized by their mothers during the first few days. Of the remaining eight mice, seven became ill and were sacrificed or died in from 18 to 40 days. All showed a meningoencephalitis and lesions in some of the other organs such as those described later. Five of these showed parasites in the lesions like those seen in the rabbits, and from three of these further successful serial passages were carried out, using brain tissue for intracerebral inoculation. Passage from a sixth mouse in which parasites were not demonstrated histologically was also successful. Thus, six of the seven mice (two each from three of the four litters) dying

within the period stated, showed evidence of having been infected with the human material. The seventh mouse, although it had a marked meningoencephalitis, showed no parasites in its lesions, nor was passage attempted from it. The eighth mouse survived and was well for 4 months when it was sacrificed. A mild meningoencephalitis was present but no parasites were found in the lesions and no passage was carried out.

The six 6 weeks old rats died on the 1st or 2nd day following intracerebral inoculation of 0.05 cc. of the emulsion of human brain and spinal cord. There were no inflammatory lesions in any of the organs except for slight acute reaction in the cerebrum in two due to the punctures. No parasites were found in any of these animals and they probably died as the result of the trauma of inoculation. No passage was attempted. The three 2½ month old rats received 0.06 to 0.08 cc. of the emulsion intracerebrally, and survived for 3 months, at which time they were sacrificed. No inflammatory lesions or parasites were found in any of their organs nor was passage attempted.

The human infection was successfully transmitted to three rabbits and to six infant mice, as evidenced by the fact that (a) all became ill within a reasonable time following inoculation, (b) each showed lesions in the central nervous system resembling those seen in the human case, (c) protozoa like those in the central nervous system of the infant were present in the lesions of seven, (d) sub-transmission of the infection to rabbits and mice from seven of these animals, including two in which parasites were not demonstrated in the lesions, was successful in each instance.

If all of the thirty-nine animals inoculated with the human material are included, approximately one-fourth of the passages were positive. It is obvious, however, that the eighteen cannibalized mice and the six young rats which died of cerebral trauma on the 1st or 2nd day after inoculation, should not be included in such an estimation. If they are excluded, nine of fifteen inoculated animals, or three-fifths, were successfully infected. That this was not a spontaneous infection activated by the inoculation is indicated by (a) the high percentage of infection following the inoculation of the human material, (b) the fact that spontaneous toxoplasmosis has not been described in rabbits or mice in North America, (c) the absence of similar infection in many animals of the same stock examined as controls. These included animals subjected to simple puncture of the brain, or injected intracerebrally with a number of foreign substances including emulsions of brain tissue from routine human autopsies and from laboratory animals used for other purposes.

Serial Passages

Methods.—Brain tissue from the infant mice and rabbits of the initial passage, obtained as soon after death as possible, was used to transmit the infection to mature rabbits and to adult and infant white mice. The brains were removed under sterile precautions and a portion emulsified in sterile physiological saline solution in the same man-

ner in which the human material was treated. No attempt was made to standardize the dosage, but it may be said that roughly one-quarter to three-quarters of a mouse brain or one-quarter of a rabbit brain was emulsified in 10 to 15 cc. of saline solution. Rabbits and infant mice were inoculated intracerebrally as in the initial passage. The rabbits received 0.2 cc. and the infant mice 0.01 to 0.02 cc. Adult mice were injected with 0.02 cc. intracerebrally by a technique similar to that used for the rabbits and the majority were simultaneously inoculated with 0.2 cc. intraperitoneally. By this means serial transfer of the infection was carried out successfully for 24 passages through rabbits and 22 passages through rabbits and mice during the first 6 months following the initial passage. Many single lines were discontinued prior to the end of this period. In the course of the serial passages, brain emulsions were occasionally passed through Berkefeld N filters. Such filtrates always proved non-infective when inoculated into rabbits and mice. Brain emulsions inoculated into a variety of culture media were repeatedly found to be bacteriologically sterile.

Duration of Illness

148 rabbits were inoculated and of these 131, or 89 per cent, became ill and died spontaneously or were killed when moribund. 11 per cent of the animals remained well and a few of these were sacrificed after a number of months for histological study; the others were used for immunological tests as described below.

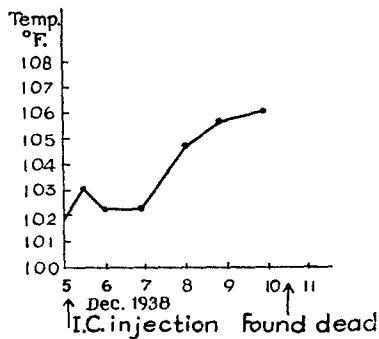
Of the rabbits that became ill and died, or were moribund and killed, 77 per cent showed symptoms within 5 to 9 days, the majority in 5 to 7 days. 19 per cent of the animals died in from 10 to 16 days. The remaining 4 per cent died within 4 days, and in most of these there was considerable gross hemorrhage in the area of inoculation which probably contributed to the early death. None died later than 16 days. Three rabbits dying in from 13 to 16 days were in the initial and succeeding passage, while the infection was probably establishing its virulence.

98 infant mice, ranging in age from 1 to 10 days, were injected. More than half were 1 to 2 days old. Of the total number, 31 were eaten by the mothers; 15 survived and were well for 2 months or more and were reserved for histological examination or immunological experiments; 52, or four-fifths of the non-cannibalized, became ill and died or were sacrificed in 10 to 40 days, the majority succumbing in 2 to 3 weeks.

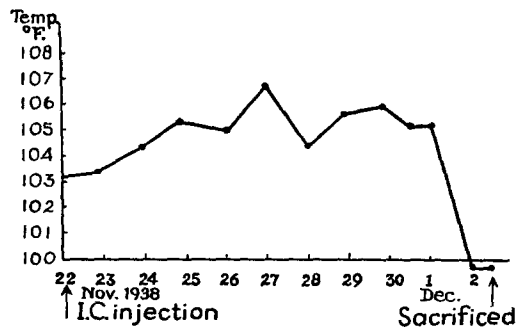
105 adult mice were inoculated. Two survived in apparent health for many months and were used for immunity tests. Approximately 65 per cent of the remaining animals became ill and were sacrificed or died in from 6 to 9 days. 28 per cent died in from 10 to 17 days, although relatively few of these lived beyond the 2nd week. The remaining 7 per cent died in 5 days or less.

Clinical Features of the Experimental Disease in Rabbits and Mice

The rabbits were inspected four times daily. Most of the 131 animals which became ill remained apparently well until the last day of life. During the last 24 hours, they became inactive and reacted poorly to stimuli. They soon developed generalized weakness terminating in paralysis of the hind legs, or of the extremities on one side. Occasionally there were retraction of the head, deviation of the head and eyes to one side, nystagmus, and generalized tremors. Clonic convulsions of short duration and diarrhea were not infrequent. Incontinence of urine was rare. Labored respiration was common terminally. Many of the rabbits showed a striking lack of symptoms until within 3 to 6 hours of death, when the course of the illness became dramatic in its rapidity. A small number were unresponsive during the last 2 to 3 days, but developed more severe symptoms only during the last 24 hours. A number of rabbits had rectal temperatures recorded daily. They showed a rise in temperature on the 2nd or 3rd day which, on the



TEXT-FIG. 1



TEXT-FIG. 2

TEXT-FIGS. 1 and 2. Temperature of rabbits 2-67 and 2-51 inoculated intracerebrally (I.C.) with parasite of human origin showing two common types of febrile reaction.

4th or 5th day, reached a maximum of 3-5°F. above the initial temperature (Text-fig. 1). In some instances, there was a fall in temperature to normal or below before death (Text-fig. 2). Blood counts were made at intervals of several days, and in some rabbits, daily. No constant change was observed in the blood picture. In some animals, there was a tendency toward mild anemia and leucopenia without a significant change in the differential white blood cell count. Leucocytosis did not occur. There was no eosinophilia.

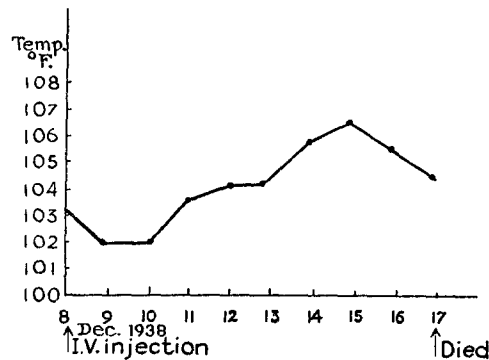
In the infant mice it was difficult to say when symptoms first appeared. Although some seemed stunted, many appeared to develop adequately. The majority seemed to remain well until the last day of life when they became weak, inactive, and at times showed paralysis of the extremities.

The adult mice generally remained apparently well until the last day of life when they became sluggish and unresponsive to stimuli. Their fur was ruffled and they sat hunched up. Paresis of the legs, rapidly progressing to paralysis, often occurred in the last 12 hours. Tonic convulsions were occasionally observed. Mice frequently appeared normal at the night observation and were found dead the following morning.

Results of Other Methods of Transmission

Extracerebral Inoculation in Rabbits and Mice.—Rabbits and mice were susceptible to inoculation by various routes other than the intracerebral. The material used for injection in each instance consisted of infected rabbit or mouse brain emulsion, prepared as above.

Intraperitoneal Inoculation.—Three rabbits inoculated with 1.0 cc. of emulsion died in 9 to 12 days. A fourth rabbit receiving only 0.2 cc. failed to develop symptoms. Of twenty-two mice inoculated with 0.2 to 0.5 cc. of emulsion, fourteen succumbed. The duration of the disease in these animals was 9 to 29 days, a somewhat longer period than after intracerebral inoculation. Frequently for several days before death the mice were inactive, hunched up, and showed ruffling of their coats, but frank neurological signs were not noted



TEXT-FIG. 3. Temperature record of rabbit 2-70 inoculated intravenously (I.V.) with parasite of human origin.

Intravenous Inoculation.—Brain emulsion was centrifuged at low speed and 1.0 cc. of the cloudy supernatant fluid injected into the marginal ear vein of rabbits. Such animals succumbed to a generalized infection in 9 to 10 days (Text-fig. 3).

Intradermal Inoculation.—0.2 to 0.3 cc. of infected brain emulsion was injected into the skin of rabbits. The first sign of reaction, after disappearance of the wheal, was a small pink papule which appeared in 24 to 48 hours. Such a response may follow injection of normal brain tissue and was not regarded as characteristic of a specific infection. In 5 to 8 days, however, the papule was redder, more elevated, and reached a diameter of 9 to 12 mm. or more. On the 4th to 6th day central necrosis began to appear at the summit of the papule as a small yellowish zone, gradually increasing in extent to 4 to 8 mm., and becoming darker in color. Such a papulonecrotic lesion constituted the typical positive skin reaction in intradermally inoculated rabbits. After the first week, the papule became paler, while the necrotic central area appeared as a firm, dark brown, slightly depressed crust. In animals which recovered the necrotic core eventually sloughed away and the lesion disappeared completely. Of eight rabbits which were inoculated by the intradermal route seven developed the typical papulonecrotic lesion described. Daily rectal temperatures were recorded in five, and all manifested fever

which began on the 3rd to 6th day, rising 2-3°F. above the preinjection temperature by the 6th to 9th day. Three of the rabbits developed a generalized infection and died in 11 to 13 days. One of these animals had reacted only with a pink papule without necrosis. Terminally the animals were markedly prostrated, dyspneic, and occasionally showed a subnormal temperature.

Subcutaneous Inoculation.—Of five rabbits receiving 0.1 to 0.8 cc. of emulsion, four remained in apparently good health. The fifth animal died on the 11th day.

Oral Route.—Feeding of infected brain emulsion at intervals by stomach tube to three rabbits was without effect.

Susceptibility of Other Animal Species

Guinea Pig.—Three young animals were inoculated, one intraperitoneally (0.2 cc.), one both intracerebrally (0.1 cc.) and intraperitoneally (0.2 cc.), and the third intracerebrally (0.1 cc.). The first two animals developed symptoms and succumbed in 16 and 18 days. The third animal showed no obvious symptoms for 2 months when it was sacrificed. Histological examination, however, showed it to have been infected.

Chick.—Intracerebral inoculation of ten young chicks, 1 to 11 days of age, produced a fatal infection in four, the birds dying in 3 to 11 days. The other chicks remained symptom-free and were sacrificed after various intervals for histological examination.

Inoculation of fertilized eggs on the 14th day of incubation was followed, in a number of instances, by the hatching at the normal time of chicks with disseminated infection. These chicks died within 3 days.

Monkey.—Two young adult *Macacus rhesus* were inoculated intracerebrally, intravenously, and subcutaneously. They manifested no symptoms and their rectal temperatures remained normal.

Pathology

Parasites.—The morphological characteristics of the parasites present in the lesions of the passage animals were similar in the various tissues of the several species studied, so that a single description is adequate for all. Parasites occurred in varying, but usually large numbers, in nearly all the lesions. Their distribution will be described in the sections on histopathology.

In paraffin sections, 4 to 5 μ in thickness, stained by hematoxylin-eosin, the microorganisms appeared ovoid, fusiform, spherical, or pyriform (Fig. 15 *a, c, e, f, i, l, m*). Rarely slightly crescentic forms were encountered (Fig. 15 *h*). They varied in length from 1.6 to 3.8 μ and in width from 0.8 to 2.3 μ . Their cytoplasm was pink with a faint bluish tinge at times. Situated at or near one pole, usually the broader end of the organism, was an oval or spherical, deeply basophilic, sharply outlined chromatin body which at times was flattened on one side or even band-like. When oval, the long axis of this granule was sometimes at right angles to that of the body of the parasite. A lighter stained central area was often seen in it and there was often a halo of lighter stained cytoplasm about it. Only rarely could fine individual chromatin granules be made out in the nucleus. Binucleated forms were encountered in which two small oval nuclei lay

side by side with their long axes parallel to that of the parasite (Fig. 15 *l*). A faint light line was often detectable in the midline of the long axis of the cytoplasm, indicating that the organism was in process of binary fission. No additional rod-like chromatin body (kinetoplast) nor any polar capsule, filament, or flagellum, could be made out. The staining reactions of the microorganisms were as follows:

Stain	Cytoplasm	Chromatin body
Hematoxylin-eosin	Pink	Dark blue
Phloxin-hematoxylin	Deep pink or red	Dark blue
Eosin-methylene blue	Pink, red, or lavender	Light or deep blue
Giemsa	Deep blue margin with lighter center or dark purple throughout	Light or deep blue
Gram	Lavender	Purple
Carbolfuchsin	Pink	Deeper pink
Patrick Laidlaw	Light brown or red	Darker brown or red
Dominici	Pink or light blue	Light blue
Silver stain (Bielschowsky) (Laidlaw) (Hortega's silver carbonate)	Light grey, granular	Dark grey or black
Gold sublimate stain	Reddish purple, granular	Very dark purple, almost black

In addition to the single forms, sharply outlined clusters of parasites were also present (Fig. 15 *b*). These were round or oval and surrounded by a light refractive membrane which was not doubly contoured. The microorganisms within this cyst were closely approximated and varied in number from eight in a single plane to 150 or more. When the numbers were large, the microorganisms were tightly packed and smaller than the free elements, often being less than 1μ in the long diameter. The outlines of the individual parasites could usually be seen but rarely their cytoplasm seemed to form a syncytium.

In smears of peritoneal fluid from intracerebrally and intraperitoneally inoculated mice stained by the Wright-Giemsa stain the microorganisms appeared larger and more variable in shape than those seen in the paraffin sections. They varied in length from 2.9 to 6.4μ , the average being over 4.5μ in length. The width varied from 1.3 to 2.5μ , the average being about 2μ . They were usually lunate, pyriform, fusiform, or roughly conical, and less often ovoid or oval in shape (Fig. 15 *d, g, j*). One end and at times both might be sharply pointed. Their cytoplasm was light blue and had fine reddish purple granules scattered irregularly through it in small numbers. Small bright vacuoles and lighter areas were present in the cytoplasm usually near the chromatin body. This purplish red nucleus was oval, round, or band-like in shape, sharply outlined, about one-fourth to one-third the size of the body, and usually slightly eccentric in position and nearer the blunt end of the organism. It was also found centrally placed or polar and in the latter position was often molded to the shape of the end of the organism. The nuclear membrane was often deeply stained and a few coarse granules of chromatin were detectable in the nucleus. The microorganism occurred free and in the cytoplasm

of large mononuclear cells. Dividing forms with two oval nuclei lying side by side and a plane of cleavage developing in the cytoplasm were often seen both intra- and extracellularly (Fig. 15 *d, k*). Encysted forms were not seen in these fluids.

Attempts at Cultivation.—Using saline emulsions of rabbit and mouse brains, a number of attempts were made to cultivate the parasite in a variety of bacteriological media. These included beef broth, beef heart broth, dextrose broth, beef and beef heart agar, 1 per cent dextrose agar, 6 per cent glycerol agar, corn starch agar, Loeffler's medium, Petroff's egg medium, Sabouraud's medium, N.N.N. medium, and Noguchi's serum medium. In addition some of these were enriched with defibrinated rabbit's blood. Both aerobic and anaerobic methods were used, and the cultures were incubated at 37.5°C. and at room temperature (about 20°C.). The cultures were observed for varying periods up to 43 days. In no instance was there evidence of growth of the parasite. Attempts to cultivate the microorganism in media containing living cells are in progress, since this has been successful with related parasites of animal origin (5, 6).

Lesions: Rabbits: Intracerebral Inoculation.—

Central Nervous System: Gross appearance: In most instances, the leptomeninges and the external and cut surfaces of the brain and spinal cord showed no gross changes, other than the inoculation tract. Yellowish discoloration of the leptomeninges and a greyish, glassy appearance of the parenchyma were at times noted at the margins of the tract.

Microscopic findings: Leptomeninges.—Localized areas of leptomeningitis were the most constant lesions in these animals (Fig. 7). They consisted of focal infiltration of the pia-arachnoid, or more diffuse infiltration with focal intensification. Lymphocytes and less frequently large mononuclear cells, some of which were actively phagocytic, were the chief elements in the exudate. Plasma cells were present in some of the animals dying after one week. Rarely an eosinophile was identified among the other cells. Edema fluid and extravasated red blood cells were occasionally present. In some animals, more often those dying in the first week of their illness, localized areas of more acute inflammation were found within patches of leptomeningitis of the type described above, or preponderated over the latter. Here, polymorphonuclear leucocytes, many of which were necrotic, fibrin, and homogeneous eosinophilic material and nuclear debris were present in addition to the round cells. Multiplication and hypertrophy of arachnoid and pial cells, at times reducing the size of the subarachnoid lacunae, were frequent. Proliferation of capillary and arteriolar endothelium was often seen. Adventitial and at times intimal infiltration of leptomeningeal arteries and veins by lymphocytes, large mononuclear cells and more rarely plasma cells was variable and was found most often in the more acute foci where polymorphonuclears were also present in this mural exudate. The veins were more often involved. In the necrotizing lesions they showed degeneration of their walls and were at times partially or completely thrombosed and impregnated with fibrin. The infiltration of the walls of the blood vessels often persisted as they penetrated into or emerged from the external zones of the parenchyma (Fig. 7). Beneath the areas in which leptomeningeal veins were thrombosed, hyaline thrombi were often present in the cortical capillaries, and perivascular hemorrhages occurred. In addition to the perivascular spread of the inflammation from leptomeninges to parenchyma, there was at times a direct extension, most frequently where the leptomeningitis was acute. Here the junction between pia-arachnoid and brain tissue was often ob-

scured. The inflammatory process usually extended into the marginal zone of the parenchyma, but at times penetrated to the third cortical layer or the equivalent depth in other regions. There was a moderate astrocytosis in the marginal tissue subjacent to areas of focal leptomeningitis.

Brain and Spinal Cord.—The parenchymal lesions were often superficial and related to the leptomeningeal foci of inflammation. Diffuse and perivascular infiltration by lymphocytes and large mononuclear cells was associated with proliferation of endothelial and adventitial cells and multiplication and hypertrophy of microglia (Fig. 3). In some of the animals that lived longer than a week, plasma cells were encountered among the infiltrating cells. The nerve cells in focal lesions were usually in various stages of degeneration, although they frequently remained remarkably well preserved. When affected, they showed chromatolysis, swelling, pyknosis and displacement of their nuclei, karyorrhexis, fading of the entire cell body, or sclerosis. At the margins of the lesions they were usually unchanged. Within the foci localized swelling and at times fragmentation of myelin sheaths, axones, and dendrites were seen. In the more severe parenchymal focal lesions, which were the less frequent in these rabbits, the infiltration included polymorphonuclear leucocytes in varying numbers (Fig. 4) and the degeneration of neural and neuroglial elements at times culminated in total destruction of the normal architecture. In such areas erythrocytes, fibrin, and cellular debris were present and there were microglial hyperplasia with transitional and phagocytic forms, diffuse local astrocytosis, and proliferation of capillary endothelium. An occasional regional vessel had undergone thrombosis. Chromatolysis, and less frequently, pyknosis of nerve cells, occurred within a wide radius of such a lesion. Focal lesions of the various types described were also found in the periventricular parenchyma, deeper cortical layers, white matter, basal ganglia, and brain stem. They were seen infrequently in the cerebellum and spinal cord. In the cord the outer portions of the white tracts and the parenchyma about the central canal were most often involved and contained small focal lesions.

In some of the rabbits in which the inoculum had apparently reached a lateral ventricle, the lateral ventricles and often the aqueduct of Sylvius, and third and fourth ventricles contained an exudate composed of lymphocytes, large mononuclear cells, and at times, many polymorphonuclear leucocytes, much fibrin, and eosinophilic and nuclear debris. The ventricular walls were denuded of ependyma in places and the bared subependymal tissue was infiltrated by cells similar to those in the ventricular exudate. In addition there were lesions similar to those in the cortex, and perivascular and mural infiltration of vessels. At times a narrow band of subependymal tissue was necrotic, its neural elements being degenerated (Fig. 6). Here cellular debris, polymorphonuclear leucocytes, occasional lipid-laden phagocytes and hypertrophied astrocytes showing clasmotodendrosis and pyknosis of their nuclei were seen. At and near the margins of the areas denuded of ependyma, ependymal cells swollen to two or more times their normal size, could often be found. These contained varying numbers of parasites. Such cells were frequently remarkably well preserved but often their nuclei were displaced to the cell margin and were flattened and pyknotic. Some seemed to have ruptured, liberating the parasites. When exudate occurred in the ventricle and when the ventricular walls were involved, focal inflammation of the choroid plexus was the rule (Fig. 8). A number of choroid papillae might appear quite normal except for coarse

vacuolization of the cytoplasm of the choroid epithelium while a few papillae were severely affected. These showed infiltration of their connective tissue cores by lymphocytes and large mononuclear cells with mural infiltration of the choroid vessels. Where the process was more severe, the papillae were swollen and edematous, polymorphonuclear leucocytes and fibrin were present in the exudate in addition to the round cells in the connective tissue and walls of the blood vessels, endothelial proliferation of capillaries and multiplication of connective tissue cells occurred in the cores of the papillae, and desquamation of the choroid epithelium was observed. Adhesions between adjacent papillae or between a papilla and ventricular wall, bared of ependyma, occurred in these areas. Adjacent to the denuded zones, the choroid epithelial cells were often swollen, vacuolated, and pale. Their cytoplasm at times contained varying numbers of parasites, which in some instances filled the cell to bursting. The cell nucleus was often peripherally displaced, flattened, and pyknotic. The wall of the central canal of the spinal cord was at times similarly affected. In one instance, a dorsal spinal root showed perivascular lymphocytic infiltration and proliferation of capillary endothelium.

Granulomas.—Small rounded or oval lesions (Fig. 5) were occasionally encountered in the cerebral cortex or periventricular parenchyma. They were rarely seen in the leptomeninges, basal ganglia, brain stem and spinal cord, and were found only once in the cerebellum. They varied in size from 68 by 76 μ to 103 by 106 μ in paraffin-embedded material. They were composed of large, irregular or polygonal cells, varying little in size and lying closely approximated. Their cytoplasm was abundant and their nuclei large and oval with a small amount of finely granular chromatin and a few coarser granules. Lymphocytes, and less often, large mononuclear cells were present in varying, but usually small numbers, in the outer half of the granuloma. Nerve cells included in the margin of such a lesion, as well as those immediately adjacent to it, appeared relatively well preserved, although occasional ones were sclerotic. Marginal capillaries showed endothelial proliferation, and at times perivascular lymphocytic infiltration. The plump endothelial cells showed a close resemblance to the epithelioid cells of the contiguous granuloma. About some of the granulomas, there was a mild, diffuse lymphocytic infiltration of the parenchyma, which also showed astrocytosis, and conversion of some microglia into rod cells.

Distribution of Parasites in Lesions of Central Nervous System.—Intracellular parasites in varying numbers were common. They were found in large mononuclear cells, proliferating capillary endothelial cells, transitional microglia, epithelioid cells of granulomas, ependymal and choroid epithelial cells, pial and arachnoidal cells, and once each in an endothelial cell of a vein and in a polymorphonuclear leucocyte.

Free parasites, and less frequently cysts, were present in nearly all the leptomeningeal and parenchymal lesions. They were found in the tissue, in the subarachnoid and perivascular spaces, and in vessel walls. Both in the pia-arachnoid and parenchyma, but more frequently in the latter, microorganisms could at times be seen penetrating beyond the margins of the inflammatory and productive reaction.

Lung.—*Gross appearance:* Congestion, frequently localized, and pale areas of emphysema, or purplish sunken patches of atelectasis were noted in the lungs of some animals. *Microscopic findings:* The pleura was normal. The parenchyma was often congested. Hemorrhages into a localized cluster of alveoli or areas of edema were seen in which pink amorphous material, erythrocytes, and occasional large mononuclear cells were present

in the alveolar spaces. Occasionally lymphocytes and polymorphonuclear leucocytes were also present in the alveolar spaces and rarely in adjacent bronchi. Scattered patches of emphysema and atelectasis were encountered. Less frequently, localized areas of broadening of the alveolar septa were seen (Figs. 9 and 10). This was due to edema, congestion and infiltration of the alveolar walls by lymphocytes, large mononuclear cells, and occasional polymorphonuclear leucocytes, as well as proliferation of the endothelium of the capillaries. The septal capillaries contained many neutrophils. The alveolar spaces were encroached upon and occasionally contained a few cells similar to those found in their walls. Sometimes the swelling of the septa was extreme and polymorphonuclear leucocytes predominated in the septal exudate, which was necrotic. Such a focus obliterated a cluster of alveoli and resulted in a miliary abscess. The walls of bronchi and of arteries and veins were only infrequently involved. Exudate like that in the septa and alveoli at times occupied a bronchial wall leaving the epithelium intact. Only very rarely was exudate seen within a bronchus, in which case the bronchial wall was penetrated and the exudate continuous with that in nearby alveoli. Vascular involvement, when it occurred, was usually in the form of a periarteritis or periphlebitis, but at times focal intimal (subendothelial) or medial infiltration was encountered. The affected area of intima was edematous and protruded into the lumen of the vessel.

Parasites were found among the infiltrating cells in the alveolar walls and spaces. In addition to free and encysted forms, they were seen in large mononuclear cells and proliferating endothelial cells of capillaries. Some were found free in alveolar spaces without accompanying reaction.

Spleen.—*Gross appearance:* In some instances the organ was enlarged and somewhat soft. Frequently it was unchanged. *Microscopic findings:* Many erythrocytes were present in the pulp in some animals while they were reduced considerably below normal in others. Neutrophils were sometimes present in the pulp, rarely forming clusters, but were more frequent in the sinusoids. Large mononuclear cells, often actively phagocytosing erythrocytes and neutrophils, were common in the sinusoids. There were small focal necrotizing lesions in the pulp and less often in the Malpighian corpuscles. In these, cytoplasmic and nuclear debris, fibrin, polymorphonuclear leucocytes, and fewer lymphocytes, large mononuclear cells, and rarely plasma cells were seen. The reticulum cells at the margins were hyperplastic. Parasites were identified in the focal necrotizing lesions and in the lumina and endothelial cells of sinusoids. In one instance they were present in the capsule in an area mildly infiltrated by lymphocytes and monocytes.

Heart.—*Gross appearance:* No abnormalities were noted. *Microscopic findings:* Focal lesions occurred in the myocardium with moderate frequency. These consisted of small interstitial collections of lymphocytes and large mononuclear cells, associated with a mild or marked degeneration of the myocardial fibers (Fig. 11). When severe, the latter showed loss of striation, vacuolization, granular degeneration, or hyaline transformation and fragmentation associated with proliferation of the muscle nuclei. In the more marked lesions, polymorphonuclear leucocytes and some proliferation of the interstitial connective tissue, and of the endothelial lining of local capillaries were seen. Rarely perivascular infiltration about a coronary vessel or slight infiltration of the epicardium was encountered near a myocardial focus. Parasites were seen infrequently, but when observed were often abundant. They were found within the sarcoplasm of involved muscle fibers and in the interstitial connective tissue.

Liver.—*Gross appearance:* Except for frequent coccidial lesions seen as white or yellowish white nodules the liver showed little but congestion macroscopically. *Microscopic findings:* The sinusoids were frequently distended with erythrocytes, and the Kupffer cells at times were prominent and increased in number. The hepatic cells about the central veins were coarsely vacuolated in some instances, and occasionally the entire lobule showed this fatty change. The common occurrence of coccidial lesions complicated the picture but small focal necrotizing lesions were noted which were similar to those seen in apparently coccidia-free mice. Parasites like those in the other organs were demonstrated in them at times. The lesions were rounded, fairly sharply demarcated, and variable in position in the lobule, sometimes lying in contact with the central vein or portal space. In recent lesions intense local congestion of the sinusoids, edema, concentration of lymphocytes and neutrophiles in the sinusoids, and coarse vacuolization and pallor of the hepatic cells, as well as pallor or pyknosis of their nuclei were seen. More advanced lesions showed disintegration and disappearance of liver cells, clusters of neutrophiles, some of which were invading necrotic hepatic cells, nuclear debris, collapsed sinusoids, and proliferation of the sinusoidal endothelium (Fig. 13). When such a lesion adjoined a portal space, polymorphonuclear leucocytes, large mononuclear cells, additional lymphocytes, and proliferation of fibroblasts were seen. More often the changes in the portal areas were due to coccidiosis and included bile duct proliferation and mild cirrhotic changes. Parasites were seen in hepatic and Kupffer cells and free in the sinusoids. They were present in the lesions but were also seen without an accompanying reaction.

Suprarenal.—*Gross appearance:* Normal. *Microscopic findings:* In a few instances small focal inflammatory and necrotizing lesions were found in the cortex (Fig. 14). These were rounded and in them necrosis of cortical cells, neutrophiles, many undergoing degeneration, fibrin, lymphocytes, and much nuclear debris were present. There was proliferation of the endothelial cells of capillaries. Parasites occurred in the lesions, free, encysted, and in the cytoplasm of hyperplastic endothelial cells.

Other Organs and Tissues.—The striated muscles rarely showed focal myositis. The lesions were small and in them muscle fibers presented a loss of striation, hyaline or granular degeneration, multiplication and pyknosis of muscle nuclei and proliferation of sarcolemma cells. Lymphocytes, large mononuclear cells and fewer neutrophiles occurred within the sarcolemma sheath and in the interstitial connective tissue. The latter was increased in amount in some instances. Parasites were found free among the infiltrating cells and within necrotic muscle fibers.

In the loose areolar tissue of the orbit adjacent to the sclera, about the extraocular muscles, and more often about the optic nerve, small inflammatory foci containing neutrophiles, lymphocytes, and large mononuclear cells were occasionally seen. Focal myositis, like that described above, also occurred in the extraocular muscles. The dural and leptomeningeal sheaths of the optic nerve were similarly infiltrated in one instance with neutrophiles predominating. There was direct extension of the inflammation into the outer portion of the nerve with mild degenerative changes in its neural and neuroglial elements. Parasites were abundant in this lesion. They were also seen in some of the other lesions. Once a few microorganisms were seen in the ciliary body without an accompanying inflammatory reaction. The choroid and retina were uninvolved.

Of the remaining organs, the kidneys rarely showed swelling of the epithelial cells of

their convoluted tubules. Hyaline droplets occurred in the cytoplasm of these cells and granular and red blood cell casts were seen in the tubules. No parasites were identified in the cells or lumina. Once in the large, and once in the small intestine, parasites were found within epithelial cells of the mucosa. Some of these cells were vacuolated but there was no inflammatory reaction present. All the other organs were normal. (The osseous system was not examined.)

Infant Mice: Intracerebral Inoculation.—

The findings were in many respects similar to those in the rabbits. The following differences were noted.

Central Nervous System.—In the gross, small focal, yellowish, softened areas were frequently seen on the surface of the cerebrum. Plasma cells were much more frequent in the leptomenigeal and parenchymal exudates since many animals survived inoculation for two to four times as long as the rabbits. Parenchymal lesions were much more prominent and often more severe, although here, too, the infection seemed to spread from the leptomeninges and ventricular system by direct extension and by way of the perivascular spaces. Large areas of cerebral cortex (Fig. 1), adjacent white matter, and periventricular parenchyma, especially in the basal ganglia and less often the brain stem, showed severe necrotizing and inflammatory changes obliterating the local architecture. A striking difference from the findings in the rabbits was the tendency to marked calcification (Fig. 2) of these necrotizing lesions. This occurred as small and large masses of coarse and fine granules. Nerve cells and their processes, other unidentified cells, and rarely what were taken to be parasites, single and in cysts, were found to be encrusted by calcium. The exudate in glial and vascular bands within the necrotic foci or in the parenchyma at their margins was usually moderate in amount and round cell in type, plasma cells often predominating. Parasites could frequently be found in the marginal exudate which occasionally contained acute foci. At times, however, only residual masses of calcium with little or no remaining inflammatory reaction and no microorganisms were encountered. Granulomas were similar to and as relatively infrequent as those in the rabbits.

Of the other organs, the lungs were involved most often, the liver occasionally, and the spleen, myocardium, and striated muscles rarely. In general, lesions in these other organs were not common. The histological findings were similar to those in the rabbits. Parasites occurred in the sites mentioned and in addition were seen in the walls of an involved bronchus and in an alveolar capillary.

Adult Mice: Intracerebral and Intraperitoneal Inoculation.—

The pathologic findings were similar in general to those in the rabbits.

Central Nervous System.—Large areas of diffuse necrosis and inflammation were more common in the cerebrum in the adult mice than in the rabbits, but were not as conspicuous as in the infant mice. Calcification, a prominent feature in the infant mice, was not encountered. Parasites were abundant in most of the lesions.

Of the other organs, the lungs, liver, spleen, and less often the heart and striated muscles (Fig. 12) showed lesions similar to those in the rabbits. Parasites were present in many of the lesions but were more frequently identified in the liver and spleen than in the other organs. In addition to their occurrence as given in the description of the

rabbit pathology, they were seen in a small bile duct and in the exudate about a portal vein. Peritonitis due to the intraperitoneal inoculation was an additional finding. This was not marked and was characterized by the presence of an exudate consisting of lymphocytes, neutrophils, large mononuclear cells, fibrin, and cellular debris. Focal and diffuse inflammatory changes were seen in the capsules of the spleen and liver, omentum, mesentery, and in the perisuprarenal, perirenal, and peripancreatic fat. The serosa of the gastrointestinal tract was the site of similar changes, and rarely focal collections of inflammatory cells were seen in the muscular layers or even submucosa. In one instance a portion of the pancreas near the spleen showed marked edema and infiltration, with necrosis of the exudate in the capsule, interlobular septa, and at times between acini of adjoining lobules. There was mild round cell infiltration of the tunica vaginalis of the testes and septa of the epididymides in one animal. Parasites, free, encysted, and in large mononuclear cells, were present in the exudate. They were usually abundant in the lesions of the various tissues mentioned in or near the peritoneal cavity. Once parasites were observed without accompanying reaction in the retina, and once in the optic nerve sheath.

Pathologic Findings in Animals Inoculated by Extracerebral Routes Alone

Rabbits and Mice: Intraperitoneal Inoculation.—

Gross appearance: In some animals, a localized lesion was present in the abdominal muscles at the site of inoculation. This was pink, nodular, and surrounded by congested vessels. Occasionally a small amount of turbid yellowish fluid, which clotted spontaneously, was present in the peritoneal cavity. Stringy bands of fibrin were sometimes attached to the loops of intestine, the surfaces of which were dulled. The omentum was frequently rolled up, nodular, reddened, and adherent to some of the organs. The spleen was often enlarged, soft and purplish.

*Microscopic findings: Central Nervous System.—*Of three rabbits inoculated, one showed severe lesions in the brain and mild ones in the spinal cord while the others showed moderate but widely disseminated lesions in the brain alone. These were focal and very similar histologically to those in the rabbits previously described, except for the absence of occasional larger necrotizing lesions in the cortex and basal ganglia. There was a wider distribution of small perivascular parenchymal lesions, frequently acute and necrotizing, but also chronic and occasionally granulomatous. The cerebral cortex and basal ganglia were most frequently involved. The leptomeninges, ventricular walls, and choroid plexuses were regularly affected but to a lesser degree than in the intracerebrally inoculated animals, although in some instances secondary spread of the inflammation into the parenchyma was observed even here. Conversely, the impression was often gained that some foci of leptomeningitis were secondary to the parenchymal lesions. Of ten mice similarly inoculated, two showed very mild, almost exclusively leptomeningeal lesions, five showed moderately widely disseminated lesions much like those in the rabbits, and three showed very marked parenchymal lesions like those in the infant mice. Large areas of necrosis and inflammation of the cerebral cortex, adjacent white matter and basal ganglia were common in these animals, but were not accompanied by calcification.

*Other Organs.—*All three of the rabbits and six of the mice had pulmonary lesions. The spleen was involved in two rabbits and six mice, the liver in each rabbit and six

mice, and the heart in all the rabbits, but only two of the mice. Evidence of peritonitis was found in the majority of the animals, although at times it was mild. The splenic and hepatic capsules, serosa of the gastrointestinal tract, and at times, muscularis and submucosa, omentum, and perirenal fat showed focal or rarely diffuse inflammation. The exudate was often acute and necrotic in the fatty tissue. Striated muscles were involved four times in the mice. The lesions in the various organs were essentially similar to those described for the intracerebrally inoculated rabbits. Parasites were present in the majority of the lesions.

Intravenous Inoculation.—

Rabbits had widely disseminated brain lesions, which were similar to the moderate lesions in the intraperitoneally inoculated rabbits. No lesions were found in the spinal cord. The lungs and spleen were markedly involved, and the liver less so. The lesions were like those described elsewhere and parasites were present in the majority of them.

Intradermal Inoculation.—

Complete autopsies were performed on five rabbits so inoculated. The site of inoculation in the skin was ulcerated at the height of reaction, some of the epithelium having sloughed away. The dermis was edematous and the connective tissue fibers swollen and hyalinized. At times they were markedly necrotic and fragmented. There was intense diffuse and focal perivascular infiltration by lymphocytes and neutrophils, which were often degenerated. Occasional large mononuclear and plasma cells were also seen and at times the septa of the subcutaneous fat were infiltrated. Parasites were numerous in and about the lesions. The brain and spinal cord showed widely disseminated, moderate lesions in two animals similar to those already described. In each the heart and suprarenals, and in one the lungs, spleen, and intraocular muscles showed lesions. The lungs were most severely involved.

Subcutaneous and Oral Routes.—

A complete examination was made of only one rabbit treated by each of these routes. The rabbit fed infected material proved negative, while the subcutaneously inoculated animal showed much the same picture as the intradermally inoculated animals: a mild meningoencephalitis, focal interstitial pneumonia, and localized lesions in the liver, spleen, and suprarenals. In the latter, the medulla as well as cortex was involved. The dermis and subcutaneous tissue at the site of inoculation showed changes similar to, but less severe, than those in the same tissues in the intradermally inoculated animals.

Other Animals Inoculated.—

Guinea Pig.—Of three animals inoculated, respectively, by the intracerebral, intraperitoneal, and by these routes combined, the first and last showed moderate lesions of the central nervous system typically like those in the rabbits, while the other animal was free of them. The intracerebrally inoculated guinea pig showed no lesions in any of the other organs while the other two had myocardial and suprarenal cortical lesions. The animal receiving the combined inoculation showed lesions in striated muscles in addition. Parasites were present in many of the lesions.

Chick.—These birds were inoculated intracerebrally. All of those that died within a

brief period and some of those that remained apparently well and were ultimately killed, showed changes in the central nervous system very much like those in the other species of animals described. The lesions contained typical parasites. The other organs were not involved.

In those instances in which fertilized eggs were inoculated and hatched, the chicks died within a few days and showed severe, widespread lesions, more nearly like those in the infant mice than in the adult mice or rabbits. Unlike the infant mice, other organs were frequently affected, especially liver and heart. The lesions were similar to those described in other animals and the majority contained parasites.

Monkey (Macacus rhesus).—All the organs were free of lesions and parasites.

Summary of the Pathology of the Experimental Disease

Animals experimentally infected with the parasite obtained from the human infant showed a disseminated meningoencephalitis characterized by focal inflammatory, necrotizing, and productive lesions; an interstitial pneumonia rarely complicated by lobular pneumonia and miliary abscesses; and focal inflammatory and necrotizing lesions in the spleen, liver, heart, suprarenals, and occasionally striated muscles. Parasites occurred in the lesions, both intra- and extracellularly.

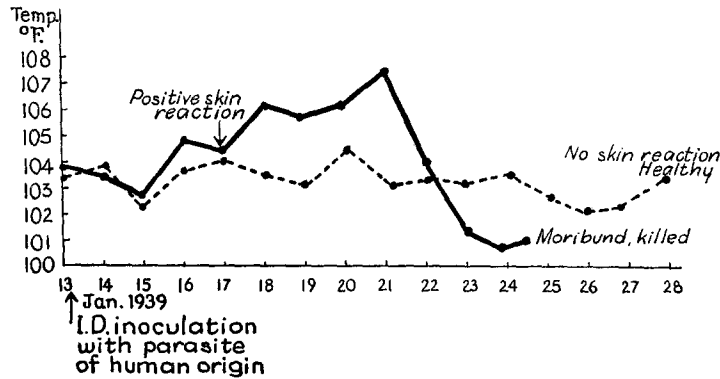
Immunity

Resistance of Experimental Animals to Infection.—As pointed out above, a small proportion of the passage rabbits failed to develop symptoms after intracerebral inoculation¹ of rabbit or mouse brain emulsion, although other rabbits and mice inoculated simultaneously and with the same materials succumbed in the usual time. Eight of these “naturally” resistant rabbits, as well as two rabbits which had recovered from an initial intradermal, two from a subcutaneous, and one from an intraperitoneal inoculation, were reinoculated,¹ intracerebrally or otherwise, one to three times after an interval of one to 23 weeks. All of these animals remained symptom-free, whereas simultaneously inoculated control rabbits and mice proved susceptible (with the exception of three control rabbits which apparently possessed a natural resistance).

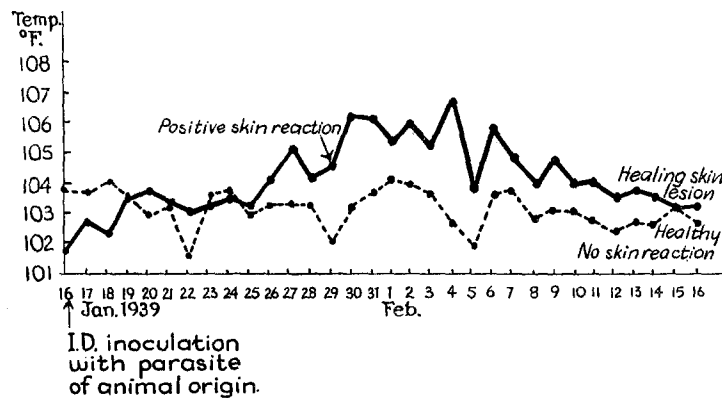
The susceptibility of the controls, and those referred to below, was confirmed in each animal by histological examination which always showed the presence of typical lesions

¹ The infectivity of the inocula in the experiments described in this section was not standardized, since weighed amounts of brain tissue and measured volumes of physiologic salt solution were not used in the preparation of the emulsions, and since the parasite content of the tissues used no doubt varied. In each reinoculation, the intracerebral dose for rabbits was 0.2 cc.; for mice, 0.02 cc. intracerebrally and 0.2 cc. intraperitoneally. Intradermal inoculations were made with 0.2 to 0.3 cc.

and parasites in the central nervous system and other organs. The results of the tests are detailed in Table I*a*. It is to be noted that rabbits which recovered from an initial inoculation with the parasite of human origin, regardless of the route administered,



TEXT-FIG. 4. Two rabbits inoculated intradermally (I.D.) with 0.3 cc. of rabbit brain infected with the parasite of *human* origin. The solid line represents the temperature curve of a normal control animal, rabbit 2-99, following this intradermal injection. Note the rise in temperature on the 3rd day which was followed by a papulonecrotic skin reaction and death on the 11th day. The broken line represents the temperature curve following the intradermal inoculation of an animal, rabbit 2-24, which had recovered from a previous intracerebral inoculation (I.C.) of rabbit brain infected with the parasite of *human* origin. Note the absence of a febrile or of a skin reaction. This animal remained in good health.



TEXT-FIG. 5. Two rabbits inoculated intradermally (I.D.) with 0.25 cc. of rabbit brain infected with the parasite of *animal* origin. The solid line represents the temperature curve of a normal control animal, rabbit 3-05, following the intradermal inoculation. Note the fever which was attended by a positive skin reaction. The broken line represents the temperature curve of an animal, rabbit 2-39, receiving a similar intradermal inoculation. This rabbit had previously recovered from a subcutaneous and an intracerebral inoculation of rabbit brain infected with the parasite of *human* origin. Note the absence of a febrile or a skin reaction.

failed, if reinoculated intradermally, to develop the positive skin reaction which usually appeared in non-resistant rabbits (papulonecrotic lesion at site of inoculation and fever, occasionally leading to generalized infection and death) (Text-fig. 4). One rabbit surviving intracerebral inoculation was resistant to subsequent intravenous inoculation although this is ordinarily fatal for previously uninoculated animals. A similar resistance to repeated intravenous inoculation has been observed in five other rabbits not listed in the table (used in collateral experiments) which had been initially inoculated by various routes.

In summary, it should be remarked that no rabbit surviving an initial inoculation with the parasite of human origin, whatever the route used, ever succumbed to a subsequent inoculation.

Six mice which survived an initial inoculation (two intracerebral, one combined intracerebral and intraperitoneal, and three intraperitoneal) were reinoculated intracerebrally and intraperitoneally within 5 to 21 weeks, with material which was regularly fatal for control rabbits and mice. These mice remained symptom-free. Two infant mice, not listed in the table, which were resistant to intracerebral inoculation at the age of 4 days, succumbed to intracerebral reinoculation 4 months later in the usual time.

It may be concluded that mice also, having survived an initial inoculation of the human strain of *Toxoplasma*, are usually resistant to reinoculation.

Cross-Immunity.—A number of the rabbits and mice which had been proved by repeated intracerebral and other methods of inoculation to be immune to infection by the parasite of human origin were tested for resistance to a strain of *Toxoplasma* isolated from a guinea pig and serially passaged in mice.² The details are recorded in the next to last column in Table Ia.

These animals, including seven rabbits and four mice, were reinoculated with the animal strain within 2 to 6½ weeks of their last reinoculation with the parasite from the human case. All remained symptom-free for periods varying from 7 to 13 weeks when they were sacrificed, while the control rabbits and mice succumbed to the infection in the usual time. One control mouse proved naturally resistant. One of the rabbits of this group, 2-39, was an animal which had resisted two inoculations of the parasite of human origin. On intradermal reinoculation (0.25 cc.) with the parasite of animal origin, no skin lesion appeared, while the control rabbit, 3-05, developed a typical papulonecrotic skin reaction and fever (Text-fig. 5).

There was, then, a cross-immunity between the two parasites as judged by skin protection, as well as the cross-immunity manifested by protection against intracerebral inoculation.

² This was secured through the courtesy of Drs. Olitsky and Sabin of The Rockefeller Institute.

TABLE I a

Resistance to Reinoculation of Animals Surviving an Initial Inoculation with Toxoplasma

Animals surviving initial inoculation with human strain of Toxoplasma	Reinoculation with human strain of Toxoplasma		Controls for animals reinoculated with human strain	Reinoculation with animal strain of Toxoplasma		Controls for animals reinoculated with animal strain
	Number of animals, route and fate	Interval after initial inoculation <i>wks.</i>	Number of animals, route and fate	Number of animals, route and fate	Interval after last inoculation with human strain <i>wks.</i>	Number of animals, route and fate
13 rabbits 8, I.C. 2, I.D.* 2, S.C. 1, I.P.	<i>1st reinoculation</i> 13 rabbits all survived 10, I.C. 2, I.D.† 1, I.P.	1-18	15 rabbits 14 rabbits, I.C. 11 d. or s. 5-12 days 3 survived‡ 1 rabbit, I.D.§ d. 13 days 8 mice, I.C. & I.P., d. or s. in 7-9 days	7 rabbits all survived 6, I.C. 1, I.D.†	2½-6½	6 rabbits 5, I.C., d. or s. 2-3 days 1, I.D.,* positive skin reaction 3 mice, I.C. & I.P., d. or s. 9-18 days
	<i>2nd reinoculation</i> 7 rabbits all survived 4, I.C. 2, I.D.† 1, I.P.	3-14	7 rabbits 5, I.C. 4 d. or s. in 5-10 days 1 survived‡ 2, I.D.* 1 d. 11 days 1 survived, positive skin reaction 2 mice, I.C. & I.P. 1 s. 6 days 1 d. 7 days			
	<i>3rd reinoculation</i> 3 rabbits all survived 2, I.C. 1, I.V.	5-23	2 rabbits, I.C. 1 d. 9 days 1 s. 10 days 3 mice, I.C. & I.P. 1 d. 7 days 2 s. 6 and 7 days			
6 mice 2, I.C. 1, I.C. & I.P. 3, I.P.	<i>1 reinoculation</i> 6 mice all survived. Each I.C. & I.P.	5-21	5 mice, I.C. & I.P., d. or s. 6-11 days Litter of 7 two day old mice, I.C., d. or s. 14 days 2 rabbits, I.C. 1 d. 5 days 1 s. 7 days	4 mice, I.C. & I.P., all survived	2-3½	4 mice, I.C. & I.P. 3 s. or d. 6-18 days 1 survived‡ 3 rabbits, I.C., d. or s. 8-12 days

I.C. = intracerebral inoculation. I.C. & I.P. = combined intracerebral and intraperitoneal inoculation. S.C. = subcutaneous inoculation.

I.D. = intradermal inoculation. s. = moribund, sacrificed. d. = died.

I.P. = intraperitoneal inoculation. I.V. = intravenous inoculation.

* Positive skin reaction (papulonecrotic lesion, fever).

† Negative skin reaction (transient pink papule without central necrosis. No fever).

‡ Naturally resistant.

§ Negative skin reaction (but mild fever and fatal generalized infection).

TABLE I b

Resistance to Reinoculation of Animals Surviving an Initial Inoculation with Toxoplasma

Animals surviving initial inoculation with animal strain of Toxoplasma	Reinoculation with animal strain of Toxoplasma		Controls for animals reinoculated with animal strain	Reinoculation with human strain of Toxoplasma		Controls for animals reinoculated with human strain
	Number of animals, route and fate	Interval after initial inoculation <i>wks.</i>	Number of animals, route and fate	Number of animals, route and fate	Interval after last inoculation with animal strain <i>wks.</i>	Number of animals, route and fate
4 rabbits 3, I.C. 1, I.D.*	4 rabbits, I.C., all survived	3-5	2 rabbits, I.C., d. 2 and 8 days 3 mice, I.C. and I.P., s. 9-15 days	4 rabbits, I.C., all survived	2½-8½	3 rabbits, I.C., d. 5-11 days
1 mouse, I.C. & I.P.				1 mouse, I.C. & I.P., sur- vived	13½	1 rabbit, I.C., d. 8 days

The attempt was also made to determine whether, conversely, animals which had recovered from an initial inoculation with the animal strain of the parasite were resistant to the human strain. Table I b records four rabbits and a mouse which failed to develop symptoms after inoculation with the animal strain of Toxoplasma. The rabbits were reinoculated intracerebrally with the same strain and proved resistant while the control rabbits and mice succumbed. After an interval of 2½ to 13½ weeks following the last inoculation with the animal strain, the five animals were reinoculated with the human strain. They showed no evidence of having become infected and were healthy when sacrificed 3 to 7 weeks later, although control rabbits died in 5 to 11 days.

Comment.—The nature of the immunity noted in these animals has not yet been adequately investigated. The so called naturally resistant animals may have had a non-specific resistance which was perhaps augmented by the initial inoculation. The possibility that these animals might have had a mild previous Toxoplasma infection cannot be ruled out although spontaneous toxoplasmosis has not been described in North America in rabbits or mice. The data at hand do not permit a decision as to whether the resistance of recovered animals depends upon a tissue immunity, the occurrence of protective bodies in the circulating blood, or both. However, the above experiments indicate that the immunity in these animals is general, and extends to tissues distant from the site of inoculation. This does not necessarily indicate a purely humoral immunity but may depend upon a

dissemination of the infection with the development of resistance in each affected tissue. Levaditi and his coworkers (6), who made very similar observations on the resistance of rabbits to an animal strain of *Toxoplasma* (*T. cuniculi*), concluded that in these animals there was no humoral immunity but that immunity depended upon a local cellular resistance in each organ affected. Sabin and Olitsky (5) came to much the same conclusion with respect to rabbits, but were able to demonstrate protective antibodies in the serum of convalescent monkeys which had been inoculated with their strain of *Toxoplasma*.

Pathologic Findings in Resistant Animals.—No gross pathologic changes were noted in the animals of the group surviving repeated inoculations of the human or animal strain of the parasite. Histologically, the brains of these rabbits often showed indications of an old needle puncture, but there was no evidence of active inflammation. Occasionally scattered mild perivascular or small focal leptomeningeal collections of lymphocytes were noted. No parasites were found in relation to such changes, and whether they represented the residue of a former specific inflammation, or were due to some casual unrelated process, is not possible to determine. The brains of two rabbits contained parasites in the form of a rare cyst unassociated with adjacent degeneration or inflammation.

The brains of two of the resistant mice showed scattered small focal cellular lesions similar to those described in the section on pathology. One mouse showed an occasional parasitic cyst in the brain without surrounding inflammation. The brains of the other resistant mice contained no parasites and showed in general the same findings as those of the rabbits. In addition a small focal area of intracerebral calcification without adjacent inflammation or degeneration was found in two of the mice. Neither rabbits nor mice showed lesions in organs other than the brain.

In summary then, minimal lesions and occasional parasites could be found in the central nervous system of some of the resistant animals, although this was not often the case.

DISCUSSION

Identity of Parasite.—That the microorganism isolated from the lesions of the central nervous system of the human infant is a *Toxoplasma* is indicated by the following:

1. Its morphology corresponds to that of *Toxoplasma* of animal origin. In *smears*, *Toxoplasma* is seen as a sharply outlined crescentic or curved organism, 4 to 6 μ long and 2 to 3 μ wide. Both ends may be pointed or one may be blunt and rounded. Each parasite contains a rounded or oval chromatin body, approximately one-third the size of the microorganism, centrally placed or nearer the blunt extremity. In *sections* of fixed tissue or under pressure, ovoid, rounded or fusiform types measuring 3 \times 2 μ

are more commonly seen in which the chromatin body is nearly always polar in position. Reproduction is by simple binary longitudinal division. Clusters of closely approximated parasites are designated as cysts, although a true cyst wall has not been demonstrated with certainty. These aggregations of microorganisms have been interpreted by some as indicative of reproduction by schizogony. The commonly cited appearance of *Toxoplasma* in smears as given above corresponds to that of the parasite as seen in smears of the peritoneal fluid of mice to which the human infection was transmitted. This parasite of human origin, as observed in sections of fixed material from the nervous system of the infant and in similar histologic preparations of the animals infected from it, is identical in its appearance with the Rockefeller Institute animal strain of *Toxoplasma* observed under similar conditions.

2. The course of the disease and the lesions produced in the animals inoculated with the protozoan from the human case are very similar to those noted in the same species by inoculation of a *Toxoplasma* of animal origin. Experimental toxoplasmosis is an infection which often runs an acute or subacute course and which is usually fatal, especially after intracerebral inoculation. The lesions in experimental toxoplasmosis as reported by Levaditi (6) and others (7), and as the authors observed it in rabbits and mice inoculated with the Rockefeller Institute strain of *Toxoplasma* of animal origin, may be summarized as follows: After intracerebral inoculation, rabbits develop focal inflammatory lesions in the pia-arachnoid, brain and spinal cord, walls of the ventricles and central canal, and choroid plexuses. The exudate is composed of lymphocytes and large mononuclear cells with the addition of neutrophils and fibrin when necrosis occurs, and plasma cells in the more chronic lesions. Productive changes, such as multiplication of leptomeningeal cells, proliferation of microglia and fibroblasts, are common. *Toxoplasmata* are present in the lesions and are most abundant in the degenerative foci. They occur free, "encysted," and intracellularly. They are seen in the cytoplasm of large mononuclear and leptomeningeal cells, endothelial cells of capillaries, epithelioid cells of granulomata, ependymal and choroid epithelial elements, and rarely in nerve cells. They are present in perivascular spaces, from which they may spread with little initial reaction into the surrounding parenchyma. Similar focal inflammatory and degenerative lesions with a frequently associated productive reaction are seen in other organs, notably lung, liver, and spleen, and less often heart and suprarenals. *Toxoplasmata* are present in these lesions. Similar changes are seen in mice inoculated by the combined

intracerebral and intraperitoneal routes. These lesions are virtually identical with those produced by the parasite derived from the human infant.

3. The susceptibility of the rabbit, mouse, guinea pig, and chick to this parasite infecting a human infant corresponds to the wide host range of *Toxoplasma* of animal origin. As noted in a previous paper (1), *Toxoplasma* has been described as a spontaneous infective agent in a variety of species of mammals and birds from many parts of the world. It was pointed out that many workers have demonstrated the low host specificity of *Toxoplasma* (6, 8). *T. cuniculi*, for instance, will infect the guinea pig, mouse, pigeon, chick, and other animals. This is unusual for a protozoon and is a feature that emphasizes the similarity between the microorganism from the human case and *Toxoplasma* of animal origin.

4. Convincing evidence of the nature of the protozoon isolated from the infant was obtained by means of cross immunity experiments described above. Rabbits and mice, shown by repeated reinoculation to be immune to infection by this parasite, proved to be immune to inoculation with the Rockefeller animal strain. Conversely, animals resistant to the animal strain were immune to infection by the human strain. After approximately 5 months of serial transfer of the infection in rabbits and mice, a total of some seventeen passages, material infected with the parasite of human origin was presented to Sabin (9), who, using somewhat different methods, has recently confirmed the authors' finding of a cross immunity in animals infected with the parasites of human and animal origin. From these facts it would appear that the microorganisms are closely related and perhaps even identical.

The collected evidence then clearly indicates that the parasite present in the lesions of the nervous system of the human infant is a *Toxoplasma*. It is proposed to name the microorganism *Toxoplasma hominis* with the reservation that it may later prove to be identical with one or all of the animal strains referred to in the literature. The disease occurring in man would then properly be designated toxoplasmic encephalomyelitis. It is possible that there may be other forms of human toxoplasmosis which have not as yet been recognized.

Remarks on Experimental Pathology.—There are interesting resemblances between the lesions experimentally produced by the human strain of *Toxoplasma*, and the pathological changes in the central nervous system of the infant from whom it was isolated. These resemblances apply equally to four other cases (2, 3, 10, 11) which have been demonstrated (1) to be instances of the same human disease.

The animals show focal leptomeningitis and localized inflammatory and necrotizing lesions in the parenchyma of the brain and spinal cord. The inflammation is round cell in type with the addition of neutrophils when necrosis is severe, and numerous plasma cells when the infection is of longer duration. Productive changes, leptomeningeal, vascular, and to a lesser extent glial, are present in most of the lesions. Miliary granulomas, so characteristic of the human disease, are relatively infrequent in the animals, but are morphologically similar. They more nearly resemble the granulomas of the human disease than do those seen in *Encephalitozoon* infection of the central nervous system of rabbits and mice. The granulomas of *Encephalitozoon* infection frequently become necrotic centrally, a feature rarely seen in the human disease or in the experimental disease produced by the same *Toxoplasma*. The ventricular walls and choroid plexuses are often involved. All of these changes occur not only in animals which are inoculated intracerebrally, in which they might be expected as a result of the spread of the infection by way of the cerebrospinal fluid pathways, but also appear in animals injected by various extracerebral routes, particularly the intraperitoneal. In a series of animals inoculated by a number of extracerebral routes nearly all showed moderate or marked involvement of the central nervous system. This conspicuous susceptibility of the central nervous system in the experimentally produced infection corresponds to its regular involvement in the human cases. Many other organs are affected in the animals, particularly the lungs, spleen, liver, heart, and suprarenals. Of the human cases only one (11) showed extraneural lesions, namely of the heart and striated muscles, but since the other organs were examined in only three of the five cases, and since extraneural lesions in the animals are less frequent than lesions in the nervous system, this difference between the human and the animal experimental disease is hardly significant. It may well be that future human cases will show lesions in organs other than the brain and spinal cord. Three of the patients with toxoplasmic encephalomyelitis had focal chorioretinitis. Such lesions were not found in the experimental animals. Rarely, the sheath of the optic nerve and surrounding periorbital fat showed inflammation and the presence of *Toxoplasma*, and in one instance the infiltration extended into the optic nerve.

The findings in the nervous system of the infant mice most nearly resemble those in the human infants. This is interesting not only because of the correspondence in age, but because the more subacute course of the infection in the infant mice, as compared to that in the adult animals, was

like the course in the human infants. Diffuse necrotizing inflammatory lesions of the cerebrum were more frequently seen in the infant mice. This was prominent among the pathological changes in the human infants. Intense calcification of such lesions was seen in many of the infant mice and occurred in two of the five human infants. It was not encountered in the adult animals. The finding of foci of calcification in the infant mice with little or no associated inflammation and no *Toxoplasmata*, may indicate that lesions in these animals can proceed to healing and calcification. It may be that abortive instances of the human disease characterized by focal calcification will be encountered. In a previous report (3) the authors reviewed a case (Brandt's) of an infant with extensive periventricular calcification in the brain and pointed out the possibility that it might have been a more chronic example of this disease, although no parasites were noted in the lesions. This supposition would seem to be strengthened by the occurrence of similar calcified lesions in the infant mice.

In animals inoculated intracerebrally dissemination of the infection in the central nervous system appears to be by way of the cerebrospinal fluid pathways. The parasites seem to enter the parenchyma directly from the leptomeninges or ventricular surfaces and by way of the perivascular spaces. From these spaces the parasites often spread radially or eccentrically into the surrounding parenchyma. They apparently reach other organs by way of the blood stream. They have been observed in the walls of cerebral vessels, and the distribution of the lesions in other organs suggests a vascular dissemination. No attempt has as yet been made to verify the presence of *Toxoplasma* in the blood of these animals by inoculating it into others, nor have the parasites been identified in blood smears. In animals inoculated by extracerebral routes spread by way of the blood stream seems apparent from the distribution of the lesions. In animals injected intraperitoneally a direct extension of the infection into the walls of the gastrointestinal tract has been noted occasionally and into the pancreas in one instance. After reaching the central nervous system through the blood stream the infection seems to spread secondarily by way of the cerebrospinal fluid from the leptomeninges, perivascular spaces, and ventricles. In the lungs there is rarely a bronchial spread from a vascular focus. From a comparison of the pathological findings in the central nervous system of the human infants with those in experimental animals it seems likely that although the infection may reach the brain by way of the blood stream, much of the further dissemination is by way of the cerebrospinal fluid spaces.

Experimental Transmission of Toxoplasmosis.—Toxoplasmosis occurring spontaneously in animals has frequently been transmitted experimentally (6, 8). The investigations described here demonstrate the occurrence of toxoplasmosis in man and constitute the first proved experimental transmission of human toxoplasmosis to animals. It is doubtful whether the experimental toxoplasmosis described by Bland (12, 13) in rabbits inoculated with the blood of patients suffering from glandular fever was an infection transmitted from human beings. In the first attempt only one rabbit was used and *Toxoplasma* was demonstrated only in the fourth serial passage from this animal. It would seem probable that what was being transmitted was a spontaneous rabbit toxoplasmosis which was perhaps activated by the inoculation of human blood. In a second attempt, three rabbits and three guinea pigs were inoculated and of these, only two rabbits developed toxoplasmosis. Again, because of the small number of animals used, one cannot rule out the possibility that a preexistent toxoplasmosis in the animals was activated. Toxoplasmata were not demonstrated microscopically in the human blood used to inoculate the animals and there was no opportunity to verify their presence in the patients' tissues, such as the enlarged glands. The blood from four other patients with glandular fever proved non-infective.

SUMMARY

1. Infected material from the brain and spinal cord of an infant suffering from a recently recognized form of granulomatous encephalomyelitis was inoculated into rabbits and mice and produced an experimental disease which was readily transmissible in series.
2. A parasite identical with that in the lesions of the human case was found in the lesions of the experimental animals.
3. The morphology of this microorganism, the course of the disease and the lesions produced in the animals inoculated with it, the wide host range of this parasite, and the results of cross immunity experiments, establish its identity as a *Toxoplasma*. It is suggested that the microorganism be designated *Toxoplasma hominis*.
4. The clinical and pathologic features of the infection produced in animals by this *Toxoplasma* are described.
5. The infection in the infant is the first proved instance of human toxoplasmosis. Since the lesions were confined to the central nervous system the disease is termed toxoplasmic encephalomyelitis.
6. The first experimental transmission of human toxoplasmosis to animals is recorded.

BIBLIOGRAPHY

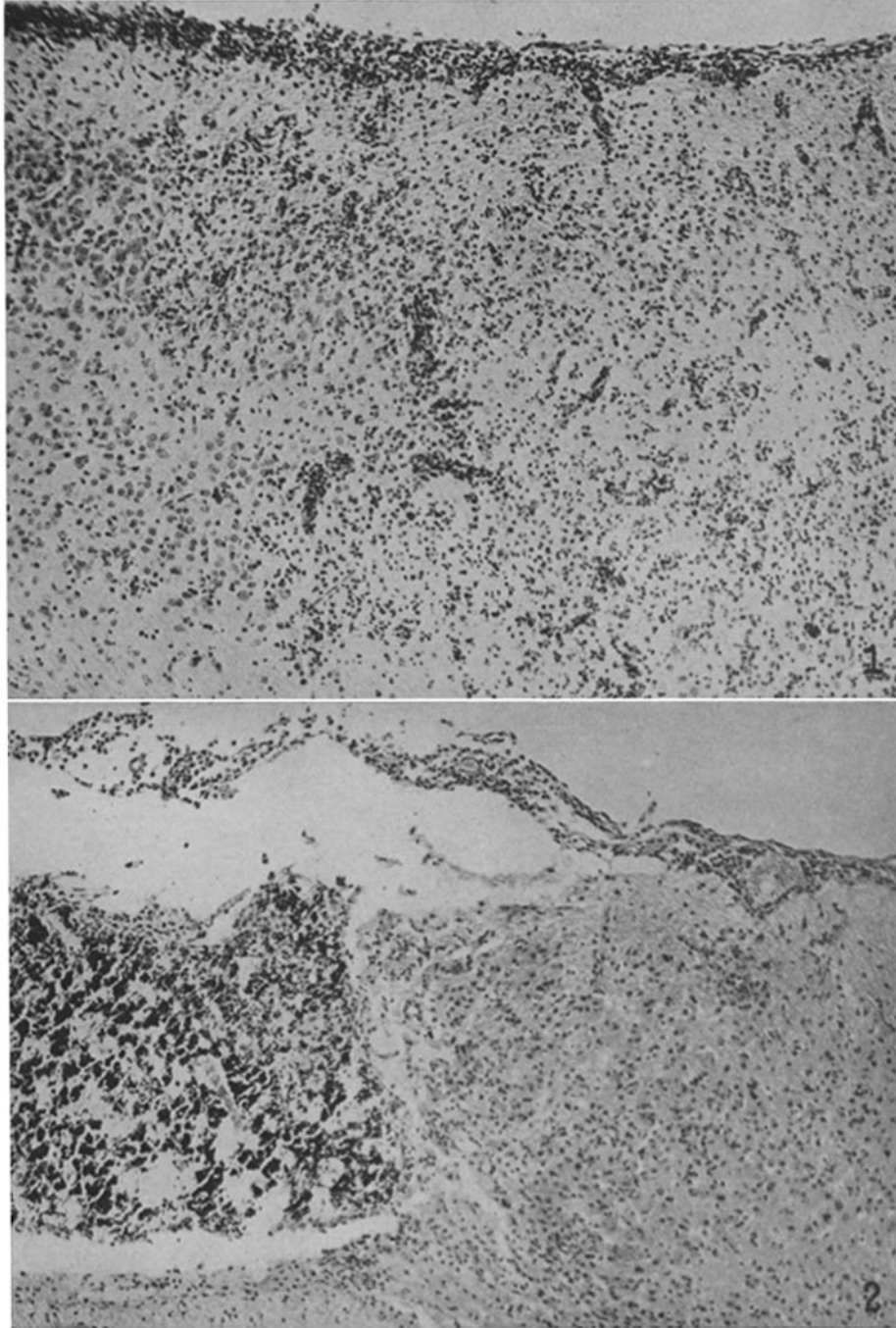
1. Wolf, A., Cowen, D., and Paige, B. H., *Am. J. Path.*, 1939, **15**, 657.
2. Wolf, A., and Cowen, D., *Bull. Neurol. Inst. New York*, 1937, **6**, 306.
3. Wolf, A., and Cowen, D., *Bull. Neurol. Inst. New York*, 1938, **7**, 266.
4. Wolf, A., Cowen, D., and Paige, B., *Science*, 1939, **89**, 226.
5. Sabin, A., and Olitsky, P. K., *Science*, 1937, **85**, 336.
6. Levaditi, C., Sanchis-Bayarri, V., Lepine, P., and Schoen, R., *Ann. Inst. Pasteur*, 1929, **43**, 673, 1063.
7. Nicolau, S., and Kopciowska, L., *Bull. Soc. path. exot.*, 1935, **28**, 490.
8. Chatton, E., and Blanc, G., *Arch. Inst. Pasteur Tunis*, 1917, **10**, 1.
9. Sabin, A., *Proc. Soc. Exp. Biol. and Med.*, 1939, **41**, 75.
10. Janků, J., *Casopis lekarew ceskyck*, 1923, **62**, 1021.
11. Torres, C. M., *Compt. rend. Soc. biol.*, 1927, **97**, 1778.
12. Bland, J. O. W., *Lancet*, 1930, **52**, 219.
13. Bland, J. O. W., *Brit. J. Exp. Path.*, 1931, **12**, 311.

EXPLANATION OF PLATES

PLATE 12

FIG. 1. Infant mouse. Diffuse cortical necrosis and inflammation and associated leptomeningitis. Hematoxylin-eosin stain. \times 140.

FIG. 2. Infant mouse. Intense calcification of degenerated cerebral cortex. Note focal inflammatory lesion in zonal cortical layer and adjacent leptomeningeal infiltration. Hematoxylin-eosin stain. \times 130.

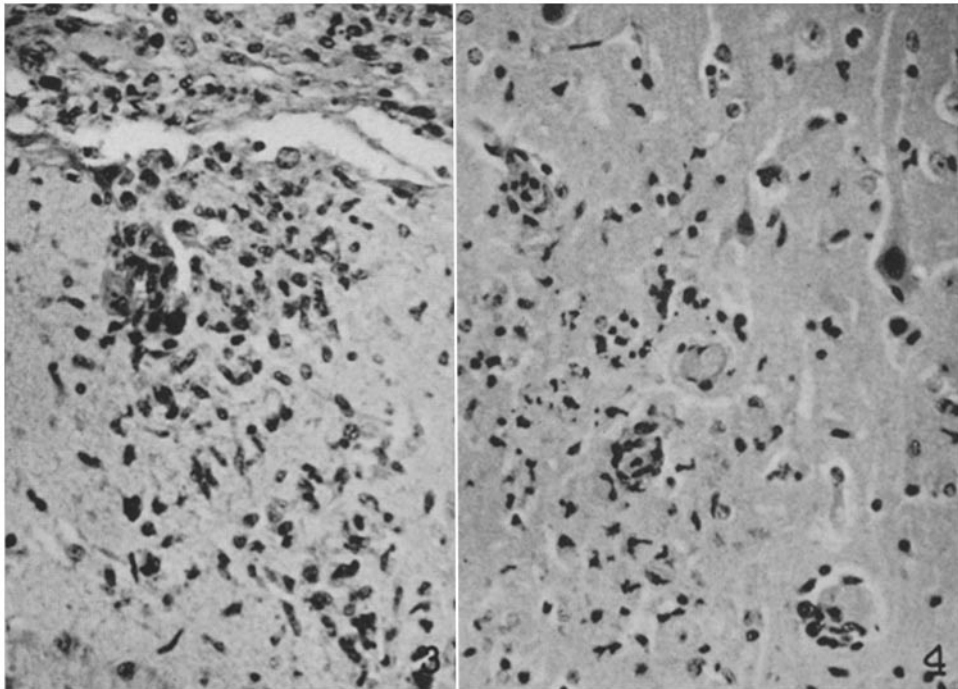


(Wolf *et al.*: Toxoplasmic encephalomyelitis. IV)

PLATE 13

FIG. 3. Rabbit. Focal inflammatory and productive lesion in zonal layer of cerebral cortex. Note proliferation of capillary endothelium, microglial hyperplasia, and diffuse lymphocytic infiltration. Hematoxylin-eosin stain. $\times 350$.

FIG. 4. Rabbit. Acute necrotizing focal lesion in cerebral cortex. Hematoxylin-eosin stain. $\times 300$.



(Wolf *et al.*: Toxoplasmic encephalomyelitis. IV)

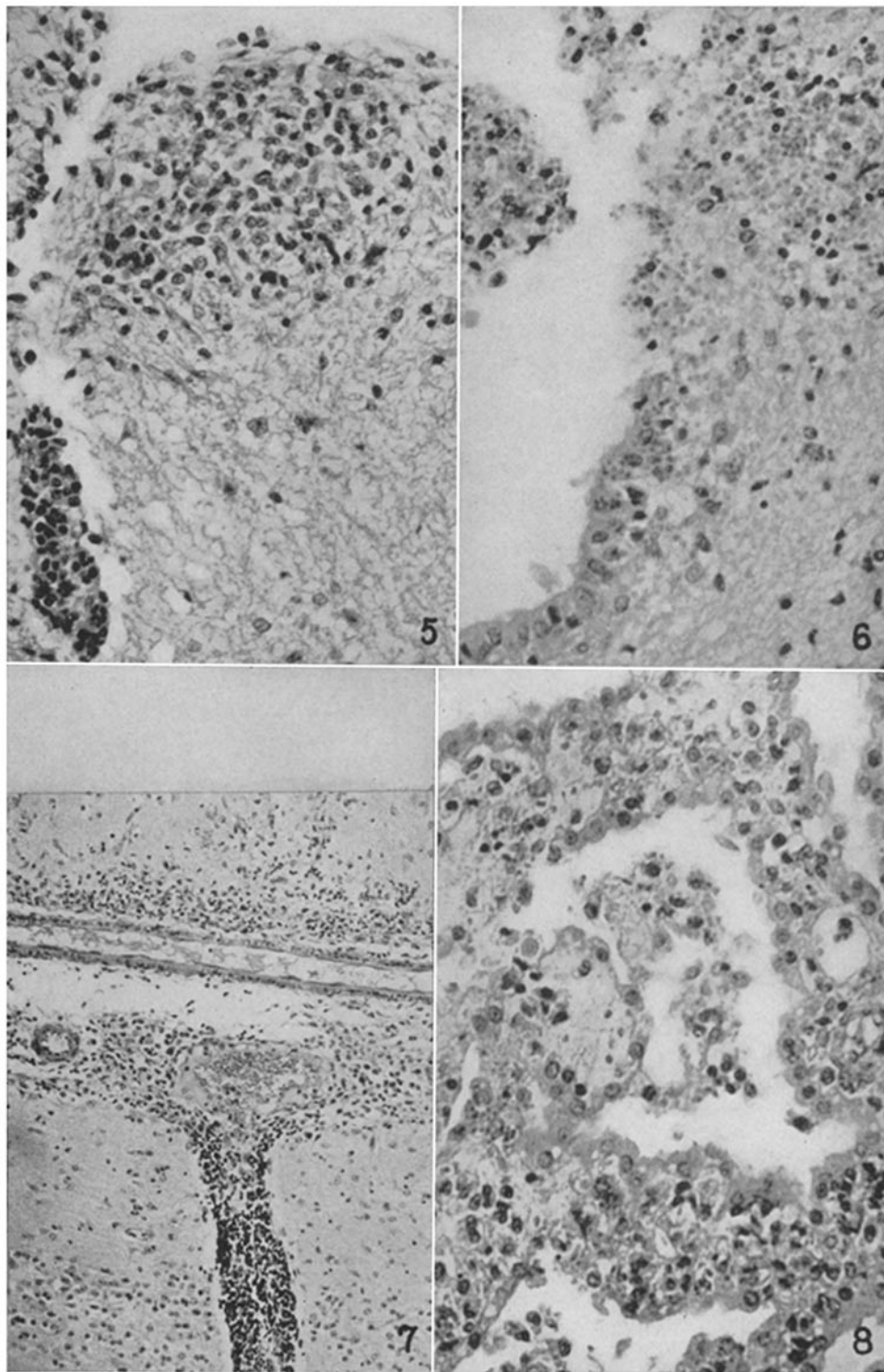
PLATE 14

FIG. 5. Rabbit. Granuloma in anterior white column of spinal cord with associated perivascular lymphocytic infiltration. Hematoxylin-eosin stain. $\times 300$.

FIG. 6. Rabbit. Necrosis and inflammation in wall of lateral ventricle. Note exudate in ventricular cavity, denudation of ependymal lining, and numerous parasites free and in some ependymal cells. Hematoxylin-eosin stain. $\times 350$.

FIG. 7. Rabbit. Leptomeningitis with perivascular extension and direct extension of the inflammation into the cortex. Hematoxylin-eosin stain. $\times 140$.

FIG. 8. Rabbit. Edematous choroid papillae in lateral ventricle showing cellular infiltration of connective tissue cores and desquamation of choroidal epithelium. Hematoxylin-eosin stain. $\times 350$.



(Wolf *et al.*: Toxoplasmic encephalomyelitis. IV)

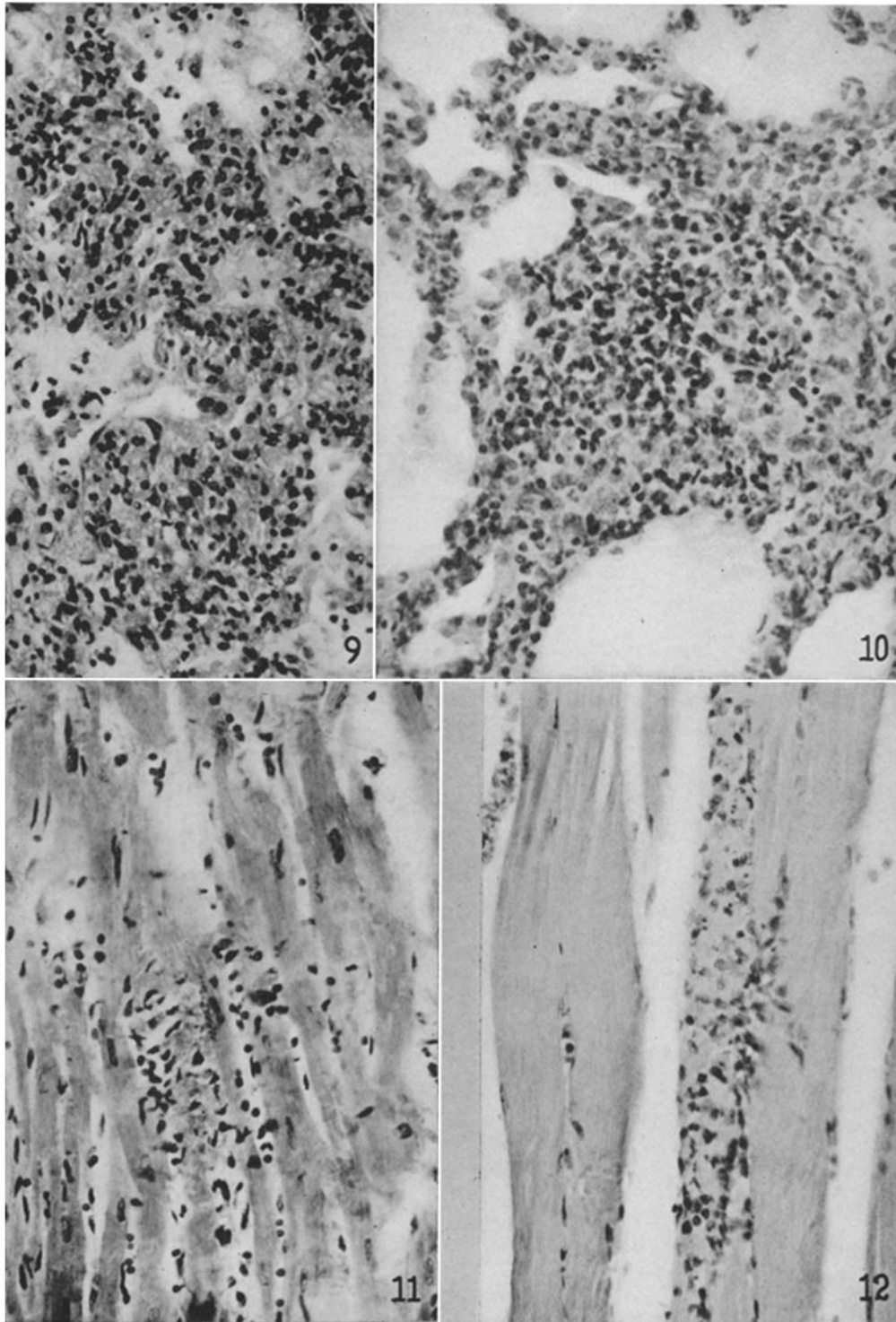
PLATE 15

FIG. 9. Rabbit. Lung: thickening of alveolar septa by cellular infiltration. Hematoxylin-eosin stain. $\times 300$.

FIG. 10. Rabbit. Lung: focal inflammatory lesion arising in alveolar septum and encroaching upon alveolar spaces. Mild infiltration of alveolar spaces. Hematoxylin-eosin stain. $\times 350$.

FIG. 11. Rabbit. Heart: focal myocarditis with degeneration of muscle fiber. Hematoxylin-eosin stain. $\times 300$.

FIG. 12. Mouse. Striated muscle: focal myositis with degeneration of muscle fiber. Hematoxylin-eosin stain. $\times 300$.



(Wolf *et al.*: Toxoplasmic encephalomyelitis. IV)

PLATE 16

FIG. 13. Rabbit. Liver: two localized inflammatory and necrotizing lesions. Hematoxylin-eosin stain. $\times 300$.

FIG. 14. Rabbit. Suprarenal: focal inflammatory lesion in cortex showing necrosis. Hematoxylin-eosin stain. $\times 300$.

FIG. 15. Parasites in paraffin sections of tissues fixed in formalin and Zenker's fluid, and in smears of peritoneal fluid. The sections are stained by hematoxylin-eosin. Magnification $\times 1050$, except *f*, which is $\times 600$. The smears are stained by the Wright-Giemsa method. Magnifications: *d*, $\times 1050$; *g*, *j*, *k*, $\times 350$.

(*a*) Mouse leptomeninges. Section. Free parasites in leptomeningeal exudate.

(*b*) Mouse leptomeninges. Section. Two parasitic cysts.

(*c*) Rabbit brain. Section. Intracellular and free parasites in degenerated cerebral cortex.

(*d*) Mouse peritoneal fluid. Smear. Parasites in large mononuclear cell. Note crescentic or fusiform shape. The lowermost parasite is dividing longitudinally.

(*e*) Rabbit brain. Section. Three parasites in a degenerating cell.

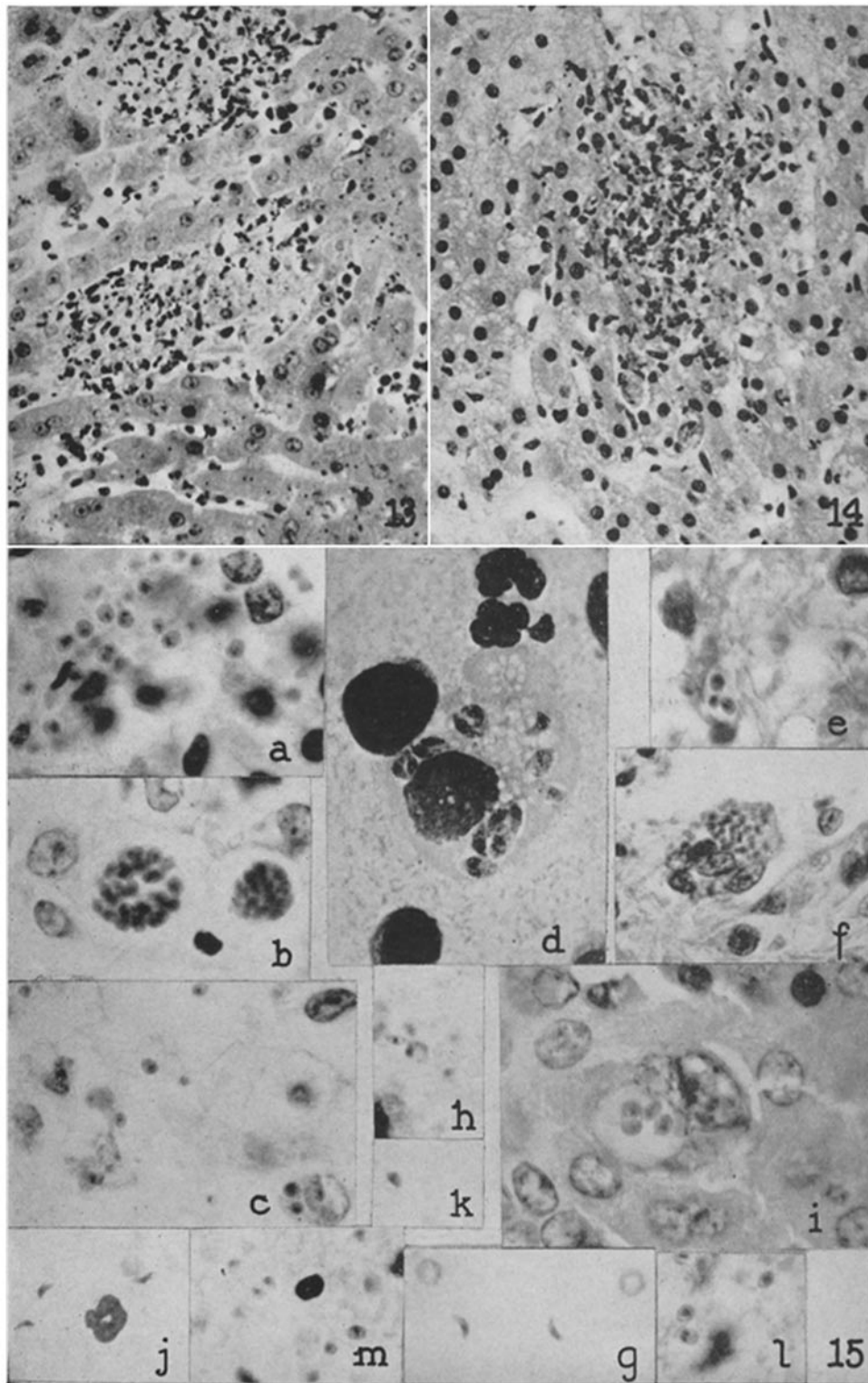
(*f*) Rabbit brain. Wall of lateral ventricle. Cluster of parasites in a swollen ependymal cell.

(*g*, *j*, and *k*) Mouse peritoneal fluid. Smear. Crescentically shaped parasites free in exudate. In *k* a parasite is dividing longitudinally.

(*h*) Rabbit brain. Section. Free parasites in degenerated cortex. One is slightly crescentic in shape.

(*i*) Mouse liver. Section. Four ovoid parasites in vacuole in hepatic cell.

(*l* and *m*) Rabbit brain. Section. Parasites in necrotic cerebral parenchyma. In *l* one microorganism is dividing longitudinally.



(Wolf *et al.*: Toxoplasmic encephalomyelitis. IV)