

Impact of a new dedicated sheath device for tissue sampling of biliary stricture on pathological diagnostic yield: Retrospective study



Authors

Fumitaka Niiya¹, Hirotoshi Ishiwatari¹, Keiko Sasaki², Kazuma Ishikawa³, Junya Sato¹, Yoshihiro Kishida¹, Kenichiro Imai¹, Kinichi Hotta¹, Hiroyuki Ono¹

Institutions

- 1 Division of Endoscopy, Shizuoka Cancer Center, Nagaizumi, Japan
- 2 Pathology, Shizuoka Cancer Center, Suntogun, Japan
- 3 Department of Medical Oncology, Sapporo Medical University, Sapporo, Japan

Keywords

Strictures, ERC topics, Pancreatobiliary (ERCP/PTCD), Diagnostic ERC

received 5.11.2023

accepted after revision 23.2.2024

accepted manuscript online 11.3.2024

Bibliography

Endosc Int Open 2024; 12: E561–E567

DOI 10.1055/a-2284-9622

ISSN 2364-3722

© 2024. The Author(s).

This is an open access article published by Thieme under the terms of the Creative Commons Attribution-NonDerivative-NonCommercial License, permitting copying and reproduction so long as the original work is given appropriate credit. Contents may not be used for commercial purposes, or adapted, remixed, transformed or built upon. (<https://creativecommons.org/licenses/by-nc-nd/4.0/>)

Georg Thieme Verlag KG, Rüdigerstraße 14,
70469 Stuttgart, Germany

Corresponding author

Hirotoshi Ishiwatari, Shizuoka Cancer Center, Division of Endoscopy, Nagaizumi, Japan
ishihiro481019@gmail.com

ABSTRACT

Background and study aims Endoscopic transpapillary biliary forceps biopsy (TBFB) is a common method for obtaining specimens from biliary lesions. Its diagnostic yield is unsatisfactory; to overcome this disadvantage, a dedicated sheath has been developed. This study aimed to evaluate the outcomes of conventional TBFB and TBFB with a novel sheath device.

Patients and methods Consecutive patients who underwent TBFB between January 2020 and December 2021 were retrospectively evaluated. The rate of obtaining adequate samples, failed attempts at forceps insertion into the bile duct, and sensitivity were compared between the two groups.


Results Ninety-two patients who underwent 115 endoscopic retrograde cholangiopancreatographies (76 in the conventional group vs. 39 in the dedicated sheath group) were included. The rates of obtaining adequate samples, failed attempts of the forceps into the bile duct, and sensitivity were 72.4% vs. 89.7% ($P=0.03$), 28.3% vs. 0% ($P<0.01$), and 66.7% vs. 88.9% ($P=0.02$), respectively.

Conclusions TBFB with the novel sheath device contributed to improved sensitivity for diagnosis of biliary stricture without insertion of forceps outside the bile duct.

Introduction

Pathological diagnosis plays an important role in determining the appropriate treatment strategy for patients with biliary strictures. However, establishing a definitive diagnosis is challenging. Endoscopic retrograde cholangiopancreatography (ERCP) is the most common technique used to obtain biliary tissue samples for pathological diagnosis [1]. Transpapillary biliary

forceps biopsy (TBFB) and brush cytology under fluoroscopy are conventional ERCP methods; however, their diagnostic yield is suboptimal, with a diagnostic sensitivity for malignancy of 33% to 88% and 18% to 80%, respectively [2, 3, 4, 5]. In addition, TBFB requires repeated insertion of biopsy forceps through the major duodenal papilla to achieve higher sensitivity [6, 7]. Careless handling of biliary forceps may cause injury to the major duodenal papilla or perforation of the bile duct be-



► **Fig. 1** Image of the novel delivery device. **a** The device has an inner catheter with a tapered tip (red arrowhead) and an outer sheath. There is almost no gap between the outer sheath and the inner catheter (blue arrow). **b** The inner catheter can be removed from the outer sheath. **c** The biopsy forceps (Radial Jaw 4) are inserted through the outer sheath.

cause the tip of the biopsy forceps is stiffer than that of the standard ERCP catheter. Moreover, frequent attempts to insert the device into the bile duct require additional time. These factors increase the risk of post-ERCP pancreatitis (PEP). PEP occurs in 3.5% to 9.7% of patients after ERCP; furthermore, in 0.1% to 0.7% of patients who develop PEP, it can be fatal [8, 9, 10]. Thus, an alternative tissue sampling method with a higher sensitivity and safer profile is required.

A TBFB method using an existing biliary stent delivery system or a biliary dilator has been reported [11]. Using these methods, adequate specimens can be obtained for pathological evaluation without leading to PEP [11]. However, these devices require modification by endoscopists for use in TBFB, which is a major disadvantage. Recently, a novel, dedicated sheath device for TBFB (Endosheather; Piolax, Kanagawa, Japan) was launched. It consisted of a tapered inner catheter and an outer sheath. After removing the inner catheter following the insertion of the device into the bile duct, biopsy forceps can be inserted into the targeted bile duct lesion through the outer sheath. A retrospective single-center study evaluated TBFBs using this novel delivery device in 14 patients and revealed high diagnostic yields of 90% and 92.3% in sensitivity and accuracy, respectively, making it a promising method for TBFB [12]. However, there have been no comparative studies of TBFB using this novel sheath device and conventional TBFB. Therefore, in this retrospective study, we compared these two techniques and evaluated the efficacy and safety of the delivery device.

Patients and methods

Study design

We retrospectively analyzed consecutive patients with suspected bile duct cancer who underwent TBFB using Radial Jaw 4 Pediatric Biopsy Forceps (Boston Scientific Japan, Tokyo, Japan) and FB-39Q-1 forceps (Olympus, Tokyo, Japan) at the Shizuoka Cancer Center Hospital between January 2020 and December 2021. More than 500 ERCP procedures are performed annually. During the study period, conventional TBFB or TBFB using a novel sheath device (Endosheather) was performed to obtain histological evidence of biliary stricture. Regarding the selection

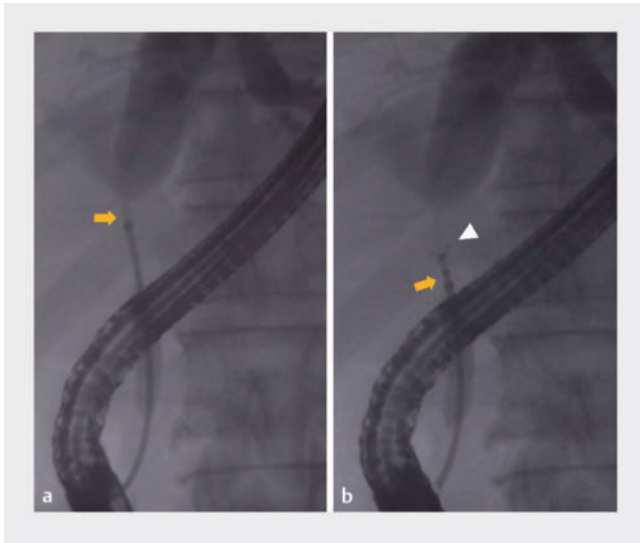
of TBFB methods, conventional TBFB was used until March 2021; thereafter, the novel sheath device was utilized. We excluded patients with surgically altered anatomy other than Billroth I reconstruction and with insufficient data. This study was approved by the Institutional Review Board (J2022-14) and performed in accordance with the principles of the Declaration of Helsinki.

A dedicated delivery system

The novel sheath device consists of a tapered inner catheter with a 1.13-mm tip diameter and a 2.44-mm outer sheath (7.2F) with a radiopaque marker (► **Fig. 1**). After inserting the device into the bile duct over the guidewire, biopsy forceps up to a diameter of 1.9 mm were inserted through the outer sheath following withdrawal of the inner catheter. In addition, this device is compatible with a 0.035-inch guidewire.

ERCP and TBFB

ERCP and TBFB were performed by three endoscopists: one with more than 10 years of experience and two with more than 5 years but less than 10 years of experience with ERCP. ERCP was performed using a side-viewing duodenoscope (TJF-Q290V, TJF-260V, or JF-260V; Olympus Medical Systems, Tokyo, Japan). After selective biliary cannulation using wire-guided cannulation, a 0.025-inch guidewire (VisiGlide2; Olympus Medical Systems, Tokyo, Japan) was inserted into the bile duct, and the biliary stricture was detected by cholangiography. Endoscopic sphincterotomy (EST) was performed when there were no contraindications or a history of EST. Regarding conventional TBFB, we generally used either of the two biopsy forceps (Radial Jaw 4 Pediatric Biopsy Forceps; 2.0 mm outer diameter, 5.4-mm opening width and effective length 160 cm, Boston Scientific Japan, or FB-39Q-1 forceps; 1.95-mm opening width, Olympus Medical Systems, Tokyo, Japan). When there was difficulty in inserting Radial Jaw 4 into the bile duct, FB-39Q-1 forceps were used instead because the latter has more flexibility. Biopsy forceps were inserted into the bile duct alongside the guidewire, and bile duct tissue was obtained from the biliary stricture. In principle, biopsies were performed at least three times. When using the novel sheath device, the delivery device was inserted into the biliary stricture over the guidewire,



► **Fig. 2** A cholangiogram image obtained using the novel delivery device. **a** The outer sheath tip is located above the bile duct stricture (yellow arrow) after removing the inner catheter. **b** Biopsy forceps (Radial Jaw 4) (white arrowhead) are inserted into the bile duct through the outer sheath to obtain the bile duct specimen.

and the inner catheter and guidewire were removed, leaving the outer sheath in place (► **Fig. 2a**). Thereafter, biopsy forceps (Radial Jaw 4 Pediatric Biopsy Forceps; 2.0-mm outer diameter, 5.4-mm opening width, and effective length 240 cm, Boston Scientific Japan, Tokyo, Japan) were inserted into the outer sheath, and bile duct tissue was obtained (► **Fig. 2b**). Five biopsies were performed because the insertion of biopsy forceps into the bile duct was easier compared with conventional TBFB. The selection of biliary drainage methods, such as endoscopic nasobiliary drainage and endoscopic biliary stenting, was performed depending on patient condition. A prophylactic pancreatic stent was inserted at endoscopist discretion. Diclofenac suppositories and ulinastatin were administered to prevent PEP when there were no contraindications. Fluoroscopic and endoscopic videos during ERCP were recorded for all patients.

Pathological assessment of the sample obtained by TBFB and final diagnosis

In the pathological reports, histological classifications were divided into five categories: inadequate, benign, atypical, suspicious for adenocarcinoma, and adenocarcinoma, which were performed by an experienced pathologist (KS). In this study, an adequate sample was defined as a specimen that included tumor cells or epithelial cells with stroma and diagnosed as a benign, atypical, suspicious, or typical adenocarcinoma. When they were classified as suspicious for adenocarcinoma or adenocarcinoma, the samples were categorized as positive for malignancy; however, samples that were considered benign or atypical were categorized as negative for malignancy. The final diagnosis was based on the surgical diagnosis of a resected specimen, positive for malignancy at TBFB diagnosis with a compatible clinical course of more than 6 months, or negative for ma-

lignancy at TBFB diagnosis with spontaneous resolution or a lack of deterioration on imaging findings for a clinical follow-up time of at least 6 months. An accurate diagnosis using TBFB was defined as positive for malignancy with a final diagnosis of malignant disease and negative for malignancy with a final diagnosis of benign disease.

Outcome measurements

We defined the conventional and Endosheather groups as patients who underwent TBFB using the conventional method and Endosheather, respectively. Patient data were collected from electronic medical records and endoscopy databases. We evaluated the sensitivity, specificity, positive predictive value (PPV), negative predictive value (NPV), and accuracy of TBFB for pathological diagnosis and compared the conventional and Endosheather methods. Furthermore, the rates of adequate sample collection, failed insertion of forceps into the bile duct per attempt, biopsy time per biopsy, biopsy time per ERCP, procedure time, and adverse events (AEs) were compared between the two groups. Regarding failed attempts of the forceps into the bile duct, defined as when the biopsy forceps were not inserted into the bile duct, two gastroenterologists (H.I. and F.N.; Japanese Gastroenterological Endoscopy Society board-certified members) reevaluated it by examining the video of ERCP for the study. When there was a discrepancy between opinions, a decision was made after a discussion between them. Biopsy time per ERCP was measured from the first attempt to insert the biopsy forceps to the end of the last biopsy. Biopsy time per biopsy was defined as biopsy time per ERCP divided by the total number of biopsies. Procedure time was measured from endoscope insertion to withdrawal. AEs were defined and graded according to the American Society for Gastrointestinal Endoscopy Severity Grading system [13].

Statistical analyses

Continuous variables were presented as medians and interquartile ranges and were compared using the Mann-Whitney U-test. Categorical variables were shown as proportions and were compared using Fisher's exact test. Sensitivity, specificity, PPV, NPV, and accuracy were compared using the χ^2 test and Fisher's exact test, where appropriate. $P < 0.05$ was considered to be statistically significant. All analyses were performed using R version 3.4.1 (The R Foundation for Statistical Computing, Vienna, Austria).

Results

Patient characteristics

During the study period, 122 ERCP cases with suspected bile duct cancer underwent TBFB. After excluding seven ERCP cases (surgically altered anatomy, $n = 3$; insufficient data, $n = 4$), 115 ERCP procedures were analyzed in this study (Conventional group, $n = 76$; Endosheather group, $n = 39$). Patient characteristics are shown in ► **Table 1**. No significant differences were observed between the two groups.

► **Table 1** Patient characteristics.

Measure	Conventional n = 76	Endosheather n = 39	P value
Age, years, median (IQR)	71 (65–77)	72 (65.8–77)	0.25
Location of biliary stricture, n (%)			
▪ Hilar	54 (71.1)	26 (66.7)	0.67
▪ Distal	22 (28.9)	13 (33.3)	
Length of biliary stricture, mm, median (IQR)	16 (12–22)	16.5 (10–22.8)	0.43
Cannulation time, min, (median [IQR])	1.25 (0.3–4)	1 (0.5–2.5)	0.08
Naïve major duodenal papilla, n (%)	45 (59.2)	20 (51.3)	0.43
EST history	28 (36.8)	10 (25.6)	0.30
ERCP-related procedure, n (%)			
▪ PGW-assisted biliary cannulation	13 (17.1)	3 (7.7)	0.28
▪ Precutting	2 (2.6)	0 (0)	0.55
▪ EST	48 (63.2)	29 (74.4)	0.30
▪ Biliary drainage tube or stent			0.24
– Plastic stent	21 (27.6)	16 (41)	
– Metallic stent	4 (5.3)	0 (0)	
– ENBD	45 (59.2)	22 (56.4)	
– None	6 (7.9)	1 (2.6)	
Pancreatic stent placement for the prevention of PEP	4 (5.3)	1 (2.6)	0.66
Final diagnosis, n (%)			
▪ Malignant	63 (82.9)	36 (92.3)	0.26
– Bile duct cancer	55 (72.4)	33 (84.6)	
– Gallbladder cancer	8 (10.5)	3 (7.7)	
▪ Benign disease	13 (17.1)	3 (7.7)	
Surgery	23 (30.3)	16 (41)	0.34

ERCP, endoscopic retrograde cholangiopancreatography; EST, endoscopic sphincterotomy; PGW, pancreatic guidewire; ENBD, endoscopic nasobiliary drainage; PEP, post-ERCP pancreatitis; IQR, interquartile range.

Procedure outcomes of bile duct biopsy

The median number of biopsies was three and five in the conventional and Endosheather groups, respectively ($P < 0.001$) (► **Table 2**). Rates of failed insertion of the forceps into the bile duct per attempt were 28.3% (95/336) and 0% in the conventional and Endosheather groups, respectively ($P < 0.01$). Biopsy times per ERCP were 220 and 296.5 sec in the conventional and Endosheather groups ($P = 0.56$), respectively, whereas biopsy time per biopsy of the conventional group was significantly longer than that of the Endosheather group (68.3 vs. 54 sec, $P = 0.03$).

Diagnostic yields of biliary forceps biopsy

Diagnostic yields of biliary forceps biopsies are summarized in ► **Table 3**. The rate of obtaining adequate samples was significantly lower in the conventional group than in the Endosheather group (72.4% [55/76] vs. 89.7% [35/39], $P = 0.03$). Sensitivity of the conventional group was significantly lower than that of the Endosheather group (66.7% vs. 88.9%, $P = 0.02$). There were no differences observed in specificity, PPV, NPV, or accuracy between the two groups.

Adverse events

Procedure-related AEs are summarized in ► **Table 4**. Pancreatitis and cholangitis occurred in 3.9% and 1.3% of patients in the conventional group, respectively; however, these events did not occur in the Endosheather group.

► **Table 2** Study outcomes of TBFB.

Measure	Conventional n = 76	Endosheather n = 39	P value
Type of forceps for TBFB, n			
▪ FB-39Q-1	25 (32.9)	0 (0)	< 0.01
▪ Radial Jaw 4	51 (67.1)	39 (100)	
Number of biopsies, n			
▪ Median	3	5	< 0.01
▪ IQR	3–3	3–5	
▪ Range	1–6	2–10	
Total number of biopsies, n	241	225	
Total number of attempts for insertion of forceps into the bile duct, n	336	225	
Total failed attempts of the forceps into the bile duct, n	95	0	
Rate of failed attempts of the forceps into the bile duct, % (n/N)	28.3 (95/336)	0 (0/225)	< 0.01
Biopsy time per one biopsy, sec median (IQR)	68.3 (53.4–103)	54 (42–69.6)	0.03
Biopsy time per ERCP, sec, median (IQR)	220 (160–330)	296.5 (218.5–375)	0.56
Procedure time, min, median (IQR)	25 (19–37.5)	24 (19–33)	0.7
TBFB, transpapillary biliary forceps biopsy; ERCP, endoscopic retrograde cholangiopancreatography; IQR, interquartile range.			

Discussion

In this study, we compared outcomes of conventional TBFB with those of TBFB using a novel sheath device. TBFB with a novel sheath device exhibited higher sensitivity than conventional TBFB.

A retrospective study evaluating TBFB with a pusher tube of an existing biliary stent delivery system revealed that the rate of obtaining samples, including submucosal tissue, was 91.4%, whereas another retrospective study using a biliary dilation catheter demonstrated that sensitivity, specificity, and accuracy were 87.5%, 100%, and 93.7%, respectively [14, 15]. Furthermore, a retrospective, single-arm study evaluating the same sheath device used in our study revealed high diagnostic yields (sensitivity, 90%; specificity, 100%; and accuracy, 92.3%). Our study also demonstrated satisfactory diagnostic ability of the novel sheath device, in line with previous studies. In addition, we compared results with those of the conventional TBFB, and no study has compared these two methods. A significantly higher rate of adequate sampling and higher sensitivity were observed when using the novel sheath device.

Insertion of biopsy forceps into the bile duct can be challenging. However, using the novel sheath device, biopsy forceps can be inserted easily into the bile duct, and once inserted, it can be repeated, in line with our study. This resulted in a shorter biopsy time per biopsy and a lower rate of failed insertion of the forceps into the bile duct in the Endosheather group. We presumed that reducing the number of failed insertions of forceps into the bile duct shortened the time required for biopsy.

Although there was no significant difference in the rate of AEs, pancreatitis was observed only in the conventional group. We speculated that the small sample size was the reason for the lack of statistical difference. However, considering the reduction in failed insertion of forceps into the bile duct, it is intuitively understandable that risk of pancreatitis was reduced. We presumed that the favorable outcome resulted from the ability to obtain tissue from the same lesion repeatedly and effortlessly through the outer sheath. In recent years, precision medicine has become increasingly important in bile duct cancer, and it is necessary to obtain a larger sample size for comprehensive genome profiling using next-generation sequencing [16]. Because increasing the number of biopsies is desirable to increase the amount of tissue obtained, TBFB using the novel sheath device can also be a promising technique to safely perform TBFB in a shorter time for comprehensive genome profiling.

Nonetheless, this study has some limitations. First, some bias was inevitable owing to its retrospective nature. However, enrolling consecutive patients and the choice of two methods (conventional TBFB and TBFB using Endosheather), which were performed at different times, probably reduced selection bias. Second, the number of biopsies performed differed between the two groups. For conventional TBFB, to consider the balance of diagnostic yield and safety, we decided that the number of biopsies was set to at least three, although we knew that five or more biopsies were reported to be an independent predictive factor for a positive cancer diagnosis of malignant biliary stricture in a retrospective study [17]. Therefore, if more biopsies had been performed, the conventional method might have had higher sensitivity. However, this may also lead to a higher

► **Table 3** Diagnostic yield of TFBF.

Conventional n = 76				Endosheather n = 39			
		Final diagnosis				Final diagnosis	
		Malignant	Benign			Malignant	Benign
TFBF diagnosis	Malignant	42	0	TFBF diagnosis	Malignant	32	0
	Benign	1	12		Benign	1	2
	Inadequate	20	1		Inadequate	3	1
Measure						P value	
Sensitivity %, (n/N)		66.7 (42/63)		88.9 (32/36)		0.02	
▪ (95% CI)		53.7–78		73.9–96.9			
Hilar		70 (31/47)		87 (20/23)		0.08	
Distal		68.8 (11/16)		92.3 (12/13)		0.18	
Specificity %, (n/N)		92.3 (12/13)		66.7 (2/3)		0.35	
▪ (95% CI)		64–99.8		9.4–99.2			
Hilar		100 (5/5)		66.7 (2/3)		0.38	
Distal		87.5 (7/8)		0		NS	
PPV %, (n/N)		100% (42/42)		100 (32/32)		NS	
▪ (95% CI)		91.6–100		89.1–100			
Hilar		100 (31/31)		100 (20/20)		NS	
Distal		100 (11/11)		100 (12/12)		NS	
NPV %, (n/N)		92.3 (12/13)		66.7 (2/3)		0.35	
▪ (95% CI)		64–99.8		9.4–99.2			
Hilar		83.3 (5/6)		66.7 (2/3)		1	
Distal		100 (7/7)		0		NS	
Accuracy %, (n/N)		71.1 (54/76)		87.2 (34/39)		0.06	
▪ (95% CI)		59.5–80.9		72.6–95.7			
Hilar		69.2 (36/52)		84.6 (22/26)		0.18	
Distal		75 (18/24)		92.3 (12/13)		0.39	

TFBF, transpapillary biliary forceps biopsy; CI, confidence interval; PPV, positive predictive value; NPV, negative predictive value; NS, not significant.

► **Table 4** Adverse events.

Measure	Conventional n = 76	Endosheather n = 39	P value
Overall, n (%)	4 (5.2)	0 (0)	0.30
Pancreatitis, n (%)	3 (3.9)	0 (0)	0.55
Cholangitis, n (%)	1 (1.3)	0 (0)	1.00
Bleeding, n (%)	0 (0)	0 (0)	NS
Perforation, n (%)	0 (0)	0 (0)	NS

NS, not significant.

incidence of pancreatitis. Whether our approach can be adopted as a conventional method in all facilities remains unclear, but we believe that there are not many institutions where biopsy forceps are consistently inserted into the bile duct for tissue acquisition, five times in every procedure. In that regard, this conventional method might be more realistic. Third, this was a single-center study with a small sample size; thus, a multicenter study with a larger sample size is required to confirm our results.

Conclusions

In conclusion, TBFB using a novel dedicated sheath device had a higher diagnostic yield without failed insertion into the bile duct than conventional TBFB. This novel sheath device can also facilitate TBFB and produce higher sensitivity.

Conflict of Interest

The authors declare that they have no conflict of interest.

References

- [1] Rustgi AK, Kelsey PB, Guelrud M et al. Malignant tumors of the bile ducts: diagnosis by biopsy during endoscopic cannulation. *Gastrointest Endosc* 1989; 35: 248–251
- [2] De Bellis M, Sherman S, Fogel EL et al. Tissue sampling at ERCP in suspected malignant biliary strictures (Part 1). *Gastrointest Endosc* 2002; 56: 552–561 doi:10.1067/mge.2002.129219
- [3] Burnett AS, Calvert TJ, Chokshi RJ. Sensitivity of endoscopic retrograde cholangiopancreatography standard cytology: 10-y review of the literature. *J Surg Res* 2013; 184: 304–311 doi:10.1016/j.jss.2013.06.028
- [4] Nanda A, Brown JM, Berger SH et al. Triple modality testing by endoscopic retrograde cholangiopancreatography for the diagnosis of cholangiocarcinoma. *Ther Adv Gastroenterol* 2015; 8: 56–65 doi:10.1177/1756283X14564674
- [5] Navaneethan U, Njei B, Lourdasamy V et al. Comparative effectiveness of biliary brush cytology and intraductal biopsy for detection of malignant biliary strictures: a systematic review and meta-analysis. *Gastrointest Endosc* 2015; 81: 168–176 doi:10.1016/j.gie.2014.09.017
- [6] Kawashima H, Itoh A, Ohno E et al. Transpapillary biliary forceps biopsy to distinguish benign biliary stricture from malignancy: how many tissue samples should be obtained? *Dig Endosc* 2012; 24: 22–27
- [7] Ikeda M, Maetani I, Terada K et al. Usefulness of endoscopic retrograde biliary biopsy using large-capacity forceps for extrahepatic biliary strictures: a prospective randomized study. *Endoscopy* 2010; 42: 837–841 doi:10.1055/s-0030-1255633
- [8] ASGE Standards of Practice Committee, Chandrasekhara V, Khashab MA et al. Adverse events associated with ERCP. *Gastrointest Endosc* 2017; 85: 32–47
- [9] ASGE Standards of Practice Committee, Anderson MA, Fisher L et al. Complications of ERCP. *Gastrointest Endosc* 2012; 75: 467–473
- [10] Dumonceau JM, Kapral C, Aabakken L et al. ERCP-related adverse events: European Society of Gastrointestinal Endoscopy (ESGE) guideline. *Endoscopy* 2020; 52: 127–149 doi:10.1055/a-1075-4080
- [11] Hijioka S, Hara K, Mizuno N et al. A novel technique for endoscopic transpapillary “mapping biopsy specimens” of superficial intraductal spread of bile duct carcinoma (with videos). *Gastrointest Endosc* 2014; 79: 1020–1025
- [12] Matsumori T, Uza N, Shiokawa M et al. Clinical impact of a novel device delivery system in the diagnosis of bile duct lesions: A single-center experience. *J Gastroenterol Hepatol* 2022; 37: 1360–1366 doi:10.1111/jgh.15866
- [13] Cotton PB, Eisen GM, Aabakken L et al. A lexicon for endoscopic adverse events: report of an ASGE workshop. *Gastrointest Endosc* 2010; 71: 446–454 doi:10.1016/j.gie.2009.10.027
- [14] Okada H, Uza N, Matsumori T et al. A novel technique for mapping biopsy of bile duct cancer. *Endoscopy* 2021; 53: 647–651 doi:10.1055/a-1248-2138
- [15] Ko SW, Lee SS, So H et al. A novel method of biopsy for indeterminate pancreaticobiliary strictures: tube-assisted biopsy. *Endoscopy* 2020; 52: 589–594 doi:10.1055/a-1127-3265
- [16] Verlingue L, Malka D, Allorant A et al. Precision medicine for patients with advanced biliary tract cancers: an effective strategy within the prospective MOSCATO-01 trial. *Eur J Cancer* 2017; 87: 122–130
- [17] Yang MJ, Hwang JC, Lee D et al. Factors affecting the diagnostic yield of endoscopic transpapillary forceps biopsy in patients with malignant biliary strictures. *J Gastroenterol Hepatol* 2021; 36: 2324–2328