

## Reverse V-Shape Kinking of the Left Lower Lobar Bronchus after a Left Upper Lobectomy and Its Surgical Correction

Min-Seok Kim, M.D., Yoohwa Hwang, M.D., Hye-seon Kim, M.D., In Kyu Park, M.D.,  
Chang Hyun Kang, M.D., Young Tae Kim, M.D.

A 76-year-old male underwent a left upper lobectomy with wedge resection of the superior segment of the left lower lobe using video-assisted thoracoscopic surgery (VATS) for non-small-cell lung cancer of the left upper lobe. He presented with shortness of breath, fever, and leukocytosis. Chest radiography showed atelectasis at the remaining left lower lobe. Bronchoscopy revealed narrowing of the left lower bronchus with purulent secretion, and computed tomography showed downward kinking of the left lower lobar bronchus. He underwent exploratory VATS, and intraoperative findings showed an inferiorly kinked left lower lobar bronchus with upward displacement of the left lower lobe. After adhesiolysis, the kinked bronchus was straightened, and bronchopexy was performed to the pericardium to prevent the recurrence of bronchial kinking. Also, the inferior pulmonary ligament was reattached to prevent upward displacement. Postoperative follow-up bronchoscopy revealed no evidence of residual bronchial obstruction, and chest radiography showed no atelectasis thereafter.

Key words: 1. Airway obstruction  
2. Video-assisted thoracic surgery (VATS)  
3. Complications of surgery

### CASE REPORT

A 76-year-old male underwent a left upper lobectomy with en bloc wedge resection of the superior segment of the left lower lobe using video-assisted thoracoscopic surgery (VATS) for non-small-cell lung cancer of the left upper lobe. Systematic dissection of the pulmonary and mediastinal lymph nodes was performed. The operation and immediate postoperative course were uneventful. The patient presented poor bronchial toileting and required supplementary oxygen. Chest radiography on the second postoperative day revealed atelectasis at the remaining left lower lobe, which was not resolved despite vigorous chest physiotherapy (Fig. 1A). The

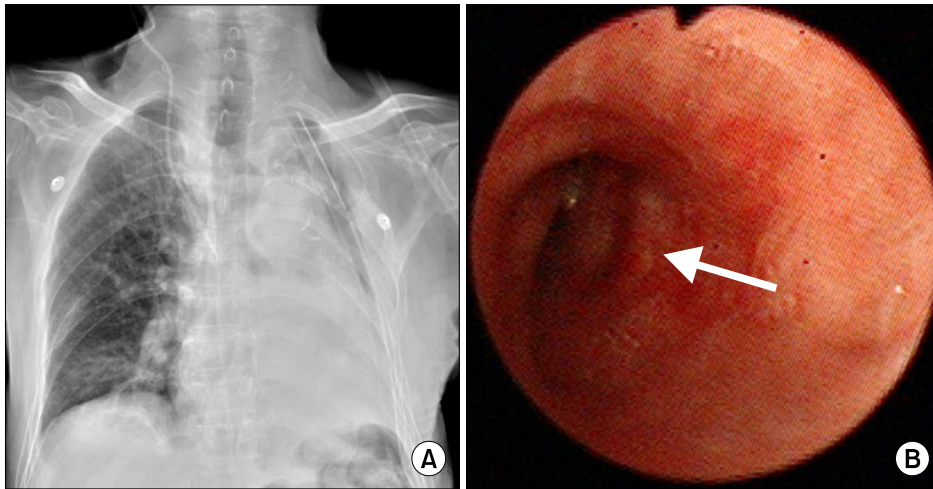
patient had a mild fever and leukocytosis. In addition, a high-sensitivity C-reactive protein (CRP) test revealed an elevated CRP level. Fiberoptic bronchoscopy on the fourth postoperative day revealed narrowing of the left lower bronchus with purulent secretion (Fig. 1B). Computed tomography showed an obstruction of the left lower lobar bronchus associated with acute angulation at the distal main bronchus. The left lower lobar artery showed right-angle angulation, and the left inferior pulmonary vein was stretched upward (Fig. 2). Perfusion to the pulmonary parenchyma was intact. The patient underwent exploratory VATS under the impression of bronchial kinking. The intraoperative findings showed an inferiorly kinked left lower lobar bronchus accompanied by an

Department of Thoracic and Cardiovascular Surgery, Seoul National University Hospital, Seoul National University College of Medicine  
Received: January 3, 2014, Revised: February 6, 2014, Accepted: February 10, 2014, Published online: October 5, 2014

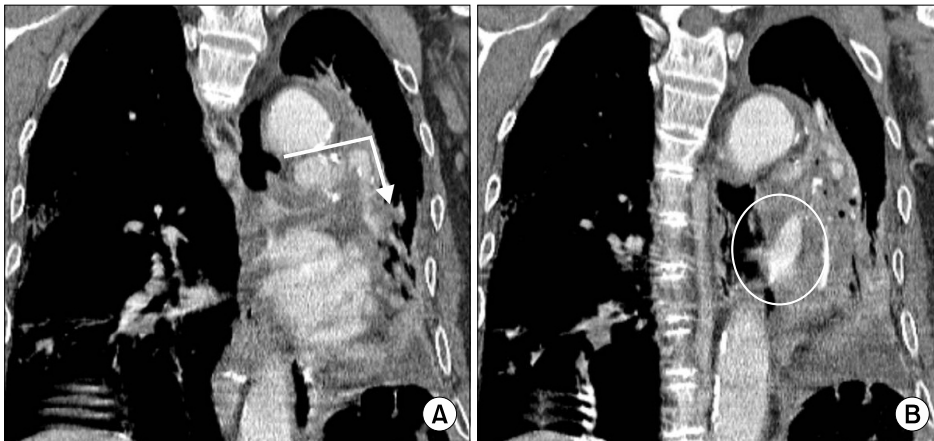Corresponding author: In Kyu Park, Department of Thoracic and Cardiovascular Surgery, Seoul National University Hospital, Seoul National University College of Medicine, 101 Daehak-ro, Jongno-gu, Seoul 110-744, Korea  
(Tel) 82-2-2072-2342 (Fax) 82-2-764-3664 (E-mail) [ikpark@snu.ac.kr](mailto:ikpark@snu.ac.kr)

© The Korean Society for Thoracic and Cardiovascular Surgery. 2014. All right reserved.

© This is an open access article distributed under the terms of the Creative Commons Attribution Non-Commercial License (<http://creativecommons.org/licenses/by-nc/3.0>) which permits unrestricted non-commercial use, distribution, and reproduction in any medium, provided the original work is properly cited.



**Fig. 1.** (A) Chest radiography of the patient on the second postoperative day revealed atelectasis of the remaining left lower lobe. (B) Fiberoptic bronchoscopy on the fourth postoperative day revealed a narrowing of the left lower bronchus with purulent secretion.



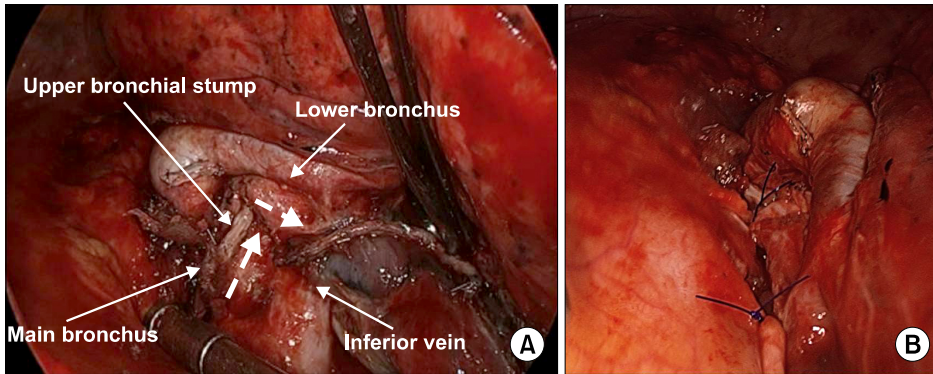
**Fig. 2.** Chest computed tomography on the fourth postoperative day revealed an obstruction of the left main bronchus. (A) Left lower lobar artery was angulated downward, and (B) left inferior pulmonary vein was stretched upward.

excessively upwardly displaced left lower lobe (Fig. 3A). The left lower lobe was consolidated without congestion. After adhesiolysis, the kinked bronchus was straightened. There was no malacia at the kinked portion of the bronchus. In addition, there was no supportive structure around the main bronchus and lower lobar bronchus due to extensive lymph node dissection. Thus, bronchopexy was performed to the pericardium with two interrupted monofilament sutures to prevent recurrence of bronchial kinking (Fig. 3B). The inferior pulmonary ligament was reattached to prevent excessive upward displacement. Postoperative follow-up bronchoscopy revealed an elliptical bronchial lumen without obstruction, and chest radiography showed no atelectasis of the left lung thereafter. However, pneumonia developed in the contralateral lung. The patient underwent a mechanical ventilation treatment for 1

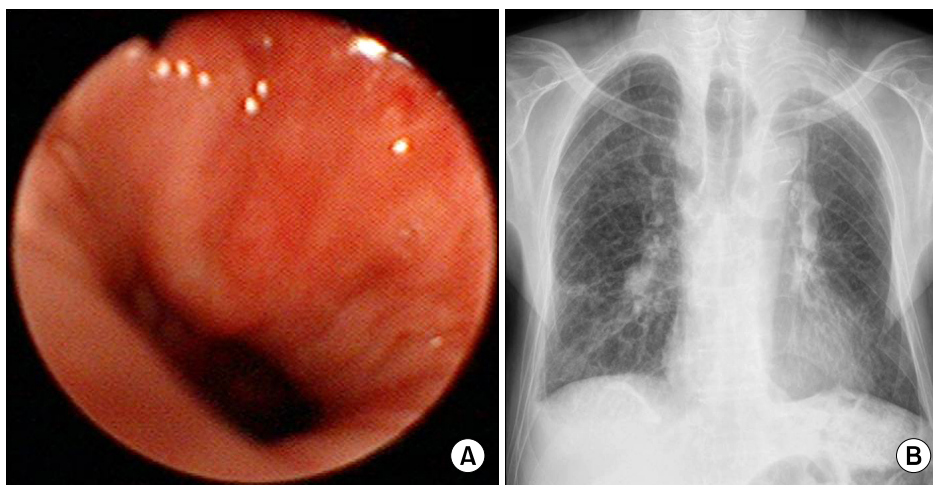
month and was discharged on the 80th postoperative day with a tracheostomy. The tracheostomy tube was removed at an outpatient clinic 2 months after discharge. Chest radiography revealed no specific findings (Fig. 4).

## DISCUSSION

Bronchial kinking after an upper lobectomy has rarely been reported and has not been well described because of the difficulty of diagnosis [1]. However, it was recently reported that bronchial kinking occasionally develops after an upper lobectomy and subsequently exacerbates shortness of breath [1]. Bronchial kinking is commonly caused by the upward displacement of the remaining lower lobe and can be diagnosed by computed tomography [1,2]. Usually, bronchial kinking af-



**Fig. 3.** (A) Thoracoscopic findings showed reverse V-shape kinking of the left lower lobar bronchus without pulmonary congestion. (B) To prevent recurrent bronchial kinking, bronchopexy was performed to the pericardium.



**Fig. 4.** (A) Postoperative follow-up bronchoscopy revealed an elliptical bronchial lumen without obstruction, and (B) chest radiography taken 7 months after the surgery showed patent left bronchus and full expanded left lung.

ter an upper lobectomy is a chronic manifestation and has an upward V-shape. In the present case, however, the patient showed an acute course and downward bronchial kinking (reverse V-shape). Bronchial kinking caused by a downward kink of the left lobar bronchus after a left upper lobectomy has not been reported thus far. Three predisposing factors can be suggested as causes of reverse V-shaped kinking. The first potential cause is an extensive dissection of lymph nodes around the lower lobar bronchus and the inferior pulmonary vein, which results in a skeletonized long segment of the bronchus. In such circumstances, the bronchus would be more susceptible to kinking because of the lack of supporting and anchoring structures. The second possibility is the wedge resection of the superior segment and the displacement of the left lower lobar bronchus. As the hilum of the lower lobe ascends excessively and nears the main hilum, the excessively long bronchus can become folded due to a pushing force. In

the present case, the left lower lobar bronchus ascended higher than the left upper bronchial stump, while the remaining left lower lobe rotated counterclockwise. This condition might have exacerbated the upward displacement of the remaining lung after wedge resection. In addition, the right-angled upper lobar stump against the main and lower lobar bronchus might have facilitated the kinking. The third possibility is the detachment of the inferior pulmonary ligament. If the ligament is not detached, excessive upward displacement of the lower lobe can be prevented.

Shortness of breath, leukocytosis, and elevated inflammatory markers may trigger a suspicion of bronchial kinking. However, it is difficult to differentiate bronchial obstruction from pneumonia on the basis of clinical symptoms and signs; therefore, it is essential to diagnose bronchial obstruction by bronchoscopy. Computed tomography is helpful for the differentiation of bronchial kinking from lung torsion in a patient

with bronchial obstruction. The final diagnosis can be made during the operation by an inspection of the lung parenchyma. In a patient with severe congestion or definitive gangrene, treatment should be directed to the treatment of lung torsion. Early diagnosis is the most important for the treatment of bronchial kinking or lung torsion. Thus, bronchoscopy should be performed as soon as possible, whenever there are clinical signs of bronchial obstruction to rule out bronchial kinking or lung torsion.

Bronchial obstruction due to bronchial kinking can be treated with a stent [3]. Intrabronchial stent insertion might be simpler than surgical correction. However, more serious complications such as bronchial wall perforation, stent migration, granuloma formation, and bacterial colonization may occur [4]. Surgical correction is the definitive treatment, and surgical diagnosis is one of the important roles of surgery. When obstructive pneumonia is combined, protection of the contralateral lung while positioning the patient in a lateral decubitus position is warranted during surgery.

In the present case, we decided on VATS exploration and surgical correction because an intraoperative diagnosis of congestion or gangrene formation was necessary. Repositioning of the lower lobe was necessary and effective in relieving bronchial kinking. By repositioning, we could also restore the pulmonary artery and vein to a more neutral position. Bronchopexy was also effective in maintaining a normal shape of the bronchus after resolving the kinking. Reatta-

chment of the pulmonary ligament was done to prevent excessive displacement of the lower lobe. To prevent bronchial kinking during the initial operation, reattachment of the pulmonary ligament after pulmonary ligament lymph node dissection would be helpful. Less extensive dissection of lymph nodes around the lower lobar bronchus may prevent acute reverse V-shaped bronchial kinking.

In conclusion, given that bronchial kinking can occur after an upper lobectomy, bronchial kinking should be one of the differential diagnoses in patients with signs of bronchial obstruction. Further, surgical exploration and correction should be considered in patients with bronchial kinking.

#### CONFLICT OF INTEREST

No potential conflict of interest relevant to this article was reported.

#### REFERENCES

1. Ueda K, Tanaka T, Hayashi M, Tanaka N, Li TS, Hamano K. *Clinical ramifications of bronchial kink after upper lobectomy*. *Ann Thorac Surg* 2012;93:259-65.
2. Mueller DK, Foiles SR. *Right mainstem bronchial kink after right upper lobectomy*. *Ann Thorac Surg* 2007;84:1401.
3. Van Leuven M, Clayman JA, Snow N. *Bronchial obstruction after upper lobectomy: kinked bronchus relieved by stenting*. *Ann Thorac Surg* 1999;68:235-7.
4. Ibrahim E. *Bronchial stents*. *Ann Thorac Med* 2006;1:92-7.