

## Hyperthyroidism presenting as ST Elevation Myocardial Infarction with Normal Coronaries – A Case Report

Gayathri Devi Krishnan, Norhayati Yahaya, Mansor Yahya

*Hospital Raja Perempuan Zainab II, Kota Bharu, Kelantan, Malaysia*

### Abstract

A 31-year-old male, apparently well, presented with typical chest pain. His ECG showed ST-elevation from V1-V4 and echocardiogram revealed anteroseptal wall hypokinesia with ejection fraction of 45%. Normal coronary arteries were seen on coronary angiogram. A thyroid function test showed elevated free T4 levels with suppressed thyroid stimulating hormone (TSH). Treatment with thionamides and beta-blockers improved symptoms. Upon review 4 months later he was well. Repeat echocardiogram showed good ejection fraction with no hypokinetic area.

**Key words:** *thyrotoxicosis, Acute Myocardial Infarction (AMI), angina, Graves' disease, Myocardial Infarction with Non-Obstructive Coronary Arteries (MINOCA)*

### INTRODUCTION

An acute myocardial infarction (AMI) can be triggered by multiple factors like increased oxygen demand, hyperlipidemia, hypercoagulable states, coronary vasospasm and cocaine abuse.<sup>1</sup> Myocardial Infarction with Non-Obstructive Coronary Arteries (MINOCA) is an increasingly recognised entity.<sup>2</sup> It is well known that hyperthyroidism is associated with heart disease, and rarely, can cause AMI.<sup>3</sup> The mechanism for this is not fully understood, although there have been many postulations.<sup>1</sup> We present an interesting case of a young man with newly diagnosed thyrotoxicosis secondary to Graves' disease presenting with AMI and normal coronaries.

### CASE

A 31-year-old male with no prior medical illness presented to the Emergency Department with sudden onset of severe left-sided chest pain at rest, associated with palpitations, diaphoresis and dyspnea. Over the preceding month, he had palpitations, heat intolerance and lost 3 kg of weight. He denied use of illicit drugs. He is a smoker and works as a rubber tapper. Family history was non-contributory. On presentation, blood pressure was 133/86 mmHg, with heart rate of 137 beats per minute, regular with good volume. Cardiovascular and respiratory system examination were otherwise unremarkable. He had exophthalmos and a diffuse goitre measuring 9x6 cm, with no bruit. Electrocardiogram (ECG) showed sinus tachycardia with ST elevation in leads V1 to V4 (Figure 1). His complete blood count and renal profile were normal. Creatinine kinase-MB (CK-MB) done within 6 hours of presentation was normal; however, a Troponin level was not measured. Echocardiogram showed hypokinetic anteroseptal wall with ejection fraction 45%, normal

valves, chamber sizes and ventricular dimensions with no evidence of left ventricular hypertrophy. He was treated for ST elevation myocardial infarction and thrombolysed with intravenous (IV) Streptokinase. He was subsequently started on aspirin, clopidogrel, fondaparinux, metoprolol and atorvastatin. Despite resolution of pain, there was minimal reduction of ST elevation with poor R wave progression from V2-V5. Coronary angiography done 3 days later showed completely normal coronary vessels with no stenosis or spasm. Thyroid function test (TFT) revealed TSH- <0.005 mIU/L (0.4-4.0) and FT4- 66 pmol/L (7.86-14.4 pmol/L). Neck ultrasound showed a diffusely enlarged thyroid gland with increased vascularity. Burch-Wartofsky score on presentation was 30. A clinical diagnosis of Graves' disease with thyrotoxicosis was made. TSH receptor antibodies were not done as it was not supported by the local lab. He was started on carbimazole 30 mg daily, gradually tapered over 4 months, and propranolol 40 mg twice daily while all other medications were discontinued. Upon review 4 months later, he was well with good effort tolerance. He was clinically and biochemically euthyroid. A repeat electrocardiogram (ECG) showed persistent T-wave inversions in leads V2 to V5 with poor R-wave progression (Figure 2). Repeat echocardiogram showed normal chambers with ejection fraction 53% and no hypokinetic area.

### DISCUSSION

Myocardial infarction induced by thyrotoxicosis is rare with an incidence of 1.8% but is showing an upward trend<sup>4</sup> A subset of thyrotoxic patients can experience angina-like chest pain. Thyrotoxic angina is described as the following: (i) the presence of angina at rest, (ii) rapidly progressive angina, (iii) cessation of angina with treatment of hyperthyroidism and (iv) the lack of typical clinical

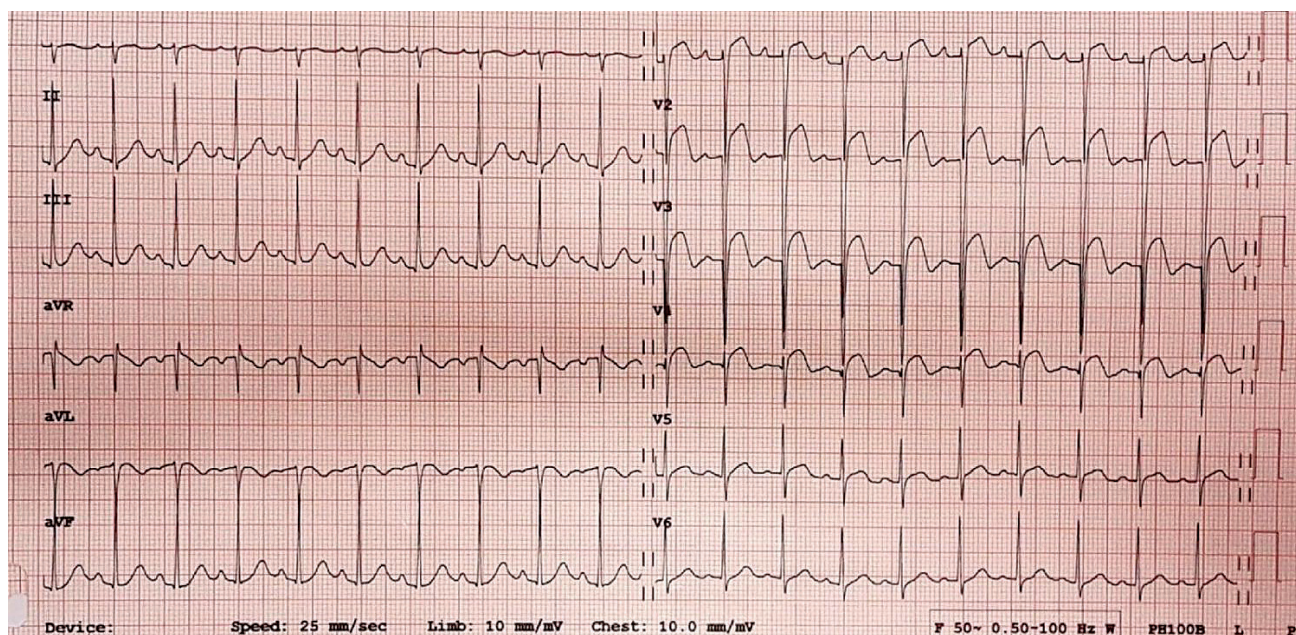


Figure 1. ECG upon arrival (March 2018).

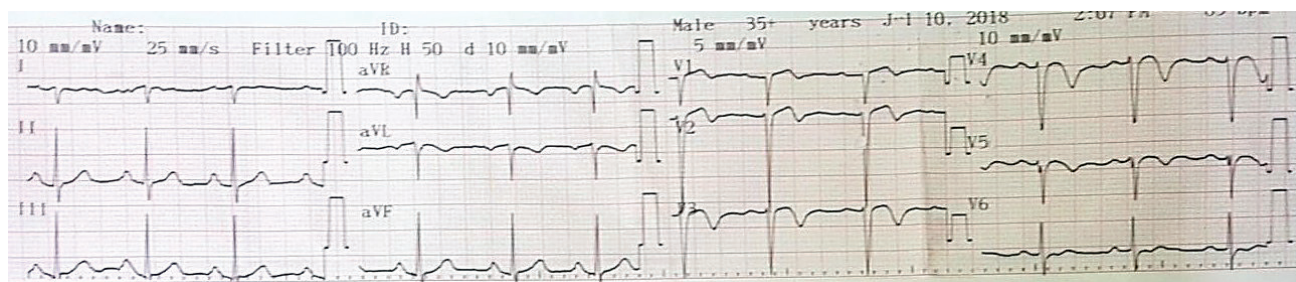


Figure 2. ECG upon review 4 months later (July 2018).

manifestations of hyperthyroidism upon presentation.<sup>5</sup> Myocardial Infarction with Non-Obstructive Coronary Arteries (MINOCA) is being increasingly recognised and has multiple potential underlying mechanisms.<sup>2</sup> The diagnosis of MINOCA requires: (i) clinical documentation of a myocardial infarct, (ii) exclusion of obstructive coronary arteries and (iii) no overt cause for the AMI presentation, such as cardiac trauma.<sup>2</sup>

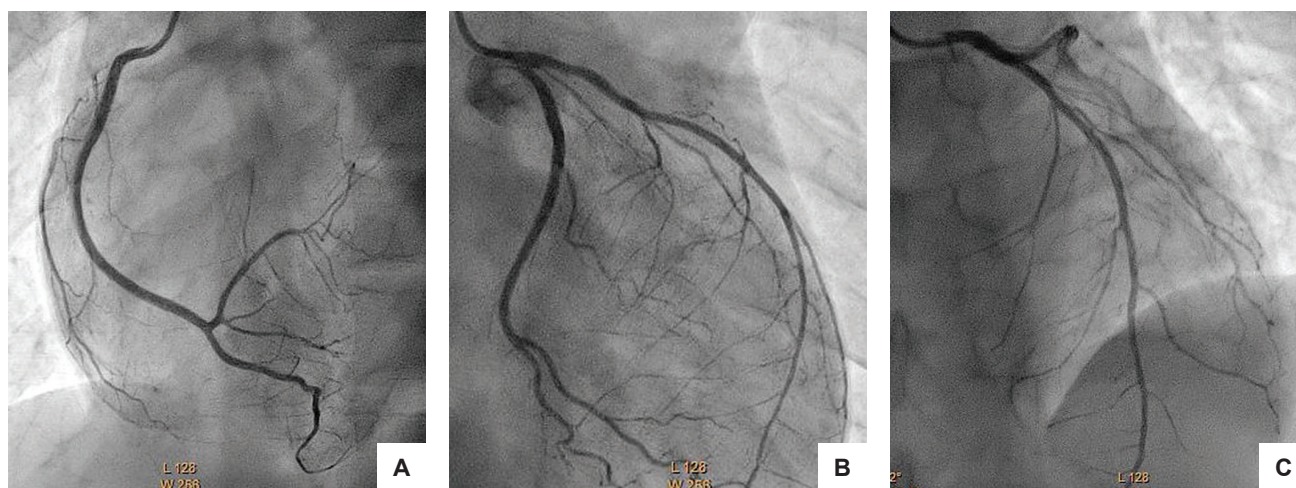
The exact cause of acute myocardial infarction (AMI) in thyrotoxic patients with normal coronary arteries is unclear. There are several proposed mechanisms such as temporary major coronary artery occlusion, small vessel disease and increased myocardial oxygen demand.<sup>1</sup> There is evidence that thyrotoxicosis is directly associated with the presence of a prothrombotic state.<sup>6</sup> Higher levels of prothrombotic factors and lower levels of anticoagulative factors have been demonstrated among patients with a history of thyroid cancer receiving TSH-suppressive L-thyroxine therapy in comparison the same subjects in hypothyroid phase prior to radioiodine whole-body scanning procedure.<sup>6</sup> Homoncik et al., reported raised concentrations of von-Willibrand factor (vWF) and increased baseline platelet plug formation in patients with thyrotoxicosis which were corrected by treatment of thyrotoxicosis with thionamides.<sup>7</sup> Vasospastic angina secondary to transient coronary vasospasm occurs in up to 20% of hyperthyroid patients, yet is difficult to confirm.<sup>8</sup> Diagnosis is suggested by finding a reversible

coronary artery stenosis on coronary angiography. However, the use of coronary angiography as a first diagnostic test in confirming this is not supported as iodine containing contrast agents used have the potential to induce thyrotoxicosis.<sup>3,5</sup> Possible mechanisms of thyrotoxicosis-induced vasospasm include enhanced coronary sensitivity to vasoconstrictors and reduced sensitivity to vasodilators.<sup>3</sup> Coronary vasospasm can also promote atherosclerosis by accelerating the formation of a thrombus and delaying fibrinolysis.<sup>3</sup> In a subgroup of females under 50 years old with documented coronary artery spasm, the incidence of hyperthyroidism was 29% and these subjects, like in our reported case, presented with severe myocardial ischemia.<sup>9</sup> Angina associated with coronary artery spasm among hyperthyroid patients resolve upon being rendered euthyroid.<sup>9</sup>

The documented aetiology of MINOCA include coronary artery spasm, microvascular dysfunction and thrombophilic states.<sup>2</sup> Although thyrotoxicosis has not been documented as a cause for MINOCA, the postulated mechanisms leading to thyrotoxicosis associated AMI is similar to some causes for MINOCA.

Our patient's coronary angiography did not demonstrate coronary vasospasm (Figure 3), possibly because it was done relatively late, after administration of nitrates and resolution of symptoms. Another postulate is that he had a clot occluding his coronary vessel which





**Figure 3.** Coronary angiogram (March 2018) showing: (A) Left- Normal right coronary artery (RCA); (B) middle- Normal left circumflex artery (LCx); (C) Right- Normal left anterior descending artery (LAD).

was successfully thrombolysed with IV Streptokinase. Limitations of this case report includes unavailability of a Troponin test that is a more sensitive marker confirming myocardial damage. This could have had added value as his CK-MB value was normal. A cardiac MRI if done early may be able to aid diagnosis in confirming the cause of initial cardiomyopathy. However, this was not done as the service was not readily available at our centre.

## CONCLUSION

Our case highlights that thyrotoxicosis can present as ST elevation myocardial infarction and may be a potential cause for MINOCA. A diagnosis of hyperthyroidism should be considered in a patient with little or no risk factors presenting with AMI.

### Ethical Consideration

Authors certified that all efforts to secure patient consent have been exhausted to no avail. All information in the case report has been provided without mention of name and every effort has been taken to ensure anonymity. They have sought permission from the Head of the Department of Medicine of Hospital Raja Perempuan Zainab II (HRPZ II) to publish the case.

### Statement of Authorship

All authors certified fulfillment of ICMJE authorship criteria.

### Author Disclosure

The authors declared no conflict of interest.

### Funding Source

None.

### References

1. Lee AYS, Chang MCK, Chen TJ. Acute coronary syndrome and hyperthyroidism. *Acta Cardiol Sin.* 2003;19:201-4.
2. Pasupathy S, Tavella R, McRae S, Beltrame JF. Myocardial Infarction with non-obstructive coronary arteries – Diagnosis and management. *Eur Cardiol.* 2015;10(2):79-82. PMID: 30310430. PMCID: PMC6159468. <https://doi.org/10.15420/ecr.2015.10.2.79>.
3. Kohno A, Hara Y. Severe myocardial ischemia following hormone replacement in two cases of hypothyroidism with normal coronary arteriogram. *Endocr J.* 2001;48(5): 565-72. PMID: 11789561.
4. Horne MK 3rd, Singh KK, Rosenfeld KG, et al. Is thyroid hormone suppression therapy prothrombotic? *J Clin Endocrinol Metab.* 2004;89(9):4469-73. PMID: 15356049. <https://doi.org/10.1210/jc.2004-0536>.
5. Homoncik M, Gessl A, Ferlitsch A, Jilma B, Vierhapper H. Altered platelet plug formation in hyperthyroidism and hypothyroidism. *J Clin Endocrinol Metab.* 2007; 92(8):3006-12. PMID: 17488803. <https://doi.org/10.1210/jc.2006-2644>.
6. Kuang XH, Zhang SY. Hyperthyroidism-associated coronary spasm: A case of non-ST segment elevation myocardial infarction with thyrotoxicosis. *J Geriatr Cardiol.* 2011;8(4):258-9. PMID: 22783313. PMCID: PMC3390094. <https://doi.org/10.3724/SP.J.1263.2011.00258>.
7. Somerville W, Levine SA. Angina pectoris and thyrotoxicosis. *Br Heart J* 1950;12(3):245-57. PMID: 15426686. PMCID: PMC479393.
8. Choi YH, Chung JH, Bae SW, et al. Severe coronary artery spasm can be associated with hyperthyroidism. *Coron Artery Dis.* 2005;16(3):135-9. PMID: 15818081.
9. Dedov II, Kalashnikov Vlu, Terekhin SA, et al. Fatal coronary artery spasm in a patient with thyrotoxicosis. *Kardiologiya.* 2012;52(11):92-6. PMID: 23237402.

Authors are required to accomplish, sign and submit scanned copies of the JAFES Author Form consisting of: (1) Authorship Certification, that authors contributed substantially to the work, that the manuscript has been read and approved by all authors, and that the requirements for authorship have been met by each author; (2) the Author Declaration, that the article represents original material that is not being considered for publication or has not been published or accepted for publication elsewhere, that the article does not infringe or violate any copyrights or intellectual property rights, and that no references have been made to predatory/suspected predatory journals; (3) the Author Contribution Disclosure, which lists the specific contributions of authors; and (4) the Author Publishing Agreement which retains author copyright, grants publishing and distribution rights to JAFES, and allows JAFES to apply and enforce an Attribution-Non-Commercial Creative Commons user license. Authors are also required to accomplish, sign, and submit the signed ICMJE form for Disclosure of Potential Conflicts of Interest. For original articles, authors are required to submit a scanned copy of the Ethics Review Approval of their research as well as registration in trial registries as appropriate. For manuscripts reporting data from studies involving animals, authors are required to submit a scanned copy of the Institutional Animal Care and Use Committee approval. For Case Reports or Series, and Images in Endocrinology, consent forms, are required for the publication of information about patients; otherwise, appropriate ethical clearance has been obtained from the institutional review board. Articles and any other material published in the JAFES represent the work of the author(s) and should not be construed to reflect the opinions of the Editors or the Publisher.