

Received: 2012.12.12  
Accepted: 2013.02.08  
Published: 2013.06.07

## A rare case of adverse effects caused by leech bite

Authors' Contribution:  
Study Design A  
Data Collection B  
Statistical Analysis C  
Data Interpretation D  
Manuscript Preparation E  
Literature Search F  
Funds Collection G

ABCDEFG 1 **Ugur Lok**  
ABCDEFG 2 **Selim Bozkurt**  
ABCDEFG 2 **Mehmet Okur**  
ABCDEFG 1 **Umut Gulacti**  
ABCDEFG 3 **Sinan Hatipoglu**

1 Department of Emergency, Adiyaman University, Adiyaman, Turkey  
2 Department of Emergency, Sutcu Imam University, Kahramanmaraş, Turkey  
3 Department of General Surgery, Adiyaman University, Adiyaman, Turkey

**Corresponding Author:** Sinan Hatipoglu, e-mail: hamitsinanh@gmail.com

**Patient:** Female, 42  
**Final Diagnosis:** Leech bite  
**Symptoms:** —  
**Medication:** —  
**Clinical Procedure:** —  
**Specialty:** Infectious diseases

**Objective:** Unusual clinical course





**Background:** *Hirudo medicinalis* (*H. Medicinalis*), also referred to as the medical leech, not only has been used by alternative medicine since ancient times, but it has also been used in modern medical care in the last century. This report introduces and discusses some rare complications from leech bite, beyond external skin hemorrhage.

**Case Report:** A 42-year-old woman was referred to our emergency room with painful and itchy lesions on her feet and legs. Because of her knee and leg pain, about 14 leeches were adhered onto both her legs. There were left rubor, tumor and some other areas of itching on leech-adhered regions. In physical examination, the right popliteal region and the same leg posterior area lesions were erythematous, edematous, and plaque-like shaped, as well as ecchymotic and hemorrhagic areas at the centre of the lesions.

**Conclusions:** In this article we present the case of a woman referred to our emergency department with skin findings related to a leech bite. We could not find any report about regional subcutaneous hematoma and cutaneous reactions in the literature. *H. medicinalis* may cause ecchymosis and various skin lesions, not only external skin bleeding. Physicians should keep in mind leech bite in patients with itchy lesions on the calves, knees, and feet.

**Key words:** leech bite • complications of leech bite • regional subcutaneous hematoma • cutaneous reactions

**Full-text PDF:** <http://www.amjcaserep.com/download/index/idArt/883936>

 904  —  2  11

## Background

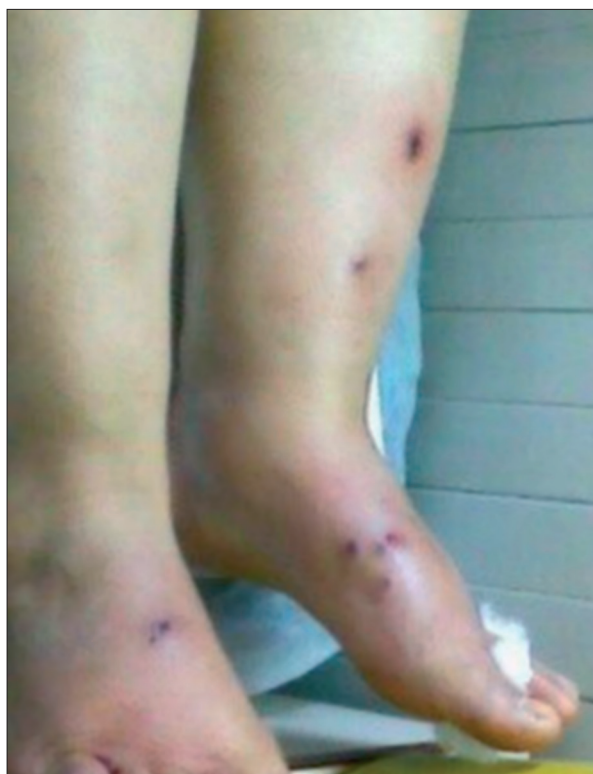*Hirudo medicinalis* (*H. medicinalis*), commonly termed the medical leech, has been used by medicine since ancient times, but has been also used in modern medicine in the last century. It is also often used to follow-up some flap and re-implantation of the graft after surgery by general surgeons to prevent venous congestion and maintain circulation [1]. In our region, *H. medicinalis* is used for as a folk remedy for treatment of joint and muscle pain. Although some cases have been reported related to vaginal, rectal, nasal, and external cutaneous bleeding with leech bite, we found no reports about regional subcutaneous hematoma and cutaneous reactions in the literature [2–6]. We present a case of regional cutaneous reactions and ecchymose caused by a leech bite.

## Case Report

A 42-year-old woman was referred to our emergency room with painful and itchy lesions on her feet and legs. She said that because of her chronic pain in the knee and legs, she had adhered about 14 leeches, which she found in a local freshwater pond, to her legs, knees and feet 1 day before. After the leeches dropped from her extremities, there were rubor, tumor, and some other areas of itching on the leech-adhered parts of her body. Due to the increasing severity of her symptoms, she came our hospital emergency department. She also said that because of knee pain, leeches from the same pond had been adhered on her legs and knee about 3 years ago, and at that time there were no symptoms and the knee pains had been relieved.

Physical examination revealed a cooperative, oriented patient in good general condition. Vital signs were stable (blood pressure 110/80mmHg, pulse rate 84 bpm, respiration rate 14 pm, and temperature 36°C). There were 14 leech bites on both of her lower extremities. The lesions, located at dorsal areas of both feet and the front of her left leg, were hemorrhagic, vesicular, and surrounded with erythema (Figure 1). On the right popliteal region and the posterior area the same leg, lesions were erythematous, edematous, and areas at the centre of the lesions were plaque-shaped, purple, ecchymotic, and hemorrhagic (Figure 2). There was no active bleeding or local fever. Blood tests results were: hemoglobin, 10.4 g/d; hematocrit, 31.1%; white blood cells, 7650/mm<sup>3</sup>; platelet counts, 361.000/mm<sup>3</sup>; PT (prothrombin time), 11.4 second; aPTT (activated partial thromboplastin time), 33.1 seconds; and INR (international normalized ratio) 0.86.

The lesions were cleaned with an antiseptic solution and covered by sterile gauze. Ciprofloxacin (Cipro 500 mg tablets,

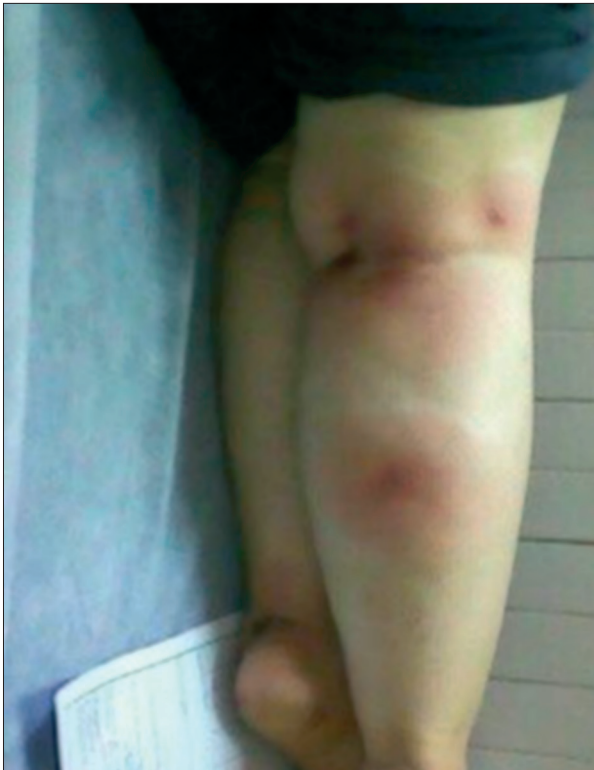

**Figure 1.** Both feet at dorsal area and left leg in front area, were hemorrhagic, vesicular, and surrounded with erythema.

Biofarma, Turkey) 2×500 mg/day per oral was prescribed for antibiotic prophylaxis.

## Discussion

*H. medicinalis* is a leech species that weighs 3–6.5 grams, is 10–15 cm in length, and consists of 34 segments. It can ingest 3–10 times its body weight in blood at a single feeding [7]. *H. medicinalis* sucks blood without causing pain, by dissecting the skin with 3 sharp teeth located in its upper jaw, simultaneously releasing mediators in to the bite via its saliva [8]. These mediators are hirudin, calin and bdellin. The mediators have very strong anticoagulant activity that activate various parts of the coagulation cascade and extend bleeding time by inhibiting platelet aggregation [9,10]. Using *H. medicinalis* for medical treatment, termed leech therapy, may result in prolonged bleeding and bacterial infections. Additionally *Aeromonas hydrophilia*, which lives in the leech's digestive tract, may cause pneumonia, septicemia, and gastroenteritis. Antibiotic therapy should be given to patients how have been bitten by leeches [7]. Although there have been reports of prolonged bleeding and local infection, to the best of our knowledge no cases with local skin reaction and subcutaneous hemorrhage, as in our patient, have been reported in the literature.



**Figure 2.** Right popliteal region and the same leg posterior area lesions were erythematous, edematous, plaque-shaped, and there were purple, ecchymotic, and hemorrhagic areas at the centre of the lesions.

Michalsen et al. [11] in a study of a small group of patients, reported that the leech can be safely used for symptomatic relief of knee pain resulting from osteoporosis. Also they reported that in patients with leech therapy were applied, there is a

## References:

1. Ayik E, Gurler N, Kuvat SV et al: Comparison of Different Prophylaxis Methods to Prevent Infections in Leech Using: preliminary report. ANKEM, 2006; 20: 76–80
2. Hasanzadeh Mofrad M, Shafiei R, Bolandi S et al: Leech bite: a rare cause of postmenopausal vaginal bleeding. Iran Red Crescent Med J, 2012; 14: 384–85
3. Al B, Yenen ME, Aldemir M: Rectal bleeding due to leech bite: a case report. Ulus Travma Acil Cerrahi Derg, 2011; 17: 83–86
4. Guloglu C, Al B, Ozhasenekler A et al: The leech as an unusual cause of epistaxis, chronic anemia, and obstruction of upper respiratory tract: our experiences due to two cases. The Journal of Medical Investigations, 2004; 2: 45–48

clinically unimportant decrease of hemoglobin, and only 1 patient had bleeding as a leakage lasting up to 12 hours. In our case, the patient declared that she used leeches for treatment of her chronic knee and foot pain. When the patient applied the same type of leeches to her knees and feet about 3 years ago, she experienced no problems, but this time she had itchiness and subcutaneous bleeding at the sites of the leech bites.

Kose et al. [5] reported on a 65-year-old male patient who had 130 leech bites on various parts of his body, and who had ongoing external bleeding from bite sites, prolonged bleeding time, and severe decline in hemoglobin value. They also reported that they used 6 units of erythrocyte suspension and 8 units of fresh frozen plasma for treatment of the same patient. Hirudin, calin and bdellin, all present in leech saliva, may cause severe bleeding, and the control of hemorrhage can be difficult. In our case, there was low hemoglobin value, but no need for erythrocyte transfusion or fresh frozen plasma.

## Conclusions

*H. medicinalis* may cause ecchymosis and various skin lesions, not only external bleeding, such as in our patient. The leech history of leech therapy elicited in patients with itchy lesions on the calves, knees, and feet, and physicians should consider the possibility of leech bite. People should be alerted about complications caused by leech bites.

## Statement

The authors report they have no conflicts of interest in regard to this article.

5. Kose A, Zengin S, Kose B et al: Leech bites: Massive bleeding, coagulation profile disorders, and severe anemia. Am J Emerg Med, 2008; 26: 1067 e3–6
6. Ikizceli I, Avsarogullari L, Sozuer E et al: Bleeding due to a medicinal leech bite. Emerg Med J, 2005; 22: 458–60
7. Godekmerdan A, Arusan S, Bayar B, Saglam N: Medicinal Leeches and Hirudotherapy. Turkiye Parazitoloji Derg, 2011; 35: 234–39
8. Singh AP: Medicinal leech therapy (hirudotherapy): a brief overview. Complement Ther Clin Pract, 2010; 16: 213–15
9. Eldor A, Orevi M, Rigbi M: The role of the leech in medical therapeutics. Blood Reviews, 1996; 10: 201–9
10. Baskova IP, Kostjukova ES, Vlasova MA et al: Proteins and Peptides of the Salivary Gland Secretion of Medicinal Leeches *Hirudo verbana*, *H. medicinalis*, and *H. orientalis*. Biochemistry (Moscow), 2008; 73: 315–20
11. Michalsen A, Klotz S, Lüdtke R et al: Effectiveness of leech therapy in osteoarthritis of the knee: a randomized, controlled trial. Ann Intern Med, 2003; 139: 724–30