

CASE REPORT

Nagoya J. Med. Sci. **84**. 673–677, 2022
doi:10.18999/najjms.84.3.673

Challenges in left sleeve pneumonectomy in the left lateral decubitus position

Shota Nakamura¹, Takayuki Fukui¹, Hideki Ito², Masaki Goto¹,
Naoki Ozeki¹ and Toyofumi Fengshi Chen-Yoshikawa¹

¹*Department of Thoracic Surgery, Nagoya University Graduate School of Medicine, Nagoya, Japan*

²*Department of Cardiac Surgery, Nagoya University Graduate School of Medicine, Nagoya, Japan*

ABSTRACT

We report the case of a 20-year-old woman with carinal adenoid cystic carcinoma who underwent left sleeve pneumonectomy in the left lateral decubitus position, during which severe desaturation was encountered. After transecting the left main bronchus, the left lung was selectively intubated and ventilated. However, oxygenation was inadequate. Hence, venoarterial extracorporeal membrane oxygenation (ECMO) was introduced. Initially, Barclay's procedure was planned to preserve the left lung, but this plan was altered due to the extent of the tumor and unstable ventilation. After the lesion was removed, the trachea and right main bronchus were anastomosed end-to-end. During left pneumonectomy, the right lung was selectively ventilated, but oxygen saturation (SpO₂) dropped to <70% despite ECMO. SpO₂ improved on additionally ventilating the left lung using another breathing circuit. Temporary right chest closure was performed with ventilation of the left lung across the thoracotomy wound. The patient was turned to the semi-supine position, and tolerated selective right lung ventilation with ECMO. Subsequently, left thoracotomy and pneumonectomy were successfully performed. Careful management is required for desaturation in left sleeve pneumonectomy in the left lateral decubitus position.

Keywords: adenoid cystic carcinoma, sleeve pneumonectomy, carinal resection

Abbreviations:

ECMO: extracorporeal membrane oxygenation

SpO₂: oxygen saturation

This is an Open Access article distributed under the Creative Commons Attribution-NonCommercial-NoDerivatives 4.0 International License. To view the details of this license, please visit (<http://creativecommons.org/licenses/by-nc-nd/4.0/>).

INTRODUCTION

Malignancies arising in the trachea and carina are extremely rare. According to an academic survey by the Japanese Association of Cardiothoracic Surgery in 2017, among 85,307 total surgeries, tracheal resection/reconstruction and carinal reconstruction were performed in 28 (0.03%) and 31 (0.03%) cases, respectively.¹ Because of this rarity, the optimal treatment strategy must be

Received: November 1, 2021; accepted: November 17, 2021

Corresponding Author: Toyofumi Fengshi Chen-Yoshikawa, MD, PhD

Department of Thoracic Surgery, Nagoya University Graduate School of Medicine, 65 Tsurumai-cho, Showa-ku, Nagoya 466-8550, Japan

Tel: +81-52-741-2375, Fax: +81-52-744-2382, E-mail: tyoshikawa@med.nagoya-u.ac.jp

considered on a case-by-case. However, these tumors are rare for everyone, we thoracic surgeons often wonders if the optimal choice of treatment was made. Herein, we report the case of a 20-year-old woman with carinal adenoid cystic carcinoma who underwent left sleeve pneumonectomy in the left lateral decubitus position, during which severe desaturation was encountered.

CASE PRESENTATION

A 20-year-old woman visited a nearby hospital because of wheezing since 2 years. Chest computed tomography revealed a tumor extending from the lower trachea to the carina (Fig. 1A). The tumor was cored out, and a Dumon stent placed at another hospital (Fig. 1B). Histological diagnosis was adenoid cystic carcinoma. She was referred to our hospital and underwent surgical resection of the residual tumor and sparing of the left lung if possible, depending on the tumor extension. Before the day of the scheduled operation, she developed bilateral pneumonia and was treated with antibiotics for 2 weeks. The operation was rescheduled.

At surgery, two sheaths for extracorporeal membrane oxygenation (ECMO) were inserted from the femoral artery and vein. The patient was placed in the left lateral decubitus position, and a right thoracotomy was performed. After transecting the left main bronchus approximately 2.5 cm from the carina due to tumor extension, the left lung was selectively intubated and ventilated (Fig. 1C). However, oxygenation was inadequate. Hence, venoarterial ECMO was established with femoral vein drainage and femoral arterial return, and oxygen saturation (SpO₂) of >90% was achieved (Fig. 2A). Perfusion Index was 2.5L/min/m², and central venous pressure was 8 mmHg under the ECMO. Initially, Barclay's procedure was planned to preserve the left lung, but this plan was altered due to the extent of the tumor.² After the lesion was removed, the trachea and right main bronchus were anastomosed end-to-end (Fig. 1D). During left pneumonectomy, the right lung was selectively ventilated, but SpO₂ dropped to <70% despite ECMO (Fig. 2B). SpO₂ improved on additionally ventilating the left lung using another breathing circuit. Temporary chest closure of the right lung was performed with ventilation of the right lung across the thoracotomy wound. The patient was turned to the semi-supine position, and tolerated selective right lung ventilation with ECMO. Subsequently, left thoracotomy and pneumonectomy were successfully performed in collaboration with cardiac surgeons. She recovered well and was discharged from the hospital on postoperative day 19 without complications.

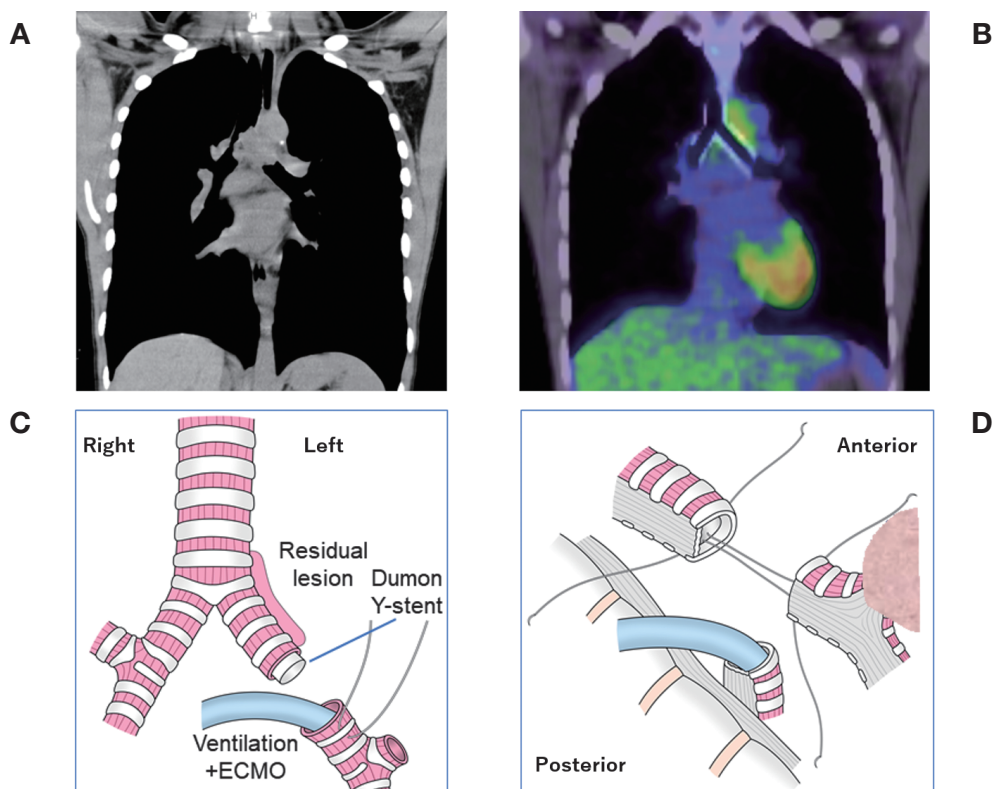


Fig. 1 Pre-operative computed tomography (CT), positron-emission-tomography / CT images and intraoperative schematic images

Fig. 1A: A large tumor extended from the lower trachea to the carina.

Fig. 1B: After a Dumon stent was placed, positron emission tomography showed slight accumulation in the residual tumor.

Fig. 1C: With left lung ventilation and extracorporeal membrane oxygenation, the trachea and right main bronchus were transected, and the lesion was removed.

Fig. 1D: The trachea and right main bronchus were anastomosed.

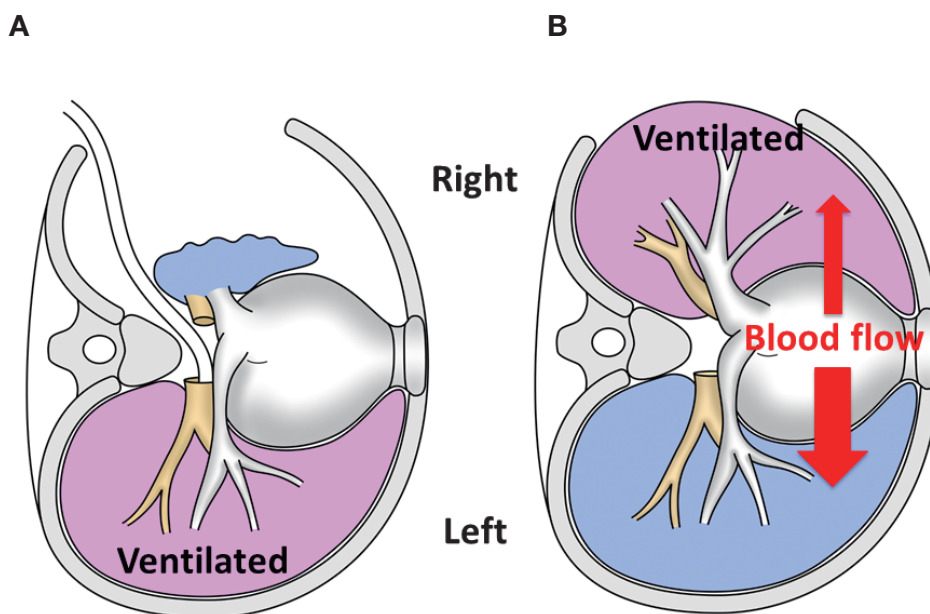


Fig. 2 Intraoperative schematic images

Fig. 2A: The first desaturation required extracorporeal membrane oxygenation.

Fig. 2B: Shunt flow caused the second desaturation.

DISCUSSION

Various approaches, including median sternotomy, left thoracotomy, bilateral thoracotomy, and clamshell incision, to perform left sleeve pneumonectomy or carinal resection have been reported.³⁻⁶ Although, left thoracotomy is a simple procedure, obtaining a good operative field for the anastomosis is difficult. Although median sternotomy is suitable for access to the trachea and carina, access to the left thoracic structures is difficult. Left sleeve pneumonectomy through clamshell incision may be safer, easier, and less invasive than other methods.^{3,4} Recently, as a less invasive approach, left pneumonectomy via video-assisted thoracic surgery followed by carinal resection and reconstruction via right thoracotomy was reported by Fujino et al⁵ In the present case, we first chose right thoracotomy because of the possibility of performing Barclay's procedure.² However, the lesion had extended to the bronchial periphery; thus, the preservation of the left lung was considered impossible.

In terms of desaturation, the first event occurred when the left lung was selectively ventilated after transection of the left main bronchus at a deeper level because of the tumor extension, resulting in deeper tube position and dislocation. Furthermore, the patient developed left pneumonia preoperatively and might not have fully recovered. Second, after anastomosis of the trachea and right main bronchus, the right lung was selectively ventilated, but oxygenation was poor, despite ECMO assistance. As oxygenation improved when left lung ventilation was restarted, a significant imbalance in blood flow due to the lateral decubitus position exacerbated the shunt effect. Even with ECMO support, the patient's own cardiac output with a dominant shunt flow from the left lung would have impaired oxygenation of the whole body. We should be cautious of these episodes of desaturation during left sleeve pneumonectomy via right thoracotomy. Furthermore,

it might have been disastrous had we performed Barclay's procedure and a desaturation had occurred during the anastomosis of the left main bronchus to the right bronchus.

CONCLUSION

We report the case of a 20-year-old woman with carinal adenoid cystic carcinoma who underwent left sleeve pneumonectomy in the left lateral decubitus position, during which severe desaturation was encountered. We should be cautious of desaturation during left sleeve pneumonectomy via right thoracotomy.

CONFLICTS OF INTEREST

The authors have nothing to disclose.

REFERENCES

- 1 Committee for Scientific Affairs, Japanese Association for Thoracic Surgery, Shimizu H, Okada M, et al. Thoracic and cardiovascular surgeries in Japan during 2017: Annual report by the Japanese Association for Thoracic Surgery. *Gen Thorac Cardiovasc Surg.* 2020;68(4):414–449. doi:10.1007/s11748-020-01298-2.
- 2 Barclay RS, McSwan N, Welsh TM. Tracheal reconstruction without the use of grafts. *Thorax.* 1957;12(3):177–180. doi:10.1136/thx.12.3.177.
- 3 Nakajima T, Yoshida S, Yoshino I. Left carinal pneumonectomy using left bronchostomy: a novel technique of crossfield intubation. *J Thorac Cardiovasc Surg.* 2017;153(2):472–475. doi:10.1016/j.jtcvs.2016.10.021.
- 4 Miyazaki T, Yamasaki N, Tsuchiya T, et al. Left sleeve pneumonectomy via a clamshell incision for lung cancer with carinal invasion: report of a case. *Surg Today.* 2012;42(6):593–596. doi:10.1007/s00595-011-0111-7.
- 5 Fujino T, Tanahashi M, Yukiue H, et al. A new approach to left sleeve pneumonectomy: complete VATS left pneumonectomy followed by right thoracotomy for carinal resection and reconstruction. *Surg Case Rep.* 2018;4(1):91. doi:10.1186/s40792-018-0496-2.
- 6 Grillo HC. Carinal reconstruction. *Ann Thorac Surg.* 1982;34(4):356–373. doi:10.1016/s0003-4975(10)61394-x.